COLUMBIA LIBRARIES OFFSITE
HEALTH SCIENCES RESTRICTED
HR01093835

V.22
1904
J
Columbia University
in the City of New York
College of Physicians and Surgeons

Reference Library

Digitized by the Internet Archive
in 2014

https://archive.org/details/journalofcutaneo2219amer

The Journal of Cutaneous Diseases

Including

SYPHILIS

Under the Editorial Direction of

James C. White,, M.D.	Boston
James Nevins Hyde, M. D.	Chicago
Edward B. Bronson, M.D.	New York
William T. Corlett, M.D.	Cleveland
Henry W. Stelwagon, M.D.	Philadelphia
George T. Jackson, M.D.	New York
John T. Bowen, M.D.	Boston
John A. Fordyce, M.D.	New York

A. D. Mewborn, M.D., New York
Editor

Volume XXII
1904

THE GRAFTON PRESS
70 Fifth Avenue
New York

Copyright 1904 by
The Grafton Press

INDEX TO VOLUME XXII

LIST OF ORIGINAL COMMUNICATIONS ARRANGED BY NAMES OF AUTHORS.

Arnold, W. F.—Method of Using Surgeon W. F. Arnold, U. S. Navy's Phototherapeutic Apparatus....23
Berry, T. D.—Report of Personal Case of Papilloma of the Sole....228
Bentz, C. A.—See Wende, Grover W.
Bowen, J. T.—Peculiar Inclusions in Lupus-like Tissue....10
Bowen, J. T.—Editorial—Recent Investigations on the Protozoa as Causes of Disease....80
Bowen, J. T.—Acute Infectious Pemphigus in a Butcher, During an Epizootic of Foot and Mouth Disease, with a Consideration of the Possible Relationship of the Two Affections....253
Breakey, W. F.—Parasitic Sycosis Communicated from Cattle....566
Carrier, H. E.—A Case of Mycosis Fungoides Treated by the X-ray....73
Corlett, W. T.—Notes on Certain Post-Vaccinal Eruptions....495
Engman, M. F.—Report of a Case of Bullous Lichen Planus. ("Lichen Planus Pemphigoides")....207
Engman, M. F.—Affections of the Mucous Membranes in Relation to Skin Diseases, 412
Fordyce, J. A.—Symmetrical Cutaneous Atrophy with the Coincident Development of Syphilis of the Skin and Nervous System....155
Fordyce, J. A.—Affections of the Mucous Membranes in their Relation to Skin Diseases....397
Gilchrist, T. C.—Some Additional Cases of Blastomycetic Dermatitis....107
Gilchrist, T. C.—Erysipeloid, with a Record of 329 Cases, of Which 323 Were Caused by Crab Bites, or Lesions Produced by Crabs....507
Gottheil, W. S.—A Case of Feigned Eruption....19
Hall, G. C.—See Koehler.
Hamburg, L. P.—Creeping Eruption: Its Relation to Myiasis....217
Hardaway, W. A.—A Further Report of a Case of Multiple Myomata of the Skin, 375
Hartzell, M. B.—Granuloma Pyogenicum (Botryomycosis of French Authors), 520
Heidingsfeld, M. L.—A Tentative Suggestion Regarding the Nature and Character of X-rays....24
Hyde, J. Nevins.—Editorial—The Passing of "Eczema"....30
Hyde, J. Nevins.—Editorial—The Fifth International Dermatological Congress, 130
Hyde, J. Nevins.—Editorial—The Fifth and Sixth Congresses of Dermatology....525
Hyde, J. Nevins and McEwen, E. L.—The Relation of Certain Dermatoses to Each Other and to Changes in Vascular Equilibrium....547
Jackson, Geo. T.—The Removal of Warts, Moles, and Other Facial Blemishes....122
Klotz, H. G.—A Case of Chronic Symmetrical Diffuse Hyperæmia of the Extremities (Erythromelie)....169
Klotz, H. G.—A Case of Reinfection of Syphilis....317
Koehler, H. H. and G. C. Hall.—Report of a Case of Blastomycosis....581
Lesser, E.—The Warfare Against Venereal Diseases in Germany....276
Montgomery, D. W.—Vitiligo Treated with Finsen Light....17
Montgomery, D. W.—A Tuberous Iodide of Potash Eruption Simulating Histologically an Epithelioma....59
Montgomery, D. W. and Howard Morrow.—Reasons for Considering Dermatitis Coccidioidides an Independent Disease....368
Morrow, Howard.—See Montgomery, D. W.
Moses, Mortimer A.—Atypical Lesions in Ichthyosis....65
Myers, Lotta W.—A Rare Bromide Eruption....231
Patek, Arthur J.—Dermatitis Exfoliativa Neonatorum or Ritter's Disease....269
Pick, Walther.—Tumor-like Forms of Tuberculosis of the Skin....305
Piffard, H. G.—Preliminary Note Relative to the More Efficient Utilization of the Spark-Gap Radiations....265
Ravogli, Augustus.—Lichen Planus Verrucosus....573

Shattuck, Frederick C.—A Case of Lymphatic Leukæmia with Purpura.....118
Schamberg, Jay F.—An Inquiry into the Etiology and Nature of the Toxic Erythemata 461
Stelwagon, H. W.—A Peculiar Eczematoid Eruption of the Lip Region.....351
Stelwagon, H. W.—A Second Case of Creeping Eruption (Lee), Larva Migrans (Crocker), Hyponomoderma (Kaposi), Dermamyiasis Linearis Migrans Œstrosa (Kumberg); with brief reference to three other cases unpublished, 359
Towle, Harvey P.—Pityriasis Rosea.....176
Wende, Grover W.—A Case of Epidermolysis Bullosa Hereditaria, associated with Congenital Alopecia and Atrophy of the Finger Ends.....14
Wende, Grover W. and C. A. Bentz.—Rhinophyma.—A Pathological Analysis of Five Separate Tumors Occurring in the Same Patient.....447
Woolley, Paul G.—Pinta; Paño Blanco.....479
Wallhauser, H. J. F.—A Case of Actinomycosis.....77
White, James C.—Some Notes Concerning Domestic Remedies Formerly Used in Skin Diseases.....362
Whitehouse, H. H.—Xanthoma Multiplex; Histology of the Palmar Striæ.....470
Wright, James H.—Protozoa in a Case of Tropical Ulcer ("Aleppo Boil").....1
Zeisler, Joseph.—President's Address, American Dermatological Association.....301
Zeisler, Joseph.—Editorial—"Feuilleton".....527

ALPHABETICAL LIST OF AUTHORS WHOSE WORKS ARE PUBLISHED OR ANALYZED IN THIS VOLUME.

A

Adamson, 443.
Adler, T., 297.
Allen, H. S., 146.
Allen, C. W., 86, 102, 189, 190, 235, 236.
Arnold, W. F., 23.
Apolant, 440.
Ashmead, 347.
Ayers, S., 146.

B

Balzer, 340, 341.
Bancroft, I. R., 543.
Barbe, 195.
Beck, C., 350.
Belot, 439.
Bentz, C. A., 447.
Bering, F., 55.
Berry, T. D., 228.
Bisserie, 439.
Bodin, 195, 196.
Boissard, 291.
Bowen, J. T., 10, 33, 34, 36, 37, 40, 41, 80, 237, 253, 335.
Breakey, W. F., 566.
Brinckerhoff, W. R., 543.
Brinkley, 589, 590.
Briquel, P., 299.
Brocq, L., 93, 439, 541.
Bronson, E. B., 43, 232, 380.
Brownrigg, A. E., 144.
Bruusgaard, F., 139.
Bukovsky, J., 443.
Bulkley, L. D., 91, 235.
Burns, F. S., 238, 242, 328.

C

Caldwell, E W., 151.
Calkins, G. N., 543.
Campana, 55.
Campbell, H., 146.
Campbell, H. J., 535.
Carle, 444.
Carrier, A. E., 73, 439.
Cathcart, C. W., 536.
Cedercreutz, A., 482.
Ceni, 51.
Corlett, W. T., 495.
Councilman W. T., 543.
Curtis, F. C., 243.

D

Danlos, 195, 592.
Darier, 195.
DeBeurmann, 196.
Delbanco, E., 492.
Dillingham, F. H., 348.
Doland, 99.
Dor, 48.
Druelle, 54, 489.
Dubreuilh, W., 391.
DuCastel, 54, 202, 247, 341.
Dugros, 341.

E

Ehrman, O., 55, 295.
Elliot, G. T., 440.
Engman, M. F., 103, 207, 412.
Erb, 144.
Etwetsky, Th. v., 299.
Eustis, A. C., 486.
Evans, W., 198.

F
Feuerstein, L., 296.
Filaretopoulo, 99.
Fischer, 52.
Fonovnont, 50.
Forbes, J. G., 248.
Fordyce, J. A., 83, 88, 93, 155, 187, 283, 284, 382, 383, 397.
Fouquet, 340, 341.
Fox, G. H., 190, 194, 279, 280, 378, 383, 585, 586, 591.
Fox, T. C., 246.

G
Galewsky, 143.
Gaucher, 248.
Gilchrist, T. C., 107, 507.
Gottheil, W. S., 19, 52.
Gowers, W. R., 147.
Guichard, 98.
Gulcke, N., 148.

H
Haig, A., 154.
Halkin, 100.
Hall, G. C., 581.
Hallopeau, 343, 344, 395, 442, 444.
Hamburger, L. P., 217.
Hammond, G. M., 147.
Hardaway, W. A., 375.
Harding, 34, 36, 37, 133, 326, 329.
Hartzell, M. B., 520.
Hectoen, L., 245.
Heidingsfeld, 24, 348.
Hess, O., 533.
Hippel, 294.
Hoche, L., 299.
Hochsinger, C., 493.
Hohfeld, 94.
Howe, J. S., 240.
Hulleu, 150.
Hutinel, 292.
Hyde, J. N., 30, 103, 130, 430, 527, 547, 596.

I
Iwanow, W. M., 56.

J
Jackson, G. T., 122, 184, 191, 378, 387.
Jacobi, 106.
Jamieson, A., 102, 438.
Jeanselme, E., 396.
Jourdran, 50.

K
Klauber, O., 388.
Klotz, H. G., 170, 183, 317.
Koehler, H. H., 581.
Kopytowski, W., 342.
Kothe, R., 392.
Kraus, A., 94.
Kreibich, K., 491.
Kreiso, 56.
Krompecher, E., 533.
Kuhn, 95.
Kryzstalowicz, F., 484, 537.

L
Lebrel, 395.
Ledermann, 53, 54, 299.
Leredde, 105, 144, 250, 445.
Lesser, E., 276.
Lesser, F., 148.
Lustgarten, 185, 193, 440.

M
Macleod, J. M. H., 204.
Magrath, G. B., 543.
Marbury, 291.
McCollum, 38.
Marsh, 439.
Mason, J. M., 349.
Matzenauer, 250.
Méneau, J., 593.
Mewborn, A. D., 88, 192, 234, 236, 282, 286, 387, 588, 589.
Meyer, G., 252.
Meyer, J., 489.
Mibelli, 490.
Monsarrat, R. M., 535.
Montgomery, D. W., 17, 59, 368, 596.
Montgomery, F. H., 103, 439.
Morris, H., 198.
Morris, Malcolm, 140, 153.
Morrow, H., 368.
Morrow, P. A., 205.
Moses, M. A., 65.
Moyer, H. M., 145.
Myers, L. W., 231.
Müller, F., 142.

N
Neumann, 201.
Nicolau, 487.
Nocton, 341.
Northrup, 57.

O
Ormsby, 103, 439.
Osler, 57, 538.

P
Patek, A. J., 269.
Pautrier, L., 488.
Philippson, 140.
Pick, W., 304.
Piffard, 44, 265, 285.
Plimmer, 200.
Post, 37, 39, 136, 137, 139.
Pringle, 106.
Pusey, 151.

R
Ramond, 196.
Ravogli, 573.
Renault, A., 151, 296.

Richon, 249.
Riehl, 438.
Roger, 197.
Rose, A., 143.
Rostaine, 248.

S
Sabouraud, 394, 441.
Sajous, C. De M., 58, 92.
Schamberg, 151, 244, 461.
Schein, M., 143, 393.
Schenck, 251.
Scholtz, 438.
Schultze, H., 444.
Sée, M., 442.
Scegall, 298.
Shattuck, F. C., 118.
Shaw, H. L. K., 243.
Sherwell, 188, 281, 385, 386.
Sicard, 49.
Smith, C. M., 138, 236, 329, 330.
Southard, E. E., 543.
Söllner, 540.
Spitzer, 141.
Stainer, 438.
Stanziale, 342.
Stelwagon, 103, 351, 359.
Swaboda, 202.

T
Török, 143.
Towle, H. P., 134, 177, 337.
Thevenot, 48.
Thimm, P., 388.
Thompson, A., 349.
Thompson, R. L., 543.
Truffi, M., 197.
Tschlenow, 97.
Tyzzer, 543.

U
Unna, 289.

V
Vernet, 93.
Vielliard, 343, 344, 442, 444.

W
Waelsch, L., 395.
Wakefield, 345.
Waldheim, Fr., 252.
Walker, 105, 145.
Wallhauser, 77.
Walsch, Rud., 50.
Wayson, 346.
Weiss, L., 96.
Weil, 197.
Wende, G. W., 14, 447.
Whitehouse, H. H., 85, 233, 470.
White, J. C., 31, 362.
White, C. J., 31, 38, 238, 241, 327, 331, 338.
Whitfield, A., 287.
Winfield, 384, 586, 587.
Wolters, M., 488, 492.
Woolley, P. G., 479.
Wright, A. E., 483.
Wright, J. H., 1.

Z
Zeisler, Joseph, 96, 301, 532.

ALPHABETICAL AND CLASSIFIED INDEX FOR THE YEAR 1904.

Abscess, multiple subcutaneous, of mycotic origin, De Beurmann and Ramond, 196.
Acanthosis nigricans, two new cases of, Otto Hess, 533.
Acne, baker's, Galewsky, 143.
Acne, new treatment of, A. Rose, 143.
Acne of nose, hypertrophic, surgical treatment of, Dubreuilh, 391.
Acne, furunculosis, sycosis, the treatment of, by therapeutic inoculations of staphylococcic vaccine, A. E. Wright, 483.
Acne vulgaris, X-ray treatment of, Török and Schein, 143.
Actinomycosis, cutan. of finger, Sicard, 49.
Actinomyces, paronychia caused by, Thevenot, 48.
Actinomyces, morph. of fungus in tissues, Dor, 48.
Actinomycosis, a case of, Wallhauser, 77.
Adenoma folliculare cutis papilliferum, a case of, Karl Kreibich, 491.
Angiokeratoma and family tuberculides, L. Pautrier, 488.
Atrophia laevis or glossy atrophy of the tongue, F. Lesser, 148.
Atrophic and scar-like spots of the skin of trunk, W. M. Ivanow, 56.
Atrophy, symmetrical cutaneous, with coincident development of syphilis of the skin and nervous system, J. A. Fordyce, 155.
Basal cells, cancer of, Krompecher, 533.
Becquerel rays, effect of, upon tissues, Halkin, 100.
"Black tongue," note upon the parasite of, Roger and Weil, 197.
Blastomycetic dermatitis, some additional cases of, T. C. Gilchrist, 107.
Blastomycosis, report of a case of, H. H. Koehler and G. C. Hall, 581.

Book Reviews.

The Internal Secretions and the Principles of Medicine, Charles E. De M. Sajous, 58.
La Nature Syphilitic et la Curabilité du Tabes et de la Paralysie Generale, L. E. Leredde, 105.
Portfolio of Dermochromes, Prof. Jacobi, English text by J. J. Pringle, 106.
A Compend of Diseases of the Skin, Jay F. Schamberg, 151.
The Roentgen Rays in Therapeutics and Diagnosis, William Allen Pusey and Eugene Wilson Caldwell, 151.
Diseases of the Skin, Malcolm Morris, 153.
Uric Acid as a Factor in the Causation of Diseases, Alexander Haig, 154.
Practical Handbook of the Pathology of the Skin, J. M. H. Macleod, 204.
Social Diseases and Marriage, Social Prophylaxia, Prince A. Morrow, 205.
Die Vererbung der Syphilis, Rudolph Matzenauer, 250.
Die Pathologie und Therapie der Unfruchtbarkeit des Weibes, Ferdinand Schenk, 251.
Beiträge zur Physiologie und Pathologie der Hunt (Die Stachellnerven Hypothese), Fritz v. Waldheim, 252.
Uber die Prognose der Syphilis, G. Mayer, 252.
Uber das Syphilome des Ciliar-Körpers, Th. v. Etwetzky, 299.
Les Lésions du Rein et des Capsules Surrénales, L. Hoche and P. Briquel, 299.
Die Mikroscopische Technik, R. Lederman, 299.
Roentgen Ray Diagnosis and Therapy, Carl Beck, 350.
Cours de Dermatologie Exotique, E. Jeanselme, 396.
Thérapeutique des Maladies de la Peau, Leredde, 445.
Studien über die Hereditäre Syphilis. Zweiter theil: Knochenerkrankungen und Bewegungsstörungen bei der angebornen Frühsyphilis, Carl Hochsinger, 493.
Studies on the Pathology and on the Etiology of Variola and Vaccinia, W. T. Councilman, G. B. Magrath, W. R. Brinckerhoff, H. E. Tyzzer, E. E. Southard, R. L. Thompson, I. R. Bancroft, and G. N. Calkins, 543.
A Practical Treatise on the Diseases of the Skin for the Use of Students and Practitioners, James Nevins Hyde and Frank Hugh Montgomery, 596.

Bromide eruption, a rare case of, Lotta W. Myers, 231.
Bromism, a gangrenous form of, Hallopeau and Vielliard, 444.
Bullous dermatitis, Balzer and Fouquet, 340.

Boston Dermatological Society. Cases Presented.

Acne rosacea, Harding, 329.
Alopecia areata, in 3 members of a family, Bowen, 37.
Bullous dermatitis, Bowen, 34.
Callositas, Harding, 36.
Carcinoma of nose, Harding, 34.
Diagnosis (for) J. C. White, 31.
Diagnosis (for) C. J. White, 31.
Diagnosis (for) Bowen, 33.
Diagnosis (for) Bowen, 237.
Diagnosis (for) Howe, 240.
Diagnosis (for) C. J. White, 327.
Diagnosis (for) Towle, 337.
Diagnosis (for) C. J. White, 338.
Eczema, follicular, C. J. White, 241.
Empyroform dermatitis, Burns, 242.
Epithelioma, Burns, 238.
Epithelioma, Post, 136.
Erythema induratum, Towle, 134.
Erythema perstans, C. J. White, 238.
Erythema induratum, Towle, 336.
Keloid, case of multiple, Bowen, 40.
Lichen planus, Harding, 37.
Lichen planus, C. M. Smith, 329.
Lichen planus, C. M. Smith, 330.
Lichen planus annularis, C. J. White, 38.
Lepra anaesthetica, C. J. White, 331.
Lupus vulgaris, C. J. White, 331.
Nail disease, Howe, 240.
Raynaud's disease, Burns, 328.
Syphilis, Harding, 133.
Syphilis, Bowen, 36.
Syphilis, papulo-vesicular, Post, 39.
Syphilis and pityriasis rosea, C. M. Smith, 236.
Tuberculosis verrucous, Bowen, 335.
X-ray photographs, presentation of, Post, 139.

Cancer, note upon the causation of, H. J. Campbell, 535.
Cancer and its origin, the Bradshaw lecture on, Henry Morris, 198.
Cancer, the parasitic theory of, H. G. Palmer, 200.
Caraté, or an analogous dermatomycosis of South American origin, Darier, 195.
Caraté, a note on the case of M. Darier, Barbe, 195.
Carcinoma mammæ, researches on the morphology of an organism associated with, and on the etiological significa-

tion of this association, R. N. Monsarrat, 535.
Carcinoma, effects of radium upon, experimentally produced in mice, Apolant, 440.
Coccus of the skin, polymorphic, Axel Cederkreutz, 482.
Condylomata acuminata, the x-cells of, P. G. Unna, 289.
Congress, the fifth international dermatological, J. N. H., 130.
Congress, the fifth and sixth congresses of dermatology, J. N. H., 525.
Creeping eruption, its relation to myiasis, L. P. Hamburger, 217.
Creeping eruption, a second case of, H. W. Stelwagon, 359.
Cystadenoma of the sweat glands, hypertrophy and multiple, O. Klauber, 389.
Delhi Boils, Malcolm Morris, 140.
Dermatitis, papulo-exudative produced form pilocarpine, Hallopeau and Vielliard, 343.
Dermatitis, chronic streptococcic, assuming the form of a pemphigus, F. Krzystalowicz, 484.
Dermatitis coccidioides, reasons for considering—an independent disease, D. W. Montgomery, 368.
Dermatitis exfoliativa neonatorum or Ritter's disease, A. J. Patek, 269.
Dermatitis follicularis et perifollicularis conglobata, Ludwig Spitzer, 141.
Domestic remedies, some notes concerning—formerly used in skin diseases, J. C. White, 362.
Eczema, the passing of, J. N. H., 30.
Eczema, the modern conception of, J. A. Fordyce, 93.
Eczema regarded as a cutaneous reaction, Brocq, 93.
Eczema, infantile, eosinophilia in, Vernet, 93.
Eczematoid eruption of the lip region, a peculiar, H. W. Stelwagon, 357.
Empyroform, a new tar preparation, A. Kraus, 94.
Epidermolysis bullosa hereditaria associated with conjenital alopecia and atrophy of finger nails, G. W. Wende, 14.
Epidermolysis bullosa (congenital) Hallopeau and Sée, 442.
Epidermolysis bullosa hereditaria, J. Bukovsky, 443.
Erythema nodosum, Kahn, 95.
Erythema exfoliative, Balzer, DuGros and Fouquet, 34.
Erythema group of skin diseases, on the visceral manifestations of, W. Osler, 558.
Erythema Exudativum Multiforme, Chorea, Rheumatismus Nodosus, Endopericarditis, Hohfeld, 94.
Erythema induratum combined with lichen scrofulosorum, Söllner, 540.
Eruptions, post-vaccinal, notes on certain, W. T. Corlett, 495.
Eruptions intermediate between pityriasis rosea of Gibert and seborrhœa psoriasiform, Brocq, 541.
Erythemata, toxic, an inquiry into the etiology and nature of, J. F. Schamberg, 461.
Erysipeloid, with a record of 329 cases, of which 323 were caused by crab bites or lesions produced by crabs, T. C. Gilchrist, 507.
Erythrodermia exfoliativa universalis tuberculosa, Bruusgaard, 139.
Favus sine scutularis, R. Walch, 50.
Favus and tinea tonsurans, x-rays in, R. Sabouraud, 441.
Favus of the mouse (Achorion quinckeanum) human inoculations of, Bodin, 196.
Feigned eruption, a case of, W. S. Gottheil, 19.
"Feuilleton" glimpses of the fifth international dermatological congress, J. Z., 527.
Gangrene of the nipple, DuCastel and Nocton, 34.
Glossitis and stomatitis caused by a streptococcus, cases observed at Madagascar, Fonoynont and Jourdran, 50.
Granuloma pyogenicum (botryomycosis of French authors), M. B. Hartzell, 521.
Hair in axilla (the growth of) and congenital defect of the thoracic muscles, Morris Schein, 393.
Hair, periodic shedding of, Lederman, 53.
Herpes progenitalis, Kopytowski, 342.
Hydrargyrum hermophenylicum, G. Seegall, 298.
Hyperæmia, chronic symmetrical diffuse of the extremities, a case of, H. G. Klotz, 170.
Hyperidrosis universalis, a contribution to the study of, Fr. Müller, 142.
Hyperidrosis, x-rays in, Stelwagon, 103.
Ichthyosis, atypical lesions in, M. A. Moses, 65.
Ichthyosis cornée, Danlos, 592.
Ichthyosis, fœtal, Meneau, 593.
Impetigo circinata, a case of, with bullous lesions on the hands and feet, and subsequent infection of the nail matrices, Adamson, 443.

Iodide of potash eruption, tuberous, simulating histologically an epithelioma, D. W. Montgomery, 59.
Iodide of potash eruption, tuberous of face, Hallopeau and Vielliard, 442.
Iodide of potash eruption, A. Schutze, 444.
Kerion, gigantic, a case of, Danlos, 195.
Kraurosis vulvæ and ulcus rodens. O. Kreis, 56.
Koilonychia and platonychia, L. Waelsch, 395.
Labiomycosis, W. Evans, 198.
Leprosy, red mangrove bark in the treatment of, Guichard, 98.
Louisiana leper home, 98.
Leprosy in Russia, 99.
Leprosy, Hawaiian, Daland, 99.
Leprosy is curable, Filaretopoulo, 99.
Leprosy lazaretto at Tracadie, 100.
Leprosy in United States, 100.
Leprosy theory (fish eating), Romanist view of, 345.
Leprosy catabolism in, Wakefield, 345.
Leprosy in Hawaii, Wayson, 346.
Leprosy, study of, 347.
Leprosy, mosquitoes and fish as factors in the spread of, Ashmead, 347.
Leprosy, Louisiana leper law, 347.
Leprosy, sporadic tubercular, Heidingsfeld, 348.
Leprosy, a case of, Dillingham, 348.
Leprosy in New Zealand, 349.
Leprosy in New South Wales, 349.
Leukæmia (lymphatic) with purpura, a case of, F. C. Shattuck, 118.
Lichen planus (bullous), report of a case of, (*"lichen planus pemphigoides"*), M. F. Engman, 207.
Lichen planus, lesions of finger nails in, DuCastel and Druelle, 54.
Lichen planus, notes on the treatment of, Zeisler, 96.
Lichen planus verrucosus, A. Ravogli, 573.
Lineæ albicantes, varieties of, W. Osler, 57.
Lineæ albicantes—skin lesions associated with the growth of long bones, W. P. Northrup, 57.
Lupus, the pathogenesis of, L. Philippson, 140.
Lupus-like tissue, peculiar inclusions in, J. T. Bowen, 10.
Lupus nodularis of hæmatogenetic origin, a case of, M. Wolters, 488.
Miscellany, a ward for cutaneous diseases in the Mass. General Hosp., 47.
Miscellany, a new medical journal, *The American Journal of Urology*, 546.
Monilethrix, H. Ledermann, 54.
Monilethrix, Hallopeau and Lebrel, 395.
Mucous membranes, affections of the—in their relation to skin diseases, J. A. Fordyce, 394.
Mucous membranes, affections of the—in relation to skin diseases, M. F. Engman, 412.
Mycosis, note on Darier's case of, Bodin, 195.
Mycosis fungoides, a case of, treated by the x-rays, A. E. Carrier, 73.
Mycosis fungoides, x-rays in the treatment of, Hyde, Montgomery and Ormsby, 103.
Mycosis fungoides and x-rays, authors quoted, Scholtz, Jamieson, Stainer, Riehl, Marsh, Hyde, Montgomery and Ormsby, Ormsby, Carrier, Brocq, Bisserie and Belot, Lustgarten, Elliot, 438.
Myomata, multiple, of the skin, a further report on a case of, W. A. Hardaway, 375.
Naevi syringoadenomatosi, M. Wolters, 492.
Nail diseases, report of cases, F. Bering, 55.

New York Dermatological Society. Cases Presented.

Acne, severe, x-ray treatment, Allen, 86.
Acne and pseudo-keloid, x-ray treatment, Allen, 235.
Acne, lupoid, desseminated, Fox, 190.
Acne rosacea, x-ray treat., Mewborn, 192.
Acne varioloformis, Fox, 190.
Alopecia areata, Mewborn, 282.
Dermatitis herpetiformis, Bronson, 43.
Dermatitis medicamentosa, Sherwell, 385.
Diagnosis, case for, Whitehouse, 84.
Diagnosis, case for, Jackson, 191.
Diagnosis, case for, Bronson, 232.
Diagnosis, case for, Allen, 236.
Diagnosis, case for, Jackson, 378.
Diagnosis, case for, Fox, 378.
Diagnosis, case for, Winfield, 384.
Diagnosis, case for, Jackson 384.
Diagnosis, case for, Fox.
Duhring's disease or neurotic eczema, Sherwell, 386.
Eczema seborrhoic of a peculiar type upon backs of hands, x-ray treatment, Bronson, 380.
Epidermolysis, bullosa, Brinkley for Bulkley, 589.
Epidermolysis, bullosa, Brinkley for Bulkley, 590.
Epithelioma of lip, Mewborn, 387.
Epithelioma (superficial) of nose and eyelid cured by X-ray, Fordyce, 187.
Erythema perstans, Winfield, 587.

Feigned eruption, Fordyce, 83.
Folliculitis decalvans affecting beard and pubic region, Mewborn, 589.
Granuloma fungoides, Lustgarten, 185.
Hyperaemia, ch. sym. diff, of extremities, Klotz, 183.
Kerion of the beard, note on, Mewborn, 286.
Lepra, Fox, 194.
Lepra, tuberculo-macular, Fox, 591.
Lichen planus, Allen, 190.
Lupus erythematosus, high frequency current treatment, Lustgarten, 193.
Lupus erythematosus, Mewborn, 588.
Lupus erythematosus of hands, Fox, 280.
Lupus vulgaris, Fox, 591.
Lupus vulgaris, Fox, 591.
Lupus vulgaris, of knee, Fordyce, 88.
Lupus vulgaris of cheek, Radium treatment, Bulkley, 91.
Lupus vulgaris of submaxillary region, x-ray treatment, Bulkley, 92.
Lupus vulgaris of leg, shoulder, and face, Fordyce, 383.
Lupus verrucosus, Fox, 383.
Mycosis fungoides, Sherwell, 281.
Mycosis fungoides, x-ray treatment, Brinkley for Bulkley, 590.
Morphœa, Whitehouse, 233.
Paget's disease of gluteal region, Fordyce, 382.
Peliosis rheumatica, Fox, 585.
Phototherapy, a few remarks on the different rays, Piffard, 284.
Psoriasis developed on a seborrhoic skin showing effect of x-ray treatment, Mewborn, 88.
Psoriasis, Mewborn, 236.
Raynaud's disease, Fordyce, 284.
Record of skin lesions, graphic, Piffard, 44.
Sarcoma, multiple, Jackson, 184.
Scleroderma with symptoms simulating Addison's and Raynaud's disease: marked improvement from administration of extract of suprarenal gland, Winfield for C. R. Love, 586.
Scleroderma of hands with facial atrophy, Fox, 586.
Scleroderma improved under use of dessicated suprarenal gland, Winfield for C. R. Love, 587.
Syphilis, in which a lesion of lower lip had been removed for epithelioma, cleared up under salicylate of mercury injections, Mewborn, 234.
Vitiligo, Allen, 189.
Vitiligo, Fordyce, 289.
"White Spot" disease, Sherwell, 188.
X-ray apparatus and treatment, remarks, Piffard, 44.

Obituaries.

Dr. George Thin, 203.
Dr. Alfred Sangster, 203.
Neils Ryberg Finsen, 531.
Dr. Francis B. Greenough, 532.

Onychoschisiasis symmetrica, Oscar Ehrmann, 55.
Papilloma of sole, report of personal case of, T. D. Berry, 228.
Parapsoriasis "en gouttes," DuCastel, 202.
Parasitic scalp diseases, sublamin in the treatment of, W. S. Gottheil, 52.
Pellagra, localization of aspergillus spores in mesenteric glands of, Ceni, 51.
Pemphigus, acute infectious, in a butcher, during an epizootic of foot and mouth disease, with a consideration of the possible relationship of the two affections, J. T. Bowen, 253.
Pemphigus vulgaris, a case of, with some observations on its bacteriology, A. C. Eustis, 486.
Pemphigus vegetans of Neumann, Stanziale, 342.
Phototherapeutic apparatus, W. F. Arnold, U. S. Navy's, method of using, 23.
Phlyctenulæ and dermatitis herpetiformis, Carle, 444.
Pinta; Paño Blanco, Paul G. Woolley, 479.
Pityriasis rosea, an erythematous eruption of internal origin, Weiss, 96.
Pityriasis rosea, H. P. Towle, 177.
Pityriasis rubra (Hebra), Tschlenow, 97.
Pityriasis versicolor of nails, Campana, 55.
Plasma cell, "the small round cell" and cells of chronic inflammation in general, Arthur Whitfield, 287.
Protozoa in a case of tropical ulcer (Aleppo boil), J. H. Wright, 1.
Protozoa as causes of disease, recent investigations on the, J. T. B., 80.
Psoriasis vulgaris and pemphigus vulgaris, Neumann, 201.
President's address, delivered before the 28th American Dermatological Association meeting, Joseph Zeisler, 301.
Rhinophyma, a pathological analysis of five separate tumors occurring in the same patient, G. W. Wende and C. A. Bentz, 447.
Rhinoscleroma, cell degeneration in, Mibelli, 490.
Rhinoscleroma, metastatic disease of the lymph glands in, A. Krause, 490.
Rhinoscleroma, the treatment of with thiosinamin, E. Glos, 490.

Rubella scarlatinosa, F. C. Curtis and H. L. K. Shaw, 243.
Sarcoma, idiopathic multiple cutaneous, F. Krzystalowicz, 537.
Scarlet fever, bacteriological examination of the blood during life in, L. Hectoen, 245.
Sebaceous glands, tumors of, R. Kothe, 392.
Sebaceous glands, the increased occurrence of on the inner surface of the prepuce, E. Delbanco, 492.
Small-pox, red light treatment of, Jay F. Schamberg, 244.
Spark-gap radiations, preliminary note relative to the more efficient utilization of the, H. G. Piffard, 265.
Sweat glands, tumors of the, O. Klauber, 388.
Sycosis, parasitic, communicated from cattle, W. F. Breakey, 566.
Syphilis
acquired in hereditary syphilitics, Gaucher and Rostaine, 248.
of central nervous system, remarks upon the pathology of, Erb, 144.
cerebral, dementia, with nuclear degeneration of some cranial nerves with atrophy of the tongue, H. Moyer, 145
congenital, suprarenals in, N. Gulcke, 148.
cerebral, Brownrigg, 144.
dactylitis, syphilitic, a case of, A. Renault, 151.
glossy atrophy of the root of the tongue, (atrophia lævis) and its relation to, F. Lesser, 148.
gumma, an example of intracranial, H. Campbell, 146.
gummata of the urethra, Renault, 296.
hereditary, joint affections in, Hippel, 294.
hereditary cerebral, of a cerebro-spinal form, a case of, Richon, 249.
hereditary, the influence of on the nervous system, J. G. Forbes, 248.
inherited, Roissard, 291.
Justus test for, Feurstein, 296.
of the newborn, ulcer of umbilicus in, Hutinel, 292.
of the brain, S. Ayres, 146.
of the heart, T. Adler, 297.
of the nervous system, the diagnosis and treatment of, G. M. Hammond, 147.
of the nervous system, the diagnosis and treatment of, Gowers, 147.
primary lesion, pathology of, S. Ehrman, 295.
pigmentary of the neck, origin of, Hulleu, 150.
phlebitis, E. Hoffman, 247.
reinfection of, a case of, Klotz, 317.
tabes and general paralysis, the curability of by intense mercurial treatment, Leredde, 144.
tabes and general paralysis, the syphilitic nature of, Leredde, 250.
tabes, general paralysis and Charcot's joint, Walker, 145.
tabes, juvenile and infantile, Marbury, 291.
treatment of by hermophenyl, Seegall, 298.
ulcer of testicle (fungoid) Du Castel, 247.
Trichophytine, M. Truffi, 195.
Trichorrhexis nodosa, Sabouraud, 394.
Tuberculosis of the skin, tumor-like forms of, Walther Pick, 305.
Tuberculides, a contribution to the study of, Nicolau, 487.
Tuberculosis of the skin, experimental, Julius Meyer, 487.
Tuberculosis of the skin following measles, a case of papular, Gaucher and Druelle, 489.
Tumors, innocent and malignant, essential similarity of, C. W. Cathcart, 536.
Ulcus molle, (chancroid bacilli) pure culture of, Fischer, 52.
Urticaria pigmentosa, Swaboda, 202.
Vaccination, complications of, Colcott Fox, 246.
Vascular equilibrium, the relation of certain dermatoses to each other and to changes in, J. Nevins Hyde and E. L. McEwen, 547.
Venereal diseases in Germany, the warfare against, E. Lesser, 276.
Vitiligo treated with the Finsen light, D. W. Montgomery, 17.
Warts, moles, and other facial blemishes, the removal of, G. T. Jackson, 122.
Xanthoma multiplex, histology of the palmar striæ, H. H. Whitehouse, 470.
X-rays, a tentative suggestion regarding the nature and character of, M. L. Heidingsfeld, 24.
X-ray burns, the treatment of, Walker, 104.
Xeroderma pigmentosum, x-rays in, Allen Jamieson, 102.
Zoster, hæmorrhagic, Hallopeau and Vielliard, 344.

THE JOURNAL OF
CUTANEOUS DISEASES
INCLUDING SYPHILIS

VOL. XXII. JANUARY, 1904. No. 1

PROTOZOA IN A CASE OF TROPICAL ULCER ("ALEPPO BOIL").*

JAMES HOMER WRIGHT, M.D.,

Director of the Clinico-Pathological Laboratory of the Massachusetts General Hospital, Boston, Mass.

THE clinical and anatomical features of this peculiar skin disease are fully described in any modern text-book of dermatology, so that it is not necessary to give any lengthy description of them here. In brief, the disease consists of single or multiple focal lesions of the skin characterized by the formation of elevated, indurated areas, which ulcerate and eventually cicatrize. They have considerable resemblance to certain forms of cutaneous tuberculosis and syphilis. The lesions occur usually on parts not protected by clothing. Histologically the lesions consist in infiltration of the corium and subcutaneous tissue by cells, together with hypertrophy, atrophy, and disappearance of the epidermis. The affection lasts for months, or for a year, or longer. It is endemic only in tropical and sub-tropical countries. It is generally believed to be of an infectious nature and is capable of transmission from one individual to another by inoculation, but apparently is not contagious in the usual meaning of that term. There is evidence that mosquitoes and other insects may be the carriers of the infectious agent. The infectious agent has been sought for by a considerable number of observers, but with only negative, or contrary, or inconclusive results. Fungi, bacteria, and protozoa have been described in the lesions. The French observers particularly have written much concerning the occurrence

*This article is published under a special arrangement with *The Journal of Medical Research*, Vol. X—No. 3, Nov., 1903.

of micrococci in connection with the disease, but have not offered convincing proof of their significance. At the present time no microorganism has been satisfactorily shown to be the casual agent in the disease.

From an examination of the literature on the subject it seems that the results of only three observers are worthy of serious consideration in this paper.

D. D. Cunningham[1] in 1885 published the results of his examination of a specimen of "Delhi boil" that had been placed in alcohol immediately after its removal from the patient in Delhi. The epidermis over the specimen was intact and there was no evidence of ulceration. He studied frozen sections of the specimen, stained in various ways, and found that the condition was one of extensive cellular infiltration of the corium and subcutaneous tissue together with atrophy of the epidermis in some places and hyperplasia in others. In sections which had been stained with gentian violet and then considerably decolorized with alcohol he found a large number of peculiar bodies which he describes as follows:

"They varied very considerably in size. The average diameters of a series of measured specimens were 12.6 μ by 8.8 μ, the largest measuring 12.8 μ by 25.6 μ, the smallest 6.4 μ by 6.4 μ. Such minute specimens as the latter were, however, rare, and as a rule they were considerably larger than the lymphoid elements among which they were situated. Their form also varied greatly. In some cases they were circular, in others elliptical, in others irregularly lobate. Their contour was in the majority of instances smooth, but in some of a more or less tuberculate character. In some specimens a very delicate cell wall was clearly visible. In others it was wholly unrecognizable or only to be detected on careful and special scrutiny. The distinctness with which they appear in sections treated with gentian violet is due to the elective staining of the nucleoid bodies which they contain by the dye. The number of such bodies present in different cells varies extremely—in some cases only a single great nucleoid mass is present, seemingly occupying almost the entire cell body, in others a few of very various sizes occur and in still others a large number of minute and fairly equal sized ones were thickly scattered throughout the entire cell. The cytoplasm in the gentian violet specimens remains almost uncolored; in those in which fuchsin has likewise been

[1] "On the Presence of Peculiar Parasitic Organisms in the Tissue of a Specimen of Delhi Boil," Scientific Memoirs by Medical Officers of the Army of India. Part 1, 1884, Calcutta, 1885.

employed it frequently shows a more or less pronounced red hue. The tuberculate appearance presented by some of the cells is due to the numbers and sizes of the nucleoid bodies present in them, which in association form a mulberry-like mass pressing upon the cell wall and molding it to the inequalities of its surface. Such tuberculate bodies on superficial examination present certain points of resemblance to the characteristic bodies in cases of actinomycosis. On closer examination, however, it is evident that they correspond structurally with the description given above and are not due to any radiate aggregation of filaments. In certain cases appearances apparently corresponding with the occurrence of processes of cell division are present, the bodies of the cells being strongly constricted so as to form two lobes connected by a narrow neck, or two distinct cells occurring, which, from their relations to one another and the character of their opposed surfaces, seem to have just arisen, due to completion of such a process. In many instances, too, a distribution of the cells in little groups separated from one another by comparatively wide areas of granulation tissue can be recognized and may possibly be indicative of the antecedent occurrence of processes of division. The individual cells in some cases are closely packed among the surrounding lymphoid elements; in a large number of instances, however, they appear to lie in a limited clear space. This appearance may possibly be an artificial one, arising as the result of shrinking during the course of preparation. The number of cells visible in individual sections and in different parts of the same section varies considerably. In some sections as many as 80 or even more may be visible at once in a single field under a power of 140 diameters. In others they are present in varying but smaller numbers, and in almost any section entire fields may in certain places fail to show any at all."

"After very careful consideration of the features presented by all the various forms present in the tissues, I am inclined to regard them as representing various stages of some simple organism of Mycetozoic nature. In the most recent systematic treatise dealing with the Mycetozoa or Myxomycetes—Zopf's 'Schleimpilze'—they are subdivided into Monadinæ and Eumycetozoa, and it is to the former group that the organism here dealt with appears to me, probably, to belong. The appearances presented by the various forms are, according to this view, to be regarded as corresponding to various stages of the development, and, especially, of the development of the Zoöcysts or Sporocysts, of some Monadinic organism. Comparing the characters of the various specimens with one another, we have apparently to deal

with the development of parent plasmodia or amebæ, which multiply by division and in which sporoid bodies are gradually developed, the process terminating in some cases with the formation of one great spore, in others with that of a dense aggregate of smaller ones."

It will be obvious to a histologist, from the reading of Cunningham's description of the bodies, that the morphological evidence adduced in favor of their parasitic nature is not sufficient to overcome the objection that they are elements of the tissue or degeneration products. This objection has the greater weight in view of the fact that Cunningham's histological technique was crude and not adapted to permit an adequate examination of the tissue, for he states that he made his observations on frozen sections. The plates that accompany the paper do not show any more morphological detail than is described in the text. It seems possible, however, that Cunningham did see among the various bodies that he describes the large cells described below, and that these large cells were what he regarded as "parent plasmodia" containing small spores.

Gustav Riehl,[1] in a paper published in 1886, reported the result of his examination of a single case. He describes among the infiltrating cells of the lesion many large epithelioid cells containing in their cytoplasm many bodies which he regarded as micrococci, with capsules, frequently more than twenty in a single cell. He regarded the bodies described by Cunningham as degeneration products.

R. H. Firth,[1] in 1891, states in a short paper that he could confirm the findings of Cunningham. This paper is but little more than a declaration that the author had seen in the lesions of the disease the same bodies described by Cunningham, and it contains nothing more convincing of their parasitic nature than does the paper of Cunningham. He proposed for them the name "Sporozoa furunculosa."

The case of tropical ulcer which is reported in this paper entered the service of Dr. R. B. Greenough in the Out-Patient Department of the Massachusetts General Hospital, July 28, 1903. The patient was a female child, nine years of age, born in Armenia. She presented in the skin of the left cheek, near the mouth, a firm, circular, elevated area, about twelve millimeters in diameter, covered with a blackish scab. This lesion had made its first appearance before the child left Armenia, some two or three months before. Through consultation with Dr. Charles J. White, of the Dermatological Department of the hospital, the diagnosis of Aleppo boil or tropical ulcer

[1] "Zur Anatomie und Ætiologie der Orientbeule." Vierteljahresschrift für Dermatologie und Syphilis, 1886, p. 805.

was made. The lesion was excised and curetted by Dr. Greenough, and the material thus obtained, consisting of a piece of grayish translucent tissue about ten millimeters in diameter, and two or three smaller pieces of similar tissue, was immediately given to the writer for examination. Smear preparations were made from this material by rubbing and squeezing pieces of it against the coverglass, so as to cause a deposit of the tissue juices thereon. The smears were then immediately fixed and afterwards stained in various ways. In these preparations peculiar bodies were more or less distinctly visible. They were most clearly seen and differentiated from cell detritus in preparations fixed in pure methyl alcohol, and afterwards stained with the Romanowsky staining fluid for blood films described by the writer in a paper published in a previous volume of the *Journal of Medical Research*. ("A Rapid Method for the Differential Staining of Blood Films and Malarial Parasites." *Journal of Medical Research*, Vol. VII., No. 1, January, 1902.) After fixation by the methyl alcohol the staining fluid was immediately applied to the preparation without washing in water, or allowing it to dry, and the process of staining continued essentially as described for blood films and malarial parasites in the paper referred to above. The best results were obtained in a preparation fixed with methyl alcohol for only a few minutes.

In the thinner and better fixed and stained portions of smears prepared in this way the peculiar bodies present the following characteristics: They are generally round, sharply defined in outline, and two to four micromillimeters in diameter. A large part of their peripheral portions is stained a pale robin's egg blue, while their central portions are unstained or white. A very prominent feature is the presence in each of the bodies of a larger and a smaller lilac-colored mass. The larger mass is about one-fourth or one-third the size of the body, is of variable shape, but always forms a part of the rounded periphery of the body. The smaller mass in some instances is round, in others is rod-shaped, and in the latter case is of a deeper lilac color than the larger mass. It is usually situated near or at the blue-stained periphery of the body. The blue peripheral portions of the bodies are usually sharply defined from the central unstained portion and sometimes show small unstained areas. A few of the bodies are oval or elongate in form. This is thought to be due to distortion in making the preparation, because in thin sections of the tissue such forms are not apparent. In the thicker portions of the smears the central portion of the bodies is stained blue as well as the periphery.

[1] "Notes on the Appearance of Certain Sporozoon Bodies in the Protoplasm of an 'Oriental Sore.'" *British Medical Journal*, Jan. 10, 1891, p. 60.

These bodies are present in very large numbers in the smears, often occurring in aggregations associated with a large nucleus, thus suggesting that they have been contained in a large cell whose outlines have disappeared in the process of fixing and staining. That this is true is shown in the sections of the tissue described below. (See Pl. I., Fig. 2, and Pl. II., Fig. 3.)

The general morphology of the bodies and the large numbers of them visible in a single field of the microscope, under a high magnifying power, are indicated in Pl. II., Fig. 5; Pl. III., Figs. 6, 7, 8, and 9; and Pl. IV., Figs. 10, 13, 14, and 15.

The constant morphology and structure of these bodies, the differential staining of their parts, their great numbers, and their position in cells seem to justify the belief that they are microörganisms and that they are the infectious cause of the lesion. Assuming that they are microörganisms, it seems reasonable to regard them as protozoa, because of their morphology and staining peculiarities. As to their classification among the protozoa, I am unable to give a definite opinion. Their small size, their great number, their intracellular position, and their morphology suggest that they are microsporidia. Nothing, however, was observed that suggested the developmental or reproductive cycle so characteristic of that group. On the contrary, certain appearances are observed in a few microörganisms, usually of larger size, which suggest multiplication by fission, which is a mode of multiplication apparently unknown among the microsporidia. These appearances consist chiefly in increased size and length of the lilac-colored masses with constriction in their middle parts, and in the presence in a single microörganism of two of the larger or two of the smaller masses or two of each (Pl. IV., Figs. 10, 11, 12, 13, 14, and 16). In two or three of these microörganisms a process is seen extending inward from the peripheral portion and tending to mark the body into two symmetrical halves (see Pl. IV., Figs. 10 and 11). Assuming that the lilac-colored masses are of the nature of nuclei, this duplication of them may be regarded as the preliminary process of division of the microörganism into two individuals.

I propose as the generic and specific names for this parasite *Helcosoma tropicum*. The generic name is derived from ἕλκος, a sore.

I do not adopt the name *Sporozoa furunculosa* that Firth applied to the supposed protozoan described by Cunningham in this disease, because that was an ameba-like, spore-forming organism and was obviously different from the one here described.

Microscopical examination of paraffin sections of some of the ma-

terial which had been fixed in Zenker's fluid gave the following results: The lesion consists essentially of a very extensive infiltration of the corium and papillæ by cells, accompanied by atrophy and disappearance of the epidermis of the part (see Pl. I, Fig. 1). The infiltrating cells are plasma cells, various kinds of lymphoid cells, and large cells with single vesicular nuclei and a relatively large amount of cytoplasm in which are large numbers of the microörganisms. These large cells, over extensive areas, are very numerous and constitute the principal part of the infiltration (see Pl. I., Fig. 2, and Pl. II., Fig. 3). They are regarded as proliferated endothelial cells. The microörganisms are generally closely packed together throughout the cytoplasm of these cells and occupy most of the available space between the nucleus and the cell membrane. They are almost exclusively in these cells. Many cells contain twenty or more microörganisms. Only in very thin sections, cut with the aid of the Minot-Blake microtome, can the morphology of the individual microörganisms be clearly made out. In these thin sections all the microörganisms appear to be of spherical form, the cortical or peripheral portions staining faintly with nuclear stains and the principal portion of the body remaining unstained, while the larger and smaller lilac-stained masses described in the smear preparations stain deeply with methylene blue and gentian violet. (Pl. II., Fig. 4, shows three of the microörganisms in focus in a thin section.)

In thicker sections the microörganisms may give to the large cells in which they are situated the appearance of containing numerous basic staining granules of about the size of ordinary pus cocci, each surrounded by a clear space. These granules are the larger nucleus-like masses of the microörganism. The appearances are such as to make it certain that the cells containing micrococci with capsules, described by Riehl in his case and referred to above, were these same cells (see Pl. II., Fig. 3). As has been pointed out before, it seems possible that these same cells were seen by Cunningham and by Firth, and represent some of the supposed plasmodia in process of sporulation described by them.

A part of the material was also used for the inoculation of a rabbit by subcutaneous injection, and by the scarification of the skin and of the cornea. No pathogenic effect was noted in the animal.

A small amount of the material was placed in a small quantity of freshly drawn human blood and kept in the incubator for some days. No evidence of multiplication of the microörganisms was obtained.

I wish to acknowledge my obligation to Dr. Robert B. Greenough for affording me the opportunity of studying this case, and to Dr. Charles J. White for helping me in the examination of the literature of the disease.

The observations recorded in this paper have resulted from the interest aroused in the subject of protozoa in disease by the studies of Dr. W. T. Councilman and his pupils on small-pox.

(For the benefit of those who may wish to apply the method used to other cases of tropical ulcer and who have not access to the paper referred to on p. 5, the following directions for the preparation of the staining fluid and for its application to smear preparations from the lesions are given.)

(*Preparation of the Staining Fluid.*—Dissolve 0.5 grm. of sodium bicarbonate in 100 ccm. of distilled water, and add to it 1 grm. of methylene blue (Grübler). Steam the mixture in an ordinary steam sterilizer for one hour, counting the time after "steam is up." The heating should not be done in a pressure sterilizer, nor in a water bath, nor in any other way than as stated. When cool, pour the mixture into a large vessel and add to it, stirring or shaking meanwhile, 500 ccm. of a one to one thousand aqueous solution of eosin (Grübler, yellowish, water soluble). In the mixture thus formed a fine blackish precipitate will be visible in suspension, and on the surface a scum with yellowish metallic luster will have appeared. Filter the mixture, collect the precipitate on the filter paper and allow it to dry thereon without washing. When thoroughly dry, dissolve this precipitate in pure methyl alcohol in a proportion of 0.5 grm. to 100 ccm. of alcohol. This alcoholic solution is the staining fluid. It will keep indefinitely, as will also the dry precipitate. Precautions should be taken to prevent the alcohol from evaporating, for thus the solution may become too saturated and precipitates may form on the preparation in the process of staining. If the staining fluid deposits such precipitates, it should be filtered and a small quantity of methyl alcohol added to it.

(*Method of Applying the Staining Fluid.*—Place the fresh cover-glass preparation in pure methyl alcohol and allow it to remain therein for two or three minutes. It is probably best that the preparation be allowed to dry in the air before placing it in alcohol. Next remove the preparation from the alcohol, grasp it with cover-glass forceps, and, without permitting it to dry, pour onto it as much of the staining fluid as the cover-glass will conveniently hold, and allow the fluid to remain one minute. Then add water to the staining fluid drop by drop until a delicate scum with iridescent metallic luster becomes visible on its surface. Avoid diluting the fluid more than enough to just cause this scum to appear. If the staining fluid has been properly prepared, this scum will form before the fluid has been diluted enough to be transparent. The diluted fluid is to remain on the preparation for three minutes. During this time the most important part of the staining is effected. After this the preparation is to be washed with water until the nuclei of cells in the better-spread portions of the preparation appear well differentiated under a low power of the microscope and until any red blood corpuscles present have a yellowish or pinkish color. This will probably require about a minute's washing. The washing in water is important, for it removes superfluous blue stain and brings out the differential staining of the elements in the preparation. The quality of the staining and the progress of the differentiation can be easily judged by placing the preparation, film-side uppermost, on a slide and examining it with a Zeiss AA or similar objective. When the decolorization is judged sufficient, the preparation is to be thoroughly dried and mounted in balsam. Dried stain adherent to the upper side of the cover-glass may be easily removed with alcohol. The nuclei of cells should have a blue or deep lilac color and red blood corpuscles a pink or orange color. The cytoplasm of polynuclear leucocytes should show lilac-colored granules and the cytoplasm of lymphocytes should have a robin's egg blue color, while the protozoa should have the color appearances described in the text.)

PLATE I.—To Illustrate Dr. J. H. Wright's Article.

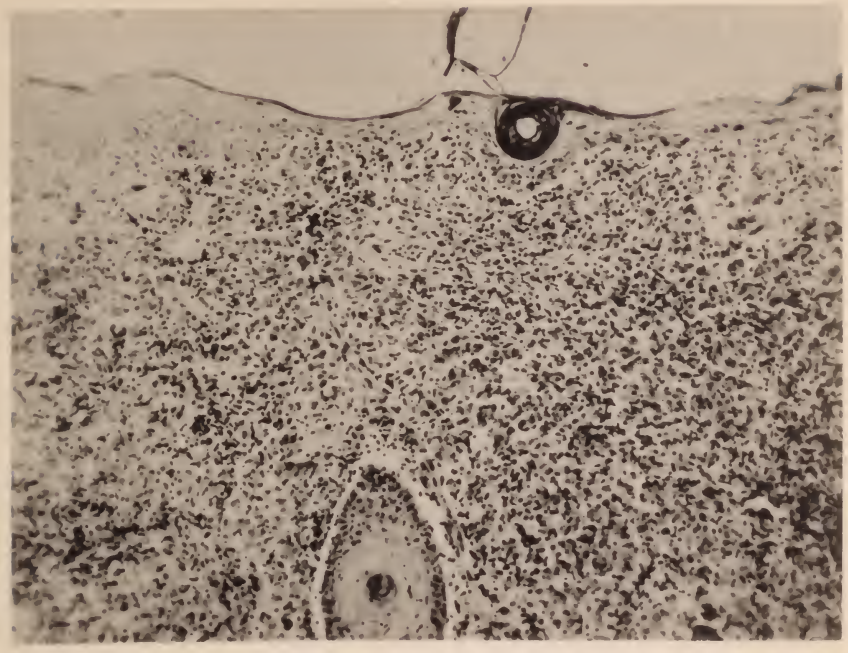

1

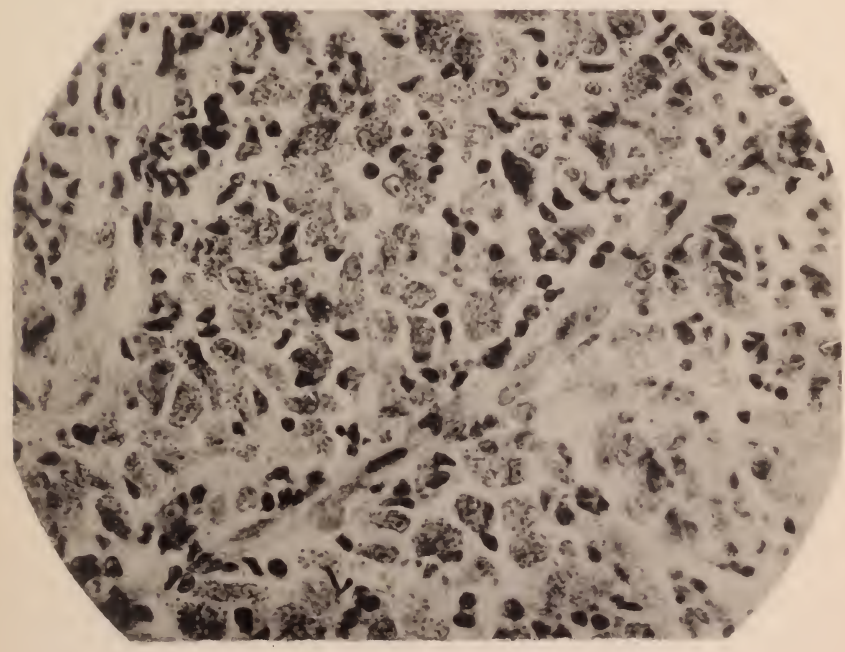

2

Wright Tropical ulcer

PLATE II.—To Illustrate Dr. J. H. Wright's Article.

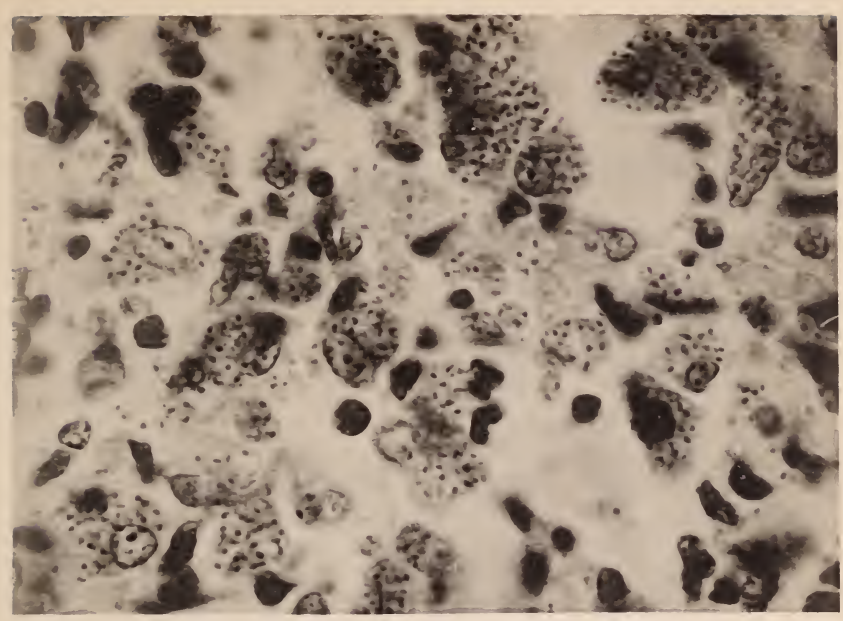

3



4

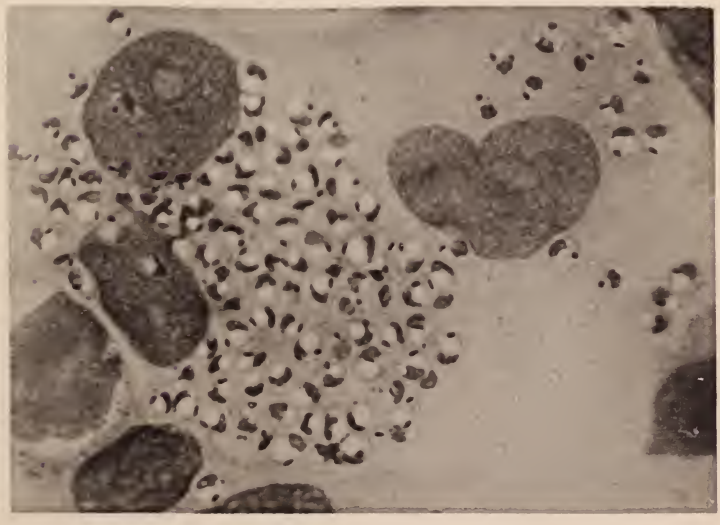

5

Wright Tropical ulcer

Heliotype Co., Boston

PLATE III.—To Illustrate Dr. J. H. Wright's Article.

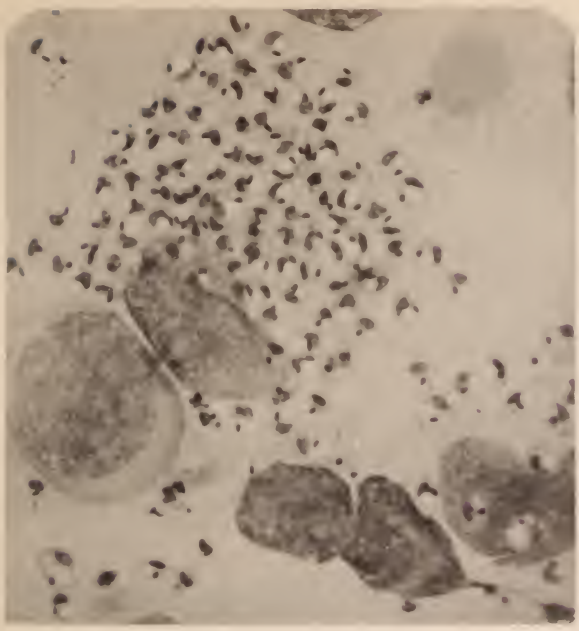

6

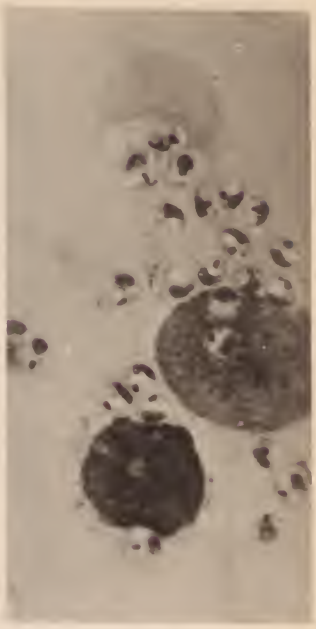

7

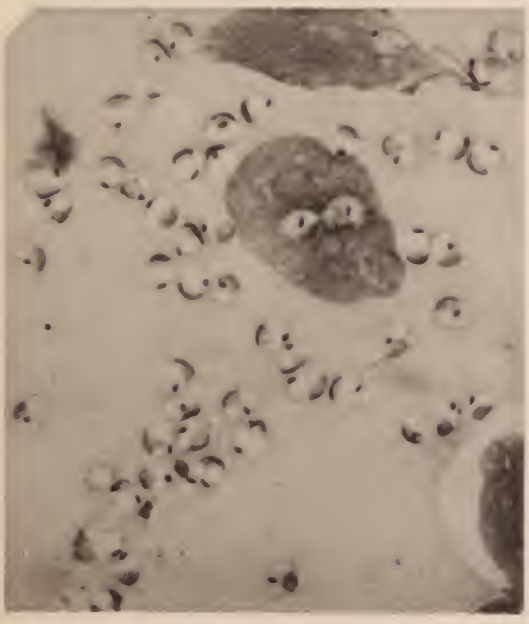

8

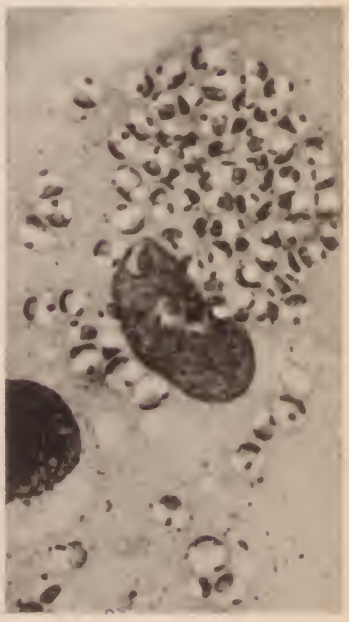

9

Wright

Tropical ulcer

Millington Co. Boston.

PLATE IV.—To Illustrate Dr. J. H. Wright's Article.

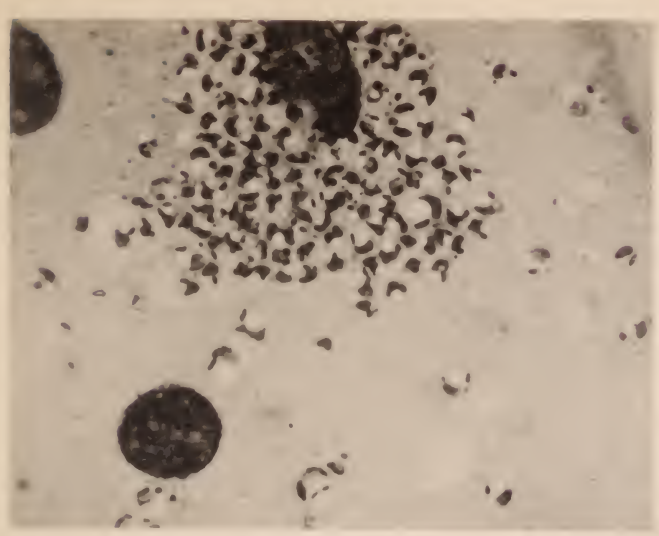

10

11

12

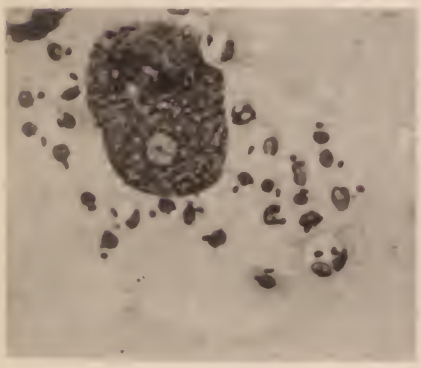

13

14

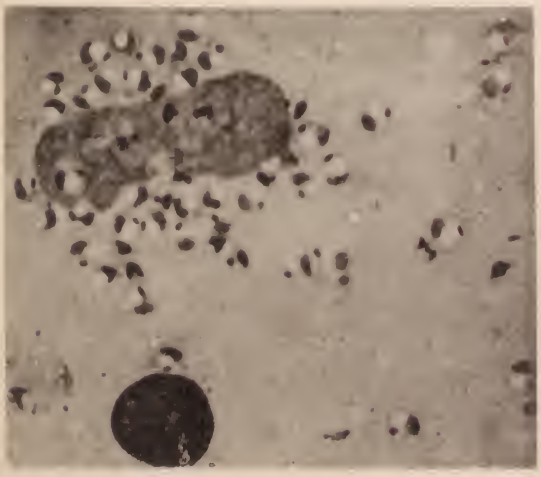

15

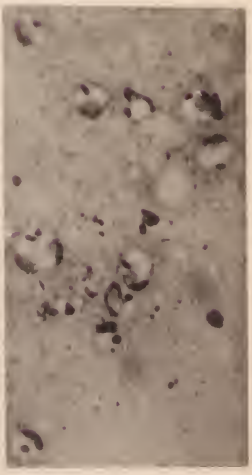

16

Wright

Tropical ulcer

Heliotype Co., Boston.

DESCRIPTION OF PLATES.

(Photographs by Mr. L. S. Brown, Clinico-Pathological Laboratory, Massachusetts General Hospital.)

Plate I.

Fig. 1. A section of the lesion under a low magnifying power, showing the extensive cellular infiltration of the dermis and the atrophy of the epidermis.

Fig. 2. A section of the lesion, showing the general character of the infiltrating cells. The granular appearance of the large cells is due to the presence of the microörganisms within their cytoplasm. x 500 approx.

Plate II.

Fig. 3. A section of the lesion, showing the large cells containing the microörganisms under a higher magnification than Fig. 2. x 1000 approx.

Fig. 4. A very thin section of the lesion cut on the Minot-Blake microtome, showing the morphology of three of the microörganisms. The indefinite mass in the center of the figure is made up largely of microörganisms which are out of focus. x 2000 approx.

Fig. 5. Smear preparation from the lesion stained with Wright's Romanowsky blood-staining fluid. The ring-like bodies with white central portions and containing a larger and a smaller dark mass are the microörganisms. The dark masses in the bodies are stained a lilac color, while the peripheral portions of the bodies, in typical instances, are stained a pale robin's egg blue. The very dark masses are nuclei of cells of the lesion. x 1500 approx.

Plate III.

Figs. 6, 7, 8, and 9. Smear preparations stained as in the case of Fig. 5 and showing essentially the same things. All x 1500 approx.

Plate IV.

Figs. 10, 11, 12, 13, 14, 15, and 16. All are smear preparations stained as described for the preceding figures. All x 1500 approx.

Figs. 10, 11, 12, 13, 14, and 16 show the elongation, constriction, and duplication of the lilac-stained, dark-appearing bodies in the microorganisms described in the text.

PECULIAR INCLUSIONS IN LUPUS-LIKE TISSUE.

By John T. Bowen, M.D., Boston.

VARIOUS notices of this subject have from time to time appeared, describing peculiar inclusions in the cells and tissues of tuberculous lesions, or of lesions with a histological structure resembling tuberculosis. Lang[1] long ago noticed bodies in the giant cells of lupus which he regarded as analogous to the corpora amylacea. Ssudakewitsch[2] regarded apparently similar bodies as degenerated elastic fibers or as products of their changes. This he considered proved by the fact that genuine elastic fibers sometimes projected from the bodies out beyond the cells. Hektoen[3], in a recent article, relates two cases, one concerning a nodule on the anal margin after excision for hæmorrhoids, in which peculiar bodies were found in giant cells, which especial methods of staining showed to be ferruginous incrustations on intracellular elastic fibers. These appearances he likened to those recorded by Róna[4], who had supported Ssudakewitsch. In a second case, that of a greatly enlarged and bulbous nose, he observed elastic fibers in great numbers scattered about through and among the giant cells. Pelagatti[5], in an elaborate article, comes to the conclusion that peculiar cell inclusions that he has found in lupus tissue are the elements of a hydromycetic fungus, which has, however, no pathological significance. Gilchrist[6] read before the American Dermatological Association last year a paper on calcified bodies in lupuslike tissue, in which he describes a case where bodies similar to those referred to were present, which he proved had undergone usually a calcareous degeneration. The tissue was inoculated on a guinea-pig with the result that on its death, in a month, nodules were found in the liver which contained large numbers of similar bodies. It does not seem to have been definitely proved that this was a case of tuberculosis.

The following case is reported as a slight contribution to the subject, although the opportunity for examination was meager. The somewhat exceptional character of the case clinically had aroused the suspicion that it might be one of blastomycetes, and these peculiar bodies were at first thought to represent this form of fungus.

---

1 *Vierteljahresschr. f. Derm. u. Syph.*, 1875.
2 Virchow's Archiv., 1889.
3 *Journal of Medical Research.* March, 1902.
4 Ziegler's Beiträge, 1900.
5 *Monatsheft. fur. prakt. Dermat.* 15 Feb., 1901.
6 The Journal of Cutaneous Diseases, Oct., 1903.

The patient, a girl of thirteen, was first seen in November, 1900. She was born in Massachusetts, of American parents. Nothing of importance could be found in the family history. She had five younger brothers and sisters, all perfectly well. No history of tuberculosis in the family or among the child's surroundings could be discovered. She had always lived near Boston. The history given by the child and by her father, an extremely intelligent man, was that about one year before she was first seen, she had had a slight burn on the flexor side of the terminal phalanx of her left thumb. When nearly well, this burn was accidentally punctured by a brass hook. There then appeared at the site of the burn what looked at first like an abscess, which opened spontaneously, leaving the present appearances, which have, however, become more extended. Now the whole flexor surface of the terminal phalanx of the left thumb is occupied by a papillomatous fungoid ulceration, projecting upward nearly one centimeter, partly covered with crusts, and bleeding freely on light pressure. There is moderate infiltration of the base, which is quite soft. On the extensor aspect, the ulceration has extended around to the fold of the nail. It is moderately sensitive to pressure.

About seven months ago, or five months after the appearance of the lesion of the thumb, there appeared a lesion of the upper lip, somewhat to the left of the median line, above the mucous membrane of the mouth, which was said to have begun as a small papule. It has now increased to a diameter of two centimeters, and presents the appearance of a round, ulcerated surface, projecting above the level of the skin, of a papillomatous appearance, but not so well marked in this respect as is the lesion of the finger. There is not much infiltration and moderate crusting.

Two months ago, a second smaller lesion appeared on the chin, above the edge of the inferior maxillary bone, also on the left side, precisely similar to the one last described. This has increased somewhat in size, is rounded, and has a diameter of about one centimeter.

At about the same time that the lesion on the lip appeared, the submaxilliary glands on the left side began to enlarge. Now most of the above named glands are considerably enlarged, together with the left post-auricular and pre-auricular, and the sub-mental. There is slight enlargement, also, of the epitrochlear glands of the left side. No other glands are affected.

The patient is a rather pale and fragile looking girl, but not cachectic. There has been no disturbance in her general health. A

careful physical examination of the internal organs at this time and at later periods, was entirely negative.

This patient was seen at intervals during the next eight or ten months. Very little change was noted in the lesions except what would be naturally expected from various stimulating applications used, and no new lesions appeared. At the end of this time the patient was lost sight of.

The histological examination of a piece of tissue excised from the upper lip resulted as follows: Epidermis: the horny layer was about normal in thickness, and contained here and there masses of leucocytes. The stratum granulosum was increased in thickness, more so in some places than in others. The rete was very much increased in size, the interpapillary prolongations dipping deeply down into the corium, of which the enormously elongated papillæ projected upward. Scattered throughout the rete, and especially in the lower layers, are very numerous polymorpho-nuclear leucocytes. Corium: the upper papillary portions of the corium and the greatly elongated papillæ were the seats of dense accumulations of cells, in some places more circumscribed than in others; and these cell masses were composed of large numbers of plasma cells, lymphoid and epithelial cells, together with the connective tissue cells, and an occasional mast cell. There were very large numbers of plasma cells, while the epithelioid were few. Giant cells were not found in every section, but here and there typical Langhan's giant cells could be seen distinctly. The lower layers of the corium were normal, as far as could be determined. Sometimes a cluster of several giant cells was seen. The grouping of the cell infiltration in foci was apparent, although not to the extent that it is usually found in lupus.

The histological appearances of a bit of tissue excised from the lesion of the thumb were much the same as those of the lip.

In both the lesions of the lip and of the finger peculiar bodies were noted microscopically. They were not very numerous, not being seen in every section examined, although sometimes several could be noted in a single section. In most instances these bodies were enclosed in giant cells; occasionally they could be seen free in the tissue. They were in general of a rounded or oval contour, sometimes pear-shaped or elongated, and were often surrounded apparently by a membrane which was sometimes double. They were deeply stained by various reagents, but did not respond to the tests for elastic fibers. With polychrome methylene blue, they assumed a peculiar greenish blue color. In unstained sections, of which only a few were ex-

amined, the bodies were not made out. In sections stained with hæmatoxylin, the addition of strong or weak hydrochloric acid caused the bodies to lose their color immediately; sooner than the surrounding cells. In the further process of destruction by the acid, the bodies and the tissue disappeared at about the same rate. There were no signs of calcareous degeneration. Treated with thirty-three per cent. caustic potash, the bodies retained their stain far longer than the surrounding tissue cells and could be seen of a pale red color where the stain had completely faded from all the tissue. Later the stain disappeared entirely and the bodies disappeared gradually with the destruction of the rest of the tissue.

Twenty or thirty sections were stained and examined for tubercle bacilli, but without result. Several pieces were inoculated on guinea pigs by Dr. J. H. Wright, but neither tuberculosis nor any other lesions could be produced.

To summarize briefly, we have a case that presented lesions resembling tuberculosis more than anything else, but of a type sufficiently peculiar to prompt us to excise a bit for examination. This examination showed bodies similar to those described by other observers in tuberculous tissue, and in tissue resembling tuberculosis. It was not possible to prove that this was a case of tuberculosis. The nature of the peculiar bodies could not be determined. In this case there was no evidence of calcareous degeneration or that the bodies bore any relationship to elastic tissue. It was difficult to avoid the suspicion that they were parasites, although no essential proof could be obtained.

The case is interesting from the fact that the clinical appearances aroused a suspicion of blastomycetes; that the pathological examination failed to prove that it was a form of tuberculosis; and that peculiar inclusions were found, corresponding with those described by other observers as occasionally occurring in lupus, or in lupus-like tissue, which bore considerable resemblance to parasites.

A CASE OF EPIDERMOLYSIS BULLOSA HEREDITARIA, ASSOCIATED WITH CONGENITAL ALOPECIA AND ATROPHY OF THE FINGER ENDS.

By Grover William Wende, M.D., Buffalo, N. Y.

In December, 1902, in the *Journal of Cutaneous and Genito-Urinary Diseases*, I reported "A Case of Epidermolysis Bullosa Hereditaria, presenting Unusual Features." The aggregate of that case and the present one, considering their many points of resemblance, constitutes a definite clinical picture. In both cases the main features were present, beginning, at first, with bullæ and progressing into a continuous dermatitis on parts subjected to the greatest friction. Each case was marked by congenital alopecia and changes of the nails. While many variations have been reported in cases of epidermolysis bullosa hereditaria, in these particular cases the similiarity is striking. There was, however, greater vulnerability in the original case, inflammation following the slightest provocation. The one point of difference consists in the atrophy of the finger ends.

Family History: There is nothing in the family history to warrant the present condition. The mother, father, two sisters and two brothers of the patient have always been healthy. There is no suggestion of nervousness on the part of any of his ancestors, and no direct symptoms of syphilis were discovered in the parents, although the mother of the child has had three miscarriages. The birth of the patient was attended with difficulty, necessitating the employment of instruments.

Personal History: The patient is a light-complexioned, robust child of five years. He has suffered from convulsions since his eighth month, resembling the *grand mal* type of epilepsy; these appear quite regularly every three months. He was completely bald at birth, and so remained until after he was three years old, when a few scanty lanugo-like hairs made their appearance, which, for the last six months, have shown no progress. The peculiar skin manifestations did not appear until he was two years old, at which time he first tried to walk. They started upon the soles of the feet and were thought to be a scald; they, however, soon appeared upon the fingers. Acute inflammatory action of the large bullæ has never reasserted itself in connection with the case since the beginning, the chronic condition being associated with the smaller ones. The affection often recedes and seems almost healed, but after awhile the underlying tissue again reddens and scales off.

PLATE V.—To Illustrate Dr. Grover W. Wende's Article.

Fig. 1

Fig. 2

Fig. 3

Examination: The hair presents many interesting features. There is a complete absence of eyelashes and eyebrows. The scalp is covered with short, colorless, downy, irregular hairs, which, for the most part, are visible only upon close inspection. They are hardly more than an inch long, are void of pigment, are quite loose and can be pulled out easily.

Cutaneous Lesions: The ends of the fingers of both hands are affected. The condition is more marked on the palmar side than the dorsal, and does not extend above the metacarpo-phalangeal articulations. The affected area is red and covered with an epidermis split into various sized laminae. The skin is thickened and easily fissured; at times it becomes smooth, but the old condition soon returns. The index finger and the thumb are most seriously affected, due to the fact of their frequent use. Another interesting point is that the fingers are involved. This has led to atrophy, which seems to be more marked on the first finger than upon the others; there is also a decided change in the index finger nail, due to atrophy of the nail-bed, while the alterations in the other nails are but slight.

Plantar Surfaces: Wherever pressure has been exerted upon the soles the corneous layer has become hypertrophied, the result of previous inflammatory changes. The epidermis is split into layers of different sizes and has a tesselated appearance. This varies at different times, the changes being more or less influenced by the act of walking. Longitudinal fissures have been observed on the under surface of the great toe, due to inflammatory infiltration and to an overgrowth of horny tissue. The nails are thin and brittle and longitudinally striated. There is considerable hyperidrosis of the feet and the hands, a condition which at times becomes aggravated. Another condition noted was that comedones of unusual size are distributed all over the scalp. The forearms and the inside of the thighs are also invaded. Although these comedones are very large, they are not associated with inflammation and can be easily expressed by the nails. This condition has existed from the second year.

Conclusions: It has seemed worth while to place on record this fresh exemplification of the interesting disease under discussion, although it cannot be regarded as unique so far as the epidermolysis bullosa is concerned. In this case a bleb was not necessary in connection with the beginning of an inflammatory area, as the skin became inflamed and chronically infiltrated, and scaled off without the influence of the primary lesion. This action should probably be regarded as an important element in the disease, since one always thinks of epidermol-

ysis bullosa in its relation to bleb formation. From its clinical peculiarities it has come to be regarded as an entity, although it has been marked by numerous variations and so associated with contradictory clinical phases as to cause different authors to interpret it differently. In the third edition of Crocker on Diseases of the Skin, he gives a summary of the views of Hallopeau, Vidal and Besnier, who think their cases are different from epidermolysis bullosa because of "The inflammatory character of the eruption; the predilection for the dorsal surface of the articulations; the non-affection of the palms and soles; the cutaneous atrophy; the permanent cicatrices and the loss of the nails; the epidermic cysts, the bullæ may develop without apparent traumatism, and the acute outbreaks following nerve distribution areas." Crocker states that the special symptoms quoted do not present anything unique, but belong to the class already generally recognized. It will be doubted by many whether this case should be classed with epidermolysis bullosa hereditaria proper; or, on the contrary, whether it should not be classed with the so-called dystrophic form. No special attempt has been made at classification, the writer having no inclination to add to our already overburdened dermatological nomenclature. The special interest the present case possesses relates to the association of the peculiar changes of the skin with the delayed development of hair, which is undoubtedly connected with the other conditions; and to the atrophy of the finger-tips; the diameter being reduced about one-half. The atrophic changes are disguised in the photograph, due to the scales covering the areas. An X-ray examination did not show any deterioration of the bones. Dr. Stelwagon, through whose courtesy I saw the patient, reports a case where atrophy of the finger-tips was most marked. The patient was twenty years of age. There was a continuous bleb formation upon the hand, wrists and upper back, and, especially, at the fingers, which caused a loss of the nails and of the phalanges. In comparing Dr. Stelwagon's case with my own, one of the most noteworthy features is presented in the atrophy due to long standing and continuous mechanical irritation. This is more marked in his case than in mine, his patient being twenty years old and mine only five. In his case there was no delayed development of hair.

From the facts belonging to these cases only one hypothesis can be advanced as to the etiologic factors. It seems evident that we have in them a great variety of manifestations, including a large per cent. of cases of defective nail development; we may soon add con-

genital alopecia, a cutaneous condition, and not a disease, in the strict sense of the word.

This condition may be the result of one or two factors, or of both together; first, improper development of the cells of the rete Malpighii, and second, lack of proper trophic innervation, and not, as generally accepted, a vasomoter irritability. These two factors may be combined, in varying degrees, in such a manner that the resulting cutaneous condition will manifest itself in the lesions of epidermolysis bullosa alone, or in alopecia and onychia alone, or in both, in the same individual.

It would seem that where bleb formation is easily brought about, the trophic nervous disturbance must be an important factor, because of the bleb formation and inflammatory reaction after even slight traumatism. I have considered all these changes of trophic and defective development under one head, since all appear to be dependent on a lack of resistance in the skin, to be embryonic in origin, and, in most cases, to be hereditary.

The history of this patient is worthy of note, as there is no evidence of hereditary predilection, and a possible injury of his head, caused by instruments used at his birth, may be regarded as the source of the epilepsy, and may account for the peculiar nerve disturbances. However, this condition has not before been noted in conjunction with epilepsy.

VITILIGO TREATED WITH FINSEN LIGHT.

By Douglass W. Montgomery, M.D.,

Professor of Diseases of the Skin, University of California.

(Read before the German Medical Society, San Francisco, Cal., Nov. 12, 1903.)

A MAN, nineteen years of age, and a full blooded Mexican, consulted me January 28, 1903, on account of vitiligo, which he said began at five or six years of age, and had been steadily growing worse until he had patches scattered over the entire free cutaneous surface. There was one tuft of white hair in the occipital region. It was the usual picture of vitiligo; a white patch with an accentuation of pigmentation about it, and with no subjective symptoms or desquamation whatever. The patient said that his father had told him that some of his relatives were similarly affected.

In regard to his general health, the patient suffered from constipation, flatulent dyspepsia, and a little acne. But he was a strong,

well built, hearty fellow, and the vitiligo could not be ascribed to any dyscrasia whatever.

On his first visit a lotion consisting of two grains of corrosive sublimate to the ounce of dilute alcohol was ordered to be used topically once a day, and internally a capsule containing arsenite of potash gr. $^1/_{50}$, ipecac gr. ¼, and precipitated sulphur gr. x, was prescribed.

I again saw the patient April 25, 1903. The acne was better, but the vitiligo was unimproved. The Finsen light was then proposed on account of its well known stimulating effect on the skin in general, and especially on the pigment. Only those spots were treated on the face and hands that were exposed to view. He had, in all, nine sittings and at each sitting the light was applied ten minutes to a given spot until a good reaction was obtained. The skin was well reddened as in a sunburn. Some of the more recent spots about the mouth showed immediate improvement on the subsidence of the inflammation. Some of the older spots were much slower, both in reaction and in improvement. In fact, he stopped treatment long before restitution of pigment in most of the spots. There were nine sittings in all, and about five applications of the light to each spot treated. The instrument used was the London Hospital Lamp.

In September I had a letter from the patient, saying that there was not a sign of a patch on the face, and that those on the hands had nearly all disappeared.

Vitiligo is one of the most stubborn of diseases to treatment, and any alleviation of the disfigurement would be most welcome. Light was tried in the above case simply because of its well known powerful effect on the pigment of the skin. It is interesting to note that in a case of chloasma, a disease which, in some respects may be looked upon as the direct antithesis of vitiligo, a course of treatment with the Finsen light, caused, if anything, an increase of pigmentation, and therefore an increase of the disfigurement. This therefore, might be looked upon as an additional evidence of the efficacy of this mode of treatment in vitiligo. In a careful search through the literature of diseases of the skin I have been unable to find any reference to the treatment of vitiligo by light.

Vitiligo is not a disease giving rise to any subjective symptoms, or to any deterioriation of the general health. Nor is it a disease that occurs frequently. In my private practice I have had nineteen cases in a total of 5,612; that is to say 3.3 per mil., and in clinic practice 17 cases in 4,888 cases, making 3.4 per mil. When it occurs on an exposed portion of the skin, however, as on the hands and

PLATE VI.—To Illustrate Dr. Douglass W. Montgomery's Article.

face, it assumes an importance wholly incommensurate either with its frequency or with its effect on the general health, as it renders the patients utterly miserable. As an increase of this discomfort the laity tend to attribute vitiligo to the presence of some abhorred disease such as syphilis or leprosy. In some countries, indeed, as Münch* has shown, it is looked upon as positive evidence of leprosy, and the patient is banished from his village.

DESCRIPTION OF PLATE.—Dr. Douglass W. Montgomery's Article.

FIG. 1 and FIG. 2 These two illustrations are simply to show the extent of the disfigurement, in some cases, of vitiligo, and are remarkable as showing the whiteness and the symmetry of the patches and the depth of the pigmentation in the surrounding skin. This young woman was seen in consultation with Dr. Krotoszyner, Sept., 1895. She was in excellent health, and there were no symptoms of Addison's disease or any other dyscrasia.

FIG. 3. This illustration of the leucoderma of leprosy is given simply to show how closely it resembles true vitiligo, even to the slight accentuation of pigmentation around the patch.

This photograph was taken in March, 1892, more than eleven and a half years ago. The patient, a Chinaman, was then suffering from tubercular leprosy quite extensively distributed. He was sent to the San Francisco Pest House, where he is now in a most pitiable condition, and is considered to be at the point of death.

A CASE OF FEIGNED ERUPTION.

By William S. Gottheil, M. D.

THE following case is of interest on account of the length of time during which the patient succeeded in imposing self-inflicted injuries upon her attendant as a true dermatosis, supposedly of hysterical origin. The deception was not detected during the weeks that the patient spent in Lebanon Hospital under close observation; and certainty was only obtained when she was so emboldened by success that she developed her lesions to such an extent that their traumatic origin was clearly apparent.

B. V., single, female, aged 28; April 30th, 1903. Had a child 10 years ago. Has been hoarse since childhood, and claims that this condition remains unchanged summer and winter. Five and a half years ago was operated on for appendicitis. Three months ago noticed that her abdomen began to swell, and has been irregular in her menstruation since that time.

For several weeks past has had attacks of nausea, vomiting, and

*In Turkestan vitiligo is looked upon as positive evidence of leprosy. Die Zaraath (Lepra) der hebräischen Bibel von G. N. Münch.

diarrhœa, coming on at intervals of two weeks or so, and lasting for several days. During these attacks she becomes extremely nervous and hysterical, and cannot sleep at night. On the second day of the first of these crises there appeared the first signs of the eruption. It consisted of minute water blisters which gradually became bean-sized and then broke; red spots were left behind, which increased in size for a number of days, until they finally stopped growing, paled, and faded away.

Two weeks later there was another similar eruptive attack, heralded and accompanied by the same gastro-intestinal and neurotic symptoms. A third one began a day ago, and is in full bloom now.

It was learned from a member of the dispensary staff who happened to see the patient that she had been treated by him for syphilis a number of years ago; the patient said nothing about it.

So much for the history; examination showed her to be a tall, dark, anæmic and markedly neurotic woman. Urine negative and tongue clean in spite of her history. Thoracic organs normal; abdomen hard and contracted; there is apparently an abdominal tumor, but it was impossible to decide at once whether the appearance was not due to the abdominal rigidity: there was a large retracted scar on the right side of the abdomen, the remains of her appendicitis operation. Marked hoarseness was present.

All over the skin of the abdomen, chest, arms, buttocks, and thighs were scattered the lesions of which she complains. They were of three distinct sets or types, marking the three attacks that she has had; but, though well distributed over the surface of the body, and mingled with one another, no lesion encroached on the site of a pre-existent one; they were all separate and distinct.

The most recent lesions, which had appeared within the last two days, were circular or ovoid bullæ, half to three-quarters of an inch in size, covered with a flaccid and wrinkled epidermis, containing a small amount of clear serum, and surrounded by a very narrow but vividly red inflammatory zone. There were no smaller or beginning ones.

Interspersed with these were somewhat larger circular areas of a dusky red color; these represented the lesions of two weeks ago. Those of the original eruption of five weeks ago were similar but faint rose-colored stains. The entire number of lesions present, new and old, amounted to at least one hundred. (Fig. 1.)

The palms, soles and face were free. There were comparatively few lesions upon the back. Suspicion as to their traumatic origin was therefore at once aroused. The patient was treated for her gastro-intestinal disturbances, and the skin was left entirely alone.

On May 6th. the patient had another attack, some 50 new lesions appearing. A few of these were quite small, pea-sized; these were said to have appeared the previous night.

I now sent the patient into my service at Lebanon Hospital, more to have her closely watched than for treatment. At the time of her admission the last crop of lesions was progressing to recovery. A new bullous eruption appeared when she had been there a short time; and as many of the efflorescences were seated under the pendulous breasts and in the genito crural fold, they resulted in extensive and very painful excoriations. Although she was under careful observation all the time neither the House Staff nor the nurses detected anything that would have led them to suspect that the injuries were self-inflicted.

During the five weeks that the patient was in the hospital repeated examinations of her other troubles were made, but without any definite result. The gastro-intestinal disturbance came on at the hysterical crisis that preceded and accompanied the advent of the new crop of skin lesions without any special cause, did not show the usual local symptoms, and disappeared without treatment. There was no abdominal or pelvic tumor; contraction of the abdominal muscles caused the apparent presence of one as revealed by an external and cursory examination. The hoarseness was found to be an hysterical phenomenon for which there was no pathological basis. The patient left the hospital voluntarily and in somewhat improved condition.

On August 19th she came back to me worse than ever. The bullæ were larger and more numerous; large areas of skin under the breasts and around the thighs and nates were excoriated and raw; she had lost flesh and strength, and her general condition was pitiable. The nausea and vomiting this last time had been worse than ever, and she had been compelled to stay in bed for a number of days.

On August 24th, when I next saw her, there was another eruptive attack; but the configuration of the lesions had begun to change, and this change became more marked in each of the succeeding attacks. The flaccid bullæ were larger; many of them were oval; and some of them had a distinct prolongation or tail, always pointing downward, and looking as if large drops of irritant material had been applied to the skin whilst the patient was standing up, and the excess had run down. One or two lesions were even of rectangular and bizarre shapes. The diagnosis had been probable before, and of course this settled it. I wanted her to enter the hospital again, proposing to bandage the trunk and limbs so that she could not get at her skin; but the patient had evidently become suspicious, and refused under the pretext that her relatives would not permit her to do so. (Fig. 2.)

Probably because she saw that we were losing interest in the case and she was not getting sympathy and attention enough, the lesions in the three attacks that she had in September were more extensive and curious still. Once she came with them in a series of parallel rings or bands extending half way around the thighs, and with one or two completely encircling the limb like garters. (Fig. 3.) Ten days later the streaks were longitudinal instead of transverse; and some of these streaks were ten inches in length. (Fig. 4.) All of them were precisely similar in character; the streaks and garters were distinctly bullous and their margins were surrounded by the narrow vividly red zone that characterised all the lesions. It was noticeable that fresh areas of skin were always selected for the new spots; old areas were permitted to heal and become mere stains before they were again attacked; and when, evidently by accident, a still unhealed area was impinged upon, as occurred with the longitudinal and transverse lesions on the thighs, the patient complained with especial bitterness of the pain that they occasioned her. There were but few lesions at any time on the less accessible portions of the body, as the small of the back; and there were never any between the shoulder blades, where the skin could not be reached, or on the face and hands where they would be visible, or on the feet where they would interfere with locomotion.

The last time that I saw the patient was on October 13th. There were then no new lesions; she had evidently maltreated her skin to a greater extent than she intended, and was giving it a chance to recover. When I asked her if she knew what Spanish fly or cantharides was she professed entire ignorance of my meaning. But when I asked her if she knew what carbolic acid was she became very indignant, and said, "Do you think I have made these myself?" She left in anger, and I have not seen her since.

I have very little doubt that the agent employed to produce the eruption in this case was pure carbolic acid. There never were the tense, full vesicles of cantharides; nor was there ever any of the toxic effects that would be expected from its employment on what was often, collectively, a very large area of the cutaneous surface. It is true carbolic acid in concentrated form usually causes an eschar and not a blister. But the bullous element in this case was not conspicuous; there was merely a slight raising of the wrinkled epidermis by a small amount of serum.

DESCRIPTION OF PLATE.—Dr. W. S. Gottheil's Article.

Fig. 1. Bullous eruption, April 30, fainter lesions being the marks of the previous crops.
Fig. 2. Bullous and streaked eruption, August 24.
Fig. 3. "Garter" lesions of September.
Fig. 4. Marks of the patient's final efforts.

PLATE VII.—To Illustrate Dr. William S. Gottheil's Article.

Fig. 1. Taken April 13th, 1903.

Fig. 2. Taken August 24th, 1903.

Fig. 3. Taken September 27th, 1903.

Fig. 4. Taken October 4th, 1903.

METHOD OF USING SURGEON W. F. ARNOLD, U. S. NAVY'S PHOTOTHERAPEUTIC APPARATUS.

THE Nernst lamp (either for constant—"D. C.," or for interrupted "I. C." current, such as is furnished for ordinary incandescent lighting) is shown in the upper part of the accompanying photograph on the right side (a), supported in an ordinary chemical-apparatus stand. Opposite to it and in the prolongation of the axis of revolution of the paraboloid, another paraboloid of revolution is held facing the first, which is the reflector for the lamp. (b) The second or smaller paraboloid, is cut off exactly in its principal focus perpendicularly to its axis of revolution; hence its action will be to concentrate parallel rays at its principal focus, which, in the case illustrated, would be upon the thumb-web of the back of the operator's left hand. In addition, the whole circle, or bottom, of this receiving paraboloid (which might, perhaps, best be called the concentrator), will be evenly illuminated both by the parallel beams from the reflector upon the lamp and by divergent rays proceeding directly downward from the lamp itself—not having undergone reflection.

The large, dark, conical object on the left of the photograph (c), is a $^1/_{12}$ horse-power fan, covered with a hood, to secure a stream of air, which is for the purpose of removing undesirable heat from the part to be acted upon. This is easily accomplished by directing the current of air into the concentrator, which is shown in the photograph (d). (It should be said that some form of *blower*, such, for instance, as is supplied by the Sturtevant Fan and Blower Company, is far preferable to the expedient shown. With a Sturtevant blower, driven by a ¼ H. P. motor, I have been actually able to "dephlogisticate" the full beam of a search-light (48-inch Mangan projector) of 20,000 C. P. that I had concentrated within a half-inch circle; so that I had test-tubes of nutrient gelatin almost incandescent but unmelted for minutes together at a spot which, without the air current, had readily melted ¼ inch zinc.)

By cutting off more of the concentrators (i. e., beyond their foci), subcutaneous concentration of light rays may be effected. This scheme is entirely new; and so, I believe, is my suggestion for protecting the skin with capsules of gelatin containing oil, etc., crowded into the concentrators.

The concentrators had best, perhaps, be attached to rods connected with the margin of the lamp's reflector. The lamp can be used in any position, which is a great advantage over any lamp in

use for phototherapeutic purposes. These latter are, without exception, so far as my knowledge extends, arc lights; hence, they will not burn without constant attention and regulation, if at all, in any other position than with their carbon electrodes placed one vertically above the other. This quite often makes it difficult to apply light efficaciously to the more inaccessible portions of the human skin, and often renders very awkward and tiresome positions necessary.

My apparatus is easily portable and could without much difficulty be used at a patient's residence, if conveniently fitted out electrically.

It can be guaranteed to afford twice the effectiveness of any other appliance for a similar purpose for, at the most, but one half of its cost.

San Francisco, California.

A TENTATIVE SUGGESTION REGARDING THE NATURE AND CHARACTER OF X-RAYS.

M. L. Heidingsfeld, M.D., Cincinnati.

ALTHOUGH almost a decade has passed since the X-rays were discovered by Roentgen, on November 8, 1895, and almost a century since they were foreshadowed by Faraday's conception of "radiant matter" in 1816 and produced but not recognized in the interim by other observers (Crookes, Lenard), their nature and character still remains, for the most part, at least, an unsolved mystery, notwithstanding the fact that they have been very generally and universally employed, and studied with most intelligent and persistent skill.

The more recent contributions to the already extensive X-ray literature, are devoted almost exclusively to the consideration of the histological and pathological changes, and to matters that pertain principally to therapy and technique, and what relatively little attention has been given to the nature of X-rays from a physical standpoint is so vague and indefinite in character, that the following theory for its production is offered, merely as a tentative suggestion, with the hope that future investigation will secure its prompt rejection or confirmation. This theory has been gleaned partially from the little knowledge already possessed regarding the nature of X-ray, and partially from physical, pathological and therapeutic phenomena as gathered and observed from time to time, over a period of several

PLATE VIII.—To Illustrate Surgeon W. F. Arnold, U. S. Navy's Phototherapeutic Apparatus.



years of practical experience. Although the theory plausibly explained almost every well known phenomenon, from the time it was first conceived, and seemed hypothetically rational, its expression has been deferred because it lacked a certain degree of positive confirmation. This confirmation, with a few suggestions for its attainment, is now entrusted to future investigation.

The basis for the theory rests on Faraday's conception of a fourth state in addition to the time honored three states of matter, solid, gaseous and liquid, namely "radiant matter." Radiant matter, according to Faraday's conception, differs from gaseous matter, only in this, that the "mean free path" of the molecules are so far extended that they can travel within the contained vessel with relatively few collisions. It will suffice for the purpose of our theory to merely grant that a fourth state exists, to which matter can, under favorable conditions, be readily raised irrespective of the path of the molecules or its distinction from gases. Therefore, accepting Faraday's conception, the X-ray is radiantly active matter with molecules actively and easily moving without collision, and this matter, if our theory is correct, consists of small particles of platinum emanating originally from the anode disc, which is thrown into a high state of activity by the favoring conditions, high voltage, low amperage and high frequency of the current, high vacuum of the tube, etc. This high activity on the part of the anode platinum disc is evidenced also by its rapid elevation of temperature from a dull red glow to an intense white heat. Completing the hypothesis, the X-ray then consists of minute particles of platinum, in a very high state of "radiant" excitation, emanating from the enclosed disc and moving radially with sufficient velocity to readily penetrate the circumscribed glass enclosure and all opposed soft and fairly hard substances. Upon this hypothesis almost all the well known and otherwise scarcely explicable phenomena, both physical and physiological, can be readily explained.

This theory finds some degree of confirmation in the close analogy, which has been observed and frequently commented upon, existing between the X-ray and the radio-active properties of uranium, radium, polonium, and allied substances. It is a natural and almost fair assumption to attribute to these radio-active substances the same properties in their natural state that platinum, iridium, etc. possess only in a very excited or unnatural one, and bear the same relation to each other that solids bear to liquids, or liquids to gases when the former are changed to the latter by abnormal influences. Although substances in their natural state were known for many years to possess

a certain degree of fluorescence or luminosity; that is to say, were able to show a certain degree of light in the dark, which was often more intense after a previous exposure to the sun's rays, and even had a practical bearing to the extent that the earth *thoria* had been used for incandescent purposes, the knowledge that these substances possess penetrating power is relatively a recent acquirement.

The celebrated French scientist, Becquerel, placed a photographic plate, enclosed in a holder, together with some uranium and an accidently interposed key away in a drawer for an indefinite period, and, upon developing the plate later, found to his surprise an image or shadowgraph of the key. This incident promptly led to the discovery that uranium possessed radio-active properties of definite penetrating powers; the so-called "Becquerel" rays, similar in many respects to the "X" or Roentgen rays. The analogy between the X-rays and the rays from the radio-active bodies is rendered more complete by numerous physical and physiological characteristics of striking similarity. Both are invisible and cannot be detected by the unaided eye unless rendered luminous, on the one hand, by the action of barium tungstate, platino-barium-cyanide, etc., or, on the other, by Sidot's blende, diamond, zinc oxide, willemite, etc. Both impart to any interposed glass, through which they are made to pass, a violaceous hue. Both exercise similar and extraordinary influences on animal tissue, inhibiting pathological growth and disease, inducing depilation and even indolent ulceration and necrosis, in accordance with prolonged action or special idiosyncrasy. These few, together with many common properties, such as their marked penetrating powers, the impenetrability of excessively hard substances, the power of the chemical or physical effects on photographic plates, the increased ozone production, etc., indicate that there are many points of such striking similarity, that it is comparatively easy to conceive that the one is matter brought by some peculiar form of excitation to a state similar to the other.

The theory that the X-ray consists, for the most part at least, of minute and highly excited particles of matter, such as platinum, is evidenced by an analogy that can be traced to radium, and the action of the latter on Sidot's blende as observed through Crookes' spinthariscope. Crookes has observed the action of radium on Sidot's blende, through a special form of microscope, called the spinthariscope, by means of which he has been able to observe the fiery shower of minute particles of radium upon the blende and the beautiful effect

of their countless scintillations—thus establishing by ocular proof its actual radiation.

The fluorescence, which the X-ray produces on various salts and minerals, such as barium tungstate, platino-barium-cyanide, etc., can be readily explained on the basis of the physical or chemical action of the highly excited platinum on these substances, and likewise the invisibility of the ray by the absence of such a specific action.

The action of the excited particles of platinum upon barium tungstate or platino-barium-cyanide is in all respects comparable to the action of radium upon Sidot's blende.

The phenomenon of a transparent substance like glass casting a shadow upon the fluoroscope, can be readily explained by its firm, impenetrable character and the intensity of the shadow will vary with the thickness and hardness of the interposed glass. Shadows of every description, whether upon the fluoroscope or photographic plate, can be easily explained by the relatively greater hardness or resistance on the part of the substance through which the flying particles of platinum must pass in order to reach the exposed surface, relatively fewer particles being enabled to pass, the harder or more resistant the character of the interposed substance, with a corresponding density of shadow.

The photographic action of the X-ray can be explained on the basis of the physical or chemical action of the platinum on the silver salt.

The phenomenal difference of hard and soft tubes is easily explained by the relatively greater excitation of the platinum in the hard tube of lower vacuum, and the consequent deeper and greater penetration of the radiantly active platinum—the intense shadow of the bony structures are also explicable on the same basis, and the relatively more frequent burns from soft tubes can be attributed to the lesser degree of the penetrating power of the platinum and its corresponding more superficial action.

The phenomenal darkening of the tubes can be attributed to particles of platinum which are arrested in their passage through the glass walls and to their gradual accumulation as they become impacted.

This darkening, however, is very slight in amount, merely sufficient to give to an X-ray tube, which has been repeatedly excited by X-ray action, a faint violaceous tinge. The relatively far greater discoloration is due to the metallic coating deposited upon the internal surface of the tube, distributed for the most part directly over

the platinum target, and can be easily removed with hydrochloric acid, more readily with the addition of a little heat, or the admixture of nitric acid. This coating possesses an unmistakable metallic lustre, and undoubtedly traces its origin from the platinum target or some other metallic substance within the tube, and its deposition and formation can be intelligently explained by the arrest of the minute metallic particles by the impenetrable glass walls, which remain impenetrable to particles driven with a lesser degree of velocity. As already stated, the removal of this internal metallic coating does not free the glass tube of a hazy violaceous hue, which imparts a certain degree of additional lustre. It is reported that the X-ray exercises a similar influence upon yellowish and inferior grade diamonds, when exposed to its prolonged action, and imparts so much additional lustre and clearness, and so materially enhances their value, that its employment in this direction is a distinctly profitable venture.

The therapeutic action can also be attributed to the direct medicinal or antiseptic properties of the platinum, comparable in analogy to silver and other metals, and more effective by reason of its more favorable distribution or highly radiant state; necrosis and sloughing, to a relatively more intense action sufficient to replace stimulation of cell tissue by actual destruction.

Upon the basis of this theory, the element of personal idiosyncrasy, which plays such an important rôle in X-ray therapy, to the extent that in a given affection X-ray treatment may be followed in one case by prompt and complete cure, in another by a negative or indifferent result or in a third by a deleterious or harmful reaction or dermatitis, is more readily comprehended when the therapeutic action of platinum is compared to the medicinal effects of such substances as mercury, iodine, etc.

Although the purely speculative character of the theory is readily conceded, its expression has been strongly encouraged, partly by the facility with which phenomena, otherwise almost inexplicable in character, are readily explained, and partly by reason of the analogy that apparently exists between the X-ray and radium, and the current and generally accepted views regarding the nature of its radiation. It is not claimed for the theory, in its present state of elucidation, that it satisfactorily and completely explains the different phenomena in all their phases, and it is probable that we can safely ascribe to the X-ray also a triple or manifold character as has already been attributed by Crookes to radio-activity (1), ultragaseous, or free electrons (2), true atoms, composed of larger bodies (3), penetrating rays. For

example, it would be difficult to explain purely on the basis of the platinum atom or molecule theory how a lead plate placed distally to an interposed photographic plate could render the image sharper and more distinct; or why the addition of lead to glass in its manufacture should render it less penetrable to the ray in a manner quite out of proportion to its increased hardness or brittleness. In other respects the X-ray conforms to the law of penetration of bodies, in marked contradistinction to light, and differs materially from the latter inasmuch as it cannot be reflected. The deflection of the X-rays by means of the magnet is explicable if we can attribute to the particles that they are electro-positively or negatively charged, in their flight from the tube.

The confirmation of the theory must entail the absolute detection of traces of platinum, after its escape from the disc to its point of ultimate deposition, which may be the wall of the tube; better, however, would be to examine some object which had been subjected to its prolonged action, at some distance from the tube. This phase of the question is left to some future investigator. Much additional confirmation, but less absolute proof, can be given the theory by a careful estimation of any loss of platinum from the disc after a careful consumption of the tube, preferably with repeated exhaustions. The platinum disc should preferably be of relatively light weight, in order to more readily show any appreciable loss.

A further interesting investigation will be the determination of what metals other than platinum, iridium, etc., will yield X-rays, and the nature, character and analogy of their respective physical and physiological properties and phenomena.

EDITORIAL.

THE PASSING OF "ECZEMA."

WITHOUT question, dermatology in the past has exhibited a vulnerability in its nomenclature. An almost unremitting criticism, however, of the weak side has resulted in the establishment of a sound basis for many of its facts in spite of the looseness of its designations. It is only within the last few years that in other fields of medicine, physiological chemistry and neurology, for example, the titles launched into the arena of science have been equally formidable as to their size, their number, and the eccentricity of their classical features.

In the list of accepted diseases of the skin, while the new arrive, usually with an excuse for their coming, the old, in many cases, lose the excuse for their survival. Is it not clear that the word "eczema," which once meant something,—indeed, once meant a great deal to the older writers and observers,—has outworn its usefulness.

Its history discloses at the outset a floundering in a quagmire of ignorance and an emergence upon only semi-solid ground after much travail of keen observation and writing. What dismal portents for the future were furnished by the old achor, porrigo, herpes esthiomenus, lichen, and the other titles which Erasmus Wilson cherished and von Hebra derided! What mists of darkness were those in which Rayer and Willan struggled courageously toward the light!

"Dermatitis" has been clothed with a new dignity since the culture-tubes and the stained sections of the laboratory have declared what, in many cases, it represents. Nearly a score of names in combination with the simple title indicate today how extensively the ancient demesne of "eczema" has been appropriated by the later invaders.

The word "eczema," in the mouth of the expert, has become a feature of the language of the street, of the advertiser, of the charlatan. There are few experts who now use it without a species of mental reservation or qualification. There is no "eczema" in the absence of dermatitis: is there any dermatitis without some of the accepted symptoms of "eczema"? Even von Hebra wrote of an "artificial eczema."

The doom of the word is probably written. It will survive where it belongs, and with no greater repute than attaches in general to the outworn and the discredited.

J. N. H.

BOSTON DERMATOLOGICAL SOCIETY.

October Meeting, 1903.

Dr. James C. White in the chair.

A Case for Diagnosis. Presented by Dr. James C. White.

The patient is a healthy woman of fifty years. She has had no children and the skin of her family has been normal.

Some twelve years ago her whole skin became itchy without apparent cause, and it has continued to itch almost constantly since, much worse in summer. There were no visible changes in the skin until eight years ago, when water blisters, large and small, some of them the size of a half dollar, began to appear on the backs of the feet. They have continued to develop at intervals since, extending to the knees, mostly appearing in summer. They leave no marks upon the skin. The whole integument of the arms and legs becomes intensely red at times. This condition is of short duration. Her general condition has remained fairly good.

Now, the legs, from groins to ankles, present a mottled, reticuled aspect of a rusty-red color with small circular interspaces of normal whiteness. The red areas are somewhat thickened and elevated and slightly roughened. This dull redness disappears slowly and imperfectly on firm pressure. On the upper, inner thighs there are light brown pigment spots of considerable size. The arms are slightly reddened in places and present over the lower half smaller pigmented spots. They have always itched less than the lower extremities. The face and trunk present no abnormal appearances. The subcutaneous glands are apparently healthy.

In the discussion none of the members could suggest any probable diagnosis and in closing Dr. James C. White said that the disease began with a generalized itching, increasing in intensity for two years, which was followed by the appearance of vesicles and bullæ and these manifestations made him think of an extraordinary example of mycosis fungoides as a possible diagnosis.

A Case for Diagnosis. Presented by Dr. C. J. White.

Two months ago there appeared on the chest of the patient, an American man aged 60, several small, firm nodules, which were soon followed by other and similar lesions until to-day there are perhaps twenty round, dull-red, distinctly firm (without seeming hard), isolated nodules the visible surfaces of which are domed, smooth and free from scales. Some of these lesions reach the size of a large pea, and are situated at the base of the chest and the upper part of the abdomen, forming a U-shaped group surrounding the lower portion of the sternum. There are no subjective symptoms and the patient appears markedly vigorous and well.

These notes were taken on September 25th, when the man was given a wash of sulphur, camphor, and alcohol.

At the same time one of the nodules was excised and moderate bleeding was the only condition noted in connection with the wounded surface. Thus the expectation of finding sebum or purulent matter or detritus was not realized.

On October 15th the condition of the nodules had not materially changed and an ointment of resorcin was recommended.

On October 27th, or about three months from the inception of the process, the appearances are much altered. Now the whole condition suggests a seborrhoic state. The lesions have become a dull, waxen yellow, are diminished in height and in many instances are surmounted or surrounded by greasy scales which vary in color from yellow to black.

Histopathology.

The sections were cut in paraffin and stained by hæmatoxylin and eosin.

The horny layer shows no important deviations from the normal. The stratum lucidum is absent. The granular layer is two to four layers in thickness and the individual cells contain abundant granules of keratohyalin. The rete is in places rather hyperplastic, the individual cells being widely separated by œdema, while the protoplasm is rarified by the same process and in places absent with nuclei crescentic and flattened against the cell wall. Occasional polynuclear leucocytes have found their way into the interstices of the rete cells.

Corium. The collagenous cells are much rarified and show marked absence of nuclei, while on the other hand there is a considerable diffuse infiltration of leucocytes—mostly lymphocytes with an occasional polynuclear element—throughout the layer. The vessels are widely dilated, but not particularly abundant and are filled with red corpuscles and polynuclear leucocytes. Here and there a widely dilated lymph space appears. In places there is considerable hæmorrhage throughout the tissue but in no apparent connection with any vessel. The appendages of the skin are entirely wanting and although the biopsy proved far too superficial, still there are no traces of any sebaceous glands, hairs or sweat ducts.

Dr. Bowen said that the disease seemed to him to be an acneiform eruption with lesions situated chiefly about the glands. It was certainly not an ordinary acne, being peculiar in its appearance and location.

Dr. Harding agreed in the main with Dr. Bowen, but thought it unusual for an acne to extend so far down over the sternal region and to be so limited in extent. The appearances suggested bromidism, but the history should exclude this diagnosis.

Dr. James C. White spoke of the firm resistance of the lesions which did not suggest to him an inflammation, but rather some distinct tissue change.

Dr. C. J. White agreed with the others that if he saw this case for the first time to-night he would certainly consider it connected with acne,

but at the first examination the lesions were totally unlike acne as one can infer from the description of the case when first observed. Dr. C. J. White had no diagnosis to offer, as the microscopical examination threw no light on the subject.

A Case for Diagnosis. Presented by Dr. Bowen.

Boy eleven years of age. No previous illness except diphtheria in May, 1900. Small, rather thin, but fairly nourished. Present eruption began fifteen months ago on right knee extending up and down the leg and over the trunk. The eruption has disappeared several times almost entirely. He has been in his present condition about one month. When admitted to the hospital on October 5, 1903, the eruption occupied chiefly the extensor surfaces of the extremities and the trunk. In the scalp were a few dry, reddened and scaling patches, more or less circular with thickened skin. Forehead dry and leathery with moderate-sized adherent scales. Cheeks also scaling with some isolated papules. Scaling with papules in eyebrows. Over the trunk and extremities the eruption is composed of small confluent, dry papules, more or less pointed in shape, in other cases rather flat at the top. The color is a dull red and there is slight scaling of the individual papules as well as of the confluent patches. Over the front of the chest from just above the clavicle to the level of the fifth rib the eruption is continuous, the border line rather sharply defined. On the extremities the eruption is represented by more or less well defined areas of these dry papules.

On October 9th, the eruption had faded perceptibly under soothing washes and pastes, but on October 26th a relapse was noted, more papules appearing with an accentuation of those already existing.

Dr. Harding said that at first sight he would have thought of pityriasis rubra pilaris, but closer examination would exclude this diagnosis. He would therefore look upon this eruption as a tuberculide.

Dr. C. J. White had seen the case before, when the disease was more scaling and less papular, and would be inclined to regard it as a parakeratosis variegata, placing it in the rather large and hazy group described by Brocq under the title "Parapsoriasis." The skin was distinctly inflamed to-night, due, undoubtedly, to the treatment, but in some places there were also suggestions of *erythrodermie pityriasique en plaques disseminées*, another division of Brocq's "parapsoriases," three examples of which Dr. J. C. White and Dr. C. J. White had published.

Dr. James C. White did not think the appearances like pityrias rubra pilaris. The seat is not the same, there are no changes in the scalp, no changes in the palm at all corresponding to the typical manifestations of that disease. A seborrhoic eczema was not an impossibility. It was a little more papular than we expect to find in the group of cases mentioned by Dr. C. J. White and it also itches somewhat.

Dr. Bowen had not thought of the group of parakeratoses but had considered the possibility of lichen scrofulosorum, although the papules were not sufficiently grouped and glandular enlargement was absent. He had also thought of a follicular eczema but was not prepared to make this diagnosis.

Carcinoma of the Nose. Presented by Dr. Harding.

Man, 58 years of age. Marine engineer by trade, has on the right side of the nose two closely approximated tumors, each about one-half inch in diameter and raised an equal distance above the level of the skin. The tops are denuded and covered with a tough crust, which is somewhat softer on being penetrated but shows no moisture or exudation. The masses are of very firm consistency to touch. They are not painful but the upper one gives evidence of slight tenderness on pressure.

The patient states that somewhat over a year ago he had a scaling spot (keratosis senilis) on the site of the upper tumor. This began to grow and last April was the size of a large pea. It was excised at that time, but started up again soon, and with it a similar-sized growth below it. These were both excised in July, but began to grow again soon and on September 7th had attained the size of a cherry. The X-rays were then applied twice a week, nine or ten times, during which the growths increased until they attained their present dimensions.

The members of the society all agreed in the diagnosis of carcinoma.

A Case of Bullous Dermatitis. Presented by Dr. Bowen.

The patient was an Englishman, thirty-one years of age. Family and previous history good. He was vaccinated in January, 1901. According to his own account there was considerable swelling of the arm, so that he found it difficult to work, but the duration of the process does not seem to have been long and the wound healed completely. After the arm had been healed for a few weeks, the first outbreak upon the surface of the skin appeared in the form, apparently, of vesicles or bullæ with crusting upon the scalp. This condition of the scalp persisted, according to the man's account, limited to this region, for eight months, when lesions began to appear on other parts of the body, first the arms, then the legs.

The man was first seen in January, 1903. During this time he had never been wholly free from the eruption, although it would apparently clear up to a great extent at times, at others occupying large surfaces of the body. The eruption was of a purely vesicular and bullous character with, in some places, a mingling of a purulent element. When seen at this time it was specially marked on the forearms and wrists, particularly on the flexor aspect, and the lower legs and ankles. The genitals were not much affected at the time, but showed deep pigmentation from the effects of previous lesions. There were a few lesions on the scalp and at the

corners of the mouth, and the patient declared that the latter situation had been a frequent site.

The eruption at this time was of rather a small type, but he declared that at times there had been very large bullæ. The trunk was but slightly affected, although the back showed pigmentation, marking the seat of previous outbreaks. The front of the trunk had never been much affected. There was a slight rise of temperature, 100.4 degrees F., but the patient had increased in weight and had no other symptoms except those of discomfort from the eruption which had prevented him from working. There was moderate itching.

When shown to the society the eruption which had continued to appear constantly to a greater or lesser extent, was situated chiefly on the forearms, wrists, and hands, the upper part of the back, about the genitals and thighs and on the lower legs. It consisted of vesicles and bullæ, appearing upon a non-inflamed base with a marked tendency to form groups and clusters and in some places to become confluent. There were some lesions scattered over the scalp and a number of bullæ about the nose and mouth. On other parts of the body were large areas of erythema and pigmentation which marked the site of former lesions. The temperature was normal, general condition good and the increase in weight had been maintained. There were no lesions on the visible mucous membranes. There was a certain amount of itching, not however, excessive. The urine was normal.

There was found an excess of eosinophiles in the blood, nearly 17 per cent. There is a large excess of eosinophiles in the serum of the vesicles and *nucleated red blood globules* were also observed.

Dr. Howe was unwilling to liken this case to the series of post-vaccinal eruptions which he had described and read before the American Dermatological Association. In his cases the eruption had followed closely the injection of vaccine and the patients had either died or the outbreak had disappeared in a comparatively short time. Dr. Howe would rather compare the present example with Dr. Bowen's series observed in children where the lesions were localized around the groins, neck and shoulders.

Dr. McCollom differed from Dr. Howe and reminded him of two of the cases which had lasted one year and one and a half years respectively.

Dr. C. J. White considered the case to be a typical example of dermatitis herpetiformis. He had seen the man on several occasions and had observed him closely during the preceding summer. The outbreaks have been characterized by an herpetiform grouping of small bullæ accompanied by itching. There have been several exacerbations and as many remissions and despite the long-continued process the man has gained rather than lost weight.

Dr. Harding would not associate this case with Dr. Howe's series but would call it a good example of dermatitis herpetiformis. He had seen several cases occurring at indefinite periods after vaccination.

Dr. James C. White agreed with the last speakers.

Dr. Bowen said that he certainly should not class this case with those reported by Dr. Howe. What relation, if any, the vaccination had to the appearance of this eruption was problematical. In many respects this case resembled those that he had previously reported in children in which the vesicular and bullous element was the chief feature, and in which there was an especial localization on the backs of the hands, wrists, and ankles. The question is whether we are to call this case dermatitis herpetiformis or not. Certainly it has very little multiformity, being purely vesicular and bullous.

A Case of Callositas. Presented by Dr. Harding.

A man thirty-four years, a clerk by trade, shows upon the inner borders of the thumb, index and middle fingers of the right hand and upon the thumb and index finger of the left hand large oval or oblong-shaped tubercles, slightly raised above the surface, of the same color as the surrounding skin, firm and elastic in consistency, and smooth and rather glistening upon the surface.

These unusual-looking, flattened nodules lie over and to one side of the knuckles and have given rise to no subjective symptoms during the two years of their existence. Curiously enough the man can give no reason for their appearance and denies absolutely that his work or his play has been associated with friction over these affected surfaces.

The members were all agreed as to the diagnosis but were at a loss as to the ætiological factor in the case.

A Case of Syphilis. Presented by Dr. Bowen.

The patient is a Russian-Jewess, seven years of age, who shows over her body typical maculo-papular lesions of syphilis with universal adenitis, condylomatous lesions on the labia majora, involvement of the tonsils and pustular, crusting lesions through the scalp. The interest in the case, apart from the age of the patient, consists in a newly-formed, depressed scar in the scalp which, the mother and older sister affirm, arose from a previous sore which appeared some weeks before any of the other symptoms.

The mother asserts that it has been the custom of this young girl to use the combs of her older sisters and although these older girls present nothing which the mother has ever noticed upon their skin it seemed to the members of the society that the child had inoculated her scalp and produced a syphilitic chancre in her hair.

Dr. Post thought that the history of the primary sore in the scalp was consistent with the existence there of the initial lesion of syphilis but said that he would also consider the tonsils as a possible source of infection.

Dr. Harding felt after his experience during the last summer that

secondary eruptions of syphilis in children were not uncommon. He had recently treated five or six children between the ages of four and ten. In one case the initial lesion was on the vulva, in another on the penis but in the others the point of inoculation was obscure.

Dr. Bowen, in conclusion, said that the laryngologists had examined the tonsils carefully and had been unable to discover any evidences of a primary lesion upon them.

A Case of Syphilis. Presented by Dr. Post.

The interest in the case consisted in the type of the lesions, which Dr. Post considered quite unusual. At various points over the woman's body appeared large, flat, dull-red nodules with distinctly atrophied and sunken centers, while around these lesions were clustered—corymb-like—irregularly-shaped, flattened, large dull-red papules.

A Case of Lichen Planus. Presented by Dr. Harding.

The woman has been exhibited to the members of the society on previous occasions as a striking example of morphœa, but appeared at the present meeting to illustrate a marked type of the linear arrangement sometimes affected in lichen planus. Long bands of confluent papules appeared on the arms, legs, feet, and backs of hands; while the lesions, scattered sparingly over the trunk assumed a more ordinary distribution.

The woman claims that twenty-five years ago she consulted Dr. James C. White for an exactly similar eruption. Later on her morphœa developed and involved large areas of her trunk and extremities, but at present this condition is decidedly quiescent.

Alopecia Areata in Three Members of a Family. Reported by Dr. Bowen.

As this interesting group failed to appear at the meeting, Dr. Bowen reported their history.

A man of thirty, born in Massachusetts, of French descent, exhibits several typical patches of alopecia areata, one the size of the palm upon the occiput and several smaller lesions. The history is that when six years of age the hair suddenly fell "in a single night" according to the man's mother and there was total alopecia. Later the hair began to grow, but has never been completely reproduced.

The man's second child, a boy of seven, lost his hair when two years of age, the hair beginning to fall in patches until at the end of five or six months there was total alopecia which has persisted until the present time.

The oldest child, a girl of nine, began to be affected six months ago and now has large confluent areas of baldness over the whole scalp so that altogether one-half the scalp is denuded. This child is described as of a highly nervous temperament. The youngest child, a girl of five, is unaffected.

A Case of Dermatitis Venenata. Reported by Dr. McCollom.

In the contagious wards of the Boston City Hospital it is the custom to require all people visiting patients ill with diphtheria to wipe their face and hands with a towel moistened in corrosive sublimate, 1-5,000. A few weeks ago a woman performed this required duty and in five or six days returned to exhibit her hands and to claim that she had been poisoned. The fingers and hands were covered with vesicles and bullæ and were so swollen that her rings had to be cut off.

This is the first example of poisoning from this source that Dr. McCollom has observed, although this little ceremony has been performed hundreds and thousands of times under his directions.

CHARLES J. WHITE, *Secretary.*

BOSTON DERMATOLOGICAL SOCIETY.

November Meeting, 1903.

Dr. ABNER POST in the Chair.

A Case of Lichen Planus Annularis. Presented by Dr. C. J. White.

The patient was an American, æt. 40, a dentist by profession. Last April he says he noticed upon his abdomen several small, whitish papules. In the course of some weeks these papules grew red and began to spread peripherally forming circular lesions. Other small papular lesions appeared during the summer but did not undergo this process of peripheral extension and remain today typical papules of lichen planus. The progress of the disease has been associated with great pruritus which has yielded only to local applications of corrosive sublimate.

When first seen the man presented upon his abdomen a moderate number of irregularly-shaped, dull red, flat-topped, firm papules and scattered among these rather sparsely distributed lesions were seen five or six circles about one-half inch in diameter with raised, pinkish, continuous border and sunken, slightly scaling, pale-brown centers resembling somewhat in color and in furfuration the central portions of the circular lesions of pityriasis rosea. In the mouth were found the grouped, whitish, flattened papules met with so frequently in lichen planus.

Such were the conditions on September 16th, and the diagnosis was somewhat doubtful but the presence of the buccal lesions turned the scales in favor of lichen planus and away from syphilis which was the other alternative. The patient was given protoiodide of mercury internally and a wash and ointment externally. On October 2d, the man was seen again and reported that he could not tolerate the mercurial pills and was therefore given Fowler's solution. In the interim more lesions had appeared and the older papules had become umbilicated and had assumed a bluer

tint. On November 12th, he reported that his stomach could tolerate only three minims of arsenic three times daily and that the older lesions had remained stationary while new papules had made their appearance on the backs of the hands and on the thigh. Tonight, November 24th, the disease appears distinctly on the decline. The pruritus has subsided and the older lesions, including the rings, have all assumed a chocolate-brown hue. On the other hand, a few new, rather peculiar, spots have developed on the abdomen and appear as dull-red, oval, scaling lesions which present an appearance very foreign to lichen planus. Unfortunately, biopsy and photographs were refused.

Dr. HARDING considered the case one of lichen planus.

Dr. BOWEN agreed in the diagnosis and asked if the ringed lesions had grown from a single spot or had formed by the coalescence of several papules. Dr. Bowen then described an extraordinary case of lichen planus which he had been observing recently. The patient, a professional nurse, had had upon her legs for some eight or ten years hypertrophic lesions which, from time to time, had developed bullæ upon their surfaces. Arsenic, as an ætiological factor in the bullous formation, could be eliminated as the woman had taken but little of this drug.

Dr. JAMES C. WHITE, who had seen the present case at an early stage, said that the diagnosis was at first doubtful, perhaps, but he now had no hesitation in calling it lichen planus. He wondered how much arsenic the patient had taken and would like to know if the ingestion of this drug could have caused the present marked pigmentation.

Dr. C. J. WHITE was glad to have his diagnosis of lichen planus annularis confirmed. He had not had the opportunity of following the evolution of the ringed lesions, but from the man's story and from the general aspect of each circle he was reasonably sure that it had developed from a single papule. He could not feel that arsenic had caused the deep chocolate staining of the receding papules, for he had prescribed Fowler's solution for seven weeks only and the patient had taken really but nine minims *per diem* on account of intolerance. In addition, the pigmentation was limited solely to the points of disease and finally, none of the other signs of arsenical intoxication of the skin were present.

A Case of Syphilis, Papulo-Vesicular in Type. Presented by Dr. Post.

The man was an Italian (?) laborer, 40 years of age. He had been treated by Dr. Post in May, 1903, for an indurated sore on the penis which had been followed by a syphilitic roseola and general adenitis. Four to six weeks ago, despite continuous mercurial treatment, as the macular eruption was fading, the present peculiar outbreak began to appear. This consists of very small acuminate papules distinctly follicular and evincing a tendency to form in little groups of two to four lesions. Some of these papules present a minute vesicle at their summit

while others, when picked, exude a clear serum. The outbreak is most abundant about the waist line, front and back, while a few lesions appear on the extremities. On the forehead there are small, follicular, flattened papules.

Dr. McCollom considered the case remarkable but undoubtedly syphilitic. He knew of no drugs that could cause an exactly similar condition.

Dr. Harding and Dr. C. J. White agreed that the eruption was one of syphilis.

Dr. Bowen concurred in the diagnosis and said that the case approached most nearly the lichenoid type, although the groups were smaller than in the other examples he had seen. He said that the papules would be interesting from a histological point of view as sections of lichenoid syphilis were known to simulate tuberculosis more than did any other form of syphilis.

Dr. James C. White said that the groups in the present case were composed of too few elements to allow it to enter the class of lichenoid syphilis.

Dr. Post, in conclusion, considered that this type of papular syphilide was rare and especially so in men. He had never, perhaps, seen a truly vesicular or bullous syphilis.

An Unusual Case of Multiple Keloid. Presented by Dr. Bowen.

The patient was an Englishwoman 38 years of age. She was quite positive that none of her immediate forbears or her children had had any unusual condition of their skin. She has always been a large woman, and, although rather short in stature, weighed, up to a year ago, 240 pounds. Since then she has suffered from malaria and has decreased in weight about 50 pounds. In reply to questions, she stated that she had always grown much stouter during each of her pregnancies, but to her best knowledge she had never known any wound or injury, or even a mosquito-bite to precede the appearance of any of the keloidal growths.

The first tumor formed over her right shoulder-blade twenty-two years ago while she was carrying her first child and has remained unchanged ever since. With each successive pregnancy, but never in an interim, one or more keloids have developed uptil now there are about fifteen of these growths scattered over her body. They appear over the right and left scapulæ, on the right breast, several over the right back and three on her buttocks. They all show a peculiar tendency to elongate and incline to follow the cleavage lines of the skin.

The tumor over the right shoulder-blade assumes the form of an ordinary dumb-bell, while on the left side the growth appears as a sphere constricted in the middle as though a string had been tied about it. Lower down on the back, another and larger keloid appears simulating the shape of a dumb-bell with a long, thick, connecting handle. Others on the back

are small and manifest the same tendency toward dumb-bell formation or throw out flame-like tongues at one end like the grenades embroidered on the collars of the English Grenadier Guards. On the buttocks the growths are more like short, stout rods with several constrictions, while on the breast the most recent development appears as a round, fibrous nodule. Many of the tumors have flattened, puckered edges like the scars of severe burns, and at present they have all grown very sensitive to the touch and so troublesome that the woman has consulted a physician about them for the first time.

In addition to the keloidal growths the patient has over each ear, extending in front and behind, a broad band of total alopecia which suggests strongly the type that one sees in advanced cases of myxœdema. This loss of hair has occurred during the last year and the woman attributes it to her malaria. Unfortunately, the woman refused to allow a photograph to be taken.

Dr. James C. White said that the case was one of great interest and thought that the only explanation of the ætiology of the true keloidal growths lay in the recurring obesity of the woman with each pregnancy and the consequent stretching and final tearing of the corium. He spoke of the similarity of the buttock lesions to fibroma molluscum except for their hardness, and in conclusion described several cases of false keloid that he had seen following tatooing where the red pigment had caused a fibromatosis wherever introduced, while the blue color had caused no reaction whatever.

Dr. McCollom spoke of the many hypertrophic scars which he had observed lately following vaccination.

Dr. Bowen thought the case worth presenting on account of its occurrence in a white woman and because of the linear arrangement of the lesions.

A Case for Diagnosis. Presented by Dr. Bowen.

The patient was an Irishwoman, æt 29. Three weeks ago there appeared upon her waist a circular, scaling lesion with a slightly raised, rather sharply bounded periphery. At the end of ten days a general eruption appeared which led her to seek medical advice. At the time of her first visit the wrist lesion had quite the look of tinea circinata, but careful microscopical examination failed to reveal the presence of any spores. Now the trunk and upper arms are covered with a scaling and circinate eruption which resembles psoriasis but is not quite characteristic. No lesions appear below the knee and there are but few on the lower arms, while along the margin of scalp and forehead exist several waving, scaling areas. A good many small papular lesions appear which are not tipped with scales as in psoriasis. The case illustrates a class that one sees that are on the border line clinically between psoriasis and

pityriasis rosea, and also the class which Brocq describes as "parapsoriasis en gouttes."

Inquiry elicited the fact that the patient had suffered for six or seven years from eructations of gas, heart-burn, distress after the ingestion of corned-beef, turnips, cabbage, and many other similar articles of diet.

Dr. James C. White considered the case to be one of pityriasis rosea with an unusual degree of inflammation. He looked upon the wrist lesion as the mother spot and even without this guide he would rule out psoriasis as a possibility and would exclude parapsoriasis also on account of the degree of inflammation present. Dr. White thought that we must enlarge our conception of pityriasis rosea as there existed cases where the unusual degree of inflammation present often altered the usual picture.

Dr. Harding would not think of psoriasis but thought that the diagnosis lay between eczema seborrhoicum and pityriasis rosea.

Dr. C. J. White was surprised at the diagnosis of the previous speakers and thought the position and appearance of the original ring distinctly unlike the mother spot of pityriasis. In addition, there was no suggestion of that peculiar combination of *café-au-lait* and pink tints in the generalized eruption which he always associated in his mind with pityriasis rosea, and finally the scaling lesions on the forehead were quite contrary to his conception of this affection. In fact, he could not consider this disease as a probability. On the other hand, he looked upon the case as on the border line between eczema seborrhoicum and a parapsoriasis. He was rather strengthened in this view by the presence in the case of stomachic indigestion. He had been collecting data upon the concomitance of these symptoms in exactly similar cases during the last few years and had gathered together quite a large series of cases. The patients, as a rule, mentioned the same symptoms which suggested dilation of the stomach with derangement of the hydrochloric acid. Some of the cases had been examined by stomach experts who had usually reported hyperchloridria, but in a few instances the amount of hydrochloric acid had been found deficient in quantity.

Dr. Bowen, in conclusion, thought that the case was probably one of pityriasis rosea but he still wanted to express a reasonable doubt in favor of psoriasis or eczema seborrhoicum. He had watched the progress of the disease and each day seemed to bring it nearer to the classical appearances of pityriasis rosea.

Charles J. White, *Secretary.*

NEW YORK DERMATOLOGICAL SOCIETY.

318th Regular Meeting, November 24, 1903.

CHARLES T. DADE, M. D., President.

A Case of Dermatitis Herpetiformis. Presented by Dr. E. B. BRONSON.

The patient was a man of sixty years who three years ago first noticed some irritable spots on the inside of either ankle which were red and very itchy. A second attack occurred about a year later, spots of similar character appearing above the ankles, but with this there appeared blisters on the left leg. Since then there had been repeated attacks, occurring at intervals of several months, and affecting various parts of the body, more particularly the extremities. At one time, the hands were much inflamed, red and blistered, and a diagnosis was made of ivy poisoning, though the patient had not been out of town. At another time, his face was affected with redness and swelling, but the attack was severe enough to confine him to the house. Some time early in the spring of this year there was a very severe attack, with the formation of purplish spots, which were regarded as gangrenous, but were probably hemorrhagic lesions. These were preceded by small blisters. The itching was intense. There had been for years more or less pruritus during the night without any apparent eruption, and in the intervals of the more decided eruptive attacks. Examination of the urine showed it to be normal aside from the presence of a small quantity of albumin. At the time of presentation there was scarcely anything of the eruption to be seen, only roughened scaly places where lesions had been. Three days before there had been a bullous eruption on the legs, some of the blisters as large as the thumb nail, with little or no inflammatory area. The eruption had appeared a few days before, and the itching was severe.

Dr. CHARLES W. ALLEN said that there was not much to be observed at the present time, but the history was very interesting. He thought the affection more like dermatitis herpetiformis than anything else.

Dr. BRONSON said he was very sorry that there was so little to be seen this evening. The patient had been to a number of physicians, and it was curious what a number of diagnoses had been made. Personally, he looked upon the case as one of dermatitis herpetiformis, but it illustrated very well the protean nature of that disease, the lesions varying from simple erythema to something looking like gangrene. When seen by him previously the case was typical of that form of dermatitis herpetiformis which bordered on pemphigus, and the patient was evidently a fit subject for that kind of disease. The man had been a hard drinker, but though exhibiting evidences of some degenerative changes, was not suffering from serious organic disease.

Graphic Record of Skin Lesions.

Dr. H. G. Piffard said that he had found it very convenient to record skin lesions by placing thin, transparent sheets of celluloid, having a mat surface, upon the skin, and tracing the lesions upon the celluloid with a pencil.

X-Ray Apparatus and Treatment. Dr. H. G. Piffard spoke on this subject, exhibiting several new pieces of apparatus.

Dr. C. W. Allen said that he had had the pleasure of seeing in Paris the new Finsen-Reyn apparatus at work, and it was doing good service. The disadvantage of it was that only one patient could be treated at a time, if this were a disadvantage. He had seen three or four patients being treated at once with the other lamps at some of the hospitals, and the patients were, at times, managing the apparatus for themselves. In his opinion, a skillful attendant should do this, just as in X-ray work he believed a skillful operator should have his eye upon the apparatus and patient all the time.

The device for keeping the radiochromometer in front of the fluoroscope and so not expose the hands unduly, was very wise. It was surprising to see with what recklessness the younger operators developed an X-ray dermatitis, although it was well known that this form of dermatitis passed not only into epithelioma but also into a form of carcinoma which endangered both limb and life. He had taken every opportunity to warn against such unnecessary exposure of the operator. Last winter, in spite of ordinary care, wart-like lesions had formed around his own finger nails, and had caused him some anxiety. Carl Beck had devised and exhibited a plan for mounting the bones of the hand to pass in front of the screen instead of using one's own hand. Dr. Allen said he had been doing much the same thing himself, and had also attached the radiochromometer to the margin of the fluoroscope so that it hung down in front of the screen and practically accomplished the same purpose as the more ingenious and elegant device exhibited by Dr. Piffard. He was very much pleased with the diaphragm arrangement exhibited, and thought it very practical.

Dr. James C. Johnston said that he had seen a good deal of the results of X-ray work, and thought these lesions could be divided into three groups, viz.: (1) A "burn," which should never occur; (2) a condition closely approaching scleroderma, and apparently produced by repeated exposure, and (3) a precancerous condition, a cumulative effect, in which the epidermis became thin and scaly, and the changes in the cutis were practically those observed in senility. Here and there in such cases warty growths appeared, which were undoubtedly precancerous in their nature. Operation wounds in such cases should never be allowed to granulate. In the case which he had already reported there was now another lesion developing a little farther away. It was becoming distinctly epitheliomatous

with a pearly border, while the center was crumbling. He intended to excise this area and graft it as before.

Dr. E. B. Bronson said that Finsen and others had stated that a high amperage was of great importance in therapeutic work, that lamps of lower amperage than Finsen's were not capable of doing the same work. Finsen had also especially insisted upon the concentration of the light for which most of the lamps make no provision.

Dr. L. Duncan Bulkley said that he saw much of the Finsen light in Copenhagen a year ago, and brought back a complete apparatus of the newest type, but he had to confess that he had not used it because the treatment consumed too much time, and just as good results could be obtained more rapidly by means of the X-ray. It was, of course, desirable to measure the X-ray, but the experienced eye could gauge this fairly well.

Dr. Johnston said that in the Royal Infirmary of Edinburgh, they seemed to differentiate between the two apparatus, using the X-ray for the more intractable and deeper seated lesions, such as epithelioma and lupus, and the Finsen light for superficial ones, such as favus, sycosis, lupus erythematosus and hypertrophic rosacea.

Dr. George T. Elliot said that Dr. Allen had spoken strongly of the dangers to the operator from the X-ray, but he would ask him to speak also about the dangers to the patient.

Dr. Piffard remarked that the patient was exposed to the X-ray two or three times a week, while the operator was exposed half a dozen times a day.

Dr. Allen said that many of the patients treated were suffering from most serious diseases, and hence, one could take unusual chances because other therapeutic measures were not successful. Sufferers from malignant disease were not only relieved of their pain but of the horrors attending death from cancer. This could all be done without X-ray burns. He estimated that he had made eight thousand exposures, and out of that number had observed only one really bad burn. This was a case of cancer of the liver, and aside from the pain which the burn caused, it should not enter largely into the question because the object of the treatment was to save the patient from a greater evil.

Dr. Elliot replied that there were many slight cases of skin disease, *e.g.*, acne, which were treated by the X-ray. The treatment of these by the X-ray he did not think was warrantable. The use of this heroic agent in malignant disease was a very different matter.

Dr. Allen said that a vast experience showed that these mild affections could be exposed without the slightest danger.

Dr. Piffard said he thought that the severe burns to which the patient was liable were rarely caused except by carelessness. Probably in most cases a slight amount of burning was necessary. He agreed, however, with Dr. Elliot that the X-ray was being used constantly in many

cases in which it should not have been, and where it was little short of criminal to use it.

Dr. S. Sherwell said that he was of the opinion that there were hardly two human beings in whom the same reaction would be observed from a given application; in short, there were decided individual differences in vulnerability. He had seen several cases of erythematous lupus which had been exposed to the X-ray by an expert, but without the slightest improvement.

Dr. Piffard said that a patient who recently consulted him, said that she had received 110 exposures to the X-ray without any apparent benefit in her condition, which was supposed to be cancer. He put her upon mixed treatment, and she improved rapidly.

Dr. A. D. Mewborn referred to the troublesome method of cooling the Finsen apparatus by means of the circulating current of cold water, and mentioned the method devised by Surgeon W. F. Arnold, U. S. N., in concentrating by means of a funnel-like hood and tube the current of air from an electric fan, which undoubtedly succeeded in blowing away the heat rays. In the summer of 1900, Dr. Arnold described, in a personal communication, how, by using the current of air from a powerful electric fan directed upon the focal point of light from a 10,000 candle power search-light, he had succeeded in rendering a culture tube of gelatine *incandescent* without liquefying its contents, and that without this current of air enough heat was generated to melt zinc.

Dr. Bulkley spoke of two cases in which the X-ray had been used on patients suffering from hyperidrosis, the latter being held in check for a day or two only.

Dr. Allen said that the X-ray would not only take out the hair, but would also make the hair grow. He preferred to use electrolysis by means of the needle in most cases for the removal of hair, because it was much more under control. He had recently been treating an old gentleman of nearly eighty for another purpose by application of the X-ray to the top of his bald head. The hair grew out nearly half an inch, strong and wiry. In another case he had treated a gentleman for cancer of the lip, and during the treatment the hair of the beard on the side exposed to the X-ray fell out, but subsequently grew in so much more luxuriantly than on the other side that it had to be trimmed and thinned out to make the two sides appear symmetrical.

Dr. Bronson said that he had made very similar observations to those mentioned by the last speaker. After temporary alopecia had been caused by the X-ray he had seen the hair return much thicker than on the other side. He had also noticed that after having given half a dozen exposures in a case of hirsuties, and then changing to electrolysis, that the side first treated by the X-ray was much more stubborn under electrolysis. He also recalled a case of inveterate alopecia areata in which

the X-ray had brought out a new growth of hair. It was not necessary to go farther than the stimulating effect of the X-ray to secure this increased growth.

Dr. Piffard said that the fact that the X-ray would stimulate the growth of the hair was a matter of record. An acne could be removed from a girl's face by means of the X-ray, but in doing so one might produce a growth of hair.

Dr. Elliot said he had a case of general alopecia areata that had been treated on a portion of the occiput by the X-ray. The hair was growing everywhere except on the area that had been thus treated.

MISCELLANY.

A Ward for Cutaneous Diseases at the Massachusetts General Hospital, Boston.

Through the generosity of a friend of dermatology, a ward for the treatment of skin diseases has been added to the Massachusetts General Hospital. It is a detached pavilion of brick, of one story, with a spacious roof garden. Sixteen beds are available in separate rooms, one-half of the ward being for males and one-half for females, the two sections separated by a broad central space. The ward is thoroughly equipped for the treatment of cutaneous diseases, especial attention having been given to the installation of baths, etc. The ward is under the direct control of the department of dermatology of the Harvard Medical School, and has already added much to the facilities for teaching. It is to be hoped that this example will be followed by other institutions, as too little provision has been made in America hitherto, for those disabled by skin affections.

REVIEW
of
DERMATOLOGY AND SYPHILIS

Under the Charge of JOHN T. BOWEN, M. D.

BACTERIOLOGY AND PARASITOLOGY

By A. D. Mewborn, M. D., New York

Actinomyces, Paronychia of the Finger Caused by. THEVENOT, *La Presse Med.*, 1903, LXXVII, p. 659.

Actinomyces, Morphological and Reactional Characters of the Fungus in the Tissues. L. DOR. *La Presse Med.*, 1903, LXXVII, p. 654.

Thevenot shows the difficulty of a clinical diagnosis in the case reported in the service of Prof. Poncet, of Lyon, on account of the variety of forms under which it may manifest itself. In this case in which a carpenter of sixty-six years pricked his finger with a splinter of wood, the disease did not manifest itself until fifteen days later and developed into a very nodular type of paronychia. It is not necessary to enter into further details of the case.

The ray fungus may enter the skin with a foreign body and remain comparatively superficial, causing a greater or less destruction of tissue which may simulate an epithelioma, a specific ulceration or a local tuberculosis. Poncet and Bérard have reported several cases among threshers of wheat which resembled lupus. At other times the fungus may develop in the subcutaneous connective tissue as an immediate suppuration or it may remain encysted for a long period as in the case reported by Müller, where a woman was wounded by a piece of wood in the finger and after a swelling which lasted for two weeks, considered herself well except for a pea-sized tumor. Two years later she was injured at the site of the tumor and there developed a large abscess from which were evacuated numerous actinomycosic yellowish green masses. Evoluting more profoundly, it may be necessary to excise a portion of the muscle (Leser and Martin), or to amputate the leg as in the case reported by Tusini. The case of Tusini was remarkable for the long period of latency of the disease. The patient was inoculated in the left leg at the age of ten years. Fourteen years later the hard nodule took on an active growth until the leg was covered with forty-three ulcerations simulating a tibio-tarsal tuberculosis, necessitating removal of leg.

Dor gives a very simple method of making a diagnosis. In an ordinary test tube as much of the pus as possible is collected. In a second tube, by expression or curettage, the fungous products and sanguinolent

fluid are allowed, by inclining the tube, to come in contact with as much of the inner surface as possible. The same process must be gone through with the first tube, although it is not so apt to be successful as with the second. When the fibrin has coagulated, the small grains, which are clearly discernible as nodular elevations, may be picked off with a platinum rod and carried to the slide, on which has been placed a drop of picro-carmine solution. This is allowed to act for a minute and a cover glass is gently applied. If the ray clusters are present they will be stained an orange yellow or bright yellow in sharp contrast to the carmine staining of cells and their nuclei. The endothelial pearls found by Rouffiandis in a special form of suppurative endothelioma and called by him *"dermite perlée,"* might lead to confusion which a staining by a Gram would easily clear up in revealing in the ray rosettes the dichotomized filaments in the form of "Y." In the disease of the horse called botryomycosis, and rarely in human botryomycosis, similar granules are present but have nothing in their microscopical appearance that might lead to mistaking them for actinomyces. Dor enters into a consideration of the botanic classification of actinomyces and considers that, in spite of the researches of Nocard on *"farcin du bœuf"* and the work of Sauvageau and Radais (1892) in establishing the fact that the term streptothricæ should not be applied to the ray fungus, but that it belonged to the oospora, our opinion should all be revised, since Von Niessen whose results were confirmed by Neukirch (1902) has succeeded in growing on glucosed and maltosed media a parasite having all the characteristics of the clubbed forms seen in the living tissues. Von Niessen considers that actinomyces belongs to the *cladosporium* and not to the oospora. Dor offers two hypotheses to reconcile this divergence of opinions, first that actinomyces is a fungus with two types of vegetation—mycelium and "clubs," and the second is to regard actinomyces as a *lichen,* i. e., the association of two entirely different parasites, one being a fungus (champignon) and the other an *alga.*

Actinomycosis, Cutaneous, of the Finger. A. Sicard. *La Presse Med.,* 1903, LXV, p. 581.

The great rarity of actinomycosis affecting the hand is shown by the statistics of Poncet and Bérard, who found only two cases of the extremities affected out of 67 cases; the face and neck being affected in 54 cases; the thorax and lung in eight cases; the intestines and abdomen in three cases. Illich, in a report embracing 421 cases, only found 11 in which the skin alone was affected. The case reported by the author has the additional interest of being clearly traceable to an infection by the fungus while leading a saprophytic existence on wheat. The case was that of a peasant woman, who, while tying a sheaf of wheat, cut the left index finger at the metacarpo-phalangeal fold with a sharp head of wheat. The wound healed in a few days; when, eight days later, the

patient noticed some œdema and a dull pain in the finger. A few vesicles appeared on the inflamed surface, but there was no lymphangitis or adenopathy. Several abscesses formed which were opened by a physician but persistent, unhealthy looking ulcerations and sinuses caused the patient to seek the author's advice. An examination of the yellow granules showed the typical ray-fungus. An X-ray photograph showed an osteitis and a periosteitis with a small sequestrum. The internal use of large doses of iodide of potash soon brought about recovery.

Favus sine Scutularis. Rudolph Walch. *Dermat. Zeitsch.*, 1903, X, p. 330.

In this abstract, taken from the author's thesis for Doctor of Medicine, the rather interesting case is described of a man aged 27 years who had suffered from favus since childhood. The disease commenced on the shin as a patch the size of a quarter of a dollar. The disease spread over the body. At the time of examination the skin of the face was reddened, scaly, and atrophic. On the neck there was the same condition with scattered and confluent reddened infiltrations extending up into the scalp. On the scalp the hair was thin, poorly pigmented and dusty looking. On the occiput there were atrophic spots devoid of hair follicles on which were great loose scales. The occipital lymph glands were indurated and the size of pigeon eggs. On the upper part of the chest there were flat patches similar to eczema seborrhoicum, with sinuous borders. There were a few yellowish red papules and brownish red scaly patches. The same picture was present on the upper part of the back. There were rounded spots on the arms, forearms, (where there was strongly inflammatory redness) on the palms and backs of hands. The fingernails were raised by enormous masses of horny substance and there were cloudy streaks in the nails. The roots of the nails were free from changes. Nowhere were there any favus cups and yet microscopically and culturally the favus fungus was found. The author states that the fungus was atypical and that it was not possible clinically to have determined the nature of the dermatosis.

Glossitis and Stomatitis Caused by a Streptococcus. Cases Observed at Madagascar. Fonoynont and Jourdran. *La Presse Medicate*, 1903, LXIV, p. 653.

Reports of tropical cutaneous affections have an interest much greater than the natural curiosity which every dermatologist takes in the description of rare exotic affections and that is the question of climatic accentuation in virulency of well known microörganisms. These two observers, attached to the indigenous hospital at Tananarive, have here presented an unusual exfoliative affection of the tongue and mucous membrane of the mouth due to a streptococcus in long chains. Slides prepared

from tongue scrapings and cultures in bouillon have always revealed the same streptococcus which has been verified by Thiroux, director of the local Pasteur Institute, as the pathogenic agent. The affection has only been observed at Madagascar where it is endemic and at times epidemic and, while mostly confined to the natives, the Europeans are not immune to it. The attack usually commences with a feeling of general malaise, slight fever, some constriction in the throat, enlargement of submaxillary glands and a burning or prickling sensation in the tongue. In a day or two a small exfoliation of the mucous membrane of the tongue occurs, spreading peripherally and joining other patches to form polycyclic, shiny or "varnished" areas with a slightly elevated whitish border. The unaffected parts of the tongue accumulate a thick coating which gives a striking contrast. The entire tongue may become denuded and resemble the varnished tongue of scarlatina. On the mucous membrane of the cheeks the patches may somewhat resemble mucous patches and might be mistaken for syphilis, but on the tongue the appearance is unique.

The affection seems to present no serious complications and heals in the course of a couple of weeks under local applications of permanganate of potash. Chlorate of potash has no beneficial effect.

The condition known as "wandering rash" or *exfoliatio areata linguæ* or *"glossite exfoliatrice marginée"* (Fournier) certainly resembles in some respects the disease just described, especially in the slightly elevated, whitish borders, but it of course differs greatly in being much more chronic and not accompanied by fever or glandular enlargement.

Pellagra, The Localization of Aspergillus Spores in the Mesenteric Glands of. Ceni, *Centralblatt f. All. Path. u. Path. Anat.*, 1903, XIV, p. 465.

The author adds to the 28 cases of fatal pellagra, in 21 of which he found pure cultures of the *aspergillus fumigatus* and *aspergillus flavescens*, the report of a fulminant case of pellagra typhus in a woman aged 45 years who came into hospital with profound nervous symptoms—mental confusion, exaggerated tendon reflexes, etc., which in three days developed into muscular rigidity and twitching, tongue-tremor and a temperature of 39 C. Death occurred on the eighth day. Nearly 100 tubes of Raulin's liquid were inoculated with pieces of the different organs. The tubes inoculated with bits of the mesenteric glands showed, on the sixth to seventh day, abundant growths of a hyphomycete which further experiments showed to be *aspergillus fumigatus*. The author considers that the poor vitality of the *aspergillus* in artificial cultures is not evidence of its diminished toxicity but is due to the restraining influence of the intestinal secretions. He considers that the aspergillus spores may entirely lose their capacity for growth in cultures without thereby losing their toxicity and that this fact explains the failure in many cases to recover in

cultures the pathogenic organism. He promises further contributions on this interesting disease.

Parasitic Scalp Diseases. Sublamine in the Treatment of. W. S. Gottheil. *Med. News,* 1903, Oct. 17, p. 735.

In an epidemic of ringworm at one of the New York Orphan Asylums where some 450 out of 900 children were affected, the author found that sublamine and the fluid citrate of ethylendiamin were of great value. A solution of 1-1,000, and in some obstinate cases 1-750 was much less irritant than bichloride solutions and followed by much less inflammatory reaction. Cures were obtained much quicker than with any other preparations used. Another interesting fact observed was that in an institution where an epidemic of trichophytosis prevails, a parasite indistinguishable from that of ringworm could be cultivated from the scalps of individuals which were apparently healthy. He is of the opinion that in such cases all the inmates' heads must be regarded as infected and a careful examination must be made of every head twice a week.

Ulcus molle (Chancroid) Bacillus, Pure Culture of. Fischer. *Derm. Zeitsch.*, 1903, X, p. 481.

In a critical review of our knowledge concerning Ducrey's bacillus, the author considers, that while Istomanoff and Akspianz (1897) perhaps were the first to obtain cultures in a medium made by adding macerated human skin (previously dried and powdered) to agar and from these cultures by inoculation on human subjects obtained typical chancroids, yet Langlet deserves precedence. Langlet used a medium containing human skin which had been digested with pepsin and, from these pure cultures, he produced typical soft chancres in the human subject from which the same bacillus could be again obtained in pure culture. Bezançon, Griffon and Le Sourd simplified the technique in using a mixture of rabbit's blood and bouillon-pepton-agar. The author follows the method recommended by Langlet to obtain a "uniseptic" ulcer by vaccination from the suspected lesion on the patient's abdomen. This transplanted lesion is protected by an aseptic dressing and, to get rid of the almost constantly present Zeissl's pseudo-diphtheria bacillus, the new lesion which develops in a couple of days is painted with tincture of iodine. This is again covered with an aseptic dressing for two days and then the bottom of the ulcer is scraped and examined microscopically for the Ducrey bacillus which, if found in abundance and fairly pure, is inoculated into his media which is prepared in the following manner:—

Rabbit's blood is drawn directly from the ventricle into a sterile syringe with all the necessary antiseptic precautions. This blood is partly distributed in sterile tubes and a part is mixed with liquefied and cooled pepton-bouillon-agar, well shaken and allowed to solidify in slants.

The blood-pepton-bouillon-agar forms a shiny, red medium which is allowed to stand 48 hours to see if it remains sterile and can be used up to two weeks, at which time growths cannot be obtained. The suspected pus from the inoculated ulcer is richly smeared on the surface and the condensation water is allowed to moisten the surface. In two days the cultures are visible as round, shiny, elevated colonies which are very adherent to the media and in transplanting must be taken up with the adherent agar. As the bacillus becomes accustomed to the media the growth is more rapid. "Klatsch" preparations of young colonies show slender bacilli in parallel chains which resemble the arrangement of hair on the human head when looked at from above. Polymorphic changes begin in 24 hours and then numerous "dumb-bell" diplococcus and point-ended forms may be seen. The bacilli lose their vitality on solid media in from 8 to 10 days, in the condensation water virulency is longer maintained. The author considers the ordinary laboratory animals as immune to inoculation. By autoinoculation on the left forearm the author succeeded in producing a typical chancroid from a culture in the condensation water of the 15th generation (one and a half months old). In two days there developed a "punched-out" ulcer surrounded by an intensely brown-red zone, the size of a "mark." This result was demonstrated before the Berlin Dermatological Society. Ducrey bacilli were obtained from smears and in cultures in rabbit's blood. In a foot note the author refers to the very interesting experiments of Himmel, who succeeded in depriving guinea-pigs of their immunity to the chancroid bacillus by previously injecting into the abdominal cavity a few cubic centimeters of a watery solution of lactic acid or of an anticomplement (antialexin). A subsequent injection of a culture of the chancroid bacilli in such prepared animals quickly caused death and from the blood of such animals pure cultures were obtained. By several passages of the bacilli in this manner through guinea-pigs the virulency was so augmented that an unvaccinated guinea-pig would die in 12-20 hours after an injection of bacilli. Nicolle and Tomasczewski have succeeded in producing typical soft chancres in monkeys.

DISEASES OF THE HAIR AND NAILS.

By H. G. Anthony, M.D., Chicago.

Periodical Shedding of the Hair. H. Ledermann. *Berl. Klin. Wochensch.*, 1903, page 332.

A girl, twenty-two years old, shed her hair every winter, in summer it would grow again. Last winter she became entirely bald and this summer her hair did not grow as usual in spite of treatment.

Severe alopecia is present on the body, this began as circular patches when she was twelve years old.

Monilethrix. H. Ledermann. *Berl. Klin. Wochensch.*, 1903, *page 332.*

The author presented three cases of monilethrix. The first was a boy ten years old, whose hair was thin, lusterless and quite short, except in the temporal region. Many of the hairs were broken off close to their point of exit from the follicles. In places the follicles were atrophic, and surrounded by scaly papules as in keratosis pilaris. At the back of the neck the broken-off hairs presented the appearance of comedones.

The disease began in the first months of life following a shedding of the first hair which was normal in appearance.

Microscopically, the hair stumps show a spindleform. The second case was the mother of this boy, who was forty-two years old, and had had the disease since childhood. It developed after an eruption on the scalp. She wears a wig to cover the thin short hair.

Examined microscopically, the characteristic spindleform hairs are present and there are also present hairs which are twisted and some which are bent close to the scalp; they contain an undue amount of pigment and air chambers.

The third case was a woman twenty-six years old and not related to the other cases. The hairs were dry and brittle and they showed alternating spindles and air spaces and contractures. The scalp is covered with stumps of hair.

Keratosis pilaris of the scalp is present. Universal keratosis pilaris has been observed in some cases. These cases are important because they illustrate the correctness of the statement made by Brocq (Pratique Dermatologique Vol. 1—Page 362) that monilethrix is closely related to keratosis pilaris.

Lesions of the Finger Nails in Lichen Planus. Du Castel and Druelle. *Ann. de Derm. et Syph.*, 1903, page 578.

Mention is rarely made in the reports of cases of lichen planus of any affection of the nails being present and in no case was there so perfect a production of the lichen papule as in this case; in previous cases the nails are described as thickened.

The papules of the nails had not been noticed by the patient, there was no itching and the fingers were free from lesions. All finger nails were equally affected. In general, the lesions present were elevations which conveyed the impression that they were papules having a greater measurement from above downward than in a transverse direction.

They have a linear arrangement extending from the luna towards the free border of the nail, some showing a central depression.

In places the papules were set so closely as to form ridges of a uniform elevation throughout. This was the exception. As a rule the ridges had depressions now and then which corresponded to the joining of two papules.

Many of the ridges extended to the free border of the nail but some were incomplete; isolated papules were observed occasionally. There was no perionychia or subungual disease. The color, growth, and free border of the nails were normal. The nails of the feet were thickened and irregularly deformed.

Report of Cases of Nail Disease. F. Bering. *Münch. Med. Wochensch.*, 1903-1777.

Bering reports the three following cases observed at Duering's clinic in Kiel:

Koilonychia: A woman twenty-one years old, very anæmic, has noticed that her finger nails were abnormally smooth for several years past. At the present time they are rough and in places scaly, thin and of a grey color. There is a saucer-shaped depression in the center of each nail without detachment from the matrix. On the border of the depression there is lamellous exfoliation of the nail. Treatment by application of carmine for cosmetic effect and compression with strips of adhesive plaster produced a marked improvement.

Papilloma subungula: A woman twenty-seven years old, in perfect health, noticed the disease of the nails two years ago. The only assignable cause is the fact that she has her hands constantly in water. The nails have a dirty grey color and are detached from the matrix. On removing a sufficient part of the loosened nail to permit examination of the matrix, it was found to be studded with little warts which were destroyed by electrolysis.

Hyperkeratosis subungualis: Masses of imperfectly formed hyperkeratotic tissue grew from the bed of the nail pushing it upward and gradually appearing at the free border.

Onychoschisis Symmetrica. Oscar Ehrman. *Monatsh. f. Derm*, 1902, Vol. XXXIV, No. 2.

The author reports a case of symmetrical splitting of the nail into plates. The patient was a man thirty-five years old, the disease affected the index fingers only, and had existed one year. About two-thirds of each nail showed a split in the surface extending from the free border towards the lunula, and dividing the nails into two plates.

The surfaces of the nails are rough and marked by pores, depressions, and white streaks. The splits occur spontaneously; when the nails grow long the splits increase. Continual trimming of the nails has produced such a marked improvement that complete recovery is expected in a few months.

Pityriasis Versicolor of the Nails. Campana. *Clinica Derm. della Universite de Roma*, 1903, page 13.

This is the report of a case in which pityriasis versicolor affected the

fingers. For a long time previous to the appearance of the disease on the fingers, the finger nails had been thickened. Microscopical examination of finger nail clippings revealed the presence of mycelia and conidia of the microsporon furfur.

ATROPHIES.

By H. Goldenberg, M.D., New York.

Kraurosis Vulvæ and Ulcus Rodens. Oscar Kreis. *Correspondenzblatt für Schweizer Aerzte,* 1902, page 11.

Patient 42 years old, married 7 years, has had 4 normal confinements with tears of the perineum. For years she had been suffering with intense pruritus vulvæ. Four years ago ago extirpation of a small wart of the left labium majus. For the last 18 months new warty growth near the clitoris, increasing in size and causing considerable pain, shortly afterwards excoriations and increased pruritus.

When the patient came under observation the author found the external genitals very much atrophied, total absence of clitoris; introitus vaginæ very narrow, of a whitish color, rough, hard and covered with excoriations. In the left inguinal region a hard gland, the size of an almond could be felt; the right side was normal. Thorough removal of the affected parts into the healthy tissue. The microscopical examination shows hyperplasia of the skin, mainly of the rete Malpighi, absence of sebaceous glands and of sweat glands, typical cancroid cells near the base of the ulceration. Kreis believes that the atrophy is preceded by a hypertrophy and hyperplasia, and that kraurosis vulvæ is an inflammatory process, probably caused by the pruritus. His patient had applied to the ulceration strong astringent solutions of alum, which may have changed an originally benign ulceration into a malignant one. The interesting point is the early metastasis. The inguinal gland looked very much like carcinoma—which anatomically was found at a time when the clinical diagnosis was negative. He concludes by laying stress on an early radical operation into the healthy tissue and on an extirpation of the inguinal glands, even when they are not found to be enlarged.

Atrophic and Scar-like White Spots of the Skin of the Trunk. W. M. Iwanow. *Archiv. f. Derm. u. Syph,* LXIV, 1903, page 369.

In a large number of adults, more frequently in men than in women, suffering from acne, sharply circumscribed, perfectly white spots are found, especially upon the back and chest. According to the author, who has made histological studies of four cases in Jadassohn's clinic, these spots have been confounded with the ordinary scars following acne, from which they differ clinically and histologically. The principal clinical dif-

ference is their location on chest and back, while they are rarely encountered on the main site of acne—the face. They are not scars, in the proper sense of the word, since there is no destruction of sebaceous follicles or sweat glands. The anatomical changes are localized in the corium and consist of a chronic inflammatory infiltration around the follicles with a total absence or with a considerable diminution of the elastic tissue. In three cases giant cells were found. The author mentions another case of Jadassohn, previously reported, where the white spots were accompanied by numerous keloids. The latter are probably due to a disposition of the individual to the formation of keloids or to an insufficient regeneration of the elastic tissue.

The Varieties of Lineæ Albicantes. W. Osler. *Med. News,* Nov. 7, 1903.

Osler distinguishes three groups of the lineæ atrophicæ: firstly, those due to the distention of skin (pregnancy, ascites, etc.); secondly, the postfebrile cases, especially after typhoid and scarlet fever; thirdly, an idiopathic form.

Referring to Northrup's article, the author claims that, while in the postfebrile cases the scars may be due to the rapid growth of young persons who have to remain through illness in bed for a long time, the fact that they occur likewise in adults, indicates that Comby's explanation is not absolutely conclusive. Amongst other cases Osler cites one of an adult who after an attack of typhoid fever developed four or five transverse scars in the sacral region.

Skin Lesions Associated with Rapid Growth of Long Bones. Lineæ Albicantes. (*Les Vergetures de Croissance.* Jules Comby.) W. P. Northrup, *Med. News,* Oct. 31, 1903.

The case of "scars-across-the-knee" similar to those on the abdomen of the parturient woman, occurred in a male patient who at the age of 17 years grew perceptibly in height, after a severe attack of typhoid fever. The scars when first seen were pinkish, like wheals or welts made by a switch.

As to the explanation of this cutaneous phenomenon, the author refers to Comby, who claims that a remarkable growth in height takes place in children who, in acute or chronic illness of long duration, are condemned to a horizontal rest. The elongation of the long bones—these welts ("vergetures") are generally observed in the femero-tibial region—is so rapid in these cases that the development of the skin cannot keep pace with it.

BOOK REVIEW.

The Internal Secretions and the Principles of Medicine. Vol. I.

By Charles E. De M. Sajous. F. A. Davis and Co., 1903.

The author of this book is thoroughly convinced not only that normal life processes are dependent on adrenal activity, but also that pathological manifestations are caused by the increase or decrease of adrenal function. Thus the muscle weakness or over-activity due to opium, cutting the nerves in animals and man, oxalic acid poisoning, phosphorus poisoning, physostigma, calabar bean, santonin, strychnin, and to a great variety of other agents is attributed to adrenal depression or stimulation. But we know that oxalic acid produces muscular weakness through withdrawal of calcium, and the clinical picture of phosphorus poisoning with its high proteid metabolism and simultaneous retention of large quantities of lactic acid, does not require a reduced adrenal activity to explain it. Strychnin, Sajous' adrenal stimulant *par excellence,* will not act in the frog if his skin be anesthetized with cocaine, or his sensory nerve roots cut, or if his cord be extirpated. Referring to the source of muscular energy, the author makes the somewhat astonishing statement that glycogen is the main constituent of myosinogen with which the oxygen of the blood combines. Again the metabolism in diabetes is alleged to decrease on account of adrenal insufficiency, whereas in reality there is no decrease in the total metabolism of the diabetic as compared with the normal man of similar build. Another statement is that the heart beat is caused by adrenal secretion, whose oxidizing agent acts in the heart upon β granules brought from the liver. This does not harmonize with the fact that Locke could keep an extirpated rabbit's heart beating for twelve hours when it was supplied with the proper solution of sodium, potassium and calcium salts containing one-tenth of one per cent. of dextrose and compressed oxygen, nor is it to be reconciled with the resuscitation of the human heart through a similar solution after it had been kept on ice in normal saline for even thirty hours subsequent to death (Kuliabko). The book also attributes the action of antipyretics to influence on the adrenals, but Sandowsky has shown that no fall in temperature will occur if the basal ganglia of the brain have been cut off from the cord. This volume brings a great mass of literature under review, and attempts to make it conform to a belief of its author's mind.

Graham Lusk.

THE JOURNAL OF
CUTANEOUS DISEASES
INCLUDING SYPHILIS

VOL. XXII. FEBRUARY, 1904. No. 2

A TUBEROUS IODIDE OF POTASH ERUPTION SIMULATING HISTOLOGICALLY AN EPITHELIOMA.

BY DOUGLASS W. MONTGOMERY, M. D.,

Professor of Diseases of the Skin, University of California.

Patient demonstrated before the California Academy of Medicine, Feb. 23, 1903.

ONE of the chief points of interest in the present case is the infiltrative character of the hyper- and parakeratosis found in the microscopical examination of one of the iodide tumors. This infiltration resembled so strikingly epitheliomatous infiltration, as can be seen in the photograph, that the danger of mistaking one for the other is apparent. On looking back over my own experience I believe I made this mistake once myself, and my only consolation is that in operating on the lesion as an epithelioma, my fee was a great deal larger than if a correct diagnosis had been made.

Few writers have given any attention to the histological diagnosis between epithelioma and the tumors of tuberous iodide dermatitis, and usually, I suppose, there is no resemblance between the two. Tuberous iodide dermatitis is designated by Ehrmann as an inflammatory granulation tumor with hyperkeratosis and parakeratosis, and probably its usual histological appearance is such as depicted by him[1], but the hyperplasia of the epithelial cells may assume much greater proportions, and may dip down into the connective tissue growth of the lesion in the most bizarre way, causing a picture resembling epithelioma such as Norman Walker has shown, and such as we have in the case under consideration.

On January 20, 1903, through the courtesy of Dr. L. W. Allen, I was called to see a man, fifty-two years of age, who was suffering from a tuberous iodide of potash eruption.

The patient said he had always enjoyed good health with the

exception of an attack of muscular rheumatism three years before. Fifteen years ago he had a sore on the penis that was shortly afterwards followed by a universal, scaly rash. He had then received a short anti-luetic treatment. Some time afterwards an ulcer developed on the outer side of the right upper arm, which improved under a patent medicine supposed to contain iodide of potash. Shortly afterwards the sore broke out again, but lower down upon the arm. He then changed to another patent medicine which he thought gave better results, but nevertheless the ulcers, with intervals of quiet, continued to break out down along the forearm until recently one developed on the back of the right hand.

About the beginning of December, 1902, the right hand was in a fair condition, there being a sore about one and a half inches in diameter on its posterior surface. There were no other sores present on the body. About this time he slightly abraded the back of the left hand while trimming scale-infected fruit trees. This abrasion suppurated and began to grow rapidly, so as soon to involve the whole posterior surface of the hand. Then the sore on the back of the right hand became worse, spreading to the back of the fingers. About two weeks later sores appeared on the forehead and vertex, and during all of this time he was taking his favorite patent medicine.

On January 3, he began, under the care of a physician, to take iodide of potash under its proper name, beginning with ten drops of a saturated solution three times a day, and gradually increasing up to fifty-five drops, but the sores kept growing worse, and more were appearing. He had also some rise of temperature, (the highest observed was 101 degrees F.) some acceleration of pulse, (the highest observed was 110) and some increase in rate of respiration, (the highest noted was 24).[2] About this time it was also found that the urinary secretion was not normal. There were wide variations in the quantity of urine voided on different days, and at times large numbers of hyaline casts were present. One day he passed only 840 c. c. of urine having a specific gravity of 1,021, and another day he was credited with passing 1,900 c. c. It was in the urine of the day on which only 840 c. c. was passed that the hyaline casts were found. At no time was either albumen or sugar found in the urine.

When I first saw the patient on Jan. 20, 1903, the eruption was scattered over the scalp, face, arms, hands, trunk, thighs and legs;—the palms and feet being free. One of the most characteristic lesions was on the forehead over the left eyebrow. It was a soft, rounded tumor about the diameter of a quarter of a dollar, and was seated on

the skin by a constricted but broad base. From this constricted base the tumor flared outwards and upwards, smooth, rounded and purple to the top, which was covered with a thick, brown crust. Under this crust the top of the tumor was rotten, uneven, purulent, and bled easily. A triangular piece was removed from the tumor for microscopical examination. This piece of tissue took in the full depth of the tumor down to the level of the skin, and its removal did not seem to cause much pain. The examination of this piece of tissue will be discussed later on. Some of the lesions were more papillary than this one, and had less of the rounded tumor-like base. One lesion on the back was a crescentic ulcer with deep brown pigmentation, and resembled a circinate, tertiary syphilide. Another lesion on the back of the right hand was circinate and papillary, was advancing at the periphery and healing in the center with a smooth scar, and also looked like a tertiary syphilide. There were, scattered over the body and limbs, a great number of white scars that looked like those following tertiary syphilides.

In regard to diagnosis; tuberous masses, as seen in this patient, are found as a result of taking iodide of potash, in mycosis fungoides, and also in dermatitis coccidioides. Dermatitis coccidioides is a disease peculiar to California, and coccidia-like capsulated bodies are found in its lesions. In the examination of the piece of tissue removed from the forehead no such organisms were found, so that that disease was excluded. The disease was not considered to be mycosis fungoides because of the absence of the eczematous, indurated, itchy lesions, characteristic of that affection. It was therefore concluded that the eruption was caused by the iodide of potash, and the drug was stopped. Subsequent events showed this view to be correct, for the lesions subsided and the patient recovered. In neither mycosis fungoides nor dermatitis coccidioides would this have happened, as they are both fatal maladies.

An important question then came to the front; had the patient ever had syphilis, and were any of the lesions on the skin syphilitic? It will be remembered that some of the lesions, namely those on the back of the hands, and one on the back resembled syphilides. Although these lesions extended by an elevated advancing margin, and cleared up in the center, leaving a scar such as late syphilides do, yet iodide of potash eruptions can act in this way too. In fact, from the rapid healing without anti-syphilitic treatment of the lesion on the back, it was concluded that even that was an iodide eruption, although in addition to the above mentioned characteristics, it had a deep brown pigmen-

tation. In both of these instances, however, the circinate eruption was bullous, which would definitely exclude syphilis, as a bullous syphilide is unknown in the adult. As far as peripheral growth of the lesions in iodide of potash eruptions is concerned, Balzer and Lecornu,[3] have reported one case, and Danlos[4] another.

Of course, it might be argued that the sores from which the patient had been suffering for years were not syphilitic at all, but were from iodide of potash. People have been known to get iodide of potash eruptions which well trained physicians mistook for years to be syphilides, and Besnier has said that whenever you run across an eruption, the nature of which is a puzzle to you, think of iodide of potash as the possible cause of it.[5]

There are, however, facts against this theory. In the first place the patient gave a clear history of a sore, followed in due course by a universal, scaly rash; the scars on the patient's body and limbs were grouped and punched out, as scars the result of syphilis are, and the patient said the sores he had previous to his last attack were always benefited by taking the so-called patent blood medicines. It is fair to suppose that the course of events was as follows:

The patient was subject to persistent tertiary cutaneous syphilides which were benefited but not cured by the small quantities of iodide of potash in the patent medicines. The quantities, I believe, are small, because in the first place the manufacturers are thrifty, and also because an amelioration is a better commercial proposition than a cure. The patient went on for years in this way until he got an infected wound while working on scale-infected trees. For some reason the kidneys did not work as well as hitherto, the iodide of potash was not well eliminated, it therefore accumulated, and an iodide of potash eruption started. The more iodide of potash he took thereafter, the worse the eruption became. The functions of the patient's kidneys were found not to be normal, and, as before mentioned, these abnormalities consisted in wide variations in the quantities of urine voided on different days, and in its containing at times, large quantities of hyaline casts. A number of observations have been made of iodide of potash being taken for a long time with impunity or with only the usual slight inconveniences, and finally producing afflicting symptoms in either internal or external organs.[6] In some cases, as in the present, good evidence of incompetency of some of the eliminatory functions, especially of the kidneys, have been found.[7] The diagnosis therefore was made of syphilis and a tuberous iodide of potash eruption.

An interesting observation was made on the examination of the piece of tissue removed from the lesion on the forehead. Many of the fields under the microscope looked exactly like epitheliomatous infiltration. There was the same appearance of connective tissue *loculi*, solidly filled with atypical epithelial cells. It is true that the whole process took place above the level of the skin, not down into it, but this last observation was a clinical not a pathological one, and one getting such a piece of tissue sent to a laboratory for examination, without a most carefully worded history or without seeing the patient, might easily commit the error of supposing the affection to be an epithelioma. Even with all the facts before one, the error is not unlikely to be made. Suppose, as is possible,[8] a case where only one iodide tumor has developed. There is, in such a case, a single tumor with a rounded edge, and a rotten, ulcerating top, having the clinical appearance of a malignant tumor. A microscopical examination is made, that also is likely, as we have seen, to lead one astray. No mention may be made of taking iodide of potash, or even if mentioned it may not receive due consideration. Mention in medical literature of the possibility of such an error is very rare, and I have never seen it referred to at all in the diagnosis of epithelioma.

To return to the consideration of the difficulty of diagnosis between some of the iodide of potash eruptions and some of the syphilides it would appear that Nature has here laid a trap to deceive all experience, learning and caution. Hallopeau and Fouquet[9] report a case where the patient had iodism six times in nineteen years, and the mimicry of syphilis was so perfect that under some physicians he received as much as six grams of iodide a day, always given with the intention of curing his malady.

Gemy[10] relates that two patients entered his hospital at the same time, one having an iodide eruption, and the other a syphilide. The iodide eruption in the one resembled some of the syphilides in the other so closely that, even with the patients placed side by side, the differentiation could only be made with great difficulty. In yet another case Gemy himself was so persuaded that the eruption was syphilitic, that he continued the patient on large doses of iodide of potash, making previously shallow ulcerations in the face very deep, and causing permanent disfigurement.[11]

On February 13, 1903, a little over three weeks after I first saw the patient, he came to the University clinic. He was much improved. The lesion on the forehead, on which the biopsy had been performed, had flattened out, leaving a red, smooth surface, cov-

ered by a light, slightly adherent crust. There was no evidence that the piece of tissue had been removed. Another lesion on the center of the forehead looked like an unusually large, prominent wart. The lesions on the scalp were covered by thick, greenish sebaceous masses. the deeply pigmented, circinate lesion on the back, and the circinate, scarred lesion on the back of the right hand were still present, but improved.

The lesions healed slowly, those on the back of the hands being the most dilatory. After healing, it took quite a length of time for the inflammatory infiltration of the hands and fingers to subside. When he last visited the Clinic, in the beginning of November, 1903, the hands were quite supple, and nothing remained of his malady but the scars.

As regards the treatment of the iodide eruption, the withdrawal of the offending drug, and the application of some inoffensive surgical dressing to relieve the pyogenesis, such as boric acid, either as a powder or as a lotion, seems to be all that is necessary. No matter how exuberant or offensive the tumors appear, curetting does not seem to be necessary.

The reason of there being no scar after removing such a large piece of tissue as that removed at the biopsy was that the tissue removed was almost wholly pathological tissue, and involved only to a very slight degree the normal tissue. The same is true of chancres for instance. An enormous chancrous ulceration will leave a most insignificant scar, because the ulceration has taken place almost entirely at the expense of the pathological newly formed tissue. When the pathological tissue is absorbed in the healing of the chancre the loss of normal tissue will often be found to be surprisingly small.

REFERENCES.

1. Ehrmann, Dr. S.—Forms of Toxic Acne. *Handbuch der Hautkrankheiten von* Prof. Dr. Franz Mracek. Band 1, s. 504.
2. The febrile reaction may have been due to a so-called "cold," or from pyogenic infection from the suppurating iodide lesions, or it may have arisen from the action of iodide itself, as such, on the system. Instances of iodide of potash giving rise to fever have been reported by:
Neumann, Vienna Society of Dermatology Meeting, March 23, 1898, reported in *Ann. de Derm. et de Syph.*, 1898, page 1158.
G. Kaempfer, *Centralblatt f. Klin. Med.*, 1890, No. 6 abstract in *Ann. de Derm. et de Syph.*, 1890, page 507.
Hallopeau, *Ann. de Derm. et de Syph.*, 1888, page 285.
Pellizzari, *Ann. de Derm. et de Syph.*, 1885, page 537, and also *Ann. de Derm. et de Syph.*, page 362.

PLATE IX.—To Illustrate Dr. Douglass W. Montgomery's Article.

Fig. 1.

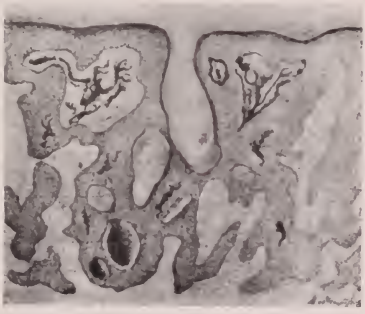

Fig. 2.

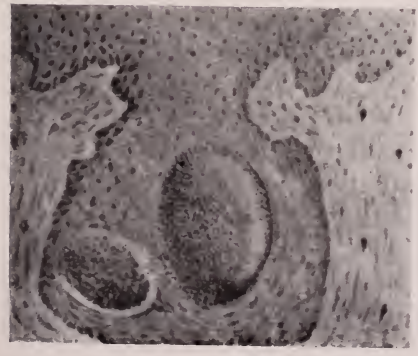

Fig. 3.

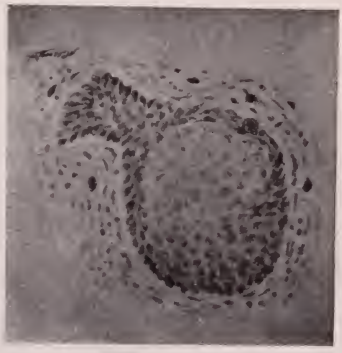

Fig. 4.

PLATE X.—To Illustrate Dr. Douglass W. Montgomery's Article.

FIG. 5.

DESCRIPTION OF PLATES

Illustrating Dr. Douglass W. Montgomery's Article on "A Tuberous Iodide of Potash Eruption."

FIG. 1. Section of a nodule in iododerma according to NEUMANN, (Taken from DR. S. EHRMANN's article on iodide acne, *Handbuch der Hautkrankheiten von* PROF DR. FRANZ MRACEK. Bd. 1. s. 504.)

FIGS. 2, 3 and 4. Taken from an illustration in DR. NORMAN WALKER's article on "Dermatitis Tuberosa," showing the histological resemblance of the iodide tumor to epithelioma. *Monatsh. f. prakt. Dermat.* Bd: XIV., s. 263.

FIG. 5. Microphotograph of a vertical section of tissue taken from a tumor on the forehead of the patient, the subject of this paper. Photographed through the kindness of IRVING HARDESTY, A.B., Ph.D., Instructor in Anatomy, University of California.

3. Balzer and Lecornu, *Ann. de Derm. et de Syph.*, 1902, page 271.
4. Danlos, *Ann. de Derm. et de Syph.*, 1898, page 1006.
5. Besnier, *Ann. de Derm. et de Syph.*, 1888, page 303.
6. F. Rosenthal, *Ann. de Derm. et de Syph.*, 1902, page 285; from *Arch. f. Derm. u. Syph.*, 1901, LVII, page 83.
   Hallopeau, *Ann. de Derm. et de Syph.*, 1888, page 285-304.
   Pellizzari, *Ann de Derm. et de Syph.*, 1885, page 537.
7. Danlos, *Ann. de Derm. et de Syph.*, 1898, page 1006.
   Neumann, *Ann. de Derm. et de Syph.*, 1898, page 1158.
   Canuet and Barash, *Ann. de Derm. et de Syph.*, 1897, page 810.
   Hallopeau, *Ann. de Derm. et de Syph.*, 1888, page 285.
8. See Norman Walker's case, *Monatsh. f. prakt. Derm,*. 1902, Vol. XIV., page 263, and Morrow, *Ann. de Derm. et de Syph.*, 1887, page 276.
9. Hallopeau and Fouquet, *Ann. de Derm. et de Syph.*, 1901, page 541.
10. Gemy, *Ann. de Derm. et de Syph.*, 1891, page 659.
11. Gemy, *Ann. de Derm. et de Syph.*, 1891, page 646.

ATYPICAL LESIONS IN ICHTHYOSIS.

Report of a case co-existing with *mal perforant du pied.*

By Dr. Mortimer A. Moses, New York.

ALTHOUGH the pathology of ichthyosis has been sufficiently well established, there still exist certain deviations from the ordinary histological picture which would seem to warrant further investigation. Again, the co-existence of perforating ulcers, which clinically resemble the condition known as *mal perforant du pied*, presents a combination of diseases which, so far as our knowledge goes, has not previously been reported. Unna divides the cases of ichthyosis into three groups, both histologically and clinically; "ichthyosis nitida" and "ichthyosis serpentina" or "sauriasis," which are both generalized forms, and the "ichthyosis hystrix," which is usually more or less localized.

Our own observations in common with the observations of many others oppose the separation both clinically and histologically of the first two groups, as we consider the two conditions to be different degrees of the same disease. Whether ichthyosis hystrix is a distinct form or even an entirely separate disease, must, we think, be answered in the affirmative; at least, we think that if we use the finer histological technique, and particularly if we investigate the rôle of the elastic fibers in the hystrix variety, we can positively conclude that the latter and the former conditions are two distinct and different conditions or diseases.

In regard to one clinical difference made by Unna between his ichthyosis nitida (usually known as ichthyosis simplex), and ichthyo-

sis serpentina, stating that in the latter only are the so-called "added eczemas" to be found, we believe that experience shows us that these eczematous (so called) processes are seen to occur in even the mildest forms of ichthyosis and not in the more serious saurodermatic conditions only, as he would have us believe. Histologically the increase of moisture of the prickle layer and the coexistence of a parakeratosis with a hyperkeratosis in sauroderma, and also the existence of acanthosis which latter is always absent in all other conditions included in the caption ichthyosis, would tend to justify the above supposition; clinically, however, we have several times seen all the symtoms of a severe inflammation in cases which presented only the mildest forms of xeroderma and in which chapping of the skin on slight provocation and the absence of transpiration were the only symptoms that called the attention of the patient to the fact that there was something wrong with the condition of his skin.

The case which we recently had an opportunity of examining and the histological findings which we desire to report here wherein certain atypical conditions prevail, was that of an idiot, who died from a gangrenous pneumonia. The boy presented during his entire life the typical picture of an ichthyosis simplex, which disease was noticed to exist almost immediately after birth, the child having apparently been born with it. There was little of special interest to be noted about the eruption, except that it was extremely diffuse, hardly any part of the body being free from lesions. The history also shows that the child suffered at various times from the so called "secondary eczemas" of ichthyosis, but after death the inflammatory lesions, as is usually the case, could not be distinguished from the others and therefore we could not select the material for investigation of that condition. In reviewing the pathological findings in ichthyosis and in attempting to deduce the pathogenesis of the disease therefrom, we are at the outset met with opinions which are diametrically opposite. Most authors consider that there is some congenital defect in the development of the cutis, chiefly of the epidermal layer, but according to Unna the defect is an acquired one and he only admits a congenital predisposition and regards it as "an infectious hyperkeratosis tending to parakeratosis" and compares it to pityriasis rubra and psoriasis; in short, in his opinion, it is a low form of inflammation shown by the constancy of an increase of cells (a dry catarrh) with the tendency to moist catarrh, which catarrh however he does not regard as an eczema, but simply as an increase of the always present, but latent, inflammation.

This view, we believe, has received but scant support. The evidence which one might deduce from the case forming the basis of this paper, in which as we shall see there were certain defects in the glandular system of the skin; and also from a case which was described by Tandlau in which similar congenital glandular defects, but without ichthyosis existed, does not guide us much in our deductions in that particular direction. Be that as it may, we consider that upon a painstaking examination one is always able to find some evidence of inflammatory action, but whether such be primary or secondary we do not feel justified from our limited observations to decide. It does, however, tend to show that congenital anomalies such as we find in Tandlau's case, and probably similar conditions which we find in the glands in our ichthyosis case, cannot be looked upon as etiological in the production of ichthyosis—the first case is referred to in the hope of stimulating investigation should a case showing similar clinical conditions to those therein noted come under observation. Furthermore, what was striking in this case, and which led us to use special care in the examination of other organs besides the skin was the existence of several sinuous ulcers, lentil to bean-sized in diameter, some extending to the bone, others more superficial, upon the soles and dorsi of both feet. Three each were seen upon the soles of each foot, and two upon their dorsi, one on each side.

These ulcers made their appearance about a year before the patient's death, following one after the other; they secreted a scanty, slightly fetid fluid and presented a blackish dirty circumference. We unfortunately did not see these ulcers during life—the physician who had charge of the case made the diagnosis of *mal perforant du pied*, probably partly basing and further substantiating his opinion upon their occurrence in a subject, who although not paralyzed or showing any gross changes in the central nervous system, was, nevertheless, a person of abnormal nervous character. It, therefore, seemed of additional interest to examine carefully the central and peripheral nervous organs in the hope of ascertaining whether any causal connex, possibly existed; a supposition which *a priori* did not seem very promising of demonstration histologically although we might well surmise such connection.

Perforating ulcer of the foot, is usually considered as a trophoneurotic disease, and according to Stelwagon, (who seemingly bases his description upon Savory and Butlin's excellent paper) can be described as a "degenerative, circumscribed, more or less calloused formation developing into an indolent and usually painless sinus leading down through the deeper tissues to the bone."

In several of Savory and Butlin's cases there was no evidence of any nervous disease; several seemed to have their point of origin from some local trauma or injury; in one case eczema existed at the site of the ulcer some time before its formation; in another case it was attributed to a blow received by the mother during pregnancy and which caused a "numbness" only in the limb until the advent of ulceration in adult life. In fact, organic nervous disease does not enter into the etiology of this affection in any of the cases described by these authors but in all cases in which a microscopic examination could be obtained the following conditions were noted. Sections showed the ordinary characteristics of a simple chronic ulcer. Transverse sections of the anterior and posterior tibial nerves as high up as possible (after amputation) exhibited great thickening of the epineurium, very little alteration of the perineurium and thickening of the endoneurium in some of its fibers; in other fibers the endoneurium was normal, but the fibers were composed only of fibrils of the largest size containing axis-cylinders and a very thick coating of medullary substance. There were very few fibrils in any of the fibres. There was no increase of nuclei. The vessels appeared normal or but slightly thickened.

The technique of the examination of our case consisted in the hardening of the ichthyotic skin pieces in alcohol; the ulcerous lesions were submitted to the same treatment. A piece of spinal cord and pieces of the nerves supplying the ulcers were hardened and preserved in Muller's fluid. Both paraffin and celloidin sections were made; and the ordinary nuclear and protoplasmic stains, the tinction for elastic fibers and for the degeneration products of connective tissue (collacin, elacin) were employed. The result of the histological examination, as already mentioned, was surprising in showing the entire absence of sebaceous glands in the extirpated skin of the chest, abdomen, back and thigh. The hairs on these parts were also remarkably few in number and atrophic. But what was of particular interest, from a clinical point of view, was the entire absence of sweat glands in the extirpated proportion of the thorax skin while there were present in the skin of the back an apparently normal number of coils. Before attempting to estimate the significance of these conditions we shall attempt to enter into the histological details of the skin lesions more fully.

The study of the preparations from the skin from several ichthyotic places gave on the whole the general picture of an ichthyosis simplex. The horny layer took the ordinary stains fairly homogeneously, but a stratum lucidum could not be well differentiated. No trace of parakeratosis was evident and, as is usual in ichthyosis, the stratum

granulosum was absent and the horny substance was superimposed directly upon the Malphigian layer without the intervention of a keratohyalin layer. Still, by means of the glacial acetic-acid-hæmatoxylin-method of Unna, a small quantity of keratohyalin could be found irregularly distributed in spots in many of the specimens. The epidermic change that immediately attracted our attention, however, on account of its conspicuousness was the deformity of the prickle layer. This layer was extremely attenuated, so much so that in many places the horn substance was separated from the cutis by only two or three rows of cells. The papillary body was also, in all preparations which were examined, very poorly developed. The Malphigian cells themselves were conspicuously small; their normal polygonal form had entirely disappeared and they took on a more or less spheroidal shape, destroying all resemblance to epithelial cellular elements. By means of a good polychrome-methylene-blue stain we could recognize the nucleus deeply colored dark blue, while the protoplasm strongly differentiated itself by its very faint tinction. According to Unna, this clear appearance of the protoplasm is caused by the absence of keratohyalin within the cells. As in our case, there was only very little or no keratohyalin present, while in other cases of well developed hyperkeratotic processes a proportional relationship between the development of the corneous layer and the keratohyalin layer exists we can, partially at least, support Unna's contention that between cornification and keratohyalin formation no relationship exists. On the other side, however, we must refer to the publication of a case of ichthyosis hystrix by Schourp where, in spite of the enormous hyperkeratosis there present, a feebly marked but distinct keratohyalin layer still existed. The prickles connecting the rete cells are only occasionally and with difficulty demonstrable; they appear to be feebly developed and take on stains poorly. This, in all probability, could be caused by a moderate interspinal œdema, a hypothesis, however, which would need more evidence to support it. The germinative (basal) layer is not very well marked in most places; in some of the preparations we can find considerable pigment arranged in larger or smaller clumps.

Beyond the transitional layer between epidermis and corium we find that the upper third of the latter presents the appearance frequently seen in hyalin degeneration. Inflammatory character is reduced to a minimum; at only a few points do we find a limited number of mononuclear leucocytes surrounding the vessels, whereas the vessels themselves seem only moderately filled. Mast cells are found with comparative rarity, perhaps with the same degree of frequency as in nor-

mal tissue; plasma cells are entirely absent. Examination of the network of elastic fibers, however, gives a decided contrast to the condition found according to our observation in ichthyosis hystrix. In that condition they were *entirely absent* in the entire upper third of the corium, whilst in this case, in accordance with the views usually held in cases of the simplex variety, they are seemingly intact and their ramifications can be traced to the utmost upper boundary of the cutis. In spite of this, however, we must admit that even in our case at certain points, there was an entire absence of elastic fibers, so that in this one point one could, histologically at least, think of a transition into the hystrix variety. But very good evidence against such supposition is supplied by the absence of marked hyperkeratosis of ichthyosis hystrix and also by the fact that the parts presenting this discrepancy were always in the immediate vicinity of the ulcerations before mentioned. Hence we can very easily believe that this change could be due to the excessively inflammatory character in these parts and not to the ichthyosis *per se*. Furthermore, we found it of consequence to direct our attention to the existence or non-existence of known chemical changes in the elastic tissue.

To this end we employed Unna's reactions for elacin and collacin, but with perfectly negative results.

However, the corium itself manifested the condition before mentioned, and which, as far as we are aware, has never before been noted in ichthyosis; namely, the change in the glandular system of the skin. *The sebaceous glands were entirely absent.* The hairs either were only rudimentarily developed, or in their place horny cysts had appeared, or at a few places the remains of lanugo hairs were to be found. In the same manner, in sections taken from the skin of the chest, there was an entire absence of sweat glands; but in the skin of the back and of other regions they were present, apparently in normal amount and condition.

These two last conditions appear to us, clinically at least, to acquire a special significance; as it is well known that individuals suffering from ichthyosis sweat very little or only in certain parts, a fact that can be explained by the results of the above investigation. On the other hand, it is admitted that the ichthyotic skin is abnormally dry, and this may also perhaps be explained as due to the absence of the sebaceous glands. Certainly, we are not warranted in drawing such conclusions from the scant material at our disposal, but it would nevertheless seem to constitute a further field for investigation.

Apart from the significance of the above facts which in our opinion

gives sufficient warrant for the publication of this case, the examination of the *malum perforans* failed to elucidate any new or unknown facts. It is of interest to note, conspicuously evident in the histological picture, that in the transition of the ichthyotic skin to the skin approaching and surrounding the ulcers, there was an enormous infiltration in, and dilatation of the vessels. Between the ulcers the evidences of inflammation were well marked. Although we were particularly interested in finding changes in the nerves supplying those parts we were destined to be disappointed. But it is not to be ignored that the cause of the absence of such changes, or rather their being non-evident, was due to the process not having been sufficiently old to have caused them. Besides, as a sign of the slightly progressive nature of the *mal perforant*, in the superficial layers of the corium, beneath the enormously filled and dilated vessels, the commencement of newly forming elastic fibers could be demonstrated, whereas in the margins and in the upper portion of the corium they were still *entirely* absent. The inflammatory action in the neighborhood of the ulcers was evidenced by well marked acanthosis; in the deeper portions of the corium could be seen circumscribed masses of plasma cells; mast cells were also present but in moderate number.

As we from the outset presupposed, the examination of the portions of the spinal cord and of the nerves leading from it, with their anastomoses, proved themselves entirely normal.

To conclude, we may state that the desire to establish any connection between skin and central nervous system has been futile. On the other hand it appears to us that the results of the histological examination showing the change in the glandular system were remarkable.

Clinically, the co-existence of mal perforant du pied and ichthyosis such as has been, as far as we could determine, never before noted, is of interest. Besides this, the localization of some of the ulcers upon the dorsi of the feet also, instead of upon the soles alone is atypical. Furthermore, the question arises, Does the clinical appearance as above described, and which corresponded to that in our case, justify the diagnosis of mal perforant, or, is it necessary to also have the evidences of local nerve involvement in a case of organic nervous disease accompanied by paralysis of the member involved, before such diagnosis is admissible? Personally we are unable to decide this point, and we think that the surgeon who treats such cases and the pathologist who has the opportunity of noting their etiology and the histological changes present after death, must decide for us. We certainly, however, have evidence for believing that ulcerations conforming to all the

clinical requirements of a mal perforant do occur in cases independently of a co-existing nervous (motor) disorder, as evidenced by the observations in the paper of Savory and Butlin before referred to, and others.

The occurrence of the ulcerations also upon the dorsi of the feet as in our case would tend to disturb the theory of those who contend that such ulcerations occur from pressure only. Further observations are needed to establish if mal perforant du pied is, or is not a complication only of certain nervous diseases affecting motility, or if, perhaps, it may not be a concomitant of some cases of ichthyosis, or other hyperkeratotic processes. Certainly, the occurrence of mal perforant in certain cases of lowered vitality, such as occur in diabetes, would also make it probable that neither pressure effects alone, nor gross organic nerve involvement must necessarily be responsible for this condition.

Literature: We are indebted for the use of the following articles in the preparation of our subject. The following is by no means a complete list of literature —only those articles bearing upon our case particularly and utilized by us are here mentioned.

Of Ichthyosis:

Unna: Histopathology.

Joseph: Ueber atypische Ichthyosis formen. Verhandlungen der IV. Deutschen Dermatol. Congress.

Schourp: Ueber Ichthyosis hystrix. Dermatologisches Centralblatt, erster Jahrgang, No. 8.

Tandlau: Virchow's Archiv., 1902, Vol. VII., page 465. Tandlau's case is the only one of its kind described in the literature, although others probably must have been observed in which no pathological examination was made. In brief, the case was as follows: The patient was a furniture polisher, aged forty-eight years, who was under observation for two years prior to 1902 and was taken into hospital on account of a chronic bronchitis. Patient had never had much hair on his body as a child, but at the age of twenty, he lost a large portion of the little he had. Patient never sweated (*absolute* anidrosis) and was therefore rendered very uncomfortable in hot weather and could only work if he wore wet underclothing. The rest of the history is very interesting, but cannot be reproduced here. The histological examination of a piece of skin from the forearm (biopsy) showed the skin to be of about half the normal thickness; the adipose tissue was *entirely* absent. There were absolutely no traces of sweat glands, sebaceous glands or hair follicles in the piece of skin examined. However, on other parts of the body the sebaceous glands and the follicles were undoubtedly present, as evidenced, the former by the presence of sebaceous secretion, the latter by the macroscopical appearance of the skin; although there were many parts in which the pores also were entirely absent. (In our ichthyosis case the sebaceous glands were also absent in the skin of the *numerous* parts of the body examined.) That this was not due to any retrogressive change is evidenced by the absence of any collections of cells which might indicate the previous site of such glands had they at any previous time been present. Other changes are those which are found in cases of atrophia

cutis idiopathica and which are mentioned by Unna, and well described by Pospelow, Buchwald and others.

Of Mal Perforant du Pied:

Savory and Butlin. Med. Chirurg. Trans. Vol. LXII., (1879), with colored plate and microscopical drawings of nerves and a full bibliography.

Tomasczewski. Münch. Med. Wochensch., 1903, XX., p. 843.

Gasquet: Thèse de Paris, July, 1890, (quoted by Crocker; the original was not accessible.) Gasquel collected ninety-one cases, eighty-four of which were in males. The age was stated in seventy-nine; three were under twenty, four between twenty and thirty, twenty-two between thirty and forty, thirty-one between forty and fifty, and nineteen were over fifty. In sixty-nine cases there was a central nervous lesion; in eight cases there were peripheral nerve lesions and fourteen cases were diabetic.

Thirty-two had tabes, seventeen general paralysis, eight were alcoholic subjects, four had traumatic disease of the cord; eight had various cord lesions, one being Friedreich's disease (being a decided contrast to Savory and Butlin's cases, most of which seemed to be due to a peripheral cause.)

Terrillon quoted in *Lancet,* April 11th, 1885, page 676. A case in which the hand was affected.

In conclusion we wish to express our indebtedness to Dr. Max Joseph of Berlin for the acquisition of material and the use of his laboratory in the preparation of same.

A CASE OF MYCOSIS FUNGOIDES TREATED BY THE X-RAY.

By Albert E. Carrier, M.D., Detroit, Mich.

In a disease so universally fatal as mycosis fungoides, any treatment that, even for a time, seems to stay the progress of the affection, or relieve it of the distressing subjective symptoms, will be heartily welcomed. Few of the cases of mycosis fungoides come to us in the early period of the disease, and we are dependent upon the memory of the patient for a description of the early symptoms. My patient was a most intelligent man, and his business (doing detail work among physicians for manufacturing drug houses) had brought him in contact with doctors who had examined him frequently during the earlier period of the affection, as well as the later, and having frequently discussed it with the patient had kept him familiar with the changes occurring during the whole course of the affection. The symptoms as described are those typical of mycosis fungoides, and I am reporting it because of the rapid, and complete disappearance of all objective, and subjective symptoms of the disease under the use of the X-ray.

The patient, Mr. B.——, aged 75, American born, occupation commercial traveller, had always enjoyed good health, never having

had any venereal disease. His family history was clear of tuberculosis, or any malignant affection.

Twelve years ago an eruption appeared on the back, and on the legs below the knees which he described as a "fine red rash." Pruritus was severe, and there was some smarting, although the lesions were never moist and were not attended by much desquamation. A physician pronounced the disease eczema and prescribed arsenic and trifolium compound. Under this treatment the eruption disappeared and the skin was free of lesions for one month, when the rash again appeared and the pruritus was very much more severe than during the first attack. From this time until my first examination he had never been free from this distressing symptom which seemed to increase in severity with the age of the disease. Soon after the second attack a number of sharply outlined round white spots, the size of a split-pea, developed on the forearms. They were not scaly, nor did they itch; his physician told him that the other lesions had developed from these spots. With this attack, desquamation became free and has continued without any intermission up to the time I first saw him. Three years ago a split-pea sized nodule, the color of the normal skin and covered with fine scales, developed in the upper part of the left popliteal space. This lesion was the first of the tumor lesions and has remained, increasing in size up to that of a small orange; it was the only one of the tumors that was scaly, and has not been attended by any subjective symptoms. Other lesions of a like character, but not scaly, developed about the hips, buttocks, and abdomen, and new ones have continued to appear up to the time he came under my care.

Previous to consulting me he had been under the care of a number of our city physicians, and the disease in every instance had been pronounced eczema. The last treatment used was called by the physician treating him the "purple-ray," to which the large lesion had been exposed daily for seventy-seven days without any benefit. I think the apparatus was a thirty-two candle power lamp, and a colored globe.

On July 27th, 1903, Mr. B—— came under my care, stating that he was suffering from the worst case of eczema that I had ever seen, and that the itching was almost beyond endurance.

Mr. B—— was a rather slender, fairly well developed man. His skin was wrinkled in places and loosely attached, and had a distinct, though light, yellowish tint. The cutaneous surface free from lesions had a peculiar appearance. At a distance it looked like an ichthyotic skin, with the outlines of the scales very sharply

marked, but there was no scaling and the skin in these locations was smooth and supple; it was simply an accentuation of the normal skin markings. On the back of the thorax were two large, indurated, sharply outlined plaques which were thickly covered with scales. The sites occupied were over the scapular regions, and each lesion corresponded in size with the underlying scapula. The color of these lesions was yellowish pink, the induration was slight, the scales easily removed. On the anterior surface of the thorax were two large plaques over the mammary region, these were also sharply outlined, and similar to those on the back. Numerous smaller patches of a like character were found on the abdomen, buttocks, etc. These plaques were the seat of intolerable itching. The scaling on all these patches was profuse, and the scales peculiar in being almost pure white in color, easily powdered between the fingers. The lesions gave the impression of being covered by a thin layer of cotton.

Distributed over the whole cutaneous surface with the exception of the face, hands and arms, and the legs below the knees were over three thousand tumors, which varied in size from a pin-head to a small orange, for the most part dome-shaped, freely movable, and, with the exception of one in the groin, and one in the axilla, were the color of the normal skin. They did not itch, and their surface was free from scales, the larger lesions were quite hard but the smaller ones were soft. No lesions had ever disappeared, and new ones were continually making their appearance.

In front of the right axilla were three ridges, two and one-half inches long, one-half inch high, and one-half inch wide. In the right groin were three similar ridges only a little larger. Mr. B— states that in the groin lesion there was at one time some ulceration between the ridges, but that it had healed under the use of a powder. This was the only time in which any evidence of the tumors breaking down had been noticed. In the left groin was a walnut-sized lesion, and over the perineum and scrotum were several large lesions.

The largest lesion was just above the left popliteal space; it was oval in shape, three inches in its long diameter, two inches wide, and one half inch in height. This was the first of the tumor lesions to appear, and had been growing for three years; it was dark brown in color, surrounded by a dense, infiltrated, ribbon-like band, one inch wide, which was more deeply pigmented than the tumor; this in turn was surrounded by a zone of lighter pigmentation which did not shade into the bordering skin, but was abrupt, the outlines of the patch being sharply marked. The top of the tumor was flat, a little depressed in

the center, and covered with scales; it was quite hard, but very much softer than the band of induration that surrounded it. Many of the lesions were so small that the aid of a glass was necessary to discern them. Between the posterior borders of the scapulæ were a number of split-pea sized, dark brown lesions, on a level with the skin, and not scaling. The itching was always in the scaling lesions.

The patient only asked for relief from the pruritus, and as he had always been told that his disease was eczema he did not realize the gravity of the affection. Efforts were made to overcome the pruritus by various local applications but without any effect, and from the benefit derived by using the X-ray in other pruritic affections I decided to use it in this case, but without any expectation that its use would cause a disappearance of the lesions. I began treatment with the X-ray, August 17th, 1903, giving daily exposures to the plaques on the front and back of the thorax, using a six-inch tube of moderately low vacuum, limiting the exposures to five minutes at a distance of five inches. Every other day I exposed as much of the surface which had not been treated, as I could in a seance of one hour. On August 20th, the first effect of the rays was noticed; this was a bronzing of the skin—no erythema. The pruritus was less severe, the tumors were not affected and new ones were appearing. On September 2d, the skin had become darker in color, and, in parts, there was a slight erythema. The pruritus had been entirely relieved, some of the smaller lesions that had been marked for identification had disappeared, and fewer new ones were developing. The scaling on the plaques was very slight. From the effect produced on the tumors I decided to direct special attention to their treatment, and selecting a space twelve inches square on the left side of the thorax where I had counted three hundred tumors, I began with daily exposures, using a tube of higher resistance at a distance of five inches for five minutes. I noticed improvement from the first, the tumors rapidly disappearing, and no new ones developing. The large tumor under the knee I gave longer exposures, never, however, exceeding ten minutes, and never during the treatment was there any evidence of a burn other than a slight erythema. On November 1st, the skin was practically free of the disease with the exception of the tumor under the knee, and this had become level with the skin, but was a little infiltrated and deeply pigmented; the indurated band surrounding this tumor was the last to disappear. On November 10th, there was present no evidence of the disease (with the exception of pigment in the sites of the larger tumors), no induration, no scaling, no erythema, no tumors, and no pruritus, and whatever benefit the patient had derived

PLATE XI.—To Illustrate Dr. Albert E. Carrier's Article.

Fig. 1. Mycosis fungoides before X-ray treatment.

Fig. 2. Present appearance.

Fig. 3. Large fungoid tumor before X-ray treatment.

Fig. 4. Present appearance.

must be traced to the use of the X-ray, for at no time during its use was any medicine given internally, nor was any applied externally. It is of course too soon to predicate anything for this treatment in mycosis fungoides, but in this instance it has undoubtedly stayed the progress of the disease. The skin is free of tumors, one of which, I think, was approaching the time when it would begin to break down and add a source of danger in the way of exhaustion, but this has been avoided without a surgical operation, and the patient is not deprived of rest and sleep by the itching. I removed one of the smaller tumors with a portion of the surrounding skin and also sections from the site of the large tumor after it had disappeared, which were sent to the Detroit Clinical Laboratory for examination. This work has not yet been completed. I am keeping the patient under observation and shall watch closely for any evidences of a return of the disease.

The dark lesions between the shoulder blades were probably seborrhoic warts, these were not affected by the X-ray, nor were several large moles, one of which I selected for a daily exposure; but after thirty treatments with no other effect than to produce a slight erythema, I stopped the use of the X-ray and the mole is still present.

A CASE OF ACTINOMYCOSIS.

By H. J. F. Wallhauser, M.D., Newark, N. J.,

Visiting Dermatologist, Newark City Hospital; Consulting Dermatologist, Hospital of St. Barnabas; Dermatologist, City Dispensary.

J. M., age twenty-eight, nativity U. S., occupation teamster, employed in carting hay, grain and flour, was admitted to the Newark City Hospital, Dec. 23, 1902.

Patient enjoyed good health until about four months ago, when he noticed a small pimple on the point of his chin, from which he pressed a small amount of pus. About one week later a swelling appeared in the same place, gradually enlarging to the size of an English walnut. This was followed by similar nodular swellings, until a firm indurated mass was developed, extending from the corners of the mouth and lobules of the ears above, to a line midway between the point of the chin and upper border of the sternum below. When the patient came under observation there was considerable œdema outlying the lesion, extending to the eyelids. The left one was entirely

closed. The plate does not show this, as the photograph was taken about two weeks after admission.

The lesion consisted of an indurated board-like mass, in which were numerous nodules and nodular masses, varying in size from a pea to a small hen's egg. The surface was glossy, of a purplish red color, and presented numerous small orifices lined with a blotter-paper-like detritus, which, when peeled off left a bleeding granular surface. These orifices marked the outlet of numerous sinuses, which permeated the mass in every direction, and that they communicated with one another was conclusively shown by injecting hydrogen peroxide into one, which caused an effervescence from all the openings, including those on the opposite side of the sinus injected.

Scattered over the surface, there were numerous pale yellow papules about the size of a split pea, and irregular purplish soft elevations, which marked the site of future sinuses. About the lower third of the lesion, there were several deep sulcated lines extending transversely across the surface corresponding to the natural furrows.

The constitutional disturbance was slight. The patient continued his work until his admission to the hospital; a period of about four months from the beginning of the disease. Pain was not a prominent feature, in fact, it was only slight compared with what one would expect from such an extensive inflammation. On admission his temperature was 100 F., pulse 104; both temperature and pulse dropped to normal on the third day, and remained so throughout treatment, which was entirely local. The sinuses were washed by injecting peroxide of hydrogen, diluted one-half, twice in the twenty-four hours, and a wet dressing consisting of the following was applied:

Ac. Boric	45.
Ac. Salicylic	24.
Aq. Distillat qs. ad.....	500.

Jan. 7th, or about two weeks after admission, the outlying œdema had entirely subsided, and the nodular masses were decreasing. The sinuses were discharging a sero-purulent fluid with a slight admixture of blood. A few new papules had appeared, which were incised and cleansed with peroxide solution. He improved steadily, and was discharged from the hospital March 5th. The nodules had entirely subsided, and the sinuses had ceased discharging. There only remained the pigmented depressed scars, and about three papules which were still being treated.

PLATE XII.—To Illustrate Dr. H. J. F. Wallhauser's Article.

A Case of Actinomycosis.

On April 7th, he was readmitted to the hospital for an attack of pneumonia which defervesced on the sixth day, followed by an active delirium, probably alcoholic, which lasted five days, from which time he convalesced steadily, and was transferred to my service April 26th. A few new papules and nodules had appeared. These were treated as before, and on May 5th, patient was discharged in about the same condition as before his pneumonia.

He was rather careless regarding his condition, and discontinued treatment for two months, during which time his condition became worse. Sept. 1st, potassium iodide in increasing doses was added to the local treatment, two months later there remained only the pigmented depressed scars.

The secretion was examined by Dr. R. C. Connelly at intervals of a few days, and although the yellowish granules were readily found in great numbers, the ray fungus could not be demonstrated in them. The crusts and sections of the tissue at the orfices of the sinuses were examined by teasing and mounting in glycerine, and once only was the characteristic clubbed mycelium found. The microscopical findings consisted mainly of leucocytes. A few polynuclear cells, red corpuscles and disorganized detritus. A few staphylococci and streptococci were almost constantly present.

The yellow granules were about the size of a small pin's head, and in color varied from a grayish white to a decided yellow. Examined with a low power, they were seen to consist of irregular segmented spheroidal and cuboidal masses of a pale yellow color; on slight pressure, they broke up into irregular masses. Stained by Gram's method, and examined with a 1-12th objective, they were seen to consist of a structureless detritus.

Cultures were made on glycerine agar with negative results.

Deductions: The primary infection was on the point of the chin, and from without. The disease advanced in two ways—First, from a pea-sized, purplish red papule, becoming yellow on the surface as it advanced and ruptured.

Secondly, by the formation of nodular masses which became soft and fluctuating, followed by the formation of yellow papules on their surfaces, which marked the site of rupture.

The small papules may be seen outlying the lower border of the lesion.

EDITORIAL

RECENT INVESTIGATIONS ON THE PROTOZOA AS CAUSES OF DISEASE.

DURING the last two years investigations on the etiology of small-pox and vaccinia have been carried on in the Harvard Medical School under the direction of Professor Councilman, which have added greatly to our knowledge of these diseases. Opportunity for the study of small-pox was given by the small epidemic which appeared in Boston in 1901 and 1902. Fifty-four autopsies were made and the lesions thoroughly investigated. At the same time the disease was studied experimentally in a number of animals, including monkeys. From these investigations it has been shown that in small-pox at the time of the earliest manifestations of the eruption there appear in the cells of the rete mucosum small structureless bodies, the smallest of them from 0.5 μ to 1 μ in diameter. These increase in size, and with the increase in size structural differentiation appears. Small points which take the chromatin stain, first appear and this is followed by a differentiation of the body into two substances which stain unequally. One part of these is allied to chromatin and the other takes the indifferent stain of cytoplasm. The bodies increase in size up to 8 μ and 12 μ, and at this time the chromatin-like substance divides into a number of small bodies similar to those which first appear. This development of the organism forms a definite cycle which corresponds to the multiplicative cycle of self-infection in malaria. All these bodies lie in vacuoles in the cytoplasm. When this cycle has been completed a second cycle begins its development in the nucleus. The first stages of the nuclear infection have not been seen but it is supposed that the bodies produced by multiplication (gemmules) enter into the nucleus and after a complicated development form sporoblasts, which consist of a large central chamber with a series of chambers arranged peripherally. In the peripheral chambers spores from 0.37 μ to 0.50 μ develop and these spores constitute the air borne infectious material of small-pox. The nuclear development is more complicated than the cytoplasmic and forms regarded as sexual appear during its course.

Vaccinia was studied in the monkey, in the rabbit, and in the calf. In these, bodies which take a course of development similar to the cytoplasmic forms of the small-pox parasite appear. There is some difference in rapidity of development and size of the organism in the differ-

ent animals and the different localities inoculated. The best development takes place in the skin of the calf. No intranuclear forms appear.

As a result of these investigations it is shown that vaccinia is a definite variety of variola; that the development of the organism in this only goes through the simple multiplicative phase. The contents of a variola vesicle or pustule inoculated on the calf produce vaccinia, and from this vaccinia is again produced. The same material inoculated on the skin of an ape produces small-pox. These cytoplasmic inclusions in small-pox and vaccinia were first seen by Guanieri in 1891 and were regarded by him as parasites. Most observers since then have given the same interpretation, but their full development and multiplication was not known. The intranuclear forms of the parasite forming the striking difference between variola and vaccinia were not known previous to this investigation.

A full repart of the investigation with numerous illustrations will appear in the *Journal of Medical Research* in February.

As an outcome of the interest taken by the pathological department of the Harvard Medical School in pathogenic protozoa in consequence of these investigations by Professor Councilman, a study of the skin in scarlet fever has been made by Associate Professor Mallory. He found that in tissues fixed in Zenker's fluid and stained with eosin and methylene blue, a variety of bodies can be demonstrated which may be divided into two groups. The first group consists of round, oval elongated, and lobulated bodies, varying in size from about two to seven microns, but sometimes considerably larger, composed of a close or coarse meshed reticulum. They are common between the epithelial cells in the lower layers of the epidermis, and also in the protoplasm of the cells, lying in vacuoles and causing an indentation of the nucleus. They are also found in the corium close to the epidermis in the most superficial lymph vessels and spaces.

The second group is characterized by a thin radiate structure. They are found both in vacuoles in the protoplasm of epithelial cells, and also free in the upper lymph spaces and vessels of the corium; in the latter situation often occurring in groups of two to four. They vary from four to six microns in diameter, are usually spherical in shape but sometimes elongated, and consist of a central round body about which are grouped in optical section from ten to eighteen narrow segments, sometimes united to one another, sometimes sharply separated laterally. In some instances these segments are larger and in their staining reaction and form, closely resemble the small bodies already described.

These results were obtained from three pieces of skin taken from the cadaver of a boy who died forty-eight hours after the first appearance of the exanthem. In sections from one of the pieces the bodies were very numerous in places, in the second they were present in smaller numbers, while in the third none was found.

They were not found in the tongue nor in the internal organs. In three other cases, from which material was available they were found in greater or less numbers, while in six cases where death occurred early in the disease they were not found, but in most of these cases only slide preparations made immediately after the autopsy were available. In addition to these autopsy cases, pieces of skin were taken, with the patients' permission, from four adults suffering from light attacks of scarlet fever, but no bodies were found.

In favor of the view that these bodies are protozoa is the fact that we have a series of bodies of distinct and characteristic morphology, which corresponds more or less perfectly with the cycle of asexual development of the malarial parasite. On the assumption that these bodies are protozoa, a series of changes from the small bodies to the radiate bodies or rosettes, together with the reformation of the small bodies from the segments of the rosettes, can be easily followed. In view of the possibility that further investigations may prove that these bodies are protozoa which bear a causal relationship to scarlet fever the name *cyclaster scarlatinalis* is proposed for the organism, from the wheel and star shape of the rosettes, which are its most characteristic feature.

Professor Mallory concludes that while he personally believes these bodies to be protozoa, and to bear a causal relationship to scarlet fever, he is far from claiming that such a relation has been proved. This article, with illustrations of the various forms, will appear in Vol. X, No. 4 of the *Journal of Medical Research*.

Finally, it may be permitted to call attention to the article published in the January number of this Journal and in the November, 1903, number of the *Journal of Medical Research* by Doctor J. H. Wright of Boston on protozoa found in a case of Aleppo boil. The observations in this case also have resulted from the interest taken in Doctor Councilman's studies of small-pox. In all these investigations the results were due to a general perfection of technique rather than to any differential or specific staining. J. T. B.

SOCIETY TRANSACTIONS.

NEW YORK DERMATOLOGICAL SOCIETY.

320th Regular Meeting, December 15, 1903.

CHARLES T. DADE, M.D., President.

A Case of Feigned Eruption. Presented by Dr. Fordyce.

Dr. GEORGE T. JACKSON said that he had seen the case previously with Dr. Fordyce. It had then impressed him as a feigned eruption because of the presence of certain streaks on the breast which looked as if they might have been produced by the application of carbolic acid which had run down on the skin. At that time there were no lesions on the leg. These certainly looked like carbolic acid burns with their whitish centers and red areola. The partial anæsthesia of the patches in connection with their general appearance was strongly suggestive of a carbolic acid burn. He regarded the case as one of malingering.

Dr. CHARLES W. ALLEN said that the appearances about the breast were much like those in a young woman whom he had shown to the society with concentric rings surrounding the scar of an appendicitis operation. In that case the operating surgeon and many others who saw it thought the lesion was tuberculous, and came to the conclusion that the appendix, which had been removed, had been tuberculous. The rings would appear around the ulcer and extend gradually, ring by ring. After she had been under his observation a short time he came to the conclusion that she was a malingerer, and this was proved to be the case by the application of an occlusion dressing. While this was on the rings did not appear, but they did so on removing the dressing. By means of suggestion without hypnosis the rings were made to disappear, and the ulcer healed. The lesions were apparently made by carbolic acid.

Dr. H. H. WHITEHOUSE thought the striated form of the lesions on the breast was evidence of its artificial character, but the most convincing evidence was the more recent patch upon the calf, the center of which was more or less anæsthetic. The burn had the appearance of having been produced by carbolic acid.

Dr. P. A. MORROW concurred in the general opinion expressed, for the lesions did not conform to the typical features of any known skin disease, either in their objective appearances or their mode of development, while they certainly could be explained on the theory that they had been artificially induced. The lesions on the leg were almost conclusive on this point. The woman was evidently hysterical, and there was some evidence of feigning during the examination to determine the presence of anæsthesia.

Dr. S. SHERWELL said he thought he had seen this woman some months ago, and had expressed to her attending physician a very decided opinion as to the feigned nature of the eruption.

Dr. L. Duncan Bulkley said that it was interesting that this spot had appeared on the leg since she had been told to come to this meeting, as she had evidently produced it for the occasion. The speaker recalled a case in which a young woman had a number of remarkable lesions of the skin. When the family proposed going to the seashore, which pleased her, there were no skin manifestations, but on being taken to the mountains, which did not please her fancy, the lesions would appear. In his case it was probable that the skin lesions were produced by the use of sand paper. She was finally told that the nature of the trick had been discovered, and that if any more such lesions appeared her parents would be informed of the true nature of the trouble, and there were no further lesions, although they had constantly appeared previously for two or three years.

Dr. S. Lustgarten said that undoubtedly this was a feigned eruption, but it should be noted that these lesions occurred almost always in hysterical subjects. He thought a careful examination of this patient would reveal certain hysterical stigmata. Even a superficial examination pointed to anæsthetic and hyperæsthetic areas. We should also bear in mind the possibility of genuine hysterical eruptions. In this connection he would recall the experiments made some years ago by Bernheim in producing eruptions by suggestion. For instance, he put a number of postage stamps on the back of a patient, and applied an occlusion dressing, telling her that he had applied a blister. On removing the stamps, large bullæ were found. He also took a letter, cut out of brass, and said he would heat this and burn the skin with it, but instead applied the brass while cold, yet an eruption appeared on the skin just as if the brass had been used to burn the skin. The speaker said that more than ten years ago he had shown to the society a case of what appeared to be gangrene of the back of the hand, which had been treated specifically, surgically and in various other ways. When seen by him the case reminded him of spontaneous hysterical gangrene of the skin. An examination of the patient showed the most decided evidences of hysteria, e. g., complete general anæsthesia. She was apparently cured of the lesion by hypnosis and suggestion. She was told it would get well, and an occlusive dressing was applied. Everything went well for a time, but the surgeon who made the original suggestion being absent for a time, there was a relapse. Further suggestion, however, succeeded in effecting a permanent cure. As these changes were produced under a starch bandage they could not have been feigned, but were truly hysterical.

A Case for Diagnosis. Presented by Dr. H. H. Whitehouse.

The patient was a woman, thirty-two years of age, with a patch on the right cheek about the size of a silver half-dollar. It had been there for about nine months. Further examination showed other lesions on the

fingers of both hands of two or three weeks' duration. She had been married eleven years, but had never been pregnant. There was no history of syphilis or former skin disease. She complained of "dead" and cold fingers, and the hands were said to be often blue. The lesion on the cheek is nearly circular in outline, with a fairly sharp definition, raised slightly above the surface and quite succulent. Grasped firmly between the fingers there can be detected quite deep infiltration. There is a slight sinking in at the center, suggestive of beginning atrophy. Around the periphery extending a little into the patch are numerous fine telangiectases. The color is a very light red with tendency to become pale in the center. The patch is perfectly smooth, being entirely devoid of scales. The patient complains of a burning sensation. The lesions on the fingers are small purplish red elevations or nodules, with a distinct depression in the center resembling somewhat the papules of syphilis. Most of these lesions occupy the flexor surfaces, though a few are present on the backs of the fingers. There are no subjective symptoms. The circulation is very poor, the hands and fingers are cold and persistently congested much of the time. Fifteen years ago her ears were frozen, and now present a notched condition as a result of it.

Dr. Lustgarten said he was under the impression that the cheek was the seat of a gummatous infiltration. He would exclude scleroderma and lupus erythematosus. The lesions on the fingers were lupus pernio, and were probably entirely independent of the lesions on the face, and due to the cold weather.

Dr. Bulkley thought the lesion on the cheek and that on the finger were of the same nature. He was not disposed to think the cheek lesion specific. Lupus erythematosus was commonly observed on exposed parts, and this was his diagnosis.

Dr. J. A. Fordyce took the same view as the last speaker. He thought it would be unusual for a gummatous infiltration to remain for nine months without undergoing some change, such as ulceration or absorption. He had seen types of lupus erythematosus which conformed to the appearances in this case. There was, however, a resemblance to a gummatous infiltration, but the objection to this view was the long duration.

Dr. Morrow said he would not be inclined to accept the diagnosis of gummatous infiltration from its duration and general appearance, but would rather consider it as a beginning morphœa. He had watched the evolution of patches of morphœa, and believed that in almost all cases there was hypertrophy followed by atrophy, condensation of the tissues and the characteristic whitening. The lesions on the hands he took to be chilblains, particularly as they had only developed since the cold weather began.

Dr. Allen believed that the lesions on both the face and arms were lupus pernio. The lesion on the cheek was similar to a case which he had

seen and studied very carefully. In that case the lesion had existed for even a greater length of time, and at times it almost disappeared so far as the tumefaction and redness were concerned. The patient here this evening stated that in cold weather the patch assumed a blue color, which, he thought, rather characteristic of lupus pernio.

Dr. H. G. Klotz said that he also would make a diagnosis of morphœa. A gumma might exist for this length of time without breaking down, but it would present a different color, and not show such telangiectases as he understood were here visible.

Dr. G. H. Fox thought the lesion on the cheek to be quite distinct from those on the hands. He did not recall having seen pernio on the cheek, nor had he seen morphœa or lupus erythematosus with the solidity of the deeper tissue presented in this patient. Gummatous deposits were often seen in the cheek, and the fact that it had remained for nine months without anything but an erythema of the skin was nothing unusual in the case of a gumma of the skin.

Dr. Whitehouse said that the patient came under his observation yesterday for the first time. His first diagnosis was that of morphœa. The blood-vessel-formation around the periphery was quite marked. Morphœa might have almost any color at the beginning, the old-ivory tint developing subsequently. The lesions on the fingers, however, made the case still more interesting. These, he felt, were undoubtedly lupus pernio, and the patch on the cheek he was still inclined to think was morphœa. The case bore some resemblance to one of lupus erythematosus which he had presented to the society some months ago. The chief point of resemblance was the amount of infiltration. He would expect more lesions with more symmetrical distribution upon the face in the case under discussion if it were lupus erythematosus. He would give the patient mixed treatment for a time in view of the opinions expressed in regard to the case.

Severe Acne Treated by the X-ray. Case by Dr. C. W. Allen.

The patient was a young man who, on coming under observation, was suffering from keloidal acne of long duration. Nearly every one of the severer lesions before disappearing turned into a pseudo-keloid. All of the active lesions had disappeared under about eight applications of the X-ray in a period of about six weeks. After the X-ray had produced a major part of the cure a little sulphur lotion had been applied.

Dr. Fordyce said that the result was certainly very encouraging, but he thought as much could be accomplished by surgical measures, such as opening the abscesses and applying scaling pastes without the risk attendant upon the X-ray treatment. For the keloidal condition the X-ray was probably the best treatment, but in some of these cases of acne there was an induration which often disappeared spontaneously.

Dr. Bulkley said that he had been using the X-ray in some cases of acne merely as an adjunct, and he thought it had hastened the absorption of certain lesions. He did not think there was any very great danger from this treatment if conducted with reasonable care and skill. He had never caused any severe burn by the X-ray. He was treating a case of keloid following an operation upon the face. The keloid had steadily melted down under the X-ray, the exposures sometimes being repeated as often as two or three times a week. The result was already very gratifying, and he knew of no other way by which this could have been achieved,

Dr. Lustgarten said that in view of the very marked inhibitory influence of X-rays on hair, and in view of the near relations between the hair and the sebaceous apparatus, there was reason to suppose that the X-ray would have a controlling effect on diseases of the sebaceous glands. He would expect seborrhoic conditions, comedo, certain severe forms of acne, etc., to be favorably influenced by the X-ray, but his personal experience in this direction was still limited.

Dr. Fox said it was very evident that there had been marked improvement effected in this case, though he thought the same could have been accomplished by surgical or other active treatment. The folliculitis which often occurred on the back of the neck was, in his opinion, very different from a dermatitis papillomatosa. Reference was made to a young man with this condition, who presented several large tumors on the back of the neck. One tumor was excised and grew rapidly. Injections of carbolic acid were made for a year without the slightest improvement. Under the X-ray, however, the case improved steadily. At one time, the hair was taken off from the occiput, but it had grown in again. He had seen this man very recently, and the tumors were practically gone. He hoped soon to show him as perfectly cured by the X-ray treatment. He had seen many cases of epithelioma and lupus which were claimed to have been cured by the X-ray treatment, whereas they had only been improved; but he was certainly quite enthusiastic over the effect of the X-ray on keloids. In another case, occurring in a negro, some improvement had been effected.

Dr. Allen said that the lesions at the back of the neck which he had referred to were not those now apparent, but lesions within the hair line. There were large comedoes and abscesses, and acne papules and pustules and a keloidal elevation running transversely. He called the whole condition a keloidal acne, a term which was also applied by some to the condition usually called by us dermatitis papillaris capillitii. All of those had practically disappeared. In many cases of acne in which he had used the X-ray as an adjunct to other treatment in fat, flabby girls of indolent habit, having an excessively oily skin, especially of the region about the nose, the effect of the ray had been almost magical. He knew of no other external application or internal treatment which would do

for these excessively active and hypertrophic glands what the ray would do. On the other hand, he would dislike very much to rely upon the X-ray alone.

Lupus of the Knee. Presented by Dr. J. A. Fordyce.

The patient was a boy of fourteen years, with an atrophic condition of the skin covering the left knee. The scar tissue which involved five or six square inches, was soft, pliable, and free from any evidence of disease with the exception of perhaps a dozen small brownish-red lupus tubercles, each of which was slightly larger than a pin's head. The skin affection had existed for about eight years, and at one time was elevated and encrusted. It had been growing steadily better without treatmant and now there is no evidence of the disease excepting the scattered nodules and the scar tissue. He had on his hand a small patch of lupus verrucosus.

Dr. Bulkley accepted the diagnosis of lupus, but thought it unusual to see so many small points.

Drs. Lustgarten and Whitehouse concurred in this diagnosis.

Dr. Allen thought lupus was rather common on the knee in children. He had seen quite a number of such cases at the Good Samaritan Dispensary, and it had occurred to him that possibly they were the result of local infection from the children creeping around on the tenement-house floors. It was known that lupus of the ear was very common because of infection from moistening with saliva the thread passed through the ear in the process of ear-piercing as practiced *en famille.*

A Case of Psoriasis Developed on a Seborrhoic Skin Showing the Effect of Treatment by the X-ray. Presented by Dr. Mewborn.

The case is presented as showing that while the X-ray may clear up a psoriasis, yet in this case, the resulting alopecia is perhaps more disfiguring than the lesions for which radiotherapy was employed. The patient is a well developed man of twenty-five years of age who first came under my care in the latter part of August, 1900, on account of an eczema seborrhoicum psoriasiformis almost limited to the regions described by Sabouraud as *"the primitive axial areas of seborrhoic infection."* To particularize:—on the scalp there was an excessive amount of furfuraceous scales on a reddened base; on the chest and back the patches were polycyclic in contour, red, and in places raw from a too vigorous scrubbing. The most annoying patches, on account of the disfigurement, were on the forehead, chin, neck, back of ears and between the eyebrows. The scrotum was affected with a scaly, fissured, eczematous condition. There were no lesions on the elbows or knees, but on the back there were, scattered over the seborrhoic areas, numerous distinct papules of psoriasis. Under treatment with oil of cade for body and a white precipitate ointment for the face, the skin was practically free of lesions in December. In February, 1901, there was a slight return around the scrotum and penis, which was

so obstinately persistent that circumcision was performed. The rest of the body remained free of eruption until January, 1902, when he returned with an eruption occupying nearly the same regions as the attack of 1900-01. Tar preparations failing to show any effect, a strong chrysarobin ointment was used until a severe dermatitis was produced on the back. Under this treatment not only were the existing lesions blanched out, but where there were no lesions a number of unstained white patches revealed themselves by the striking contrast with the surrounding brownish discoloration of the normal skin. As you may observe by comparing the photograph of the back taken in November, 1900, and a photograph of the lesions present in 1902, the scattered isolated patches in the first attack were not present in the second. The third photograph taken during the attack of chrysarobin dermatitis, reveals as unstained areas the blanched out lesions of the 1902 attack as well as the scattered patches which can be readily identified as belonging to the lesions of 1900. There must, then, be produced by the psoriatic lesions some more or less permanent modification of the skin's susceptibility to chrysarobin staining, which would *cause it to act like the image on an exposed photographic plate under the influence of a developer:*—in this case the *developer being the chrysarobin dermatitis.*

The patient was entirely free of eruption until the following spring. In July, 1903, he returned for treatment with an eruption of about the same distribution as in the former attacks, but the lesions were much more infiltrated and the scales were more micaceous. In addition to an ointment of chrysarobin, he was given five centigrams of sodium cacodylate hypodermically for twenty days. In August, when the patient stopped treatment, there was present only a small amount of papulation around the margins of the lesions on the back. In September there was a return of the eruption and he went to Portland to be treated by the X-ray. He states that he was exposed daily for ten minutes at a time at a distance of ten inches from the target of a focus tube actuated by a static machine. In one week the head was much better. Treatment of the scalp was stopped after twelve exposures and one week later the alopecia occurred, which you now see covering an area the size of the palm. The face is remarkably smooth and free from its former seborrhoic condition, in fact, aside from slight freckling, is very dry and clear. The scrotum, which was thickened and red, is now supple and healthy-looking. The back, although showing evidences of a severe desquamating dermatitis—a mild X-ray burn—has almost cleared up. While the result of radiotherapy in this case may seem favorable the permanence of the favorable result attained is very doubtful and we can only hope, for the patient's sake, that the disfiguring alopecia shall not be permanent. In any case, just as good results in a reasonable length of time can be attained with much safer remedies. Furthermore, there is a danger of producing sterility in X-raying the testicles, as shown by the interesting experiments of Albers-

Schönburg (Münch. Med. Woch., 1903, XLII, p. 1860), Schönburg X-rayed the testicles of five rabbits and six guinea pigs for varying periods of time. These X-rayed males were paired off with females and kept under observation for a number of months. Although their capacity for copulation did not seem impaired, in no instance did impregnation occur. It was not the fault of the females as several had already borne young by unexposed males. A microscopical examination of the testicles and seminal vesicles showed complete absence of spermatozoids in all the males exposed to the X-ray for 377 minutes and longer. In one animal 195 minutes of exposure caused necrospermia.

Dr. Allen said that two years ago he had shown to the society a case of psoriasis treated by the X-ray. The effect was quite as marked as in the case now under discussion. He believed that psoriasis was here present. He wished once again to utter a word of caution against the X-ray operator's needlessly exposing himself to the ray. He had just come from a meeting of X-ray workers, and had been astounded at the large number of those present showing lesions resulting from such exposure. From what had been said about the experiments on rabbits he thought it would be well to be cautious about exposing the testicles to the X-ray lest it might result, as in the rabbits, in producing sterility. He was careful about exposing the immediate precordial region, the solar plexus and the brain to the action of the X-ray.

Dr. Morrow said that there was no doubt that the lesions on the back had cleared up under the X-rays. Probably an equally good and more prompt result would have been obtained by the use of chrysarobin or tar preparations. One of the results of the treatment in the case under discussion was the loss of hair on the back of the head, and while it was probable that the hair would return, this was not certain. This case seemed to him an excellent argument against the indiscriminate, and, in his opinion, unjustifiable application of the X-ray to certain dermatoses which could be cured by simple and harmless remedies. A patient had been brought to him a year ago with acne, and had been cured by simple means, but last summer the acne having returned while the patient was out West, he was subjected to a long course of X-ray treatment. This indiscriminate use of the X-ray, the speaker thought, had done more than anything else in the last twenty-five years to discredit dermatology. The use of the X-ray was, of course, perfectly justifiable in cases like those of keloid described by Dr. Fox, and in cases of lupus, epithelioma and malignant growths generally.

Dr. Sherwell said that as these cases were usually so easily cured by well-known remedies and applications there seemed to be no need for the X-ray. He thought, moreover, the result would be obtained just as quickly and far more safely.

Dr. Fordyce said that he had seen this patient fifteen years ago, at which time there was no involvement of the body, but a typical seborrhoic

eczema of the scalp, which disappeared under pyrogallic acid ointment.

Dr. Bulkley said that although he was using the X-ray daily he was heartily in sympathy with those who had so severely criticized the indiscriminate use of this powerful agent in many affections which could be just as effectively treated by simpler and safer means. It was an excellent adjunct to ordinary methods of treatment.

Dr. Lustgarten said he would indorse what Dr. Allen had said about the possibility of doing harm to the vital organs. Certain manifestations of psoriatic conditions were excellent for the use of the X-ray. It was especially useful upon the hands, and while, in all probability, the result was not permanent, it was quite satisfactory and superior to older methods. There was a form of psoriasiform eczema, found on the hands mostly of middle aged, corpulent and arthritic people, which was very obstinate to ordinary treatment, and which yielded better to the X-ray than to anything else. The same was true of the psoriatic form of eczema around the anus, and accompanied by intense itching. Five or six exposures of five minutes each would often effect a cure in such a case.

Dr. Fox said he was extremely interested in the photographs exhibited by Dr. Mewborn in connection with his presentation of this case. Long ago, a man had come to him with an obstinate psoriasis, which had been treated by a strong chrysarobin ointment. The last time he saw the man he found a number of other white disks on the back, which he could not account for until he discovered that they undoubtedly marked the patches of psoriasis of a previous year. At the time this point was entirely novel to him, so that he was glad that this had been corroborated by the photographs just presented. It was very singular that even after the skin had apparently returned to its normal condition, these patches remained for at least a year or more immune to chrysarobin staining.

Dr. Mewborn, in closing, emphasized the fact that just as good results had been obtained in this patient by various older methods. At first, tar preparations were used, and in six weeks the skin was cleared up. With each recurrence of the eruption it had been more of a psoriatic type. On one occasion the patient was directed to expose himself to the sun on the seashore. The result was a considerable improvement in the patch on the forehead. Hyde made the statement that because he had found sunburn so useful he had been led to treat these cases with the X-ray.

Lupus of Cheek Treated by Radium. By Dr. L. Duncan Bulkley.

The patient was a boy of twelve years, who had had lupus of the left cheek ever since babyhood. Various mild treatments had been tried, but no scraping or burning. He had been first seen by Dr. Bulkley on November 5, 1903, and he had had the radium treatment fourteen times. The exposures at first were only five or six minutes, but this had been gradually increased until the last two exposures were thirty minutes each.

The exposures had been made every other day, but as yet there had been little, if any, effect upon the lesions.

Dr. Bulkley also showed a photograph of a boy about the same age with a lupus of the cheek. He was cured in Copenhagen by three applications of the Finsen light.

Dr. Fox said he had been using radium, but it was too early yet to say what the final result would be. He was not over sanguine, however, regarding it.

Dr. Allen said that for some time he had treated a similar patch of lupus with the ultra-violet light, using Dr. Piffard's lamp, and had almost cured it when the mother became ill and was unable to bring the child for further treatment. He had learned since then that the patch had almost completely disappeared.

Dr. Sherwell remarked that he thought he could cure the case by active curettage and the application of acid under anæsthesia.

Dr. Bulkley said he appreciated the fact that one or two curettages would remove the disease, but he had presented the case with the object of showing what might be accomplished by the new radium treatment.

Dr. Fox said he would not think of using curettage in such a case, because the nodules were separate, and the tops would simply be removed and there would be a relapse. If, however, a dental burr dipped in carbolic acid were used, a permanent cure would be effected.

Lupus of Left Submaxillary Space Treated by the X-ray.. By Dr. Bulkley.

The patient was a young lady (previously shown before the society) who had had lupus nearly all her life. She had had thirty or forty applications of the X-ray since April 28, 1903, and at present there was a considerable superficial burn that had been purposely produced.

Dr. Allen remarked that it was proper to attempt to produce a decided reaction, and he had done this at times at the second or third sitting with much benefit, so that one burn effect almost cured the disease.

CORRESPONDENCE.

To the Editor of The Journal of Cutaneous Diseases.

Dear Sir:

In the review published in your January number of the first volume of my work on the "Internal Secretions and the Principles of Medicine," Dr. Graham Lusk overlooks two important statements emphasized in the Preface (pp. xiii and xx), (1) that the element of specificity is by no means lost, though drugs more or less actively stimulate the pituitary body—the governing center of the adrenal system, and (2) that the subject of Pharmacodynamics, which includes the specific action of drugs, forms part of the—as yet unpublished—second volume. All the questions embodied in Dr. Lusk's review being fully treated in the latter, I must request your readers to await its appearance before deciding whether the experimental evidence to which he refers in any way conflicts with my views.

Respectfully yours,

C. E. De M. Sajous.

REVIEW
of
DERMATOLOGY AND SYPHILIS

Under the Charge of JOHN T. BOWEN, M. D.

INFLAMMATIONS.

BY H. P. TOWLE, M. D., BOSTON.

Eosinophilia in Infantile Eczema. VERNET. *Compt. Rend. Soc. de Biol., Paris,* 1903. LV.—557.

The author gives tables of blood counts in three cases of eczema in infants. He concludes that eosinophilia is as marked in the new born attacked by eczema as in adults. In one case the eosinophiles were increased long before the appearance of the cutaneous lesions. Whenever the eosinophiles increased, in spite of apparent improvement in the cutaneous lesions, the improvement was only temporary and was followed soon after by a new outbreak of eczema. In one case with an increase in the eosinophiles he noted the appearance of "granulation acidophiles."

Eczema, The Modern Conception of. J. A. FORDYCE. *Jour. A. M. A.,* June 13, '03, p. 1621.

This article is a plea for the more careful investigation of the cause of eczema. The author believes that if such careful search be made, local causes can be found to explain the case. He says that the modern tendency is to call all inflammations of known or apparent cause dermatitis and those where the cause cannot be ascertained eczema. The author, however, objects to this because all people do not act alike to irritants and further a dermatitis may spread peripherally, develop secondary patches or become generalized after the irritant is removed. It is however a convenient distinction for teaching purposes. Clinically the picture may be the same in both dermatitis and eczema. Admitting that, we have good ground for assuming that all such conditions may have a local cause. The general conditions may be a factor in preparing the tissues for an attack by lowering their power of resistance.

Eczema—Regarded as a Cutaneous Reaction. BROCQ. *Ann. de Derm. et Syph.* March, '03, p. 77.

The author in this article writes only of vesicular eczema. After speaking of the uncertainty in regard to the etiology and pathology of eczema he goes on to say that "if clinical facts are analyzed we find that eczema sometimes follows external irritations, sometimes divers intoxications, auto-intoxications, organic diseases, etc. It follows that all of these

conditions play causative rôles only occasionally." He then brings out the point that "each individual reacts in an individual manner to various influences and it may be in different ways at different periods of his life." These reactions he calls the morbid reactions. They are not like a fixed disease and have no fixed symptomatology. They have but one element by which they can be grouped—the objective appearance. In the case of eczema he selects a vesicle as being pathognomonic, whether this be pronounced or whether it be in a measure abortive and almost histological. He is disposed to regard the true vesicular eczema as a pure cutaneous reaction. The various theories advanced to explain eczema, and particularly the microbic theory, he holds explain nothing. The cutaneous reaction theory for eczema, however, is a theoretical hypothesis which is perfectly possible and logical, which agrees with clinical facts and allows us to understand them. It does not overthrow the microbic theory but is only a mode of interpreting clinical data. He then repeats that all the causes which are given to explain an eczematous eruption are not in reality the provocative causes but the secondary agents which determine the outbreak or explosion. "We must therefore seek elsewhere for the *primum movens* perhaps in the chemical modifications of the tissues and liquids of the economy. There is therefore no eczema but an eczematisation."

Empyroform, a New Tar Preparation. Alfred Kraus. *Prag. Med. Wchensch.*, 1903, August 13.

Kraus reports on the results obtained at Pick's clinic in Prague with empyroform, a new tar preparation manufactured by the Actien Company in Berlin.

It is a fine, dark gray powder produced by condensation of oleum rusci and formaldehyde. It does not have the odor of tar and would not be taken for a tar product. It is not hygroscopic, it does not dissolve in water, alcohol or ether; it is soluble in aceton, caustic alkalies and chloroform. It produces no bad effects, it is antipruritic and of therapeutic value in chronic eczema and in other conditions, and it is best used in the form of an ointment.

℞

Empyroform, 5.
Lanolin.
Vaseline, aa, 50.

Erythema Exudativum Multiforme, Chorea, Rheumatismus Nodosus, Endopericarditis. Hohfeld. *Berl. Klin. Wchnschr.*, 1903, xl, 701.

Hohfeld reports this case with the above diagnosis with a view to adding something to the knowledge of erythema multiforme. The case was that of a boy of nine. Four weeks before, a red and itching eruption had appeared on the abdomen and back with fever. Thence the eruption had

spread over the whole body, forming ringed figures. Two weeks after the outbreak upon the skin restless movements of the left hand were noticed. Seven days later movements of the whole body began so that the patient could neither stand nor walk. For eight days the left hand has been swollen and tender. The eruption on entrance was everywhere over the body, pale, red, circular, slightly raised spots varying in size from a pea to the palm. The center was often paler and depressed while the edge was wall like. The redness disappeared on pressure. Chorea present. Cardiac lesion also present. Urine negative. The eruption disappeared within a week. The other symptoms grew graver, until 18 days after entrance death followed.

Erythema Nodosum. Kuhn. *Archiv. f. Kinderheilkunde.*, XXXVI 3-6, p. 195.

The author begins by saying that there has been and that there still is much discussion of the relationship of erythema exudativum multiforme to erythema nodosum. Willan, who first used the name erythema nodosum, considered the disease to be a variety of erythema exudativum multiforme. Kuhn then reviews the opinions held by various men both for and against this conception. Continuing he states that Lewin wished to include erythema nodosum among the eruptive fevers. Bäumler asserted that in many cases the disease was of an infectious character which assertion has been supported by other men. Cases have also been reported which seem to show that that the disease may be contagious and Kuhn quotes Mousson, Heim and others in support. Several authors have reported finding a micrococcus or bacterium which was morphologically similar to staphylococcus pyogenes alba and which they believed to be the cause of the disease. The author has searched each of his cases for bacteriological cause but without result. In one case only was an organism found. The organism grew like staphylococcus pyogenes citreus but Kuhn laid no stress upon this. Rheumatism was advanced as a cause of erythema nodosum as early as the 17th century and since then the connection between the two has been noted many times. Against this theory, says Kuhn, are Mackenzie's figures who in 1866 reported 108 cases of erythema nodosum among which there were only 17 associated with rheumatism. In the 22 cases reported by Kuhn himself two had pains in the joints but neither case showed any objective changes. Of these two cases one died later of tubercular meningitis, the other never had any further rheumatic symptoms. Heart trouble was more frequent but this he does not attribute to rheumatism but to the infection as such. In seven cases he noted quick attacks of endo- and myocarditis all of which however passed off without doing permanent injury. Since Uffelmann's paper in 1892, the relationship of erythema nodosum to tuberculosis has been much discussed. Uffelmann found a strong tubercular family history in all but two of his cases. Oehone went further than this and asserted that

erythema nodosum was the first warning of tuberculosis. Kuhn states in comment that according to their experience at the hospital although tuberculosis may follow erythema nodosum there are no grounds for considering the affection to be the forerunner of tuberculosis.

Kuhn believes that erythema nodosum should be classed with erythema multiforme. He divides erythema nodosum into a symptomatic form and an idiopathic. The disease he assigns to the infectious diseases, especially those occurring in childhood. The symptoms he divides into four groups. 1—Incubation, at most 12 days. 2—Invasion (indefinite pains, gastro-intestinal disturbances, fever). 3—Eruption. 4—Convalescence. Two of his cases were preceded by angina. None was feverless. The fever lasted not over three weeks, was slightly remittent and usually fell by lysis. The duration varied from eight days to four weeks. As to the sequelæ, in no case did the heart affection fail to clear up entirely. As to complications, two cases had slight albuminuria and one a neuritis.

Lichen Planus, Notes on the Treatment of. Zeisler. *Jour. A. M. A.*, June 13, 1903, p. 1636.

In a generalized eruption of lichen planus the author would resort to arsenic in the form of Asiatic pills or as Fowler's solution. Owing to the occasional failures of this treatment he also gives prominence to hydrotherapy after the French manner. The patient remains in a tepid bath for 10-15 minutes. Then, by means of a hose, the spinal column is irrigated with water, at first lukewarm, but gradually becoming cooler. Finally comes a general sponging and a half hour's rest. The author has also seen good results follow the use of the protoiodide of mercury. As an adjuvant he usually prescribes an alkaline water. The obstinate hypertrophic forms he now invariably treats with the X-rays.

Pityriasis Rosea, an Erythematous Eruption of Internal Origin. Weiss. *Jour. A. M. A.*, July 4, 1903, p. 20.

Weiss chose this subject for his address before the Dermatological Section of the American Medical Association. After a few introductory remarks and a historical sketch of the disease and the views as to its origin held by various authors, he goes on to say that the frequent coincidence of pityriasis rosea with gastric disturbance can no longer be ignored or looked upon as accidental. The sudden outbreak, the character of the eruption, its non-contagiousness, its cycle course, diffuse distribution, the mode of its appearance and its rare recurrence, he looks upon as evidence that the disease is of endogenous origin, most probably transmitted to the skin by autointoxication. The author thinks that the teaching of general pathology that the propagation of disease in the system is due to pathogenic substances carried through the blood, is not given due weight in dermatology. This theory explains the lesions of pityriasis

rosea. The irritative substance on its way from the blood to the surface becomes attenuated. The deeper strata of the skin will, therefore, be the first attacked and the main lesions will be found there. If the disease were of mycotic origin, he argues, the external irritant would invade the upper layers of the skin first and the main lesions would be found at the surface. In pityriasis rosea the case is clinically mild, but histologically the main lesions are found in the lower strata. He cites four cases, all of which had gastric symptoms preceding the outbreak. Microscopically no fungi were found. The main histological lesions were in the cutis. A pathognomonic sign he gives as follows: Upon scratching a recent and not yet scaling patch with the finger-nail some scaling can invariably be produced in its center, even although there was apparently not the slightest indication of such scaling. Another aid to diagnosis is the herald patch which appears about two weeks before the general eruption.

Pityriasis Rubra (Hebra). Tschlenow. *Archiv. f. Derm. u. Syph.* Bd. LXIV, Heft I.

The author begins his article with an exhaustive discussion of the question as to whether pityriasis rubra (Hebra) should really stand alone or not; its relation to dermatitis exfoliativa (Wilson), erythéme scarlatiniforme récidivante and to dermatitis exfoliativa neonatorum. He also gives Jadassohn's list of cases, which, in 1892, numbered only forty-three and then adds three of his own. His three new cases are given in detail with the histological findings in two of them. With the aid of these two cases he concludes that it is now possible to trace the process of the disease from the beginning to the end. These changes he gives as follows: 1. Loosening of the horny layer in the form of small plates and the presence of nucleated cells. 2. Marked diminution and, in places, complete disappearance of the horny layer. 3. Thickening of the rete in the early stages and thinning in the later. 4. Increase of mitosis in the rete at the beginning of the process. 5. Few leucocytes in the rete. 6. Diminution or complete disappearance of pigment in the basal layer. 7. Unimportant small celled infiltration in the papillary and subpapillary layers and here and there in the cutis. 8. Increase in the normal connective tissue. 9. Moderate increase in mast cells. 10. Marked amount of pigment in the cutis, part free, part lying within the cells. 11. Vessel changes. 12. Marked atrophy of the skin in the further progress of the disease. He sums up as follows: The creation of a group of pityriasis rubra (Brocq), or a group of erythrodermies exfoliantes (Besnier) is not scientifically correct. Pityriasis rubra (Hebra) has its own and its clinically characteristic form. Dermatitis exfoliativa (subacuta) (Wilson-Brocq), also has its own distinct form. Erythéme scarlatiniforme récidivante is, in many cases, identical with the so-called drug eruptions. The clinical picture of pityriasis rubra (Hebra) shows certain variations

from the original as described by Hebra, yet corresponds in general. The histological changes consist of a primary affection of the epidermis with secondary inflammatory changes in the cutis which, in consequence of the long course of the disease, lead to complete atrophy of the skin. As yet no theory has been put forward which explains the etiology satisfactorily. The prognosis in general is unfavorable, but is less so than Hebra thought.

LEPROSY.

By Isadore Dyer, M. D., New Orleans.

Red Mangrove Bark in Leprosy.

In 1899, P. Guichard, of Key West, a druggist, called attention to the use of this remedy and Dr. A. Moreno employed the several preparations of the bark, relating excellent results as a consequence. Except for some newspaper notoriety, little attention was paid to the report, coming in an irregular way. Within the past two years, however, Drs. Duque and Alfonso, in Havana, have given the watery extract, and one case at the San Lazaro is held as cured after this treatment. In the treatment, Duque with Moreno, believes that the effects are evident in early cases in from six to ten months; later cases improve, but cure is not established. The preparations employed are a watery extract of the red mangrove (*rhizophora mangle L.*) bark, a dried extract after percolation, and salves made from powdered bark. The powder itself is employed in the baths. Ten grammes of the extract are given night and morning, with a daily increase until 80 to 100 grammes are taken each day.

Duque is quite enthusiastic over the treatment, but no results have been published yet.

A series of cases at the Louisiana Leper Home were put on dried extract of the mangrove bark in 1899 and this treatment was maintained for nearly two years, without result. It is fair to say, however, that there was no systematic observation of the cases at that time, and the treatment may have been irregular.

It is proposed to essay a new set of cases, under strict observance of the Havana régime, both as to medication and bathing, as well as diet. (From Personal Correspondence—D.)

The Louisiana Leper Home within the past year has materially improved its facilities for the care of the inmates. Several raised cottages have been erected, each with modern hospital furniture, sanitary closets, bathing facilities with hot and cold water, as well as steam heat. When it is considered that the home is on an isolated plantation, removed some eighty miles from New Orleans, and about four miles from a town, this is a creditable achievement.

Leprosy in Russia. Since April, 1902, Russia has defined the status of the leper in his relation to the public: Commissions composed of a medical inspector and not less than two medical men, informed in leprosy, are appointed to investigate the patient both as to his physical and sociological conditions. Domestic segregation is allowed under governmental inspection and regulations. Specific and plenary power is given this Commission to determine the contagiousness of each case. A patient detained in a leper asylum, believed to be no longer infectious, may return to his home after examination and discharge by the Commissioners.

In a running commentary upon the attitude of the government, and with a view to explaining the present status, Dehio, of Dorpat (*Lepra,* Vol. 4, fasc. I) relates the work done in the leprous centers of Russia, by Muench, von Wahl, Wellburg, Paulson, Hellat, and von Bergmann. Von Bergmann carefully demonstrated about 60 per cent. of recorded cases as having lived or intimately associated with lepers. V. Riessen related that nineteen cases had originated in an almshouse at Riga from four who were admitted as lepers. At Oesel, Lohk ascertained the restriction of leprosy to centers more densely populated.

A very interesting point is brought out by the writer who relates that of forty-eight cases of nodular leprosy, in thirty-six probable contagion could be traced, from which other cases had spread; in thirteen cases, two mixed and eleven anesthetic, not a single case of infection could be traced. Hansen and Looft were quite explicit in declaring that the maculo-anesthetic forms have less bacilli than the nodular, and that they carry no bacilli in the secretions, while in the nodular form the bacilli are nearly always present in the secretions. Dehio marks this point and states his position very clearly: "Nodular leprosy is an infectious disease, whereas maculo-anesthetic leprosy is caused by infection through the *bacillus lepræ* or the leprosy virus, but is not itself, or only in slight degree, contagious."

Dehio voices a rather general opinion when he says: "The higher a nation stands in intellectual and material respects, the sooner it will be possible to leave the lepers to home supervision and nursing; the dirtier and less civilized a nation is, the oftener will it be necessary to remove lepers from among their fellows and to segregate them in leper asylums to check the spread of infection among the masses."

Hawaiian Leprosy. Doland, *Journal Am. Med. Assn.,* Nov. 7, 1903, in an interesting paper on the leper settlement of Molokai concludes that the Hawaiian is particularly susceptible and that syphilis is a predisposing cause. He acknowledges the *bacillus lepræ* as the cause of the disease, which he holds as feebly contagious. Heredity is a factor, but of small importance. There is no cure, in his opinion, and the care of lepers should be based upon hygiene, baths and antisepsis.

Leprosy Is Curable in the earlier stages, says Filaretopoulo, of

Athens (*Journ. des Mal. Cut. et. Syph.*, Jan., 1903; *Brit. Journ. Dermat.*, Sept., 1903). The treatment indicated is with mercurial injections and chaulmoogra oil, up to three hundred drops a day. Hygienic and dietetic regulations must be enforced. The writer is quite emphatic in the belief that the disease is hereditary and rarely contagious. The offspring of leprous individuals either derive immunity, or there is contamination direct or indirect, giving rise to tubercular leprosy in the first instance, or to local trophic lesions or "para-hereditary" leprosy; direct contamination implying infection with the lepra bacillus, indirect with the toxins of the bacillus. This view justifies the author in grouping general leprosy and local leprosy as the forms of the disease arising from the bacillus or the toxins, respectively, the latter form being an abortive type which is "never contagious." The abortive forms are not to be isolated.

The Leper Lazaretto at Tracadie, New Brunswick, has nineteen patients, twelve males and seven females, one having been admitted in 1902.

Leprosy in the United States. The centers of leprosy in the order of their numerical importance in the United States are the following: Louisiana, New York, California, Florida, Minnesota, North Dakota, Texas, Mississippi, Illinois, Missouri, Wisconsin, Massachusetts, Alabama, Pennsylvania, Georgia, Ohio, Iowa, Maryland, Montana, Nevada, Oregon and South Dakota, or twenty-two known foci of possible infection. Louisiana alone has a leper home and, excepting in California, New Jersey, North and South Dakota, there is no attempt at care of these cases.

A bill was introduced at the last Congress by Senator Platt, of New York, aimed at the control of leprosy, but it has so far been buried in Committee. The important features of this bill are the following: A leprosy commission; one or more national asylums; the appropriation of fifty thousand dollars for buildings for the habitation of lepers, not including the Hawaiian Islands, Porto Rico, Anam, or the Philippines; provisions for the transportation of lepers; the injunction of the importation of lepers; supervision of suspected immigrants of leprous families.

The Public Health and Marine Hospital service is to have full charge of such homes if established.

RADIO-THERAPEUTICS AND PHOTO-THERAPEUTICS.

By W. A. Pusey, M.D., Chicago.

The Effect of Becquerel Rays upon Tissues. Halkin. *Arch. f. Derm. u. Syph.*, 1903, LXV, p. 201.

Halkin has used guinea-pigs and young pigs for experiments to determine the action of the Becquerel rays on the skin; the cutaneous structure of the latter corresponding very closely with that of the human skin. A certain spot on one side of the animal corresponding in size to the cap-

sule containing the radium was exposed one hour on alternate days, and another spot on the other side of the animal was exposed two hours on alternate days; and the areas were then excised for examination at varying intervals. Where the exposure was for two hours on alternate days there developed after eight days a diffuse somewhat livid color, disappearing under pressure, which later became sharply defined at the periphery. After twenty-five days the macroscopic effects were most marked. The surface was livid, with a bluish tinge, with some yellow pigmentation covered with numerous scales. In the center there was a mild inflammation with a small dry crust. The periphery was still sharply defined from the unaffected skin. In thirty-eight days the area showed only diffuse pigmentation and a few scales. The areas which received only one hour every other day showed the effect first after fifteen days and did not at any time reach the degree of severity of the others.

Microscopically there was no change from the normal one day after exposure. After three days the first changes were evident, consisting of increased prominence of the capillaries of the upper part of the corium. After five days the capillaries were noticeably dilated but there was no change visible in their walls and no surrounding infiltration. After several days a slight infiltration was visible around the vessels and some leucocytes in the connective tissue, and all the capillaries and small vessels were much dilated and filled with blood. The cells of the intima were swollen and their nuclei were larger than normal. As yet no change had appeared in the epidermis. Twelve days after the first exposure the changes in the vessels were still more marked; there was much degeneration of the cells of the vessel walls which were markedly vacuolated and some of them had dropped off into the lumina. Pigment cells in the corium were much more numerous than normally. In the center of the affected area the connective tissue of the corium was degenerated; there was marked vacuolation of the cells, in some of which both protoplasm and nuclei were broken up into fragments; the connective tissue was infiltrated with leucocytes. The entire palisade layer of the epidermis was filled with vacuolations, which were present in the cell bodies. The protoplasm stained with difficulty, the nuclei were fragmented, and the boundary between the epidermis and the cutis was indistinct. A few leucocytes were present in the epidermis. After twenty days there was present a condition of ulceration. The horny layer of the epidermis was raised up, was broken into flakes and contained some nucleated cells. The rete Malpighii had almost entirely vanished, being represented by only one or two rows of irregularly swollen cells with faintly stained nuclei. The only remains of the palisade layer was a mass of cell remnants and fragmented nuclei. There was much more pigment present than normally, lying among the fragmented cells. The corium presented the changes already described, in a more advanced degree. There were

only a few leucocytes to be found in the exudations. The hair follicles showed these same degenerative changes as the epidermis, but to a less marked extent. After twenty-four days the dilatation of the blood vessels was advanced to such an extent that they were represented by large spaces through which hæmorrhage had taken place into the tissues.

From this series of observations it is evident that the Becquerel rays affect at the same time all the elements of the skin,—epithelium, connective tissue and blood vessels. The effect on the blood vessels appears first, but it is not to be looked on as the cause of the other phenomena, and still less as the result of an inflammatory process; but rather the result of a lessening resistance of the vessel walls through some sort of paralysis. The effects of Becquerel rays are altogether very similar to those of Roentgen rays.

Halkin has also exposed areas of lupus tissue to the Becquerel rays. Only after prolonged exposure, two hours each day for nineteen days, was any considerable microscopical effect obtained. Here both in the normal and in the lupus tissue there was cellular degeneration, dilatation of the vessels and hæmorrhage. These changes appeared, however, only in the most superficial layer of the tissues, and deeper portions of the lupus area were absolutely unaffected, not the slightest change being visible.

Halkin concludes that while we cannot deny that the Becquerel rays have a definite effect on the skin, yet the superficial ulceration produced is not due to any deep effects such as would make them efficient as a therapeutic agent in the treatment of lupus vulgaris. For other skin diseases, such for instance as lupus erythematosus, the therapeutic effect might be entirely satisfactory.

X-Rays in Xeroderma Pigmentosum. Dr. Allen Jamieson, *Lancet*, London, 1903, I, p. 105.

Dr. Jamieson reports a case of xeroderma pigmentosum cured by X-rays. The patient, a little girl, at twelve months of age began to develop freckles at the sides of the nose. Later telangiectases appeared on the face and hands. When seen there were warty growths on the face, one on the tip of the nose being epitheliomatous. Thirty-four exposures caused a dermatitis, with the disappearance of which the lesions vanished entirely.

X-Rays in Xeroderma Pigmentosum. Allen. *Journal A. M. A.*, 1903, XL, p. 508.

Allen reports a case of xeroderma pigmentosum in which there has been apparent recovery as far as the skin lesions are concerned. Both eyes were involved, one being destroyed; the other is improving under the treatment.

Mycosis Fungoides. Hyde-Montgomery and Ormsby. *Jour. A. M. A.*, XL, p. 5.

The writers briefly refer to another case of mycosis fungoides which has improved under treatment.

[The reporter has treated for one month a case of mycosis fungoides, his attention during this time having been devoted to tumors about the head which were just beginning to ulcerate. There were many lesions over the body in all stages of development short of ulceration. The shrinking and the disappearance of ulceration while the patient was under treatment was very marked, but further treatment could not be carried out.

He also has had a personal communication concerning a well developed case of mycosis fungoides, in a woman in early adult life, which has been symptomatically cured, the lesions having entirely disappeared under persistent, cautious X-ray exposures. It is not known that a diagnosis in the case has been made by an expert dermatologist, but the case has been in the hands of perfectly competent practitioners and from the description of the case there seems to be no reason to doubt the accuracy of the diagnosis.

These findings in xeroderma pigmentosum and in mycosis fungoides particularly, are among the most brilliant results which have been attained by X-rays. Theoretically it is hard to account for the improvement in any of the symptoms of xeroderma pigmentosum, except the epitheliomata, from the influence of X-rays, but mycosis fungoides, with its exuberant granulomata confined to the skin, is a disease in which *a priori*, the indications for the use of X-rays, are strikingly present.]

Hyperidrosis. Engman. *Interstate Med. Jour.*, 1903, X, p. 377.

Engman reports a case of hyperidrosis of the axillæ treated cautiously with X-rays for three months, until the hair fell out and until a dry erythema was produced, after the subsidence of which there was found an improvement of fifty to seventy-five per cent. in the condition, and this has remained permanent for several months.

Hyperidrosis. Stelwagon. Journal of Cutaneous Diseases, 1903, XXI, p. 354.

Stelwagon has reported similar improvement in a case of hyperidrosis of the palms. He was led to try it in this condition accidentally, because of the improvement in hyperidrosis of the palms which he observed while treating the hands for eczema.

[The reporter suggested, *Jour. A. M. A.*, 1901, XXXVII, p. 820, that upon theoretical grounds the use of X-rays was indicated in the treatment of hyperidrosis. Several other cases of hyperidrosis successfully treated by this method are within his knowledge.]

Treatment of X-Ray Burns. Walker. *Brit. Jour. of Derm.*, 1902, I, p. 695.

Walker now never finds X-ray burns intractable, as a result of the use of the following:

Cretæ Preparatæ	15.
Olei Olivæ	8.
Adipis	4.

[It is probable that he has been extremely fortunate since the first use of this ointment, in the character of the X-ray burns which have come to his attention.]

Strebel, *Fortschritte a. d. Geb. d. Roentgenstrahlen*, B. VI, p. 74, has tried the effect on X-ray ulcers of exposures to blue light rays, but has not been able to confirm the good results obtained by Kaiser (Hamburg Naturforscher Congress, 1901). With the use, however, of the violet and ultra-violet rays he has seen an increased rapidity of development of a satisfactory trophic condition.

Engman, *Interstate Medical Journal*, has suggested the following very soothing and agreeable cream in the treatment of X-ray burns:

Acidi Borici	45.
Zinci Oxidi	
Amyli	
Bismuthi subnit	
Olei olivae, aa	30.
Aquae calcis	
Lanolini, aa	90.
Aquae rosae	45.

M. Sig.: Apply locally to the affected areas on gauze.

The powder should be rubbed up in a mortar with the lanolin. The olive oil and lime water are well mixed and slowly added to the bismuth and lanolin mixture. The rose water should be added last and a creamy paste is the result. One or two per cent. of carbolic acid may be added if the pruritus is excessive.

[The reporter has found Engman's cream, when well made, an exceedingly agreeable application as a protective in X-ray burns, but, like almost every other application suggested, it has, at times, been disappointing in his experience.]

BOOKS RECEIVED.

The Journal of Cutaneous Diseases *acknowledges the receipt of the following new publications. Reviews of those possessing special interest for the readers of the* Journal of Cutaneous Diseases *will shortly appear.*

La Pratique Dermatologique. Besnier, Brocq and Jacquet. Tome IV. (Masson et Cie., Paris, 1904).

Practical Handbook of the Pathology of the Skin. By J. M. H. Macleod, H. K. Lewis, 136 Gower Street, London. P. Blakiston's Son & Co., Philadelphia, 1903.)

The Practical Application of Röntgen Rays in Therapeutics and Diagnosis. By Wm. A. Pusey and Eugene M. Caldwell. (W. B. Saunders & Co., Philadelphia and New York, 1903.)

Beiträge zur Physiologie und Pathologie der Haut. (Die stachelzellnerven-Hypothese). By Fritz v. Waldheim. (Franz Deuticke, Leipzig und Wien, 1904).

Ueber die Prognose der Syphilis. By G. Mayer. (G. Karger, 15 Karlstrasse, Berlin, 1904).

Ueber das Syphilome des Ciliarkörpers. By Prof. Th. v. Ewetzky. (S. Karger, 15 Karlstrasse, Berlin, 1904).

Die Pathologie und Therapie der Unfruchtbarkeit des Weibes. By F. Schenk. (S. Karger, 15 Karlstrasse, Berlin, 1904).

Die Mikroskopische Technik, mit besonderer berücksichtigung der färbetechnik. By R. Ledermann. (A. Holder, Wien und Leipzig, 1903).

Functional Diagnosis of Kidney Disease with especial reference to renal surgery. By L. Casper and P. F. Richter; translated by R. C. Bryan and H. L. Sanford. (P. Blakiston's Son & Co., Philadelphia, 1903.)

A Compend of Human Anatomy. By S. O. L. Potter. Seventh edition. (P. Blakiston's Son & Co., Philadelphia, 1903).

A Compend of Diseases of the Skin. By Jay L. Schamberg. Third edition. (P. Blakiston's Son & Co., Philadelphia, 1903).

A Non-Surgical Treatise on Diseases of the Prostate Gland and Adnexa. By G. W. Overall. (Marsh & Grant Co., Chicago, 1903).

How to Succeed in the Practice of Medicine. By J. McD. Mathews. (J. P. Morton & Co., Louisville, 1902).

BOOK REVIEWS.

La Nature Syphilitique et la Curabilite du Tabes et de la Paralysie Generale. (The Syphilitic Nature and Curability of Tabes and General Paralysis). By L. E. Leredde. Paris: C. Naud, 1903.

Leredde combats Fournier's dictum that tabes and general paralysis while syphilitic in origin are not of syphilitic nature. He believes that both affections are essentially syphilitic and curable in certain stages by properly chosen and properly employed mercurials.

He criticises the designation, "parasyphilitic," the term employed by Fournier to define a group of affections presumably of luetic origin but incurable by specific medication.

Fournier includes tabes and general paralysis in his parasyphilitic group for the following reasons:

(1) Syphilis is not an invariable antecedent factor, (2) the histological changes in the nerve centers are not those of syphilis, and finally these affections are little influenced by antiluetic medication. In Leredde's opinion it is fair to conclude, in the light of our present clinical knowledge, and for other reasons, that a syphilitic infection has always preceded the evolution of tabes or general paralysis, although the patient through ignorance or bad faith does not always reveal it. From the standpoint of the histologist it is difficult to determine the early changes in the tabes, but recent investigations by Marie and Guillain favor the view that the earliest lesions are in the posterior lymphatic system of the cord and that they are syphilitic in nature. As to general paralysis there is nothing in the pathological findings which in any way excludes syphilis.

Assuming, as we must, that the vast majority if not all such cases are of syphilitic origin and nature, how can we explain our inability to obtain positive results from therapeutic agents, and the general pessimism which exists regarding their curability?

Specific lesions of the nervous system, because of the tissues involved, though curable in themselves, may leave behind permanent structural impairment or entail secondary degenerative changes.

For these reasons the prognosis of spinal or cerebral syphilis is more grave than where organs of minor importance are invaded.

In Leredde's opinion the curability of tabes and general paralysis is chiefly a question of the time at which treatment is begun, the manner in which mercury is used and its proper dosage.

The scleroses and degenerations which follow the early vascular changes and which easily result in irremediable conditions often yield in the beginning to the vigorous employment of hypodermic injections of a properly chosen mercurial. An arrest in the usual progressive symptoms of these diseases after the prolonged use of mercurials may point to a cure even though absence of the knee jerks and other phenomena may persist. The well-known tendency of these affections to spontaneous improvement and to long periods of cessation of symptoms should not be lost sight of in estimating the value of our therapeutic measure.

The cures which have been achieved in recent years of certain obstinate sclerotic syphilitic lesions of the mucous membranes by the hypodermic method leads us to think that similar results may be obtained in organs removed from our observation.

Careful consideration should be given by all syphilologists and neurologists to the author's views, for it is only by their adoption that we may hope to avert the helpless conditions which syphilis of the nervous system so often entails.

J. A. F.

Portfolio of Dermochromes. By Professor Jacobi of Weiburg im Breisgau. English adaptation of the text by J. J. Pringle, M.B., F.R.C.P., Physician of the Department of Diseases of the Skin, Middlesex Hospital, London. New York: Rebman Company. London agents: Rebman, Limited. London, 1903.

In a previous number of this JOURNAL the first volume of this excellent atlas was noticed and the admirable results secured in reproducing flesh tints by the photo-mechanical process of color-printing devised by Dr. Albert of Munich were favorably commented upon. The same high order of excellence is maintained in printing the plates of the second volume which is now before us.

The completed work comprises 86 plates with 157 figures,—14 of the plates are devoted to a delineation of cutaneous affections of venereal origin. As in all works of this character, some of the illustrations are better than others, but in these reproductions an exceptionally uniform standard of artistic excellence has been secured.

We have no hesitation in commending this atlas not only to the specialist in dermatology, but to the general medical practitioner whose practice bring him in contact with ordinary forms of skin disease which are important for him to identify. As indicated in the notice of Vol. I., this atlas is intended chiefly to meet the wants of the general practitioner, as the subjects selected for illustration are, for the most part, examples of the commoner forms of skin disease which are met with in every day practice,—the rarer, more unusual forms of cutaneous disease which possess an interest for the specialist alone are excluded. This feature, taken in connection with the handy size of the volumes, renders them convenient and available for ready reference, and should make them a most acceptable addition to the library of the physician, while the exceedingly low price of the work is an additional attraction.

P. A. M.

PLATE XIII.—To Illustrate Dr. T. Caspar Gilchrist's Article.

THE JOURNAL OF
CUTANEOUS DISEASES
INCLUDING SYPHILIS

Vol. XXII. MARCH, 1904. No. 3

SOME ADDITIONAL CASES OF BLASTOMYCETIC DERMATITIS.

By T. Caspar Gilchrist, M. R. C. S., L. S. A.,

Clinical Professor of Dermatology, Johns Hopkins University and the University of Maryland.

Case I. was of interest because the lesions were so typical and because it offered opportunities for some further observations on this disease. John Z., a tall rather thin white man, a painter by trade, came to the dispensary of the University of Maryland complaining of sores on his face (colored plate). He gave the following history: Eleven months ago he had throat trouble and bronchitis which was followed a week later by abdominal pains in the right side which lasted for about six months; bowels were constipated and when he applied later at the Johns Hopkins Dispensary for these pains, they were thought to be due to lead colic. The skin disease began seven months ago on the posterior surface of the right wrist as a small pea-sized hard lump or nodule similar, so the patient says, to a lesion which now appears on the neck. This latter lesion is about the size of a small pea and is situated in the upper portion of the corium; it can be easily picked up and rolled between the finger and thumb. The nodule is dull red, firm and is beginning to show a tendency to be papillomatous; a small quantity of rather sticky whitish pus can be squeezed out from between the papillæ. The primary lesion, which appeared on the right wrist, very gradually increased in size for five weeks before it broke down and exuded pus. It then began to assume a marked papillomatous appearance similar to the lesions now seen on the face but more pus could be squeezed out than out of those on the face. Before the primary lesions broke down it was mistaken by the first attending physician for a ganglion and he tried to rupture it by

pressure but could not do so; the lesion was accompanied by itching. The patient got into the habit of squeezing the pus out a number of times a day and he noticed less and less pustular exudate followed this method of treatment with the consequently healing up of the patch, so that in four to five months it had entirely healed with practically no scarring.

A second lesion appeared at the base of the right thumb about a week after the first one and it followed a similar course and was treated by the patient in the same manner with curative results.

A third and fourth lesion appeared, soon after the primary, and respectively on the left buttock and the left thigh posteriorly. The lesion on the buttock gradually formed a firm, smooth lump about the size of a marble and a month elapsed before it broke down. Later it became markedly papillomatous, and by persistent squeezing by the patient it gradually disappeared. The disease now began to break out on the face as a pimple on the chin and the pimple was accidentally cut during shaving. Later other lesions appeared at the rate of about one a week. One small lesion occurred on the pinna of the left ear and as soon as pus could be squeezed out the patient used this method of treatment; the lesion disappeared in a month's time.

There are now sixteen lesions on the face and neck, and of these, six are especially well marked (four of them are represented in the colored plate). They are all well defined, raised, firm, diseased areas, situated in the upper portion of the skin so that they are freely movable over the deeper structures. All the lesions are distinctly and markedly papillomatous, the papillæ varying from small to large pin-head in size. The papillæ are firm and can easily be separated; in places they are closely apposed and in other places are comparatively rather widely separated. Whitish,rather sticky pus can be squeezed out from between the papillæ so that in places where it has oozed out, dirty brown black scabs have formed over the middle portion of some of the patches due to the dried pus. The edges of the lesions are sloping, smooth and dull red, with a few minute yellowish points (miliary abscesses) present here and there. One recent patch which is situated on the right eyebrow is like a small, firm, semi-globular, fairly smooth nodule which shows a tendency to become papillomatous; a little pus can just be squeezed out. Other lesions, one on the left cheek near the ear and one on the chin have apparently dried up as no pus can be squeezed out and all evidences of inflammation have disappeared, yet there are distinct signs of dried papillomatous growths on a scarred surface. The largest patch is on the left cheek (colored plate) and measures 2.5 centi-

meters in diameter; four other lesions measure 2.5 centimeters by 1.7 centimeters in size. The smallest patch is 1 centimeter by 1.5 centimeters in size.

There are no enlarged glands. Patient complains of a sickly odor from these lesions and they throb and burn when the pus is allowed to accumulate in them. Much relief follows the squeezing of the patches. Itching is another symptom of which the patient complains.

After careful inquiry no information whatever could be obtained as to the source of this disease. There had been no previous history of any injury.

On examination of the pus which was squeezed out from between the papillæ and soaked in liquor potassæ, double contoured budding refractive bodies were found but they were not very numerous. The size varied from 8-12 in diameter.

The protoplasm contained many refractive granules of various sizes. Some of the buds were not doubly contoured.

Cultures. Nine cultures from the pus taken from various lesions yielded two pure and five impure growths. One pure culture was obtained on glycerine agar and it did not grow in a mycelial form but it presented in two days a dome shaped, soft, moist, pure whitish, glistening colony. Microscopical examination of the colony showed yeast like bodies which varied in size from 4-7 μ in diameter; some were oval, others were round. Numerous budding forms were seen and a fair number of commencing mycelial formations were also noticed. Many of the bodies had perfectly clear contents whereas others were beginning to be granular. Many were not doubly contoured, others were.

The pure culture on agar yielded seven colonies of blastomycetes; they were dirty white in color, glistening and formed cone or dome shaped colonies which were firmly adherent to the media, in fact it grew into the media. On low magnification one could see a fine fringe round the edge which was mycelial in nature. As this culture grew older there appeared gradually from the largest colony a number of fine aërial hyphæ with terminal tufts. They grew at room temperature. These aërial hyphæ are represented by Fig. 4, which is double the actual size. They consist of whitish slender rods with shorter and fine projections growing from them, upwards and outwards. As the culture grew older, very fine films seemed to join these aërial hyphæ together. The other colonies had increased in size and run together so that a fine whitish mycelial growth had covered the whole surface of the media.

Pathology. Three portions were excised and sections showed the usual features of blastomycetic dermatitis, viz: marked hypertrophy of the epidermis with miliary abscesses scattered here and there, attempts at formation of pseudo-tubercles in the corium, large numbers of plasma cells, also a few miliary abscesses in the corium just beneath the epidermis. Only a few scattered blastomycetes were found in the miliary abscesses and in the corium.

Animal Experiments. Subcutaneous inoculation was made with the budding yeast-like forms (the glycerine-agar growth), but the results were negative, whereas the inoculation with the mycelial growth on agar proved to be pathogenic in guinea-pigs.

Drop Culture. After washing one of the lesions with alcohol, pus was squeezed out and one drop of pus was mixed with a drop of sterile bouillon on a cover slip which was placed upside down on a hollow glass slide, thus forming a hanging-drop culture. Vaseline was smeared over the peripheral portion of the cover slip so that air was excluded. A number of single and budding blastomycetes were seen in the drop culture.

Two days passed before the specimen was examined again microscopically, the slide remaining in the meantime at room temperature. A striking picture was then observed. All the blastomycetes had thrown out mycelial elongations which were easily found under the microscope. Four of the bodies were then watched carefully at short intervals at room temperature (56 degrees F.) so that the process and rate of growth could be followed. The dotted lines in Fig. 1 represent the varying rates of growth at special times and was drawn with the aid of a camera lucida; *k* and *m* represent the budding blastomycetes; *n* is the commencing mycelial prolongation. The exact rate of growth during the night of twelve hours when the temperature was about 45°-50° F. is represented by *a* to *b; b* to *c* is seven hours' growth at temperature of 56° F.; *c* to *d* is one hour's growth, and *d* to *e* is one and a half hours' growth at the same temperature; *e* to *f* is one and a half hours' growth at 65° F.; *f* to *g* is forty minutes' growth at 65° F.; *g* to *h* is twelve hours at 45°-50° F., and *h* to *i* is eight hours' growth. Although the elongation of the mycelium was watched carefully and often, yet no motion of the granules could be observed nor did any division of any kind take place. During the growth in one and a half hours no granules had followed the elongation during that time, but ten minutes later a granule appeared from the upper portion of the mycelium. The advancing outline of the mycelial growth was very fine and delicate.

Although the bouillon surrounding the organisms was swarming with bacilli and micrococci, yet the mycelium had no phagocytic action whatsoever on the micro-organisms.

The magnification of the drawing is about 480. (Oc. 4. Obj. 6, camera lucida.) The blastomycetes measure about 8 μ in diameter and the mycelial growth was about 5 μ in one and a half hours at a temperature of 56° F. and no granules appeared during that time.

The cover slip was then accidentally broken, the bouillon dried up and as a result the protoplasm within the membrane of mycelium retracted into greenish refractive clumps; sixteen hours later when it had thoroughly dried up water was added and the granules had run together and it presented an appearance like Fig. 2.

The growth of other blastomycetes was followed in the same way, an example of which is seen in Fig. 3. The blastomyces (*k*) has sent out two mycelial prolongations one upwards, the other downwards. The lower branch later sent out two other branches. In forty-eight hours at room temperature the mycelial outgrowth had grown upwards as far as *a* and downward as well as branching to *e* and *f*. Later the growths represented by *a-b*, *e-c*, and *f-g* occupied twelve hours overnight at a temperature of 45°-50° F.

In one other example on the one mycelial outgrowth from a single blastomyces there appeared five lateral buds in eight hours. This method of hanging-drop culture direct from the pus has been mentioned by D. W. Montgomery and also by Otis and Evans. I would suggest it as an aid to diagnosis or where the blastomycetes can not easily be found. After two days' growth the picture under the microscope is very striking of mycelial outgrowths from the blastomycetes.

This patient got quite well with the application of X-rays and the administration of potassium iodide internally.

Case II. This case is noteworthy on account of the remarkable hypertrophy of the lesions of the foot.

Aaron P., a negro laborer, was admitted to the Johns Hopkins Hospital for a disease of the left foot. He was a robust, well built man. The history was as follows:

Two years ago the disease commenced on the foot as a nodule which afterwards formed an abscess (?) and one month later was incised. Instead of healing, the wound began to show excessive amount of granulations which in time took on a distinct papillomatous appearance. Six months later the toes became infected and one year after, his nose and face became involved.

Present Condition. December, 1902. On the left foot just below the

ankle, on the inner side is a remarkable pear-shaped outgrowth extending from the (Fig. 6) tendo Achilles to just beyond the middle line on the dorsum and is about 12.5 centimeters broad at the greatest width with an average height of 2 centimeters. About the center of the growth is a linear scar about 7.5 centimeters long. The surface presents the appearance of giant papillæ which are flat and are covered with rather thin epidermis. The smaller yet nearly pea-sized papillæ have a warty appearance and are crusted over with a thick brownish foul smelling exudate.

On removing this scab there is no bleeding but from the spaces between the papillæ a sanguinous purulent discharge can be squeezed out. The margins of the patches are well defined, sloping and often contain numerous yellowish points (military abscesses).

Over the first, second and third toes and scattered irregularly over the rest of the foot are about twenty-five similar swollen areas varying in size from pea- to lemon-sized lesions, all exhibiting the same warty tendency as the larger patch. (Fig. 6.)

The lower half of the nose and upper lip is the seat of a similar eruption (Fig. 5) but the papillomatous excrescences are much smaller than those of the foot although they are just as clear and well defined and exhibiting similar discharges. The papillæ are from small to large pin-head size and can easily be separated. Sticky pus can be easily squeezed out. The lesions are similar to those in the colored plate. There are also four small nodules which are situated along the naso-labial fold and one on the chin presenting the same features. On the right cheek are two pronounced superficial abscesses about the size of a bean, one oval (Fig. 5) and the other crescentic. They contain a very fluid sanguinous pus. They remind one very strongly of large sub-epidermal abscesses which are sometimes met with in severe acne vulgaris. There were no enlarged glands. Examination of the pus obtained from different lesions demonstrated the presence of numerous blastomycetes varying from 8-12 μ in diameter and presenting similar appearances to those seen in the first case. Cultures of the blastomycetes were also obtained but none of them pure, as ordinary pus organisms were also present. No inoculation experiments were carried out.

The patient was given large doses of potassium iodide which caused rapid improvement. The lesions on the foot resulted in large keloidal growths which were almost as large as the original excrescences so that the foot represented a giant warty appearance. This case was shown before the American Dermatological Society in 1903.

Dr. Cole of the Johns Hopkins Hospital demonstrated that the *blood of this patient had the power of agglutinating a pure culture of the organism derived from the first case.* Control experiments were also carried out showing that normal blood did not agglutinate the blastomycetes.

Case III. J. B., a robust, rather stout white man, age forty-five, consulted me regarding an eruption on his right forearm and left calf. He gave a history of having had malaria and rheumatism five months previous; also of having had sugar in his urine (so his Doctor said) but the sugar disappeared after taking arsenic. He had been taking some iodide preparation for the last month.

The present eruption began five months ago on the outer side of the right forearm as a small papule about the size of a pin-head. The lesion grew gradually in size and when it became pea-sized six weeks after it commenced, it broke down. Pus exuded especially on squeezing and it showed a tendency to become papillomatous. Two weeks later a second lesion appeared on the inner side of the left calf, three inches below the bend of the leg. The lesions at present have the following characters: They are well defined, deep red, raised, roundish patches which are markedly papillomatous but with firm sloping margins. The papillæ were about pin-head-sized and whitish sticky pus could be expressed from between the papillæ. The lesions on the forearm measured six and a half centimeters by four and a half centimeters and the one on the calf was less in size. No enlarged glands were present and the general health was good. No explanation could be obtained how the disease was caught. Examination of the pus revealed the presence of a number of double-contoured budding blastomycetes which measured about 10-12 μ in diameter. A portion of the lesion on the leg was excised and the sections showed the usual histological features which have already been mentioned and a fair number of blastomycetes were found in the miliary abscesses and in the corium. No cultures were taken as the case was only seen once.

Case IV. In connection with above unrecorded cases of blastomycetic dermatitis it will be interesting to refer to a case again which I have already published in the *British Medical Journal* of 1903 and in which a relapse had occurred due to stoppage of treatment before a cure had taken place. The disease had produced during the relapse an extensive foul smelling papillomatous patch which extended half around the body from the spine to the umbilicus (Figs. 9 and 10). The disease began in the usual way as a papule, and while the patient, a negro, was in prison. Other lesions had ap-

peared in the right groin, right axilla and right side of the chest near the nipple. Pure cultures of blastomycetes were obtained and they grew as closely adherent whitish mycelial colonies. Blastomycetes of the usual size were demonstrated in the pus. The patient had chills and a high temperature, but no organisms were found in the blood. Intravenous inoculation of some of the pus into a dog, which was carried out by Dr. E. R. Strobel of the Johns Hopkins Hospital, yielded positive results. The dog was killed one month later and numerous pseudo-tubercles were found in the lungs and pure cultures of the organisms were obtained from some of these tubercles. The patient took treatment for about a month and he improved in general health and weight. He then left the hospital. He returned a year later, no medicine having been taken in the meantime, with a marked relapse (Figs. 9 and 10) showing again practically the same lesions in the same situation more extensive than on the first occasion. Potassium iodide was given both times in large doses, and on the last occasion with apparently curative results.

Case V. This case is of special interest, because it is unknown to American literature and is recorded in the *Indian Medical Gazette*, Vol. XXXVIII (April, 1903), by Dr. R. McCarrison. The patient was an old man, a native of Northern India, aged about fifty years. The following history is given: Two months previously when out collecting branches for firewood, he injured the back of the right hand with a piece of wood; four days later the back of the hand swelled up to a height of about one inch. A discharge followed from the site of the original wound. The swelling went down. There was no pain, only tenderness. Dr. McCarrison saw the patient two months after the injury and described it as follows: "The lesion occupies the lower half of the dorsum of the hand and encroaches on the fingers. It is markedly defined, first by the cuticle of the healthy skin stopping abruptly at its edge, and secondly by the raised reddish infiltrated edge of the sore itself. The whole lesion is superficial and confined entirely to the skin which can be moved freely over the underlying tissues. There are two well marked zones, an outer dark reddish smooth portion which has a shiny appearance . . . . . underneath the surface of this area numbers of minute subepithelial collections of fluid are seen. From those nearest the advancing edge a blood stained pus can be expressed, while in those more centrally situated the pus is white. When these abscesses have burst, red scabs of varying sizes have formed. . . . . This external zone gradually merges into what is

the most characteristic feature of the lesion, namely, the second zone. It constitutes the base of the lesion, is soft and supple and is made up of numerous small papillæ which project from the surface and which appear to join together at the base, forming a sort of mesh-work. From the meshes of the network pus can be squeezed. Each mesh seems to contain a very minute abscess. The papillary projections are pinkish in color and vary in size, those in the center of the lesion, which is the oldest part of the sore, are larger and about the size of a large pin-head. They project about one-eighth of an inch above the level of the rest of the sore and in the situation approximate more closely to the normal epithelial appearance of the healthy skin. The papillæ become smaller as they gradually merge into the smooth external zone or redder as they become continuous with the bright red papillomatous "active" parts of the area. . . . . A pronounced odor is noticed. There are no other lesions on the body and no glandular enlargement." Oval or spheroided doubly contoured bodies, 12-14μ in diameter, were found in the pus obtained from the minute abscesses and also from between the papillæ. Many organisms showed budding and the protoplasm of all was granular.. The disease improved with carbolic acid dressing and the administration of potassium iodide internally.

This is an undoubted typical example of blastomycetic dermatitis, and is the first case to be recorded in India. It is very interesting because the lesion commenced as an injury by scraping the skin while the patient was breaking a piece of wood. The disease was also fairly rapid in its growth, being only two months old when Dr. McCarrison saw it.

Dr. McCarrison, in sending me a reprint of his article, wrote me that Sir George Scott Robertson had noted in his writings that there was prevalent in the northern portion of India a peculiar form of ulcerative disease which appeared to be limited to the face, mouth and throat. The disease was cured with iodide of iron and cod liver oil, and iodoform used locally. It was thought that the disease might be a kind of rodent ulcer(?)

I have added two other photographs (Figs. 7 and 8), which are of interest from a diagnostic standpoint. The first case was (Fig. 7) a man who came to the Johns Hopkins Dispensary for a skin disease on the nose and foot. It began three years previous as a pimple on the left side of the tip of the nose. There was no itching or pain. The pimple increased in size and broke down, and the disease gradually spread over the entire nose and down the left

side of the cheek to the left angle of the mouth. The whole lesion when first seen was made up of soft variously sized papillæ from between which pus could be expressed. The edge of the patch was firm and sloping, but no small or minute abscesses could be seen along the border. In many places yellowish and even black scabs covered the patch, especially along the free border of the nose. There was no pain or itching, only tenderness. About two years after the primary eruption a lesion appeared on the right big toe. The patient thinks the shoe abraded the skin from the tip and then it rapidly became infected. The entire right great toe was found on examination to be swollen, dull red, and and covered with scabs, underneath which were papillomatous lesions. Pus could be squeezed out from between the papillæ. There were no enlarged glands. The patient gave a history of having had syphilis many years ago. A tentative diagnosis of blastomycetic dermatitis was made. There were no other evidences on the skin of any present or remains of previous ulceration. Sections from a portion excised from the diseased patch showed histo-pathological features similar to those of blastomycetic dermatitis, but no organisms could be found in the pus or in the sections, although many specimens were examined. No growth of blastomycetes could be obtained, although many cultures were tried; they were either sterile or ordinary pus organisms were grown. The case was not one of tuberculosis, as the sections were not like those of tuberculosis. No tubercule bacilli could be found nor did any tuberculosis nor other pathological lesions develop in a guinea-pig, into which portions of the tissue were inoculated. Syphilis was considered as a possible diagnosis, but the lesions did not present the features of syphilis, and the disease had persistently been papillomatous for three years. There were no enlarged glands, yet there was a history of syphilis, but it was not particularly clear. Large doses of potassium iodide produced a marked improvement in the disease. Since no blastomycetes could be demonstrated either in the sections or in the pus or by culture, although nearly all the clinical and histological features of blastomycetic dermatitis were present, yet one cannot class this as an example of this disease. It must have been an unusual form of cutaneous syphilis and a very interesting one.

Fig. 8 represents a negress who also came to the dispensary with a lesion on her upper lip. It began four years ago as a small firm pimple on the right nostril. It grew straight downward towards the margin of the lip and hung over the lip. It was then one to one inch and a half broad. Patient cut it off when it was small because she was told it was a wart. It grew more rapidly after it was

cut, but not until six months had elapsed. It only took about one month to extend over nearly the whole upper lip.

When first seen (March, 1900) the whole lip was increased to double its natural size, and it presented a markedly dry, papillomatous, firm mass. The papillæ were mostly large pin-head sized and closely aggregated. No pus could be squeezed out from between the papillæ. Round the margins were a number of isolated pin-head sized firm papules, but no minute abscesses. The sublingual and submaxillary glands were markedly enlarged. The diagnosis lay between syphilis, tuberculosis and blastomycetic dermatitis. No history whatever of syphilis could be obtained and no other symptoms could be detected. One of the small discrete papules was excised and also a portion of the larger growth. Since no pus could be squeezed out there was no chance of examining it for blastomycetes. The section did not show any features of blastomycetic dermatitis, nor were any of the organisms found in the section. The pathological features were rather those of syphilis. No tubercles was present nor giant cells nor tubercle bacilli. One week after the first examination, the patient presented a rather typical papular syphilide on the extremities. She was put on anti-syphilitic (mixed) treatment and after the lapse of about four weeks marked improvement followed so much so that the papillomatous appearance had disappeared and the induration had almost passed away. The patient disappeared after four months' treatment, and the disease had to all appearances been quite cured. She returned a year and a half later with a pronounced relapse of the disease as seen in Fig. 8. No medicine had been taken in the meantime. The patch had extended in area, measuring 11 centimeters by 3 centimeters, the central portion having become somewhat clear and forming a smooth scar, whereas the peripheral portion had resumed the papillomatous character, firm, hard and infiltrated. No pus could be squeezed out. The sublingual and submaxillary glands were again enlarged. The patch again yielded to anti-syphilitic treatment with good results, in fact the disease practically disappeared again after three to four months' treatment. The case is an interesting one because of the marked papillomatous features, wherein it simulated blastomycetic dermatitis.

Since my article on Blastomycetic Dermatitis in the *British Medical Journal*, Oct., 1902, p. 1321, wherein I discussed the clinical symptoms, pathology and bacteriology of this disease, a number of other cases have been published in this and other countries. In the large majority of all the cases thus far recorded (over 40), including

the present series, the clinical symptoms and particularly the histopathology are practically identical. Of special interest are the systemic cases of which there are now four in number. The observations of F. J. Otis and Newton Evans on Ormsby and Miller's case are very interesting, because the disease had probably commenced in the lungs, and the parasites were demonstrated in the blood post-mortem. These authors also noted that the lymph glands were not involved and that sporulation forms were found in the tissues; also that the effect of exposure of the organisms to the X-rays was negative. In all the cases thus far recorded, there has been great similarity in the morphology of the organism as it occurs in the tissues and in the purulent exudate. No mycelia has ever been found in the tissues. From a cultural standpoint many varietions have been described; some cases yielding chiefly budding forms, some mostly mycelial growths, whereas others have yielded aërial hyphæ, of which our Case I is a marked example.

As far as treatment is concerned the administration of potassium iodide internally, as first suggested by Dr. Bevan, of Chicago, as well as the exposure to the X-rays, until a mild burn is produced, will in my opinion, cure the disease except in severe systemic cases.

It is interesting to note now the wide distribution of this disease, cases having been recorded in Germany, France, Italy, England, South America, India, as well as in this country (over 40 cases have now been recorded in North America). Another fact of importance is the confirmation of Hektoen's original observation that the blood of a patient suffering from this disease will agglutinate the blastomycetes, The blood of Case II agglutinated the organisms derived from Case I. Stokes and myself originally gave the name of *blastomyces dermatidis* to the organism causing this disease.

A CASE OF LYMPHATIC LEUKAEMIA WITH PURPURA.

By Frederick C. Shattuck, M.D., Boston.

Jackson Professor of Clinical Medicine, Harvard University.

A MAN of twenty, a cab driver, born and living in Boston, was seen in the Out-Patient Department of the Massachusetts General Hospital, October 22, 1903. He was referred to the hospital by Dr. R. C. Cabot, with the diagnosis of lymphatic leukæmia, and entered the wards of Dr. F. C. Shattuck November 2, 1903. On account of the marked skin manifestations of the disease, the case

PLATE XIV.—To Illustrate Dr. T. Caspar Gilchrist's Article.

Fig. 1. Fig. 2. Fig. 3.

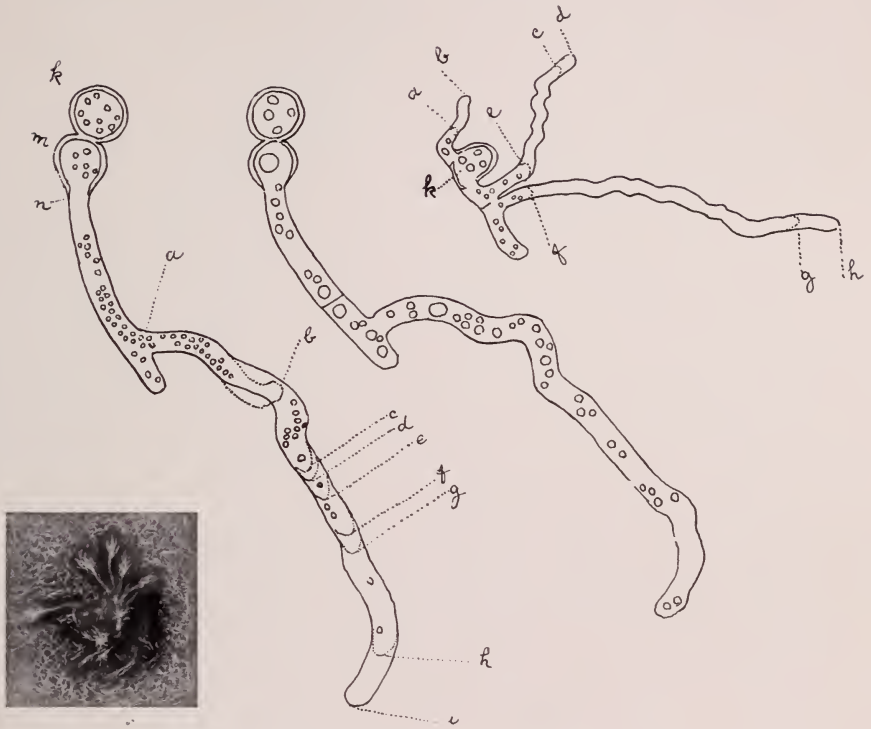

Fig. 4.

DESCRIPTION OF PLATES.

PLATE XIV.

A drop of pustular exudate from Case I was placed in hanging drop of bouillon and watched microscopically.

Fig. 1 represents a budding blastomyces, *k* and *m*, which, after two days, showed a mycelial outgrowth to *a*. The dotted lines represent the different rates of growth of mycelium at definite intervals. Magnification about 480.

Fig. 2 is same as Fig. 1, but after the organism was accidentally dried and water was added.

Fig. 3 is another example of a blastomyces growing mycelium in the hanging drop culture.

Fig. 4 represents aërial hyphæ in a pure culture of blastomycetes on agar.

PLATE XV.

Figs. 5 and 6 represent Case II of blastomycetic dermatitis on the face and foot of a negro.

Fig. 7 is a case which simulated clinically and histologically blastomycetic dermatitis, but since no organisms could be found, and cultures were sterile, it was considered to be syphilis.

Fig. 8 is also a case of cutaneous syphilis in a negress.

PLATE XVI

Represents Case IV of blastomycetic dermatitis in a negro.

Fig. 9 shows the anterior view, and Fig. 10 the posterior view of the body.

PLATE XV.—To Illustrate Dr. T. Caspar Gilchrist's Article.

Fig. 5.

Fig. 6.

Fig. 7.

Fig. 8.

PLATE XVI.—To Illustrate Dr. T. Caspar Gilchrist's Article.

Fig. 9.

Fig. 10.

is reported in brief, at the request of Dr. J. T. Bowen, who saw the case in consultation.

The family history is excellent and his habits not remarkable; he denied having had venereal disease. With the exception of measles in childhood he had no recollection of any illness, and was well and strong up to the onset of his present trouble, seven weeks ago.

At that time he noticed swelling of the neck, and lumps near the angles of his jaw. At the same time there appeared a smooth red rash on the back of his hands and forearms; he had been taking no medicine previous to its appearance. About two weeks later he noticed lumps in the axillæ, but was not aware of any in the groins, until his attention was called to them. The glands in the neck are smaller than at first, but there has been no change in the masses in the groins. In the course of two weeks the rash which had been localized at first on the extensor surface of the forearms, spread over the body, face and extremities. It is now generalized all over the body, including the palms of the hands and the soles of the feet. The rash appears and disappears on various parts of the body; there is some itching. The rash, when seen by Dr. Bowen in the Out-Patient Department, ten days before entrance to the hospital, was papular, vesicular, follicular, mascular, with hæmorrhages old and new.

In addition to the glandular enlargement and the rash, there had been indefinite symptoms at first; some cough, some dyspnœa upon exertion, some indigestion with loss of appetite. He complained of dizziness with frontal headache, and there had been of late some impairment of the vision. For the past three or four weeks there had been ringing in the ears with considerable deafness. At the onset of the disease there was a transient, slight œdema of the feet. His best weight before he became sick was 165 pounds; in the last seven weeks he has lost twenty-five pounds.

On entrance to the hospital his temperature was 100.5, pulse 105, respiration 28. He was well developed and nourished, and physical examination was, in brief, as follows: Pupils unequal, right larger than left, both react to light and accommodation; a small subconjunctival hæmorrhage present in right eye; tongue clean, teeth neglected. An erythematous area small in size on hard palate.

Nothing abnormal found in the lungs.

Heart: Impulse and dullness correspond in fifth space inside nipple line; no increase to right. Action is regular, sounds of fair quality; systolic murmur heard over precordia loudest at apex and transmitted toward axilla. Pulmonic second sound louder than aortic sec-

ond. Pulses are equal, synchronous, of good volume and tension; arteries not palpable. The liver dullness extends from sixth rib to two centimeters below costal border, edge not felt; spleen not palpable. Abdomen otherwise not remarkable.

Reflexes: Knee jerks not obtained. Plantars, abdominal, cremasteric normal. No œdema; external genitals normal.

Glands: In posterior, anterior and submaxillary triangles of neck, in supra-clavicular regions, axillæ and groins are numerous firm, discrete, non-tender glands, varying in size from a pea to a horse chestnut. The right epitrochlear is also palpable. Scattered over the scalp, immediately beneath the skin were a few small, tender nodules.

Skin Manifestations: Scattered over the entire body, but most marked on face, neck, front of chest and abdomen was an erythematous, papulo-macular eruption, confluent on face, neck and trunk, discrete on limbs. There were also areas of hæmorrhage old and new; these were most marked on face and neck; wherever there had been pressure they were especially evident. There were present on the palms of the hands, especially the right, numerous small bullæ, varying in size from a pea to small bean. The impression, in passing the hand over the surface of the body, was one of marked induration about the papules, a shotty feel not unlike that in small-pox. Dr. Bowen's note of the skin lesions two days after entrance was as follows: "Purpuric and vesicular eruption, mostly follicular; a most unusual appearance which is evidently symptomatic of leukæmia."

Pathological report upon piece of skin excised, by Dr. J. H. Wright. "The specimen received for examination consists of a piece of skin less than one centimeter in greatest dimension. This was hardened in Zenker's fluid, and paraffin sections cut from it. Microscopical examination of these sections shows the following: In the epidermis are four flattened cavities of somewhat variable size; the largest of these cavities contains some red blood corpuscles, the other three are more or less completely filled with masses of small cells. Most of these cells are mononuclear and have a relatively small amount of, or no recognizable protoplasm; while they are not like the typical lymphoid cells observed in lymph glands, there is no reason to believe that they are not identical with the prevailing mononuclear cells observed in the blood smears in this case. Among the cells in these cavities are a good many which contain chromatin fragments, as if their nuclei had undergone fragmentation. No polynuclear leucocytes were positively recognized. The epithelium bordering on these cavities presents more

or less kerato-hyalin change, such as always occurs about a vesicle or similar lesion in the epidermis. In the papillæ and corium there is a moderate amount of infiltration with cells in various places. These cells in many instances present the appearance of being distorted masses of chromatin. In other instances they are of a mononuclear type not unlike those cells seen in the cavities of the epidermis. No polynuclear leucocytes definitely observed among these infiltrating cells. There is no hæmorrhage in the corium or papillæ.

Blood Examinations: When first seen in the out-patient department, October 22, 1903, his hæmoglobin was 75 per cent, red corpuscles 3,896,000, white corpuscles 45,600. A differential count at that time gave the following result: polymorphonuclear neutrophiles 21 per cent., lymphocytes (chiefly small) 67.5 per cent., eosinophiles 6.5 per cent., myelocytes 5.5 per cent., mast cells 1 per cent.

November 2d, the day of entrance to the hospital, hæmoglobin 45 per cent., red corpuscles 2,968,000, white corpuscles 31,400. Polymorphonuclear neutrophiles 16 per cent., lymphocytes 81 per cent., eosinophiles 1 per cent., myelocytes 3 per cent.; 1 megaloblast and 7 normoblasts were seen during the differential count.

Examination November 10th. Hæmoglobin 37 per cent., red corpuscles 3,024,000, white corpuscles 50,800; the differential count gave polymorphonuclear neutrophiles 21 per cent., lymphocytes (small) 70 per cent., large 4 per cent., myelocytes 3 per cent., eosinophiles 2 per cent. Examination of the stained specimen showed considerable achromia, marked poikilocytosis, few polychromatophilic cells, a few cells with granular stippling; 9 normoblasts were seen during the count. The count of blood platelets November 11th was 94,200.

November 15th. Hæmoglobin 25 per cent., red cells 2,320,000, white cells 51,000. Differential count of 500 cells gave the following result: Polymorphonuclear neutrophiles, 10 per cent., lymphocytes 84 per cent. (large and small), eosinophiles 4 per cent., myelocytes 2 per cent. The stained specimen shows marked achromia, poikilocytosis, with numerous polychromatophilic cells, a few cells with granular stippling. During the count 6 normoblasts were seen.

During his stay in the Massachusetts General Hospital there was then a slightly increasing white count, the highest being 51,000, an increasing lymphocytosis, the highest count being 84 per cent. (large and small; the small predominating), and an increasing secondary anæmia, as shown by the blood examinations. A few myelocytes were constantly present in his blood. During his stay in the hospital he

ran a continuous temperature ranging from 100-101, while the pulse ran from 110-120. Three days before death there was a rise of pulse, respiration and temperature, possibly due to a terminal infection. In addition to his skin hæmorrhages, and the hæmorrhages in the conjunctiva and mucous membrane of hard palate, he developed retinal hæmorrhages, some bleeding from the gums and an occasional epistaxis. There was no melaena or hæmaturia, nor did the urine show at any time anything pathological. In view of the tendency to hæmorrhage in this patient, it is interesting to note that the coagulation of the blood was delayed, requiring ten minutes, ten seconds. The patient grew progressively worse, the skin lesions became more and more severe, and nausea and vomiting with mild delirium appeared, and he died 2 weeks after entrance to the hospital. The duration of the whole process from its earliest appearance was a little over nine weeks. From the first day of observation until death he had persistent skin lesions; the blood was that of a lymphatic leukæmia. Unfortunately no autopsy could be obtained.

THE REMOVAL OF WARTS, MOLES, AND OTHER FACIAL BLEMISHES.

By George Thomas Jackson, M.D., New York.

Read before the Alumni Society of the City (Charity) Hospital April 8, 1903.

LAST winter I had the pleasure of reading before you a paper on the treatment of acne, the most common facial blemish. To-night I shall speak to you of some blemishes, most of which are rather deformities than diseases, and if you will permit me, at some future time, I shall talk to you about the other dermatoses that especially affect the face.

The facial blemish to which I would first draw your attention is the *wart*. In young people, particularly in children, warts sometimes will appear in great numbers so that the whole face, or sections of it, will be sown over with small papular, flat, soft warts of the color of the skin, or perhaps of a pinkish color. In older people also this variety of wart may be seen, but it is not so common as in children. The ordinary wart, such as occurs on the hands is not common on the face. In people of middle and advanced life the so-called senile warts are encountered. They are flat, brownish or blackish in color, oval, somewhat raised, rough excrescences. There may be

PLATE XVII.—To Illustrate Dr. Frederick C. Shattuck's Article.

but one or several of them. They may be not more than a quarter of an inch in diameter, or they may be one or more inches in diameter. They not infrequently become epitheliomas.

The best treatment for the disseminated seed warts, when practicable, is to scrape them off with a curette a few at a time, touching the excoriated surfaces left with pure carbolic acid. This treatment will leave no scars. In many cases this can not be done on account of the age of the patient, a child being frightened by the operation. If you can persuade him to allow you to curette off a few, he will find that the operation is not very painful, and will permit you to scrape them all off. When curettage is not practicable the warts may be removed by touching them with glacial acetic acid, a few being treated each time. A better means is to apply to a part of them at a time a saturated solution of salicylic acid in collodion. By going over them again and again they will drop off. It must be remembered that in course of time they will all disappear of themselves and on this account nothing must be done that will leave a scar.

Filiform warts should be snipped off with a clean pair of scissors close to the skin, and the base touched with pure carbolic acid. When done quickly the operation is not painful.

Senile warts may be removed by the saturated solution of salicylic acid spoken of a moment ago. If they show the least tendency to enlarge they must be treated as if they were epitheliomas, thoroughly curetted and the base cauterized with nitrate of silver, or treated with arsenical paste, or chloride of zinc. The tendency of these warts to become malignant must be kept ever in mind, and unless they are very unsightly and therefore objected to, it is often best to leave them alone. Mild caustics and the application of weak ointments are worse than useless, as they only tend to stimulate them into malignancy.

Another form of facial blemish we are often called upon to do something for is what we call *nævi*, what the layman speaks of as birthmarks and moles. They are familiar to all of you. They may be vascular, pigmentary, hairy, or fibrous. Not infrequently they are pigmentary, hairy, and fibrous at the same time.

Vascular nævi may be simple dilatations of capillaries. These are called telangiectases. They may be congenital or acquired. A common form of the acquired telangiectasis has a central dark red point from which radiate a number of fine red lines. They bear a fancied resemblance to a spider, and are the so called *spider cancers*, a horrible name for a most innocent and harmless disease.

Or they may take the form of patches of varying shades of red, from pink to purple, spreading out on the face, the so called *port wine* mark. Their color changes under the influence of heat, cold, or excitement, becoming of a darker shade. Their surface may be smooth, or have upon it here and there small vascular tumors.

Or they may take the form of vascular tumors, the so called *angioma cavernosum.* These are most often found over the forehead, near the anterior fontanelle. When pressed on they can be made to flatten out, but when the pressure is taken off they slowly fill up again. They often feel as if they had a fibrous scaffold inside of them. This is the only form of vascular nævus that imperatively calls for treatment, as it frequently gives rise to a severe and dangerous hæmorrhage if broken by a blow. If the tumor is small, ulceration may take place after the injury, and in that way may undergo a cure. But it is a dangerous method of cure.

Pigmentary nævi are of various shades of color from brown to black, and of all sizes. The small ones are sometimes spoken of as permanent freckles. Very often long fine or coarse hairs will be found growing in them, forming the hairy nævus. Occasionally these nævi are very large, so as to cover a quarter of the face. Very often the base of such a nævus is thicker than the surrounding skin, thus forming a variety of fibrous nævus.

The *fibrous nævus* is a fibroma. It may be sessile or pedunculated. Its color may be that of the skin, or it may be some shade of brown. Fibrous nævi may be found anywhere on the face, but perhaps they are most often seen on or near the nose forming prominent excrescences. They vary in size from a small French pea to a small marble. In some families they are frequently seen and are regarded with pride as a mark of the race. Such people reject with scorn any suggestion to remove them.

To remove vascular nævi of all forms there is, in my experience, nothing so rapid and brilliant in its results as liquid air. The great drawback to its use is that it can not be readily obtained. Liquid air is applied by means of a swab of absorbent cotton or by means of the syphon bottle. When the swab is used it should be pressed on the nævus until the growth is frozen hard; when the bottle is used the air should be sprayed on to produce the same effect. When sufficiently frozen the part acted upon will turn white like a piece of ice, will feel cold like ice, and when struck with a hard object it will give the sound of striking upon a solid substance. In a few moments it will thaw out and if not too much frozen, it will not slough excepting very super-

ficially. The nævus is destroyed with one or two applications and with very little scarring. Unfortunately, for some hours after the operation, the patient suffers a great deal of pain, to relieve which it may be necessary to administer an anodyne. Electrolysis is the next most reliable agent because it is under our control while caustic acids and alkalies are not. In simple telangiectases the vessels may be destroyed by passing the fine steel broach, such as is used for the destruction of superfluous hair, attached to the negative pole of a galvanic battery, into their course and using a current of about two milliampères for half a minute. The vessels will be seen to shrink up and disappear. In the so called spider cancer it is only necessary to pass the point of a fine cambric needle into the middle prominent point and turn on a current of two milliampères for a minute to destroy them. As soon as the central point is destroyed the dilated vessels shrink up and disappear. You can do the same thing by passing the point of a red hot needle into the central point, or by touching it with a drop of fuming nitric acid. But these latter methods are more prone to leave a scar.

Very many infants have small vascular nævi of the port-wine mark variety, especially on the nape of the neck, forehead or lip. Many of these will disappear of themselves in a short time. It is therefore well to advise against operative interference for a time and watch the case, telling the parents of the probability of their spontaneous disappearance. In order to hold the case and to give the parents the idea that something is being done for the child, and also because pressure does have some effect in hastening the disappearance of nævi, it is well to have them painted constantly with collodion. If they are in localities where pressure of more active kind can be made, a bandage may be used. The danger of producing sloughing must be kept constantly in mind. The port wine mark is a most unsatisfactory thing to treat. Of course as the vessels lie deep in the skin it is impossible to destroy the nævus without at the same time destroying the skin. What we aim to do is to destroy as little of the skin as possible and to substitute for the red mark a delicate pink one. If we do more than this we produce a white scar which though not as prominent as the red mark is conspicuous. If the infant is young enough to be held firmly, or the deformity is in an older patient who will help us in our work, we can do much for these cases by electrolysis. A steel broach or a fine cambric needle should be used in a needle holder attached to the negative pole of a galvanic battery, and a number of punctures made in lines and at a distance of

a sixteenth of an inch apart. A current of two to three milliampères should be used for about a half minute in each place. It will be seen that this is a very slow and tedious operation if the nævus is of any great size. But by care and perseverance a good result can be attained. In small nævi we can obtain more rapid results by passing the steel broach under the nævus and from side to side. As it is always dangerous to use general anæsthetics of any kind, it does not seem to me advisable to administer them to children in order to operate on a port wine mark, especially as they would have to be given again and again. For we must go over these nævi many times before we obtain the effect we want.

Where a child is too old to be held, and in cases where for any reason electrolysis can not be used, we can do something for port wine mark by using fuming nitric acid, or the acid nitrate of mercury, or ethylate of sodium. Any one of these acids should be used with care, not swabbed over the whole surface, but applied by means of a sharpened stick wound with absorbent cotton in a series of dots, as spoken of under the use of electrolysis. In the young and tender skin of children these applications are more efficacious than they are in older people. Multiple punctures with a steel needle dipped in fifty per cent chromic acid are also recommended. But none of these acids gives as good results as does electrolysis.

Angioma cavernosum of small and medium size can be destroyed most effectively by electrolysis. I have removed several so that after a time it was hard to find the place where they were. This may be done by using a fine steel needle attached to the negative pole, passing it into and under the nævus from side to side, and letting a current of about three milliampères run for about a minute. The current is then to be broken by removing the sponge electrode. The needle is to be drawn back until it is just about to leave the point of entrance and then passed in again at a slight angle to its former course. Then the sponge electrode is to be touched to the skin, and the current allowed to run as before. And so the operation is continued, making a number of radiating passes through the nævus with only a single point of entrance. If we are fortunate enough to strike the blood vessels, one operation will be enough, but most often we will have to repeat the operation once or twice. Instead of a single steel needle we may use a steel needle attached to the negative pole and a gold or platinum one attached to the positive pole and introduce both at the same time, the current being turned on by an assistant as soon as the needles are both in place. After several operations it is well to let the patient alone for some weeks, as the

effect of the operation continues for some time after active work is stopped. Then if the cure is not complete the operation may be repeated. If the patient is an infant it can be held firmly and no anæsthetic is needed, as the pain ceases at once as soon as the operation is over. For a few minutes the infant cries from fright, and then smiles as if nothing had happened. If the child can not be held an anæsthetic must be given.

If for any reason electrolysis can not be used, small cavernous angiomata can be destroyed by touching them with fuming nitric acid in the same way as is described in speaking of port wine mark. They may also be destroyed by puncturing them with a shoemaker's awl heated to a red heat and allowed to cool to a black heat. This may be used in the large angiomata, as may also surgical methods of excision and tying the arteries. But I will not go into the surgical methods of treating these tumors, as there are others here better qualified to speak of them. I would only say that they have been successfully treated with the galvano and Pacquelin cautery, and would emphasize my belief that the best and most conservative method of treating the smaller ones is by electrolysis.

Pigmentary nævi may be destroyed by electrolysis, the needle being passed under them from side to side in a series of parallel lines. Touching them with fuming nitric acid, if done with care as in vascular nævi, will give much more rapid results and quite as satisfactory in the larger patches. In small nævi electrolysis is to be preferred. The application of pure carbolic acid will remove some of those of light brown color. As soon as the scaling from the application is over a second application should be made, and so on. Glacial acetic acid will also remove these nævi.

In *hairy nævi* electrolysis is the only really satisfactory agent for removal that we have. It should be used as in the removal of superfluous hair, and when done with care there will remain a scarcely perceptible scar. If hairs occur in pigmentary or fibrous nævi they should be destroyed before the underlying nævus is attacked. Fortunately the hairy nævus usually does not annoy until the patient is old enough to give us his aid in treatment. When they happen to be of large size in a child they are most difficult of treatment. Nitric acid is practically all we can use.

Fibrous nævi can of course be cut off, but the cut is apt to be so deep as to leave a linear or prominent scar. Then too it is an operation attended by loss of blood even though small, and most people dread the knife. By means of electrolysis they can be removed with a slight amount of pain, with absolutely no loss of blood, and very often with-

out leaving the slightest scar. At the worst, only a very slight flat scar is left. I am in the habit of using as the negative electrode a tenotomy knife such as the ophthalmic surgeons use. I have the staff of the blade made to fit in my needle holder. This is passed just beneath the tumor, care being taken to penetrate the true skin as little as possible. When the blade is in place the sponge electrode is placed indifferently and a current of three or four milliampères is turned on. With the slightest pressure the blade sinks through the tissues which melt away with much evolution of bubbles of hydrogen gas. When one-half of the base is destroyed in this way, the blade is reversed and the other half of the base is destroyed. It leaves a moist surface which may be covered with collodion after disinfection. In a few days the wound is healed. One operation is usually sufficient, but the patient should be seen in a month or two and if there is any point that is not destroyed it should be treated again with electrolysis.

Freckles resemble pigmentary moles, as they are deposits of pigment in the skin. They differ in not being permanent, and in their origin, they being caused by the action of the sun. Blonds freckle more than brunettes. The true freckle fades in winter and becomes more pronounced in summer. Children and young people are affected more than adults. We are sometimes asked advice in regard to their removal. We can do more in the way of prevention than of cure. The wearing of veils will prevent them to a certain extent, but is a nuisance. Keeping the face constantly covered when outdoors with a lotion containing a pigment will also prevent them to a certain extent. My favorite prescription is calamin 1.3, zinc oxide 4., glycerine 8., aquæ calcis 24., aquæ rosæ ad 120. There is little use in removing them as they will return. They may be faded out with peroxide of hydrogen, or removed by blistering the skin. The favorite blistering agent is bichloride of mercury, 2 grains to the ounce, applied on cloths until the skin reddens. It is then stopped and the old skin is allowed to peel off. This should be done a week or ten days before the patient wishes to appear in public. Usually brides apply for this treatment. A twenty per cent solution of resorcin in equal parts of alcohol and water applied three times a day, or pure carbolic acid, will accomplish the same end. The ointment of the ammoniate of mercury with ten per cent of bismuth has a reputation for the removal of freckles.

Xanthoma, another facial blemish, is a yellow patch which comes in the eyelid. Usually there are several patches in both eyelids. They are soft and velvety to the touch, and give rise to no subjective symptoms. As they are unsightly we are sometimes called upon to

remove them. Here again electrolysis is the best agent for their removal. The fine steel broach attached to the negative pole of the battery should be passed under them from side to side and a current strength of about two milliampères used. Several passes through them at about an eighth of inch distance should be made. In this way they are destroyed without causing any deformity of the lid. They may be cut out or destroyed by caustics, but these agents are not so manageable and are more prone to cause contraction of the lids.

So much has been written about the destruction of *superfluous hair* by electrolysis that I would not speak of it to you now but that I still hear of physicians who advise against the operation, and tell the patient that the hair will come back and that deforming scars will result. It is strange how dense some folks are! When the operation is done with care and by an experienced hand, it is a perfect success, and as a rule leaves no scars, almost never any unsightly ones. As we have to destroy a very small point, the hair papilla, it is impossible to strike it every time, and some few hairs will return no matter how skilful we may be. Perseverance will result in the destruction of these. It is impossible to prevent a few fine scars on the upper lip in the form of dot-like white points. There are also some delicate skins that will show those dot-like cicatrices anywhere on the face. But they are hardly perceptible except in a strong light, and are always preferred to the hair. Only once in the hundreds of cases that I have worked on have I seen a bad scar, and that was due to the chin being frozen. If you take time, work no oftener than once a week on the same part of the face; leave at least one hair between every two that you destroy at any one sitting; use a sufficiently fine needle; and do not let the current run too long in any one follicle, you will not leave scars.

Radiotherapy is the latest method proposed for the removal of hair. It is still on trial. The operation must be done over and over again, and it is still too soon to speak with certainty of its being a permanent cure. It sometimes leaves a pigmentation that is more unsightly than the hair, and an unpleasant wrinkling of the skin. If it proves itself in time a reliable means for permanently destroying hair it will be a great boon, as it is entirely painless. At present I would not advise it except in extensive hairy nævi in children, as I have seen so many unexpected ugly burns caused by the Roentgen rays that I am afraid of it. But in hairy nævus it is worth while to assume the risk so as to get rid of the hair temporarily at least and give us an opportunity of attacking the pigmentary base with fuming nitric acid.

EDITORIAL

THE FIFTH INTERNATIONAL DERMATOLOGICAL CONGRESS.

INVITATIONS have been issued to attend the sessions of the Fifth International Dermatological Congress, to be held in the city of Berlin, Germany, from the 12th to the 17th of September of the current year. The presidency of the Congress has been conferred upon a distinguished representative of dermatology in Europe, Dr. E. Lesser; the Secretary-General is Dr. O. Rosenthal, well known for his scientific contributions to the themes that will occupy the attention of the Congress in September.

The invitation for attendance to the dermatologists of this country will scarcely pass unheeded. The value to them and to the world of science accruing from the work done in the four Congresses preceding has not been overestimated. Not the least among the rewards offered by these gatherings of men interested in the same field of research is the intimacy resulting from personal contact with physicians who have attained distinction in this special department of medicine, and who have come together from what to-day may justly be described as all parts of the civilized world. A review of the subjects discussed in the four volumes that have been published of Transactions of the preceding Congresses, even on cursory examination, establishes the fact that there are few subjects considered which without these contributions can be intelligently discussed from the point of view of the latest investigation. The papers published in these Transactions relative to the lichen group, pityriasis rubra, pemphigus, and the several forms of bullous dermatitis, tuberculosis of the skin in its several manifestations, the vegetable parasites, and the important questions relating to the cutaneous and other manifestations of syphilis, have become an essential part of the literature of modern medicine.

An exceedingly interesting feature of the Congresses held previously has been furnished by the gallery expositions, in which have been displayed illustrations of diseases of the skin in models, pathological specimens, photographs, paintings, etc. Even, however, exceeding these in the matter of importance to members in attendance have been the opportunities for clinical observation of patients affected with diseases of the skin. These clinical demonstrations have included not only the common, but the rare and important diseases, seen for

the most part only in those large centers of population in which the expert can collect during a relatively short period of time and from a wide area of distribution, groups of cases ordinarily observed elsewhere only at long intervals and in isolated instances. Still more important, however, from the point of view of the interests of nomenclature, is the opportunity which has thus been afforded of interpreting what may be termed the local dialects of physicians in various parts of the world into an intelligible language of science. Out of the confusion which has arisen from the expression of diverse and often conflicting opnions, these conferences have at times resulted, if not in the establishment of a single and accepted title for a cutaneous affection, at least in practical unanimity respecting the morbid condition to which a needless number of designations refer. Through the opportunities for personal contact afforded in these gatherings, physicians have learned to associate with the thing, the several and often confusing terms in which that thing is designated in different regions and countries. A vast and towering Babel has been in process of building, in the tearing down of which every disciple of science must take an interested part.

No one can doubt that the Berlin Congress from every point of view will be superior in value and importance to those held in Paris, Vienna, and London. The resources of the great metropolis unquestionably will be sufficient to crown with success the labors of our German *confrères*.

The subjects announced for the special consideration of the congress are as follows:

1. *Hautaffektionen bei Stoffwechselanomalien.*
2. *Syphilitische Erkrankungen der Zirkulationsorgane.*
3. *Die Epitheliome und ihre Behandlung.*
4. (a) *Stand der Verbreitung und der Bekämpfung der Lepra seit der ersten Lepraconferenz im Jahre,* 1897.
   (b) *Der gegenwärtige Stand der Lehre von der Lepra anæsthetica.*

The dermatologists of the United States and Canada are invited to communicate at an early date with either the General-Secretary or the Secretary for America, announcing their intention to be present and to take part in the proceedings by contribution of papers or exhibits. Details relating to rules governing the Congress and the measures to be taken for registration, securing of space for exhibits, etc., will be found on another page. J. N. H.

NOTICE.

Fifth International Dermatological Congress, Berlin, September 12-17, 1904.

LAWS.

1. The Fifth International Congress of Dermatology and Syphilis will take place in Berlin from the 12th to the 17th of September, 1904.

2. The meetings will be held in the auditory of the pathological anatomical Institute of the "Charité."

3. All duly qualified medical men, German and foreign, approved by the Executive Council, who shall have enrolled themselves by September 1st, 1904, and shall have paid the fee for membership, shall be members of Congress.

The fee for membership shall be 20 marks (25 francs or £1.) and entitles members to the volume of Transactions.

Tickets of membership will be distributed in the rooms of the Congress, on presentation of the receipt for subscription fee.

Subscriptions may be addressed either to the Secretary General or to one of the foreign Secretaries.

4. At the first meeting, the officers of the Congress shall be elected by the committee of organization.

5. The meetings of the Congress shall be public.

6. Members may express themselves in English, French, Italian, or German.

7. The program of the proceedings shall be prepared beforehand by the committee, and distributed to the members before the opening of the Congress.

8. The subjects for discussion shall be of two orders, those selected by the committee and those chosen by individual members of the congress. Each of the subjects selected by the committee shall be introduced by special reporters.

Members contributing papers on other subjects must give notice to the Secretary General before July 1st, 1904. Such papers must not have been published or read before any society before the opening of the Congress.

No paper may last more than a quarter of an hour, and in the discussions no member may speak for more than ten minutes; should there be many speakers ,the president will have the right to reduce the time to five minutes. The time over, the president has to ask the meeting for a prolongation.

9. Manuscripts of all papers and of all remarks in debates must be left with the Secretary General before the end of each meeting.

10. The Executive Committee shall decide as to the entire or partial publication of papers in the Transactions of the Congress.

The debates shall be reported in German, but papers in English, French, or Italian shall be published in these languages.

11. A Museum of models, photographs, and drawings, histological and bacteriological preparations will be opened in the rooms of the Congress; another one of instruments and chemical products will be in a special room.

General Secretary: President, PROF. DR. E. LESSER,

Dr. O. Rosenthal, Sanitätsrat,
Berlin, W. Potsdammer Str. 121g.

Secretary for the United States of America:
Dr. James Nevins Hyde, Chicago.

SOCIETY TRANSACTIONS.

BOSTON DERMATOLOGICAL SOCIETY.

Regular December Meeting, 1903.

Dr. J. H. McCollom in the Chair.

A Case of Syphilis. Presented by Dr. G. F. Harding.

The patient is a married woman, aged forty-four years. She said she had had a generalized eruption over her body ten years ago for which she had been treated intermittently for two years, at first by liquid medicine and later by pills. No cutaneous symptoms had appeared for a period of six years after cessation of treatment, but since that time, that is during the last two years, she has had several outbreaks on various parts of her body which have never lasted more than three weeks at a time.

At present, she has at the right angle of her mouth a split, moist papule. Below it, on the lip, there is a group of two or three papulo-pustules arranged peripherally on an indurated, reddened base. On the inside of her cheek there is an eroded plaque and finally at the base of her tongue appears a triangular space devoid of epithelium and studded with a few papules.

Dr. James C. White said that the lesions about the mouth were not inconsistent with a recurrent herpes, but thought that the history rendered a diagnosis of syphilis necessary.

Dr. Post thought that the lesion on the inside of the cheek could be easily accounted for by the irritation caused by the patient's false teeth and he believed, contrary to what many dentists had told him, that such lesions could be produced by the presence of false teeth. He also wanted to state that a split papule at the angle of the mouth did not necessarily

mean syphilis, for he had seen exactly similar lesions follow in the wake of herpes. Nevertheless, considering all these lesions as a whole and the area upon the tongue in particular, together with the history, he would make the diagnosis in this case of syphilis.

Dr. C. J. White considered the lesion on the lower lip sufficient evidence of syphilis to make that diagnosis proper in the present instance. Such a peripheral arrangement of papulo-pustules on a raised, reddened base with a suggestion of sinking in the center seemed to him quite compatible with the oft-recurring, often isolated lesions observed in late cutaneous syphilis.

Dr. Bowen differed from the last speaker and did not consider the labial lesion characteristic of syphilis, but thought that the split papule in the angle of the mouth gave reason enough to call the case syphilis.

Dr. McCollom considered the lingual involvement as due to syphilis, but he wanted to add his testimony to that of Dr. Post's, that split papules at the angle of the mouth were not necessarily syphilitic. In his scarlet fever wards it was very common to find herpetic lesions in the corners of the children's mouths during convalescence. These lesions frequently produced lesions absolutely similar to the one on the present patient's mouth, and, furthermore, these herpetic lesions in children could leave behind them scars which often closely resembled the radiating cicatrices so commonly regarded as pathognomonic of hereditary syphilis.

Dr. Harding considered the case to be syphilis and thought that the appearance of the tongue alone would warrant such a diagnosis.

A Case of Erythema Induratum(?). Presented by Dr. H. T. Towle.

The patient is a married woman, aet. thirty-three, at present in Dr. Bowen's ward at the Massachusetts General Hospital. The paternal grandfather had hip disease and the mother died of phthisis pulmonalis. The patient has always considered herself well and gives no history pointing to any past trouble with her lungs. The present cutaneous condition first appeared four or five years ago, commencing in the autumn and since then the disease has returned every year upon the advent of the cooler weather, has persisted throughout the winter and has disappeared regularly about the month of April. The lesions have always developed in the same manner and have always been confined to the same regions. The first symptom is a slight soreness over the calves of the legs. Inspection reveals nothing, but palpation allows one to feel bean-sized nodules beneath the skin. The over-lying skin soon grows red, then purple and finally desquamates, and during this period the nodules begin to disappear. The tenderness which has been marked up to the purple stage also fades away. These nodules make their appearance, one at a time, and each individual passes through the cycle just described. While the lesions are forming the patient suffers from grippe-like pains in the legs and notices some

œdema of the feet. She states further that two years ago, for the first and only time, three of the nodules suppurated and on healing left scars.

One year ago a small gland appeared on the left side of the neck and remained without change for nine or ten months when it disappeared of itself. About this same time the glands on the right side commenced enlarging and have been growing ever since.

Examination reveals a woman slightly anæmic but well developed and nourished. Dr. J. M. Jackson, of the out-patient staff, has examined her lungs and reports moist râles with increased tactile fremitus in the right supra-clavicular fossa and these signs, in connection with the glandular swellings, he considers as highly suspicious of tuberculosis. The sputum examination has not been completed.

The blood examination by Dr. Rowly shows 8,000 leucocytes consisting of polynuclear elements 56.5 per cent., lymphocytes 39 per cent., eosinophiles 4 per cent., and mast cells 0.5 per cent.

At present thorough examination of the skin finds the disease limited to the lower legs. Over the calves are numerous dark red and purple areas varying in size from a bean to a walnut, while on the front and sides of the legs similar but more sparsely distributed lesions appear. The color does not disappear on pressure. Beneath these discolorations one can feel well-defined, indurated masses which are firm, slightly elastic, somewhat sensitive, and, except for a slight attachment to the skin, freely movable. Their average size is about that of a cherry and for the most part they elevate the overlying skin, but whenever discoloration is absent sight alone does not reveal their presence.

On the front and inner aspect of the left leg there is a much larger area, perhaps two inches in diameter, infiltrated, dull red and rather soft to the touch. This does not appear as an isolated nodule, but more as a rather vaguely defined, superficial infiltration with the suggestion of a central necrosis.

Dr. Bowen considered the case to be an example of Bazin's disease, but the curious periodicity and its appearance in winter alone made the diagnosis a little doubtful. He thought one was justified in ruling out the purely bacillary forms of skin tuberculosis and also ordinary types of cellulitis and syphilis, while the present condition of the patient's lungs and glands, and the family history made him consider it a tuberculide.

Dr. Harding acquiesced in the diagnosis of erythema induratum.

Dr. C. J. White agreed with this opinion, but he wished to emphasize the anomalies present. The periodicity was certainly unusual, while the appearance of a majority of the lesions, especially the larger ones, on the anterior and lateral portions of the legs was quite irregular.

Dr. James C. White said that in erythema induratum he had never seen so many small lesions nor so few large ones, and he had never known of such a periodicity, nor of such short duration of individual lesions.

Moreover, the site of the nodules was atypical. In his experience he was wont to find erythema induratum not in broken down girls, but rather in big, rather healthy ones. He would consider this another type of tuberculide rather than erythema induratum.

Dr. Towle thought that the periodicity was the strongest factor against the diagnosis he had offered. Vision, apparently, showed in this case that the lesions were more abundant anteriorly, but palpation showed that the majority of the nodes, though smaller, were situated posteriorly. He had called the case erythema induratum because he had not been able to find a more appropriate title for it.

A Case of Epithelioma. Presented by Dr. Post.

A woman, fifty-six years of age, presented on the side of her face an abnormal area of skin extending in the form of a square from the right side of her nose to the middle line of her right eye and from the right lower lid to a line level with the upper border of her right nostril. This area had begun to develop eight years ago without any apparent cause and had spread peripherally ever since, the greatest rapidity of growth having occurred during the last two years. The involved skin is slightly atrophied and sunken and for the most part reddened, but in places appears moist and whitish. On the right ala of the nose there is an irregular line of broken epidermis. The border along the right perpendicular boundary, is slightly raised, firm and whitish, but presents no pearl-formation, while the other boundaries of the lesion are practically level with the adjacent healthy skin and the dividing lines are simply ones of color and appearance rather than of level and consistency.

When first seen, about six weeks previously, there was a considerable exulceration about the nose, but under iodide of potash and applications of mild citrine ointment the skin had entirely healed with the exception of the irregular linear break above referred to.

Dr. Harding diagnosticated the case as a superficial spreading epithelioma. Syphilis and tuberculosis were other possibilities, but the raised, whitish border on the right boundary of the lesion pointed directly to epithelioma.

Dr. C. M. Smith said that he had seen the case at an earlier date and had thought then that the condition resembled syphilis more than cancer. However, he would now call the disease epithelioma.

Drs. McCollom, C. J. White, Towle and F. S. Burns agreed with this diagnosis.

Dr. James C. White stated that he had seen exactly similar appearances produced in lupus erythematosus after treatment by caustics. He did not agree with one of the previous speakers who would exclude the diagnosis of epithelioma whenever firm, hard edges were wanting, and in this case he would certainly call the condition epithelioma. Some years

ago he had seen a very similar condition in a patient who had had the disease for thirty years, illustrating well, as in the present case, how benign epithelioma may sometimes be.

Dr. Bowen regarded the case as a benign rodent ulcer showing little tendency to ulcerate or to grow downward into the tissues.

Dr. Post confessed that he had not previously made any positive diagnosis and was greatly surprised at the unanimity of opinion expressed by the society, especially after the history of the rapid healing of the ulceration under anti-syphilitic treatment.

Dermatitis Herpetiformis or Syphilis? A case presented by Dr. Post.

The patient was a stationary engineer, a Nova Scotian by birth, aged thirty-six. Three weeks ago he had come to the Boston Dispensary with an abundant eruption on his skin which dated back two months. The first lesions appeared on the buttocks and seemed to the patient like hard kernels out of which he could squeeze a "worm-like" mass. The lesions have gradually spread and wherever present are accompanied by local pruritus. On inspection one finds the eruption limited to certain areas. In the scalp, confined mostly to vertex and to adjacent lateral areas, there are many excoriated, rather bloody papules. In the neck are large, hard glands, but the patient claims that they have "always" been present. Along the crest of the ilia, extending down over the head of the femurs and backward over and to the lower part of the buttocks, over the sacral region, at the bend of the knees, over the patellæ and perhaps scattered elsewhere at rare intervals appear small grouped lesions about three-eighths of an inch in diameter. These apparently develop as small, flat, red, moist papules which spread and in their peripheral development suggest the formation of rings. A few of the lesions are undoubtedly bullæ with slightly hæmorrhagic contents, but Dr. Post is positive that none of these lesions were present until after the application of a mild citrine ointment recommended by him.

Dr. C. J. White made the diagnosis of dermatitis herpetiformis, basing this statement on the presence of bullæ (few, to be sure), the great and marked symmetry of the eruption, the groupings and tendency to ring formation of individual lesions and lastly the pruritus.

Dr. Burns agreed with this diagnosis, but wanted to suggest the possible presence of erythema bullosum.

Dr. Towle would not commit himself so closely to a name, but would rather call the case one of bullous dermatitis.

Dr. James C. White did not want to rule out the possibility of syphilis, but would rather incline his opinion toward dermatitis multiformis.

Dr. Bowen said that if he could establish firmly in his mind that the bullæ were not artificial he would certainly vote in favor of dermatitis herpetiformis.

Dr. Harding favored the diagnosis of syphilis, and felt that the disease had not been studied or observed long enough to warrant the diagnosis of dermatitis herpetiformis.

Dr. Post called the case syphilis and reiterated his statement that the bullous lesions were not observed before the application of his citrine ointment. He thought that the presence of blood in their contents was against the probability of dermatitis herpetiformis, and he made the diagnosis of syphilis because the lesions resembled syphilis.

A Case of Syphilis in a Negro. Presented by Dr. C. M. Smith.

The man was a caisson-worker, thirty-two years of age. He said that he had had a chancre on his penis three years ago which had yielded to external treatment in about three weeks and pointed to a depressed, pigmented scar as evidence of his story. Now over his trunk and scattered less abundantly over his extremities appear fine, acuminate, grouped, scale or crust-tipped papules and pustules, which often affect the follicles of the skin. On the back the lesions extend from the neck to the lower buttocks and seem to avoid the spinal region tending to group themselves especially over the scapulæ and nates. In front, the same eccentric distribution is noticeable. The palms of the hands, the face, the neck, the scalp and the soles of the feet are practically free, while all subjective symptoms are wanting.

Seen from a distance the picture of the papules alone was certainly suggestive of keratosis pilaris, but nearer inspection and the localizations of the lesions upon the trunk rather than upon the extremities would naturally exclude such a diagnosis.

Dr. C. J. White could not reconcile the history of the chancre three years ago with the present eruption and, therefore, did not make the diagnosis of syphilis, but suggested a possible iodide eruption.

Dr. Burns coincided with this opinion.

Dr. Post believed the case to be syphilis, but would not commit himself positively. However, the distribution of the outbreak, the enlargement of the glands and the multiformity of the lesions all pointed toward syphilis in his mind.

Dr. James C. White thought that possibly the ulcer might not have been a syphilitic one and would, therefore, perhaps, look upon the present eruption as an original outbreak of the disease. On the other hand, he wanted to bear in mind the possibility of drugs as the causal agent.

Drs. Bowen and Harding considered the case to be syphilis.

Dr. McCollom agreed with this diagnosis, but wished to call attention to the absolute similarity of some of the lesions present to the early papules of variola.

Dr. Smith, in closing the discussion, said that there was no positive evidence that the man had ever had syphilis three years ago and that he

had at first regarded the present eruption as one of secondary syphilis. He had noted, however, that he could squeeze out of many of the papules a cheesy, perhaps rather spine-like matter, which had rather shaken this diagnosis.

PRESENTATION OF X-RAY PHOTOGRAPHS BY DR. POST.

Dr. Post said that syphilis manifested itself most frequently in the skin, but that next in order of involvement came the bones. He then showed about a dozen interesting skiagrams illustrating very clearly the force of his statement. One is not apt to regard the fibula as participating in the syphilitic disease of the bones. We all recognize the malformations of the tibia, but are not so well versed in the possibilities of syphilitic osteitis of the fibula. The photographs showed remarkable pictures of involvement of the fibulæ, one exostosis on the lower end reaching almost to the ground. Other pictures showed syphilitic exostoses and osteophytes on the femur, ulna, radius and clavicle.

Charles J. White, Secretary.

REVIEW
of
DERMATOLOGY AND SYPHILIS

Under the Charge of John T. Bowen, M. D.

INFECTIOUS GRANULOMATA.

By H. G. Anthony, Chicago.

Erythrodermia Exfoliativa Universalis Tuberculosa. F. Bruusgaard. (*Archiv. f. Derm. u. Syph.*, Vol. 67, page 226.)

A woman, sixty-three years old, developed an inflammation of the skin, which beginning on the calf of the leg, gradually extended and became universal in a few months. When the disease was fully developed the integument was of a deep red color, markedly infiltrated and the epidermis was undergoing exfoliation which was lamelar in places. There were no weeping surfaces present. The nails and hair were affected early in the disease and were gradually exfoliated. Th lymph glands were enlarged.

The clinical picture present was that of a severe disease. From time to time exacerbations of inflammation occurred, during which the entire cutaneous surface was not equally affected. The attacks were accompanied by fever, dyspnœa and severe itching. As the general condition of the patient grew worse the attacks decreased in frequency and in intensity, finally ceased to appear, and then reappeared in a mild form. As the

patient grew weaker, cachexia, a peculiar pigmentation around the hair follicles, and universal swelling of the lymph glands, developed rapidly.

On post mortem examination the bacillus tuberculosis was found in the lymph glands; and in some of the specimens of the skin taken here and there from various parts of the body, tubercles were found in the papillary and subpapillary layers of the skin and around the hair follicles. In the liver and spleen miliary tubercles were present and there was a tuberculous ulcer in the ileum. The case was one of primary tuberculosis of the lymph glands in which emboli of bacilli were carried by the blood vessels or lymphatic channels into the skin, producing an inflammation. The clinical picture here presented differs from pityriasis rubra of Hebra chiefly in the degree of inflammation present.

Delhi Boils. Malcolm Morris. (*Brit. Med. Jour.*, 1902—page 130.)

An officer of the Indian medical service was affected with Delhi boils on the arm. The lesions were probably contracted from a dog. They were in no sense of the word boils, but resembled the verrucous form of lupus of the extremities.

MacLeod performed the microscopical work in the case, of which the most important finding was cellular infiltration of the corium. Blastomycosis, which is the first possibility of diagnosis which would be considered in such a case in any clinic of our country, is not even mentioned in the clinical or microscopical report of the case.

Lupus, the Pathogenesis of. L. Philippson. (*Arch. f. Derm. u. Syph.*, Vol. 57—page 73.)

The development of radiotherapy has awakened the interest of the general practitioner in lupus. A study of the cases which have passed through the hands of physicians who are not dermatologists shows that they are treating all cases in a routine manner and without a comprehension of the pathogenesis of the disease, which is not surprising considering the fact that even our latest text-books on dermatology exhibit a lack of knowledge of the fact that lupus is not usually a local skin affection.

There are two diseases included under the diagnosis lupus; primary or inoculation tuberculosis which begins in adult life and which should be called tuberculous granuloma, and secondary lupus which constitutes the majority of cases and which begins in childhood. The primary focus of tuberculosis from which the secondary form of lupus is derived is most frequently to be found in the mucous membrane of the nose, in the lymph glands, joints, tendon sheaths, and the bones.

Where a sinus leads to a dead bone, it is easy to find the origin of the disease, but where the bone disease is situated deeply or where the primary affection has healed, the origin of the disease cannot always be

determined, and that is the reason that we were so late in learning that lupus is a secondary disease.

Since the publication of Adenot's article (*Revue de Chir.*, 1893), Philippson has found that most cases of lupus of the extremities in children are derived from bone disease. Starting from the bone, tuberculosis may extend through the deep tissues and produce œdema and chronic hypertrophy of connective tissue, and lastly lupus. In two such cases of elephantiasis and lupus of an extremity, the author, following a fistula, came upon cavities which were the remains of former abscesses originating from bone. Lupus may develop long after the osteopathy or adenopathy from which it is derived has healed.

Following the acute exanthemata a tubercular thrombus carried into the general circulation from a deep seated tubercular nodule of the visceral organs or mesenteric glands, being deposited in the skin causes lupus more frequently than is generally supposed.

Patients do not know of previous existing tubercular deposits or of the presence of distant foci of disease and hence they pass undetected unless carefully sought for by the physician.

There are three kinds of lupus of the nose: the disease may originate in the skin and extend to the mucous membrane of the nose; it may originate in the mucous membrane of the nose and extend to the skin, or thirdly it may be the true secondary variety associated with scrofula. From this it will be seen that there can be no routine method of treating lupus, the treatment must remain that of scrofula, surgical tuberculosis of joints and bones, lymph glands, nose and throat. The best results of treatment with Finsen rays are obtained in cases of tuberculous granuloma, and these are the ones in which good results were always obtained. Light treatment is the best local treatment which we possess but it is not our only treatment and above all it is not a routine treatment.

The statement made by Besnier, that there was no routine method of treating lupus and that each case gave rise to special indication of treatment, according to form, variety, depth, and extent of the disease, is as true to-day as when it was written twenty years ago.

DISEASES OF THE SEBACEOUS AND SWEAT GLANDS,

By H. G. Klotz, M.D., New York.

Dermatitis Follicularis et Perifollicularis Conglobata. Ludwig Spitzer. (*Dermat. Ztsch.*, 1903, X, p. 109.)

Under this name Spitzer describes a chronic affection of the hair follicles and sebaceous glands which principally occurs in individuals who exhibit a peculiar development of plump comedones in pairs or groups, frequently the so-called double comedones and numerous white scar-like depressions, which, according to Lang, are really

atrophies and not true cicatrices. The disease begins as small, bluish red nodules open around a comedo, not painful; they increase to the size of a bean and then begin to break down, discharging detritus, epithelia, pus and giant cells. These foci are found in smaller or larger groups and may run into larger nodules. On the occiput and in the axillæ they communicate under bridges of apparently normal skin with larger cavities with numerous openings, out of which pus can be expressed. Here deep destruction of the skin and extensive cicatrization can take place. The process may extend over the entire body and be indefinitely prolonged.

Microscopical examination shows that owing to chronic irritation by the accumulated horn masses in the comedones, the wall of the follicle develops a granulation tissue very rich in cells with proliferation and protrusion of epithelia. Gradually the epithelium disappears at the fundus and the granulation tissue becomes exposed. Bacterial infection leads to secondary suppuration and dissolution of the granulation tissue with widely distributed subcutaneous destruction. Spitzer believes that these cases, although nearly related to acne, ought not be classed under that name.

Hyperidrosis Universalis, A Contribution to the Knowledge of.

FRIEDR. MÜLLER. (*Münch. Med. Woch.*, L. 1954, 10 Nov., 1903.)

A nurse, twenty years of age, heretofore in good general health, except irregularity of menstruation, (every five to eleven weeks for two to four days,) after very exacting work during the winter developed profuse sweating in April, 1901, at first only during the day, but later on also at night. Menstruation had ceased; on its return in May and June, perspiration became somewhat less, but increased again after renewed and permanent cessation of menses. In May an eczematous eruption began on the sternal region, rapidly spreading and increasing in intensity with the progress of sweating. Loss of appetite and sleep (principally due to the eczema) greatly reduced the general condition (loss in weight from May to December forty pounds). On admission to the clinic of Prof. Kast, all organs were found in good condition except a distinct hypoplasia of the uterus, and no other symptoms but tachycardia were observed. On removing the bed covers the body would appear covered with big drops of sweat; after being dried they would reappear in one-half to one minute. The eczema was almost healed with the exception of the axillæ and beneath the pendulous mammæ. The part most affected was the breast, then followed the abdomen, back, face, lower and upper extremities; slight remissions were observed, but no intermissions. A change of clothes was necessary nine to eighteen times in twenty-four hours, at an average fifteen times, in January, 1902; in February nine to twenty-three, with an average of eighteen, and in March more than

twenty times. Considering the enormous loss of fluid the quantity of the urine remained quite high; on February 2, 2200c.c. of 1012 spec. grav. was voided, on other days 500 at 1020 to 1033, averaging about 1000 c.c.; the pulse was between 110 and 120, respiration somewhat increased in frequency, temperature normal.

The general health was considerably affected by psychic depression, and as none of the usual methods of treatment had shown the slightest favorable effect on the condition, the patient left the hospital in March to go into the country. A slight improvement was reported in April, but in June the former conditions returned and after two months her death was reported.

The author points to the fact, that the symptoms present were exactly those which follow excess of mechanical work, an increase of oxydation. He considers as the immediate cause an increased irritability of the sweat centers in the cortex cerebi, medulla oblongata and the gray cornua anteriora of the spinal cord. He looks upon the case as one of the numerous forms of neurasthenia, acquired and not hereditary. The possibility of a tumor of the brain cannot be excluded, particularly in the absence of an autopsy or some definite report on the death of the patient.

Acne, A New Treatment of Certain Cases of. A. Rose. (*Med. Brief.*, XXXI., 1327, 1903.)

A patient who was treated for gastroptosis by strapping of the abdomen with adhesive plaster, was incidentally cured of an acne of long standing.

Baker's Acne. Galewsky. (*Münch. Med., Wchensch.*, 1903, XXXVIII, p. 1636.)

A physician for the Baker's Union in Dresden, *Galewsky*, observed sixty-six cases of acne and comedones among one hundred and eighty-one cases of skin disease, most of them between sixteen and twenty-two years of age. He believes that the age, the poor general conditions followed by anæmia, the dust of the flour (also acne is not infrequently observed in millers), and the temperature of the oven favor the development of the disease among the bakers.

Acne Vulgaris, Treatment of with Roentgen Rays. Ludwig Török and Moritz Schein. (*Wien. Klin. Rundscheu*, 1903, XVII, p. 665.)

Severe cases of acne which had resisted all other treatment, usually gave excellent results with the X-rays. This effect is not due to reactive hyperæmia, but to different circumstances.

(1) The destruction of the lanugo hair, which resists longer than the

ordinary hair; its destruction favors the emptying of the contents of the follicles after a temporary increase of the same.

(2) The restriction of the secretion of the sebaceous follicles owing to increased cornification of its parenchyma..

There is no antiparasitic effect. After one course of treatment relapses occur after five to six months, but rarely after a second treatment.

SYPHILIS OF THE NERVOUS SYSTEM

By J. M. Winfield, M. D., Brooklyn.

Syphilis of the Central Nervous System, Remarks Upon the Pathological Anatomy of. Dr. Erb. (*Deutsche Zeitsch. f. Nervenheilkunde.*, Vol. 22, 1902, Parts 1-2.)

The paper is an analysis of a number of presumably syphilitic cases with cerebral lesions, collected from the literature. From a careful study they are classified as follows: First, gumma, meningitis, myelitis, arteritis, with direct degenerations of known specific origin; in all there was a history or a strong suspicion of syphilis. Second, typical degenerations not apparently specific, but showing specific changes in the bloodvessels, cord and meninges. And third, primary scleroses in syphilitics, without any associated specific lesions. He summarizes his results as follows:

That there are, in some cases of undoubted syphilis of the nervous system, changes that resemble primary degeneration; in others the primary degeneration is the predominant feature and the syphilitic changes are slight, and also degenerations without syphilitic changes in persons who have syphilis.

He believes there is no reason to think that the absence of syphilitic lesion is proof that the nerve process is not syphilitic.

Para-Syphilitic Affections, the Curability of Tabes and General Paralysis by Intense Mercurial Treatment. Leredde. (Paris, France.) (*Phil. Med. Journal*, Feb. 10th, 1903.)

The author is absolutely convinced that in syphilitic patients these diseases are not only syphilitic in origin but can also be cured by mercury, providing the dose is pushed to the highest limit.

He considers tabes and general paralysis not diseases with a single etiology but that they are anatomico-clinical conditions, and that they are not only syphilitic in origin but also syphilitic in nature.

Cerebral Syphilis. A. E. Brownrigg. (*Boston Med.-Surg. Jour.*, Jan. 15th, 1903.)

In speaking of cerebral syphilis the author states that there are no pathognomonic symptoms or group of symptoms in the diagnosis of syphilis of the brain, but the chief points that help toward a suspicion of the

disease are: First, headache and vertigo. Second, nausea and vomiting. Third, optic neuritis. Fourth, cranial nerve palsies or paralysis. Fifth, apoplectiform paralysis, somnolence or coma and partial hemiplegia. Sixth, irritability and general mental failure. Seventh, polyuria and polydipsia. Eighth, marked remittant character of all the symptoms.

Cerebral Syphilis, Dementia with Nuclear Degeneration of Some Cranial Nerves, and Atrophy of One Half of the Tongue. HAROLD M. MOYER. (*Jour. of Nervous and Mental Dis.*, Feb., 1903.)

A patient with the following history was presented before the Chicago Neurological Society:

Male, aged thirty-seven, no previous history of illness except an indefinite one of syphilis ten or fifteen years ago. In 1898 he consulted a specialist for paralysis of the vocal cord which improved under treatment. Autumn of 1901 he had a "sinking spell," was tired and inclined to sleep a great deal; shortly after was attacked with vertical diplopia, complained of pain over the eyes at the top and back of the head; became incapable of mental concentration; the throat paralysis reappeared making swallowing difficult. Dr. Moyer found paralysis of the right external rectus muscle, and a typical Argyll-Robertson pupil of the same side. The tongue was atrophied on the left side. Although there was no definite history of syphilis, anti-syphilitic treatment was instituted, which appeared to clear up some of the symptoms.

Tabes, General Paralysis, and Charcot's Joint. S. J. WALKER. (*Journal of Nervous and Mental Dis.*, Feb., 1903.)

A patient with this history was presented before the Chicago Medical Society:

Male, aged forty-four, never had any severe illness, but the man undoubtedly had had syphilis when about thirty. Ten years ago he had an attack of what was called rheumatism, the pains being of a lancinating character, which had continued at irregular intervals ever since. Seven years ago an ulcer appeared at the base of the right big toe. The lesion being intractable to treatment the toe was amputated. A little later he noticed he could not walk well in the dark. Experienced some difficulty in urinating, a relative incontinence. He had no ocular symptoms of any kind. Seven months before he was shown to the society he fell and sprained his right ankle; after the inflammatory swelling had subsided the joint remained larger. The condition of the patient gradually grew worse, he showed marked impairment of memory and lack of mental concentration, and upon ocular examination an Argyll-Robertson pupil was found. The diagnosis was tabes, Charcot's joint of the right ankle and finally general paresis supervening on the tabetic affection.

Syphilis and Epilepsy, Two Cases Illustrating Certain Relations of. H. S. Allen. (*Cleveland Med. Jour.*, March, 1903.)

The article is a report of two cases of epileptiform convulsions occurring in subjects undoubtedly syphilitic. The first case was a male, aged twenty-eight. The epileptic attacks were of the grand mal type. His condition after entering the hospital gradually grew worse, finally a paralysis of the left side developed. After he was put on a saturated solution of iodide of potash (eight grammes daily) a marked improvement began. As there was a clear history of syphilis the diagnosis was epilepsy from syphilis.

The second case was a negress whose age was not given; she had been married sixteen years, no children, but had had four miscarriages. She was known to be syphilitic; she had had convulsive attacks of the grand mal type seven months before admission to the hospital. After being there a short time she died suddenly without showing evidence of convulsions. On autopsy the brain and membranes were found markedly syphilitic; the internal surface of the calvarium was thickly studded with nodules; the right middle cerebral artery was apparently obliterated; the dura was thickened. The interventricular fluid exceeded the normal quantity; there were also a number of gummata in the liver.

Gumma, an Example of Intercranial. Harry Campbell. (*The Polyclinic*, London, May, 1903.)

The patient was a woman, aged thirty-three years, who had had one miscarriage and three still births. Four months before consulting the author she complained of pain in the left side of the face and head, also attacks of vomiting which occurred without any relation to the taking of food. She also complained of dimness of vision. Ophthalmoscopic examination revealed the presence of double optic neuritis. From the combination of the above symptoms the diagnosis of cerebral tumor was made and on account of the still-births and miscarriage, syphilitic gumma was strongly suspected. Her condition improved under large doses of iodide of potassium. In concluding the writer makes a strong plea for the administration of large doses of this drug in syphilitic lesions of the nervous system.

Brain Syphilis. Samuel Ayers. (*Penn. Med. Jour.*, Aug., 1903.)

In introducing the subject an urgent plea is made for the segregation and proper control of syphilitics. The various symptoms of brain syphilis are carefully gone over, those that he considers of most diagnostic importance being continued headaches, optic neuritis, paranesthesia, lapses of memory, monoplegia and localized spasms.

A number of illustrative cases are cited. The paper concludes by emphasizing the point that first a correct diagnosis must be made and then the patient must be put under early and active anti-syphilitic treatment.

Syphilis of the Nervous System, The Diagnosis and Treatment of. Graeme M. Hammond. (*The Post-Graduate,* 1903.)

The author begins his article by stating that syphilis is a form of microbic infection producing inflammation which begins in the blood vessels and extends to the meninges and tissues of the brain and cord. Gumma and exudates are the natural results of this inflammation. He classifies the inflammatory syphilitic diseases of the nervous system in four division: Cerebral, spinal, cerebro-spinal, and syphilis of the peripheral nerves. In cerebral syphilis there may be meningitis, meningo-encephalitis or gumma. In spinal syphilis, meningitis, meningo-myelitis or gumma. Cerebro-spinal syphilis is a combination of the two above varieties. Syphilis of the peripheral nerves includes neuritis from inflammation or compression by gumma.

Beside the inflammatory diseases there are two grave degenerative processes, one of the brain the other of the cord, paresis and tabes.

The author states that if the general history of syphilis is at all obscure the diagnosis is often extremely difficult, but if a person under forty years of age should develop convulsions, defective speech, mental hebitude, partial hemiplegia without a history of traumatism, alcoholism or brain tumor, syphilis should always be suspected.

He also insists that a man who develops tabes dorsalis without a history of debauchery must have had syphilis whether he admits primary infection or not. He also emphasizes his opinion that the Argyll-Robertson pupil is a clear indication that the patient is either suffering from tabes or paresis.

The only treatment mentioned is the employment of "massive doses" of strychnia, which, in his hands has seemed to be of great benefit in these cases of syphilis of the nervous system.

Syphilitic Diseases of the Nervous System, Prognosis and Treatment of. William R. Gowers. (*Brit. Med. Jour.,* April 4th, 1903.)

The author agrees with all other writers on syphilis of the nervous system that if the history of the primary infection is clear and the syphilitic nervous symptoms are well marked, the prognosis is reasonably good; but if, as is often the case, there is complete absence of syphilitic history, together with the presence of many obscure and contradictory nerve symptoms, the prognosis becomes grave, because the syphilitic process having existed so long without treatment the injury to the delicate tissues is so great that even though the process is stopped the destruction to the brain and nervous centers is irreparable.

The iodides are recommended when a rapid effect is desired; and mercury is indicated for counteracting any inflammatory condition. He prefers inunctions of the oleate of mercury to inunctions of the ordinary blue

ointment because of the slightly counter-irritating effect of the former and of its non-telltale color. He does not seem to be a strong advocate of large doses of iodide, although he states that it is sometimes necessary to push that drug to its full extent.

VISCERAL SYPHILIS

By F. J. Leviseur, M. D., New York.

Atrophia Laevis, The So-called Glossy Atrophy of the Root of the Tongue and Its Relation to Syphilis. Fritz Lesser. (*Berl. Klin. Wchenschr.* No. 45—page 1026.)

Lewin has divided this affection into three stages. A general diminution in number and size of lymph follicles, absence of follicles in the center with preservation of a few small and hard ones near the border, and almost total absence of follicles. This classification the author thinks is of small practical value. Variations in the amount of hardness of the root of the tongue, and palpable infiltration are the symptoms of atrophia lævis. Atrophy of the follicles is due to induration of the tissues. The affection should therefore be named more appropriately glossitis lævis (posterior) or glossy induration of the root of the tongue. In order to make a clinical diagnosis the affected organ has to be palpated. Pharyngoscopical or laryngoscopical examination serves only to confirm the diagnosis. Forty-four per cent. of the patients affected are syphilitics, so that a relation between these two diseases is evident. Still there is reason to believe that other diseases may play some part in the production of glossitis lævis. The author has never found it in hereditary syphilis. The affection results in two conditions: Infiltration of the root of the tongue combined with glossiness, and the formation of star shaped scars together with increased hardness of the remaining tissue. Among a total of 166 cases, 153 belonged to the first, and only thirteen to the second variety. In ten of these thirteen cases syphilis was manifest, the remaining three showing no positive signs. Sex seems to play no decided role in the production of glossitis, a fact which proves that tobacco and alcohol are not etiological factors.

Suprarenals in Congenital Syphilis, The. N. Gulcke. (*Virchow's Archiv.* Vol. 173—page 519.)

Of all internal organs the liver is most frequently affected in cases of congenital syphilis. The kidneys come next in frequency—then lungs and pancreas and spleen. Strocbes found among thirty-four cases of congenital syphilis ten which presented lesions of the kidneys. Möller's eighteen cases were entirely free from renal changes. Affections of the suprarenals of syphilitic nature are very rare indeed. Petersen was unable to quote a single case in his tabulation of fifty-two cases of vis-

ceral syphilis. In a period of ten years not a single case of gumma of the suprarenals was seen by Winogradow, who performed a very large number of autopsies at the St. Petersburg foundling asylum. In fact, compared with tuberculosis or malignant tumors, syphilis plays a subordinate rôle in the affections of the suprarenals. Virchow states that he has seen occasionally an enlargement and total fatty degeneration of these organs. According to Orth specific changes are rare but gummatous new growths have occurred in congenital as well as in acquired syphilis.

Rolleston briefly mentions the occasional finding of gummata in the suprarenal glands. Baerensprung, describing the autopsy of a syphilitic child four weeks after birth, found the suprarenals very large, hard and their surface studded with numerous whitish granules on a greyish red very transparent background. Flecker and Buhl's case concerns a syphilitic child with sclerema. Both suprarenals were two and a half centimeters long, infiltrated, greyish and of the hardness of cartilage. Huber observed in a child fourteen days old who had been suffering from pemphigus, an enlargement of the suprarenals. They were of a greyish transparent color, showing a great many whitish irregular spots of the size of a poppy seed. Besides there were nodules of the size of a lentil, yellow, hard, mostly localized on the posterior portion of the organs. On microscopical examination they were found to consist of fatty detritus. Oberndorfe and Girode saw each a case of gumma with central cheesy degeneration; Hintzen a case of enlargement and fibrous induration of the suprarenals. In Winogradow's case the right organ was affected exclusively. It was twice the size of the left one and contained centrally a hard mass surrounded by a connective tissue capsule. It was impregnated through and through with lime salts. In the center of the mass there was some detritus and on its outside, coagulation-necrosis with preservation of cell-elements. Flecker, who described his case more in detail mentions the presence of miliary gummata in the glands. The post mortem examination in Gulcke's case was as follows: Girl born at full term, somewhat atrophic in general, the skin showing a bluish discoloration. Heart normal, lungs normal with the exception of one lower lobe which was solidified and exhibited numerous red spots. The throat and mouth pale. Thyroid, dark red. Thymus hard. Lymphatic glands normal. Spleen, hard, dark red with trabeculæ emphasized. Kidneys pale yellowish, but otherwise normal. Both suprarenal glands of unusual size. The right gland measured three and one half by four, by one and one half centimeters; the left three by four, by two centimeters. Very hard. On incision the cortex appears riddled everywhere with isolated yellow cheesy foci of the size of a hemp seed. In spots the cortex is very much enlarged—to six millimeters. Liver very large, extremely hard. The surface is leathery, shining, with many yellow, irregular spots. The intestines also show yellow spots surrounded by a red halo. Stomach and pancreas normal. The genitals normal. On the arachnoidea a few

red spots, and the cortex of the brain was covered with minute points of a reddish, yellowish tint. Diagnosis: *Syphilis congenita, hepatitis gummosa, splenitis interstitialis, hæmorrhagiæ pulmonum et arachnoides, osteochondritis syphilitica gravis, gummata glandularum suprarenalium.* The microscope revealed two distinct pathological conditions, (1) formation of gummata with interstitial fibrous induration and, (2) foci of necrosis not of absolutely specific character. These latter foci which have their seat in the external part of the cortical substance may occupy its whole breadth. They primarily consist of miliary, circumscribed points of necrotic tissue which soon become surrounded by a wall of infiltration. They are not due to vascular changes but, as the author thinks, to an intoxication of tissue parenchyma by the syphilitic virus.

SYPHILIS OF THE SKIN AND MUCOUS MEMBRANES.

By Walter C. Klotz, M.D., New York.

Pigmentary Syphilide of the Neck, Origin of. (Sur L'Installation de la Syphilide Pigmentaire du Cou. Etude Clinique). Hulleu. (*Ann. de Derm. et de Syph.,* October, 1903—p. 731.)

The question of the mode of origin and development of the pigmentary syphilide has been the subject of considerable discussion for many years. In attempting to clear up the present confusion of opinions, the author has presented his own careful observations in twenty-three cases of pigmentary syphilide of the neck. In some of these cases he was able to observe the development of the lesion throughout its whole course, and from the very outset. In other cases he has had to depend, in part, upon the history as furnished by the patient. In some cases plaster casts were made of the skin of the neck at a time when a fully developed secondary eruption was actually present. On subsequently reapplying the casts, when the pigmentary syphilide had completely developed, he was able to satisfy himself that the white areas of skin corresponded exactly with the site of the former macular or papular lesions. The author concludes, from his observations, that a secondary eruption occurs on the neck more frequently than is generally supposed; that the pigmentary syphilide follows a previous macular or papular eruption accompanied by hypervascularization, which, on disappearing, leaves in its place white zones (cicatrices, atrophy or loss of pigment); that the pigmented net work ("lace collar") is simply due to the fact that it occurs in a part of the body where there is a natural tendency to pigmentation, and that the latter must be considered an expression of defense against the syphilitic virus.

While the author's opinions are at variance with those of some American dermatologists, he has evidently made some careful observations and if he has not succeeded in settling the vexed question, he has at least offered some very interesting and valuable suggestions to other investigators.

Syphilitic Dactylitis, A Case of. Alex. Renault. (*Bull. de La Soc. Franc. de Derm. et Syph.*, Vol. XIV, No. 7, p. 347.)

The case presented by the author is of interest on account of the extensiveness of the lesion and the fact that the affection developed so early in the course of the disease. It is rather noteworthy that the primary lesion was decidedly phagedenic in character. The first eruption developed after the usual interval and subsided promptly under internal treatment, which was kept up for three months. The affection of the fingers first developed about one year after infection as a redness and swelling at the tip of the right thumb. About one month later the index finger became affected. When presented before the society the thumb was distinctly enlarged and bright red in color, the pulp was almost entirely destroyed by an extensive fungoid ulcer. There were three deep ulcers at the lateral and dorsal aspects of the thumb along the line of the interphalangeal articulation. Flexion was impossible. The bone was considerably thickened as a result of periostitis. The index finger presented similar lesions. There was nothing in the occupation of the patient to account for the existence of the affection. The nails were not affected.

BOOK REVIEWS.

A Compend of Diseases of the Skin. Third Edition. Jay F. Schamberg, M.D. Philadelphia: P. Blakiston's Son & Co. 1903.

This little volume seems to have met with a fair measure of success, deservedly, for its terse considerations convey as good an idea of skin affections as it is possible to compass in so small a space. If the average student knows even that much, it is rather more than one would expect. We could bid a cheerful good-bye in a new edition to many of the old plates of histology which in their palmy days bore no resemblance to the lesion they are supposed to represent.—J. C. J.

The Roentgen Rays in Therapeutics and Diagnosis. By William Allen Pusey, A.M., M.D., and Eugene Wilson Caldwell, B.S. (Saunders & Co., Philadelphia and New York, 1903.)

Though the time is hardly ripe for the standard work to be written on the value and employment of Röntgen rays, nevertheless a book like the one before us has very definite and timely uses. The interest in the subject, widespread and deep as it is, has already given rise to an enormous literature and every report of new developments is scanned with eagerness by a multitude of earnest inquirers. That what is written now on a subject so imperfectly understood will probably soon be forgotten is to be expected. An ephemeral life is peculiarly the property of nearly all medical literature. Most medical papers and most medical books become soon obsolete, submerged or absorbed in the general stream of medical progress. Here and there some individual work by virtue of its greater weight and significance preserves its identity, grown of coördinate increments that have become unified, crystallized into a mass and thus is generated the standard authority. Sometime we shall have such a work on the medical relations of X-rays. Meantime to keep track of all the scattered contributions, fugitive increments of progress, is a bewildering task and almost impossible. How much easier it is to take our opinions from a single source! When the author has the credentials of wide personal experience, is familiar with the current literature and has a way of

putting things convincingly, or at least plausibly, we save much labor and perhaps avoid error by simply taking his view points with regard to his own experience as well as to that of others as our own. Considering the inchoate nature of its subject matter the volume before us may be pronounced a timely and a useful one.

What is more especially the technical part of the work is by E. W. Caldwell and comprises the first third or so of the book. It contains a succinct account of the discovery of the Röntgen rays as well as of what later investigations have revealed of their behavior and properties. The questions relating to apparatus together with the subjects of radiography and diagnosis are thoroughly expounded and throughout this part of the work the different topics are presented with a simplicity and clearness of style that is to be highly commended.

The major part of the book is taken up by Dr. Pusey in presenting the therapeutic side of the subject—radiotherapy—and it is this part naturally that especially interests us here. In his preface the scope of the work is modestly stated as consisting of a review of his own experience and comparisons with that of others. It is practically a report of progress and largely consists of records of cases together with appended comments or conclusions. He says all that he claims is that it has been his "constant endeavor to keep well within the facts." This claim apparently he has well maintained and one of the most notable features of his work throughout is its conservatism.

Beginning with "the effects of X-rays on the tissues" he discusses not only the familiar superficial effects such as pigmentation, burns, loss of hair, hyperkeratosis, etc., but also the deeper effects. With regard to the latter he says "there is every reason to believe that X-rays may affect deep-seated tissues, but this effect must be less than upon the tissues nearer the source of the rays." "Must be" seems a trifle overstated when we consider the relief of pain in deep-seated parts, the fall of the hair, the effect on enlarged glands or other parts below the surface that may occur with no appreciable or the very slightest change in the superficies of the skin.

The writer is disposed to be hopeful with regard to the effect of Röntgen radiation in tuberculosis of the lungs and other interior organs and sees no ground for apprehension that under its influence the disease may assume more virulent character.

A difference in susceptibility to the rays in different individuals is admitted but in the writer's experience has never amounted to a "marked idiosyncrasy," though the very precise statement is made that the variation in different individuals sometimes amounts to "four times the susceptibility in one case over that in another." He does not agree with those who find one part of the surface more susceptible than another except in the case of the ocular conjunctivæ which, he says, are peculiarly sensitive to the X-rays. Nor has he found any noticeable difference in different individuals depending on complexion, whether fair or dark.

Concerning the germicide action of X-rays the writer, while admitting the consensus of testimony tending to show that the rays *per se* have little or no effect on bacteria outside the body, considers it quite a different case when these germs occur in living tissue. In the latter case the organisms are often destroyed though not by the direct action of the rays, but rather through reaction first effected in the tissues in which they grow, possibly through increased phagocytosis.

In discussing what the X-rays are, Pusey easily arrives at the conclusion that they "are transverse vibrations of the ether of essentially identical character with light rays." Most physicists are not so sure of this. Beside the active effects one of the chief arguments to the writer's mind for believing these rays to be essentially identical in character with ordinary light is based upon the fact that the former do under certain conditions produce a sensation of light on the retina. By parity of reasoning electricity and other physical activities that may give rise to similar light sensations might be called forms of light. The subject is yet too

intricate to admit of definitive conclusions and for the present the non-committal name derived from the algebraic sign of an unknown quantity remains the best designation for the peculiar phenomena which we call X-rays.

The technique employed in the productions of the rays is considered chiefly from German standpoints. The methods most closely followed by Pusey are those of Schiff and Freund, though mention is not made of all the points given in Freund's recently published work (*Grundriss der gesammpten Radiotherapie.*) In describing his "standard light" he gives mechanical details of the way the machine is operated rather than any very definite means of determining the quality or quantity of the "light" actually produced. With his own large experience he may not be dependent upon such methods of estimating the intensity of the radiations as it would be desirable to impart to the beginner. Certain instruments of precision that have been proposed in this connection and are now receiving more or less attention are not referred to at all. He prefers the induction coil to the static machine because he finds that with the former the amount of energy can be better gauged and more accurately regulated.

With regard to exposures he states in a general way that his plan is to use a small quantity of "light" at frequent intervals rather than strong exposures at longer intervals. He begins with the tube at fifteen centimeters and gradually reduces the distances at each seance until by the end of the second week, if no reaction occur, the tube is placed at a distance of eight centimeters. He then begins increasing the time of exposure. What the initial duration was is not stated. He speaks of a maximum exposure of fifteen minutes at five centimeters. Elsewhere he intimates that an average daily exposure is one of from ten to fifteen minutes' duration at five centimeters' distance. Certainly he must use a very weak light.

The therapeutic results are presented chiefly in reports of numerous cases together with an abundance of photographic portraits—both before and after. The record on the whole is a good one. Apparently there has been no shirking of reports of bad cases and the successful ones suffice to reflect credit both on the agent employed and on the writer's method of employing it. Though in our review we may have touched more on the weak points than on the strong with no reserve we highly commend the book to all who are interested in X-ray work or in the progress of radiotherapy. E. B. B.

Diseases of the Skin. An Outline of the Principles and Practice of Dermatology. By Malcolm Morris. New edition. (W. T. Keener & Co., Chicago. 1903.) pp. 642.

"Good wine needs no bush" and a good book in what we would call its fifth edition needs no praise from us. But it is a pleasure for us to add our voice to that chorus of praise that has welcomed the present edition of this most excellent book. When it first appeared with its modest 288 pages it was recognized as a lusty child and a credit to its parent. In ten years it has more than doubled in size and has maintained its vigor. We indulge the hope that before long it will grow to full manhood, and we will have another first-class text-book on dermatology from our cousins across the sea.

The present edition contains sections on seven diseases not in the previous editions; has some thirty or more illustrations, and the subject matter has been brought down to the time of going to press. The colored plates that were in the front of the last edition have been omitted, which is to be regretted.

It is the most readable book on its special subject that it has ever been our good fortune to read. The style is vigorous, and the author states his views clearly and forcefully but with deference to other authorities. He has essayed the impossible in endeavoring to group the dermatoses in etiological classes. This results in some surprises, as when we find lupus erythematosus among the neurotic

affections of the skin and acne under local inoculable affections. But then our author regards lupus erythematosus as a form of erythema; and if we accept the most recent theory of acne, that it is due to micro-organisms, there is no reason why our author's classification should not be accepted. But then, why not place under the same heading tuberculosis and many other diseases?

Judging from the illustrations England is far behind us in the making of half-tones. Those in this book are on special paper as inserts and are deficient in clearness. A specially commendable feature of the book is the admirable index which is at the same time an index to the text, and to the treatment.

The dermatologist will find the book well worth reading, and will profit by it even more than the student and the general practitioner. We heartily commend the book to our readers. G. T. J.

Uric Acid as a Factor in the Causation of Disease. By Alexander Haig, M.A., M.D., Oxon., F.R.C.P., Physician to the Metropolitan Hospital and the Royal Hospital for Children and Women. Late Casualty Physician to St. Bartholomew's Hospital. Sixth Edition, with 75 Illustrations. Philadelphia: P. Blakiston's Son & Co. 1903.

The first edition of this work of Dr. Haig appeared in 1892. No higher tribute to the value of the work and the estimation in which it is held by the medical profession could be adduced than the fact that within a little more than a decade a sixth edition has been called for.

The work of Dr. Haig is too well known to the medical profession to justify a detailed analysis of its contents. After some preliminary considerations upon the "Formation and Excretion of Uric Acid," "Uric Acid and Metabolism," the "Relations of Uric Acid with the Circulation," the relations of uric acid with the pathology of various disorders are considered at length.

From the large number of diseases and morbid conditions which, though usually credited with a diverse etiology, are referred by Dr. Haig to a common etiological element, viz., uric acid toxæmia, it is evident that in the opinion of the author a large portion of the field of medicine is covered by this pathogenetic factor. However this may be, there is no question but that uric acid plays a prominent rôle in the causation of many diseases of the cutaneous system.

From this point of view the work of Dr. Haig has a special interest to the dermatologist. From time immemorial the view has been held that many forms of eruptive disease are the local expression of some general diathetic disorder. This view found expression in the *psora* of the older school of dermatology and later in the "dartrous diathesis" of Hardy, the "arthritic diathesis" of Bazin and the "herpetic diathesis" of other exponents of the French school. While the authority of the German school which taught the exclusively local origin and nature of the dermatoses for a while dominated medical opinion upon the continent, the opinion has always prevailed, especially among English and American dermatologists, that a large number of cutaneous affections are in their essential nature symptomatic of some internal or constitutional disorder.

The contention of Dr. Haig that a large class of eruptive disorders, more especially these grouped among the inflammatory affections of the skin—certain forms of erythema, urticaria, eczema and psoriasis, etc., are often associated with an excess of uric acid or urates circulating in the blood—will meet with general acceptance.

The therapeutic indications of withholding albuminoid foods which contain an excess of nitrogenous elements, the administration of solvents for the urates and the free use of diuretics and purgatives for the removal of the excrementitious principles cannot be too highly commended.

The dermatologist as well as the general practitioner will find in this volume much of interest and practical value. P. A. M.

PLATE XVIII.—To Illustrate Dr. John A. Fordyce's Article on Symmetrical Atrophy of the Skin.

THE JOURNAL OF CUTANEOUS DISEASES
INCLUDING SYPHILIS

VOL. XXII. APRIL, 1904. No. 4

SYMMETRICAL CUTANEOUS ATROPHY WITH THE COINCIDENT DEVELOPMENT OF SYPHILIS OF THE SKIN AND NERVOUS SYSTEM.

By J. A. FORDYCE, M.D., New York.

THE patient, whose history is about to be narrated, has been under the occasional observation of the writer since 1896.

A brief report of the case with the histological findings of some recent lesions, was read before the American Dermatological Association in 1897.

In 1901 a further report of the same case was made to the Association, giving the details of some interesting phenomena in connection with the nervous system and the skin which tended to make somewhat clearer the obscure nature and etiology of the affection.

The patient has also been presented before the New York Dermatological Society on several occasions where an opportunity was given the members to observe the early erythematous and atrophic lesions as well as those which developed at a later period. The several cases which have been reported in dermatological literature since the writer's attention was first attracted to the subject have shown that the affection is not so uncommon as at first supposed.

The views which were expressed by Buchwald and others as to the idiopathic nature of the atrophy have been modified to conform to a more comprehensive clinical group of symptoms.

We now know that the atrophy is the terminal stage of a condition which is primarily inflammatory and that the conception of some of the earlier cases was obtained from an observation of those of long standing where the initial erythemato-inflammatory condition had ceased to exist.

The type of cutaneous atrophy in question is, however, sufficiently well defined to readily enable us to separate it from the large group of secondary atrophies which follow the involution of the lesions of the infective granulomata, scleroderma, certain types of striate and macular atrophy, as well as the congenital and senile forms of the affection.

The mere addition of another case of this interesting skin condition to those already recorded would be of little interest were it not for the symptoms pointing to a profound implication of the nervous system and the later lesions of the skin which afforded a possible clue to its obscure etiology.

History. The patient, a woman, aged forty, born in Sweden, was first seen in December, 1896, when the following notes were taken: She had lived in America ten years; had been married four years; but had no children and has had no miscarriages. Her parents were dead. She had two brothers living in good health. She knew of no case of consumption in her family. She was nervous, easily fatigued and subject to frequent attacks of mental depression. The hands showed pronounced tremor at times. Her menstruation lasted eight or nine days and was very profuse.

The skin affection from which she then suffered, began about two and a half years before, on the dorsum of the left hand, soon implicating the left foot and ankle. The right lower extremity was soon involved in much the same manner as the left; irregularly rounded, red and scaly patches from the fraction of an inch to several inches in diameter appearing on the legs and extensor surfaces of the knees. On the upper extremities the extensor surface of the left elbow including a portion of the forearm and upper arm were next involved, followed by an implication of the corresponding parts on the right side, and finally by an involvement, to a slight extent, of the right hand and flexor surface of the wrist.

Aside from the regions mentioned, several small spots had been noticed on the upper lip, on the left auricle and beneath the left breast. These minor patches last mentioned had all disappeared spontaneously without leaving a trace of their presence.

The patient stated that the first abnormal change in the skin began on the outer side of the left hand near the wrist. She noticed a slightly scaling circular spot in this locality, which gradually increased in size until the entire dorsal surface of the hand, and the skin covering the first phalanges were involved. The atrophic process now completely encircled the wrist and extended in a narrow band the entire dis-

tance from the wrist to the elbow, where it was met by the advancing margin of a similar patch in that region.

The hand was at first swollen, crimson red to purplish-red in color and tender to deep pressure or manipulation. Slight scaling had been present at times, but had never been a prominent feature of the affection on the upper extremities. No ulceration or discharge of any kind had been present in connection with the atrophic patches on the hands or arms. The left hand was colder than the right.

The dorsum of the left foot and ankle were next involved, a small scaling patch being first noted which soon extended over the entire dorsal surface to within half an inch of the phalanges.

Bullæ formed over the affected surface which ruptured and discharged a serous fluid. The foot at times became swollen and painful so that locomotion was difficult, and she was unable to bear the pressure of a shoe.

The pain and swelling would remain for a few days, then disappear for two or three weeks, when a singular attack would follow. The extensor surface of the left knee became in time the seat of a red scaling patch followed by a like condition over the upper third of the dorsum of the right foot and around the ankle. After six months the right knee was involved in the same way. Both ankles were completely encircled by the red, scaling atrophied skin and numerous irregular rounded patches from half an inch to two or more inches in diameter were present over the lower half of the left leg and lower third of the right. These patches had also been the seat of bullous formation; they appeared slightly infiltrated, at times warmer to the touch than the surrounding skin and were more sharply defined than the affection on the hands and feet.

The pains in the feet and legs have been of a deep seated burning character, and were more pronounced along the anterior surfaces of the tibiæ.

The epidermis about the feet and ankles was cast off in large sheets, leaving a reddened, shiny and atrophic surface, through which the veins were distinctly visible.

In addition to the red and scaly patches on the legs there were white atrophic spots surrounded by zones of pigmentation, which evidently were the result of lesions which had undergone complete involution.

The skin covering both legs, aside from the active lesions and white atrophic spots, appeared thinner than normal, the meshwork of veins being distinctly seen through the shiny atrophic skin.

The extensor surfaces of both knees presented an appearance very similar to that of the elbows; patches from six to eight inches in length by from one to two in width being present which were surrounded by pigmented skin and a zone of dilated capillaries (Plate XIX). The capillary dilation which seemed to be the first pathological change, extended half way up the thighs, and on careful examination, numerous brownish-red, pin-head-sized and somewhat larger spots were visible, which did not disappear on pressure.

The capillary congestion was of a purplish-red color and was soon followed by a slight desquamation, and finally by a thinning of the underlying skin.

Over the hand, the elbows, the ankles and knees, where the atrophy was pronounced, the skin was dry, wrinkled and parchment-like, being thrown into numerous transverse and longitudinal folds, which recalled in a striking manner the description by Bronson. With the exception of the spots on the legs above the ankles, the atrophied areas showed no well defined margins, but passed imperceptibly into the surrounding capillary dilatation. The irregularly rounded patches between the knee and ankle showed the presence of a slight infiltration and more clearly outlined margins resembling the appearance met with in certain cases of lupus erythematosus. Had they been met with alone, the case would undoubtedly have been called by that name.

When the patient was first seen last September, the left hand was swollen, and the color of a more scarlet hue. Some tenderness or soreness was felt on deep pressure. At the present time, (April 20th), the swelling had entirely disappeared, the color of the skin had assumed a brownish-red hue and the atrophy was more pronounced. (Plate XX.)

In several places over the dorsum, the deep color was disappearing, leaving white atrophic areas which looked like scar tissue of some age. On close examination the small brownish-red spots previously mentioned were seen beneath the epidermis over the entire atrophic surface and in the advancing margin of the dilated capillaries. The glossy appearance of the affected skin was more marked here than in other localities. When picked up between the fingers much of the normal elasticity of the skin was seen to be absent.

The periodical attacks of pain and swelling of the feet and legs no longer occurred. She was in better general health and had lost much of the nervousness which was so pronounced when she was first seen.

No fresh spots had appeared during the past two months; and

the progress of the old ones seemed to be for the time arrested. Although the atrophy had involved a larger surface on the left side than on the right, the almost absolute symmetry of the eruption was a pronounced feature.

Neither the palms of the hands nor the soles of the feet had been affected and at present no spots could be seen about the face or scalp.

Thinking that some change in the central or peripheral nervous system might be found which would throw some light on the origin of the skin lesions, the patient was sent to Doctor Joseph Collins for examination. Doctor Collins reported that he carefully looked over the patient but was unable to find anything that pointed to a spinal cord or peripheral nerve lesion.

He found no defect of any sort of sensibility mediated through the skin; the tactile, pain, thermal and kinæsthetic sensibility were found to be entirely normal. There was no disorder of the special senses.

The knee jerks were normal, perhaps slightly exaggerated on the left side. There was found to be no reaction of degeneration in the muscles or nerves with the electrical current. Faradic irritability quick and normal, ankles, forearms and legs.

Dr. Collins was inclined to regard the trouble as a trophoneurosis, not only from its clinical manifestations, but because of the detectible difference in the volume of the pulse on both sides (pulse was much weaker in the left radial artery), and the fact that the surface temperature on the two sides was found to be different. (100 degrees F. in the left axilla and 99.5 degrees in the right.) The depression of spirits, attacks of crying, occurring daily and without cause, the hopelessness, easily induced fatigue, uneasy sleep and attacks of vertigo, indicating disturbance of vaso-equilibrium in the brain and brain stem were regarded as additional reasons for upholding this view. An examination of the blood failed to reveal the presence of eosinophile cells or other pathological change. The urine contained neither albumin nor sugar.

The patient again came under observation in January, 1898, and stated that for over three months she had suffered from severe nocturnal pain in the left side of the head extending to shoulder and arm, and finally to the entire left side. This was followed by tinnitus and deafness and, within three weeks, by general anæsthesia and hemiplegia of the left side. A pin could be stuck into any part of left side without pain. At this time it was noticed that she was unable to close her left eye and that there was double vision. She experienced difficulty in swallowing and vomited frequently.

After confinement to bed for several weeks sensation gradually returned in the hand and later in the leg. The ability to move her arm and leg was also slowly regained, so that she could walk with the aid of a cane. She was at this time under the care of a physician and was actively treated by him with mercury and iodides. An examination made after a partial recovery from the foregoing condition showed marked impairment of hearing in the left ear.

She stated that at times she had double vision and vertigo, but that she was daily improving in these respects. The pupils responded to both light and accommodation. At the time of the hemiplegia, in addition to the ptosis on the left side, the eyeball turned slightly inward and its movements were limited. At the time she was seen the mobility of the lids and eyeball was apparently normal. Sensation, she stated, first returned in the hand and arm and finally in the leg.

Dr. Collins saw the patient again at this time and kindly sent me the following report: "Pulse much weaker in left radial artery. No ocular anomalies. Both knee-jerks absent. Some swaying on standing. No limitation of visual fields in either eye. No disturbance of sensation in extremities. No loss of dexterity."

"The left hand does not seem to be more advanced in the atrophy of the skin than when I saw her before, except the more acute trophic changes are going above wrist now. Her head is so sore that she can scarcely comb her hair, especially left side, top also somewhat tender. She cannot tell heat from cold on the left side of her face, but as soon as one gets behind ear or below angle of lower jaw she tells readily. She cannot tell pin-point over same area, *i.e.*, tactile anæsthesia. Knee-jerks elicitable very slightly to-day on reinforcement."

"Jan. 18, 1899.—Knee-jerks weak. Pulse very unlike on the two sides. Tongue and lips seat of peculiar slow, vermicular tremor. When the hemiplegia came on it was noticed that the left eye could not be closed, that the left upper lid drooped and that the eyeball turned slightly inward. It could be moved voluntarily inward, but very slightly outward, not at all backward, and downward very little. At the time of the examination the left pupil was larger than the right, but the state of the accommodation was not tested. There was constant diplopia, the images standing obliquely. All of these symptoms have gradually diminished, the diplopia ceasing three weeks ago. At the time of the examination the mobility of the eyeballs was apparently normal. There was a slight exophoria equal in all directions of the gaze. With a red glass before the eyes a candle flame appeared broadened and red on the right side, indicating a slight

tendency to cross-diplopia. Vision is 20/20 in each eye + 1. D. Accommodation, pupillary reaction, fields of vision and ocular perception were normal. There was some diminution of sensibility in the left half of the face and in the left cornea and conjunctivæ. The pupils were small and of equal size; the interior of the eye and fundus normal. In other words, there was a paralysis of the auditory, facial, abducens, trigeminus, trochlear and all of the divisions of the motor oculi to a variable degree. The auditory nerve has not regained its function, the trigeminus has regained it in part and the other nerves have apparently got well."

"Both drum membranes unscarred. No sign of present or previous middle ear trouble. In the right ear the hearing was normal to the voice, watch, high and low pitch tuning forks. In the left ear the hearing was entirely destroyed. When the tuning fork was placed upon the left mastoid it was heard in the right ear. The tinnitus had gradually diminished in intensity, while the dizziness had diminished both in intensity and frequency. The dizziness was not brought on by particular postures of the head and was experienced only when standing and then particularly when the room was brilliantly illuminated or when she went into the street. When this vertigo first set in it was less severe when the eyes were closed, and it has been very much less intense since the diplopia ceased. The vertigo was apparently of both aural and ocular origin, the latter, however, predominating."

Dr. Collins expressed the opinion at this time that a syphilitic vascular brain lesion was responsible for the symptoms she presented.

A number of recent circular patches of redness with scaling and some crusting at the periphery appeared over the elbows, arms and about the knees.

After the subsidence of the hyperæmia, atrophic areas were left, surrounded by zones of pigmentation.

An irregularly rounded patch of this character is shown in the colored plate, which simulated in a striking manner a lupus erythematosus and seemed to form a transitional stage between the atrophic area on the dorsum of the hand and the more circumscribed lesions about to be described. (Plate XVIII.) At the same time she developed pustular and ulcerative lesions about the atrophic spots on the lower extremities, which were at first thought to be due to the iodide of potassium she had been taking. They persisted, however, long after the iodide was discontinued, and appeared in other locali-

ties. These lesions healed after a time, leaving superficial pigmented scars.

She was observed again some months later with a typical serpiginous and ulcerative syphilide on the inner aspect of the right forearm, which involved an area between two and three inches in diameter. (Plate XXI.) Under the persistent use of mercury and the iodides for more than a year this condition slowly yielded.

In March, 1901, the following notes were recorded: She had been taking anti-luetic remedies for more than a year and had greatly improved in health. Her hands were still purplish-red and easily became cold. Menstruation, which formerly persisted fourteen days, was now more nearly normal in duration and quantity. Eyesight and hearing were good. She had no numbness or loss of muscular power. The papillary reflexes were normal, though the knee-jerks were absent.

She was again seen in December, 1903, when her general condition was even better than two years before. She was well nourished, had a good appetite and had gained ten pounds or more in weight. She slept well, had no pain, swelling or tremor of the extremities. The hands still retained their purplish-red color and showed the wrinkled atrophic condition. Her vision was good and no ocular paralyses were apparent. She was somewhat deaf in the left ear, hearing the watch tick only on contact. The knee-jerks were present. The atrophy had not progressed beyond the regions first invaded.

Histology of a Recent Lesion. A piece of skin from the margin of a recent patch on the leg was excised for microscopic examination, sectioned and stained in a variety of ways. The spot from which the piece was excised was dusky-red and somewhat infiltrated at the margins, while the center showed an atrophic depression.

A glance at the sections showed that the affection was not one of primary atrophy, as the process was distinctly an inflammatory one, the epidermis and papillary region being densely infiltrated with exudation cells. (Plate XXII. Figs. 1 and 2).

These cells in sections stained with Grübler's hæmalum, consisted chiefly of mononuclear leucocytes. They were grouped about the vessels throughout the entire thickness of the skin, densely packed around the coil glands, and scattered singly and in groups throughout the tissue into the subcutaneous fat.

Many small vessels showed a thickening of their external and middle coats, and several obliteration of their caliber. (Plate XXIII,

Figs. 3 and 4. Thrombi were seen in some of the deeper vessels (Plate XXIII, Fig. 4).

In some of the larger arterioles the adventitia and media were thickened, while their component cells showed a fine granular condition of the protoplasm and stained imperfectly.

Sections stained with Unna's polychrome and decolorized with neutral orcein and glycerine-ether revealed the presence of numerous plasma and mast cells in addition to the small lymphocytes.

The epidermis presented striking changes: (Plate XXII., Figs. 1 and 2). The stratum corneum was thickened in places, most of the cells preserving their nuclei to the surface. The transitional layers were absent or very imperfectly developed. The parakeratotic layer became readily detached in large sheets, leaving the prickle cell layer between the rete pegs extremely thin; it was in places only two or three cells in thickness. The interpapillary pegs were lengthened, broadened and infiltrated with small cells. Many of the epithelial cells were œdematous and showed degenerative changes. The basal layer in places was scarcely distinguishable from the bordering cell infiltration (Plate XXII, Fig. 2).

No hair follicles or sebaceous glands were seen in the tissue examined.

The coil glands and ducts were surrounded by numerous large and small plasma cells, their epithelial lining was, however, normal.

The cell infiltration, which was dense and diffused in the papillary and subpapillary areas of the corium, was more circumscribed in the deeper region, being grouped around the small vessels and extending in foci to the subcutaneous fat. In the latter localities the vascular and perivascular changes were more pronounced or better defined because of the circumscribed nature of the infiltration.

The thickening of the vessels walls (adventitia and media) was a constant feature in all the sections examined, leading to partial or complete obliteration of their caliber. The vascular change pointed to a primary involvement of these structures in the inflammatory process and strongly suggested the vessel changes met with in syphilis.

Histology of a More Advanced Lesion. A small piece of skin was excised from a lesion of the arm in which the atrophy was more pronounced, but which showed some evidences of infiltration at the margins. The epidermis here was markedly atrophic, consisting only of three or four layers of prickle cells with entire absence of interpapillary pegs. The stratum corneum and transitional layers were faintly marked in places and again entirely absent.

The cell infiltration was less dense than in the recent lesion, but was made up of the same character of cells distributed in much the same manner.

The collagenous bundles in the upper corium were faintly marked and had undergone some degenerative changes.

The elastic fibers were, however, partially preserved.

In sections stained by the Unna-Tänzer method the fine fibrils beneath the epidermis were sharply defined, but below that area they were less numerous than in the normal skin.

The atrophic process, as shown by the histological examination, was plainly the result of an infiltration and not of an idiopathic nature; the greatest intensity of the inflammatory process in the upper corium causing secondary changes in the epidermis. The alterations in the vessels' walls and the perivascular infiltration pointed strongly to these structures as the primary seat of the trouble.

This view was strengthened by the clinical picture of the affection, as the majority of the cases observed in their early stages showed primary vascular dilatation before the secondary atrophy was manifest. The formation of bullæ, which took place over the lower extremities was readily explicable by reason of the sharp inflammation in the papillary region, together with the diminished resisting power of the diseased and atrophic epidermis.

We can account in the same manner for the ulcerations on the legs, which were noted by Bronson, Buchwald and others.

Aside from the syphilitic lesions of the skin and the phenomena on the part of the nervous system, which the patient developed several years after the onset of her trouble, the case in its objective features as well as in its development and clinical course is almost a counterpart of the type first described by Buchwald as idiopathic atrophy of the skin.

The primary implication of the extremities, the sites of predilection over the dorsal surfaces of the hands and feet, the flexor surfaces of the elbows and knees, and the blue-red color of the skin, were noted in the case under observation as in those previously described.

The swelling, pain and paræsthesias which were present in the case were notably absent in the majority of the others on record.

These symptoms might have been unobserved in some instances because of the late period in which the affection was first observed, but were evidently not constant accompaniments of the condition. The slowly progressive nature of the condition with its resulting parch-

ment-like atrophy of the skin, could in no wise be distinguished from the typical examples of the condition.

In addition to the hands, feet, knees, and elbows as sites of the atrophy there were several sharply circumscribed areas of redness and infiltration on the legs and forearms which clinically somewhat resembled lupus erythematosus (colored plate), and which resulted in the same terminal atrophy as of the skin on the hands and feet. The clinical picture was further complicated by the occurrence of ulcerative and encrusted lesions of the legs and arms, and by the development of a typical serpiginous syphilitic infiltration in the skin of the forearm.

From an early period of the affection there was profound involvement of the nervous system which later culminated in hemianæsthesia, a partial hemiplegia and various oculo-motor paralyses. Under antiluetic medication these nervous manifestations, along with the definite specific infiltration in the skin, disappeared.

It may, therefore, be considered as definitely established that syphilis was present as a complicating if not as an essential factor in the case.

There were certain reasons, however, for assuming that syphilis might have been responsible for the entire clinical group of symptoms, although that infection had never been invoked in the etiology of this type of atrophy.

The early implication of the nervous system, at the time of or soon after the extremities showed the first signs of hyperæmia and atrophy; the occurrence of the atrophy in patches, rather than in the diffuse form usually met with, and the circumscribed transitional areas of swelling and redness, suggested at least that a single cause might have been operative. This view was strengthened by the result of the histological examination which revealed vascular change in the early atrophic lesions fairly typical of syphilis.

A definite diagnosis could not well be made on the strength of the changes in the vessels alone, but in connection with the subsequent developments in the case they were, to say the least, very suggestive.

It is, of course, not impossible to conceive that the patient was afflicted with the so-called idiopathic atrophy and syphilis at the same time. If such had been the case the syphilis probably antedated the atrophic change, for when unmistakable specific lesions of the skin appeared they were of the late variety and pointed to an infection of several years' duration. The strongest reason for rejecting syphilis as an etiological factor in the writer's patient is the fact that in the

cases hitherto reported (with one exception) its possibility as a causative agent has not been suggested. It would not be altogether wise, however, to assume that our knowledge of syphilis is complete or that its capabilities are fully known.

Within comparatively recent years it has been proved that certain gangrenous ulcers and even Raynaud's disease have resulted from specific vascular changes. It seems not irrational to assume that the atrophy of the skin, though not conforming to any known cutaneous lesion of syphilis, might have been induced by the partial obliteration of the lumen of the vessels which the histological examination revealed. Such an hypothesis, based on definite tissue alterations at the site of the atrophy, agrees more accurately with our knowledge of the action of the specific virus than the assumption of an obscure trophoneurotic disturbance of a central or peripheral origin.

Ravogli in the past year has reported a case of "Progressive Idiopathic Atrophy of the Skin," affecting a girl of eighteen years, who died in coma succeeding delirium. The autopsy revealed multiple gummata of the brain and cicatrices of the liver due to old syphilitic deposits. The author endeavored to connect the changes in the skin, through trophoneurotic disturbance, with pressure on the vasomotor center in the medulla.

The clinical features of Ravogli's case were, however, totally at variance in their location and evolution with those recognized in this type of atrophy. The impression is conveyed from the description in Ravogli's article that the atrophy was secondary to the involution of multiple cutaneous foci of syphilis.

The most comprehensive and important contributions to the affection under consideration have been made by Unna and Herxheimer and Hartmann. The former writer formulates a classification of all the known forms of atrophy of the skin and includes the type in question in his group of primary atrophies.

His histological examination was made from a case of long duration, and is mainly interesting in showing the secondary changes in the skin.

Microscopic studies of diffuse and circumscribed atrophy of the skin have been made by Buchwald, Pospelow, Columbini, Bechert, Huber, Neumann, Krzysztalowicz, Jadassohn, Nikolski, Heuss, and others, of tissue removed in various stages of the trouble, a *résumé* of which may be found in the article recently published by Herxheimer and Hartmann, entitled "Acrodermatitis chronica atrophicans."

The name proposed by the latter writers to supplant the old desig-

nation of idiopathic atrophy is based on the clinical fact that the extremities (hands and feet) are primarily implicated and that the atrophy is secondary to an inflammation, and merely represents the terminal stages of the process. Twelve cases are reported by Herxheimer and Hartmann, in three of which microscopic studies were made in both the stage of redness and that of exudation and atrophy.

They emphasize the presence of an antecedent infiltration in the skin and believe it is always present if the case be seen in its early stages.

Pick and Klingmüller's cases of "erythromelie," where the redness was accentuated and the atrophy less pronounced, are connected by the authors with the condition in question, as are also Kaposi's "Dermatitis atrophicans" and Neumann's "Erythema paralyticum."

Little information is afforded us in the clinical histories or pathological anatomy of the cases reported as to its etiology or pathogenesis. The weight of evidence favors a primary vessel involvement leading to an exudation and followed by a destruction of certain elements in the corium and epidermis. The atrophy which results leaves the blood vessels without support and they in turn dilate, thus giving rise to the red or blue-red color of the skin.

The attempt made by Neumann and others to associate the atrophy with a tropho-neurotic disturbance has little support in the clinical behavior of the disease. A central tropho-neurosis would scarcely be limited in its effects to the skin; other structures such as the muscles would be involved in the atrophic change.

It has been conclusively proved by Herxheimer and Hartmann that the atrophy is limited to the parts which were the seat of the primary vessel involvement and the infiltration.

Erythromelalgia presents certain features in common with the case of atrophy of the skin under consideration, notably in the redness, swelling and pain in the extremities. While typical cases of the two affections are easily distinguishable there have been reported transitional types which have more analogous features.

Schütz (quoted by Herxheimer and Hartmann) has described a case which was characterized by swelling and discolorization of the arms and cheeks, terminating in atrophy, and attended with burning pain and such general symptoms as headache, dizziness, ringing in the ears and partial deafness.

In view of the occurrence of transitional cases between erythromelalgia and acrodermatitis chronica atrophicans, it is noteworthy that the former affection is chiefly of vascular origin (Mitchell and Spiller,

Sachs and others), the larger vessels of the extremity involved being the seat of obliterative endarteritis. In the atrophic areas of the affection under discussion the smaller vessels were similarly affected. It seems proper in this connection also to refer to Osler's case of Raynaud's disease in which repeated attacks of monoplegia, hemiplegia and aphasia alternated or occurred with local syncope or asphyxia of the fingers and toes, and also to the cerebral complications of the erythema group of skin diseases, of which he has reported several instances. The toxæmias which bring about the skin lesions are equally potent to produce changes in the central nervous system or the viscera.

It is fair to assume in the writer's case that the ocular and other paralyses were due to changes in the cerebral vessels analogous to those found in the skin lesions.

REFERENCES.

Buchwald—Ein Fall von diffuser idiopathischer Haut-atrophie, *Virteljahr. f. Derm. u. Syph.*, 1883, Bd. XV., p. 543.

Bronson—A Case of Symmetrical Cutaneous Atrophy of the Extremities, *Jour. of Cutan. and Gen.-Urin. Dis.*, 1895, Vol. XIII, p. 1.

Ravogli—Progressive Idiopathic Atrophy of the Skin, *Jour. A. M. A.*, 1903, Vol. XL., p. 73.

Unna—Ein Fall von idiopathischer diffuser progressiver Haut-atrophie, *Festschrift für Neumann*, 1900, p. 910.

Herxheimer und Hartmann—Acrodermatitis chronica atrophicans, *Archiv. f. Derm. u. Syph.*, 1902, Bd. LXI., pp. 57 and 255.

Pospelow—Cas d'une Atrophie Idiopathique de la Peau, *Ann. de Derm. et Syph.*, 1886, p. 505.

Columbini—Klinische und histologische Untersuchungen über einer Fall von Atrophie idiopathica, *Monatsh. f. prakt. Derm.*, 1889, Bd. XXVII., p. 65.

Bechert—Ueber einen Fall von diffuser idiopathischer Haut-atrophie, *Arch. f. Derm. u. Syph.*, 1900, Bd. LIII., p. 35.

Huber—Ueber Atrophia idiopathica diffusa progressiva cutis im Gegensatze zur Senilen Atrophie der Haut, *Arch. f. Derm. u. Syph.*, 1900, Bd. LII., p. 71.

Neumann—Ueber eine Seltene Form von Atrophie der Haut, *Arch. f. Derm. u. Syph.*, 1898, Bd. XLIII., p. 3.

Krzysztalowicz—Ein Beitrag zur Histologie der idiopathischer diffuser Haut-atrophie, *Monatsh. f. prakt. Derm.*, 1902, Bd. XXXIII.

Jadassohn—Ueber eine eigenartige Form von Atrophia maculosa cutis, *Arch. f. Derm. u. Syph.*, 1892, Bd. XXIV., Ergh.

Nikolski—*Derm. Zeitsch.*, 1897, p. 346.

Heuss—Beitrag zur Kentniss der Atrophia maculosa cutis. *Monatsh. f. prakt. Derm.*, 1901, Bd. XXXII., p. 53.

Pick—Ueber Erythromelie, *Festschrift. f. Kaposi*, 1900.

Klingmueller—Ueber Erythromelie (Pick), *Festschrift f. Kaposi*, 1900.

Mitchell and Spiller—A Case of Erythromelalgia with microscopical examination of tissue from an amputated toe. *The American Jour. of the Med. Sciences*, 1899. Vol. CXVII., p. 1.

Sachs—On Erythromelalgia, *Mount Sinai Hospital* Reports for 1898.

Osler—On the visceral manifestations of the erythema group of skin diseases. *The Am. Jour. of the Med. Sciences*, 1904, Vol. CXXVII., p. 1.

PLATE XIX.—To Illustrate Dr. John A. Fordyce's Article on Symmetrical Atrophy of the Skin.

PLATE XX.—To Illustrate Dr. Jno. A. Fordyce's Article on Symmetrical Atrophy of the Skin.

PLATE XXI.—To Illustrate Dr. John A. Fordyce's Article on Symmetrical Atrophy of the Skin.

PLATE XXII.—To Illustrate Dr. John A. Fordyce's Article on Symmetrical Atrophy of the Skin.

Fig. 1.

Fig. 2.

PLATE XXIII.—To Illustrate Dr. John A. Fordyce's Article on Symmetrical Atrophy of the Skin.

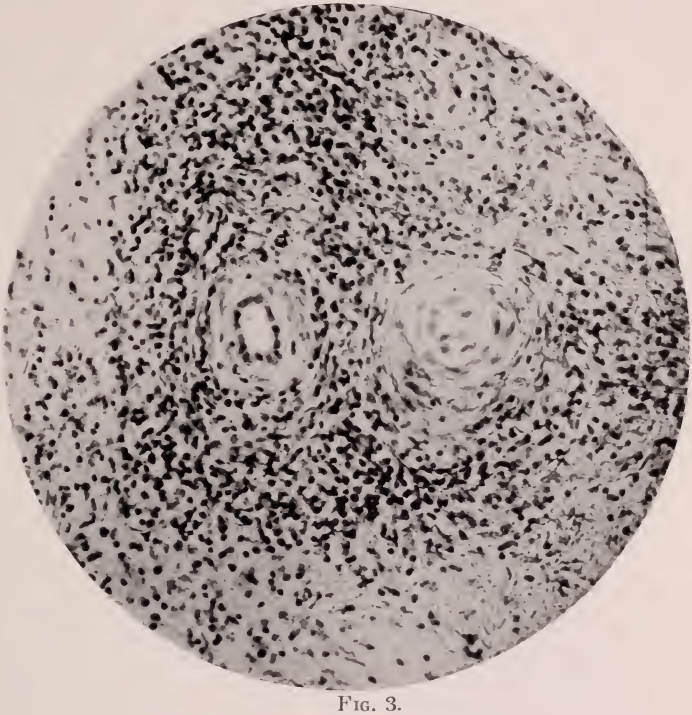

Fig. 3.

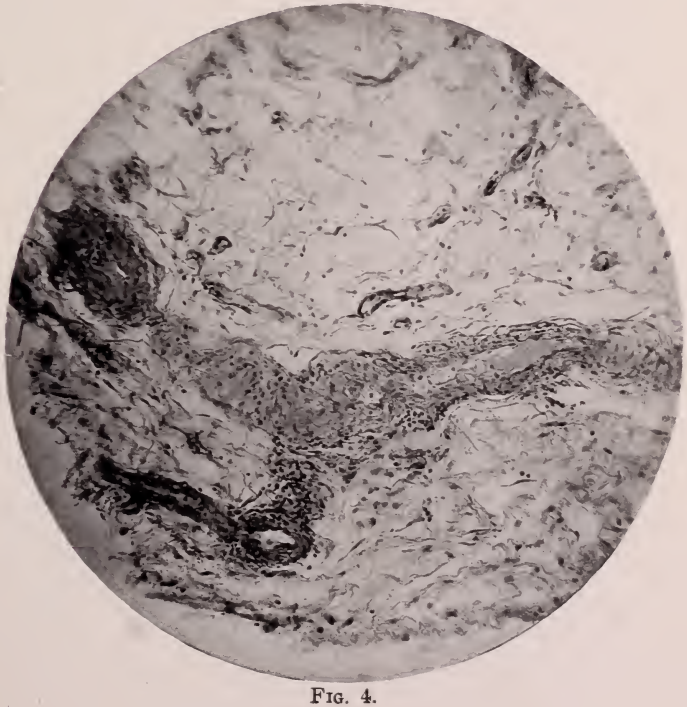

Fig. 4.

DESCRIPTION OF PLATES.

PLATE XVIII.

The colored drawing is intended to illustrate the irregularly rounded lesions on the back of the forearm which were believed to represent transitional forms of eruption between the typical atrophy on the dorsum of the hand and the serpiginous syphilide which appeared later on the arm. The red atrophic skin on the back of the hand is not as pronounced as the condition showed in the patient.

PLATE XIX.

Showing the symmetrical scaling and atrophic patches on the ankles, feet and knees.

PLATE XX.

Parchment-like atrophy of the skin of the dorsum of the hand after the subsidence of the inflammatory process. The blue-red color of the skin continued after the subsidence of the swelling and pain.

PLATE XXI.

Syphilitic serpiginous ulceration of the forearm. The photograph shows only half the extent of the syphilitic infiltration. The skin about the elbow is atrophic and pigmented.

PLATE XXII.

Fig. 1. Section of one of the atrophic lesions under a low magnifying power (Spencer ½ in., Zeiss compens. ocular 4) showing dense cellular infiltration in the upper corium and the exfoliating epidermis.

Fig. 2. Section from the same lesion more highly magnified (Spencer ¼ in. Zeiss compens. ocular 4.) showing the cellular infiltration and the invasion of the epidermis with the mononuclear leucocytes. The epidermis between the rete pegs is atrophic.

PLATE XXIII.

Fig. 1. Spencer ¼ in. Zeiss projection ocular 2. Showing perivascular cell infiltration with partial and complete obliteration of the vessels' caliber.

Fig. 2. Spencer ½ in. projection ocular 2. Showing a thrombus in a small vessel with partial obliteration of its caliber.

A CASE OF CHRONIC SYMMETRICAL DIFFUSE HYPERÆMIA OF THE EXTREMITIES, (ERYTHROMELIE).

By Hermann G. Klotz, M.D., of New York.

GEORGE SCH., forty-one years of age, a native of Bavaria, was admitted to the German Hospital on Jan. 7, 1904. The family history does not reveal any unusual features; the patient does not remember the occurrence of skin affections among his relatives. Except the usual diseases of childhood, he always enjoyed robust health and was mostly engaged in beer-brewing until he came to the United States, twenty-one years ago. Ever since, he has been working as a street paver. He has never had any venereal disease, has been married eighteen years and has one child; he drinks beer moderately, but smokes considerably. He has always been possessed of great muscular strength, excelling in physical power and endurance among his co-workers. His general health was undisturbed until about twelve years ago, when he had "rheumatism" in the back. As far as it is possible to ascertain at the present time, he suffered then from pains beginning in the lumbar ("kidney") region, extending over the buttocks and thighs to the knees. For several weeks he was not able to move about without great pain. This somewhat vague history points to a severe form of lumbago or muscular rheumatism rather than to a more deep-seated affection of the spine, etc. Some time after this sickness, certainly not less than eight to ten years ago, he noticed some changes in the color of the skin on the back of the left hand, a red stripe about one inch wide extending across just above the knuckles. This condition was not accompanied by any abnormal sensation whatever, neither pain, nor burning, nor itching, and for that reason but little attention was paid to it although soon afterwards similar changes were noticed on the right hand and later on both feet. On account of the absence of all subjective symptoms, the affection of the feet may have existed for some time without being recognized. The redness, in the meantime, gradually spread, at first over the fingers and toes, later from the periphery upwards to its present extent. Within the last year the patient has had repeated attacks of rheumatism in the back and in the extremities without any well defined objective symptoms; a particularly severe one occurring in November, 1903. During the last few years the skin on the portions affected by the redness has become dry and more or less scaly, particularly over the joints on the back of the hands and feet. On the latter regions the condition has

become more aggravated; the skin around both malleoli and the tendo Achillis, with the exception of the sole, has become so much hardened and stiff that the freedom of motion in the ankle joints has been considerably impaired. On account of this stiffness, which is principally noticeable in the morning after rising and gradually yields during the day, after having received but temporary relief from local remedies prescribed by his family physician, fearing that gradually he might become unable to work the patient sought relief at the hospital. Except for this condition of the feet the patient does not experience much discomfort from the affection of the skin; he is not particularly sensitive against exposure to cold as he states that he could work for six hours in cold and damp weather without any unusual inconvenience; he freely perspires under proper conditions. There is absolutely no tendency to any swelling of the feet or legs, nor to the formation of cracks or ulcers, although occasional injuries to the legs seem to have been slow of healing. The abnormal conditions always seem to have been somewhat more aggravated on the left side. Examination shows a man about five feet seven inches in height, strongly built, broad shoulders and uniformly well developed muscles. The important internal organs: heart, lungs, liver, kidneys, etc., are all in good, healthy condition, the urine is normal, the scalp is thickly covered with dark brown hair, growth of beard scanty, moderately developed mustache, eyes brown. The skin of the face and of the trunk appear perfectly natural in color and general appearance, but on all four extremities it shows a dull, somewhat livid redness, slightly more pronounced in the upright position than when lying down. In some portions the coloring is somewhat mottled. Where the epidermis is not much changed, numerous fine dilated capillary blood vessels can be distinguished, forming a delicate network. On pressure the redness disappears without any signs of pigmentation. On the upper extremities it extends from the finger tips to the upper third of the arm, gradually blending with the natural color. On the lower extremities it reaches in front to the inguinal folds, on the back over the buttocks also without any well defined borders; palms and soles are not affected, no perceptible difference between extensor and flexor surfaces. But within the affected area some portions, mostly over the articulations, show a more uniform, distinctly bluish color; most prominent on the backs of the hands and feet. This difference in the color apparently is not due to a greater development of the hyperæmia, but to the diminished transparency of the skin, owing to changes in the epidermis and particularly in its horny layer. Over the extensor and volar aspects of the elbows and knees and over the fingers and knuckles the

finer lines and furrows cannot be distinguished, the skin appears less elastic, dry, smooth, except here and there fine scales, with coarser wrinkles which suggest the appearance of crumpled up paper. However, the condition does not resemble that of crushed or squeezed cigarette paper (*"zerknittertes Cigaretten papier"*) of the authors; to the touch it is rather stiff and hard, than pliable and thin. At first sight, indeed, the skin suggests an atrophic condition, but on closer inspection and manipulation, neither increase nor decrease of the cutis proper can be demonstrated. A somewhat advanced development is observed on the backs of the hands and on the volar aspects of the wrists; here the surface is uniformly smooth, hard, almost glistening as if polished, without any trace of the natural furrows and folds; when perfectly dry small thin scales are being detached. While freely movable, the skin cannot be lifted up into folds. On the left hand a very sharply defined straight line, running diagonally across, marks the limits of the deeper color. The most intense hardening and stiffening, however, is found on both feet, surrounding the ankles almost exactly in the shape and to the extent of a gaiter. Here the horny epidermis is developed to such a degree that the bluish color gives way to a yellowish or brown tint, particularly on pressure; the surface throughout is dry, smooth and hard, so that considerable resistance is offered to movements of the foot and the feeling of extreme tightness is felt by the patient. On the back of the feet the horny layer is detached at intervals in the shape of more or less extended transparent pieces, resembling fish scales. This detachment is usually preceded by a moderate pain, feeling of pressure and tightness. In spite of the resistance to the movements of the foot no fissures or cracks are visible; the degree of hardness gradually diminishes toward the periphery and it disappears about one-fourth inch from the sole. There is nowhere an indication of œdema. On the lower extremities moderately dilated veins become visible in places, but not more than would be expected on a man engaged in work like street paving, which requires the employment of great muscular exertion in the standing position. There is however nothing in the appearance of these veins resembling those in cases of atrophy of the skin. The nails on fingers and toes are not in the slightest way affected; not much hair nor lanugo is found upon the affected portions, but the patient positively states that he never had much hair on the body or on the extremities. After bathing and washing with soap a bright desquamation can be observed almost over the entire affected area, but the scales are very thin, asbestos-like and closely adherent, and there is no copious detachment as in psoriasis and in other exfoliative processes.

As the result of the examination we find in an otherwise apparently healthy man, several abnormal conditions of the skin; the most conspicuous and evidently the principal feature is a hyperæmia, which occupies the larger part of all extremities, but not including the palms and soles. The redness of the skin has been observed to begin at least eight or ten years ago, it has gradually spread from the periphery and apparently is still extending. Absence of any local increase of temparature, of œdema and of every sensory disturbance demonstrate the passive character of the hyperæmia; on pressure the deeper color disappears completely to return immediately on the removal of the pressure, on some portions numerous dilated small and capillary blood vessels can easily be distinguished, as well as small round foci of dilated capillaries apparently around hair follicles. There is not the slightest evidence of any local or general cause for this dilatation or for the abnormal accumulation of blood in the papular layer of the skin.

Within this hyperæmic area certain changes in the condition of the epidermis, principally of its horny layer, become manifest, greatly varying in intensity upon different portions of the extremities from a quite insignificant xeroderma with fine dry minute scales peeling off the smooth surface, to the formation of stiff horny shields resembling fish scales; in fact, we find almost any stage of hyperkeratosis from a slight hardening to real ichthyotic forms. The cutis itself does not seem to have undergone any alteration, neither increase in volume nor decrease, neither hypertrophy nor atrophy. In consideration of the long duration of the process, without so far developing into atrophy, it seems reasonable to assume that atrophy is not a part of the anatomical changes. It is probable that there is some etiological relation between the hyperæmia and the hyperkeratosis.

In none of the accepted types of skin disease do we meet with a combination of hyperæmia and hyperkeratosis in symmetrical distribution over the extremities, together with the absence of all sensory symptoms. Several of the features, however, invite closer consideration and comparison with other cases in literature, principally the symmetrical appearance and restriction to the extremities with the tendency to spreading from the periphery. It is a characteristic feature in a number of observations, the majority of which have been published as cases of *Idiopathic atrophy of the skin.* Some have been described as *Erythromelie* (Pick,[1] Klingmüller[2]). In a very elaborate essay which includes a critical review of all the published cases Herxheimer and Hartmann[3] have tried to prove that in by far the greatest majority of such cases the atrophy is preceded by redness (congestion) and infiltration of the cutis, that is by an inflammatory process,

from which the atrophy results as a secondary process. For that reason they have proposed the name of *Acrodermatitis chronica atrophicans* for all cases in which some signs of infiltration or inflammation had preceded or were accompanying the atrophy. The name is to indicate the principal features: the chronicity, the inflammatory nature, the tendency to atrophy and the starting form the periphery of the extremities. As appears from a tabulated synopsis of the cases published by Herxheimer and Hartmann themselves and collected from literature, the histories greatly differ in detail, particularly in regard to the extent of the affection, but some features are common to all. Pick applied the name *Erythromelie*, meaning: "redness of the extremities" to a case which he published in 1894 and to two more observations in 1900 without paying any attention to infiltration or atrophy. But Herxheimer and Hartmann have found sufficient evidence of these conditions in the histories of Pick's second and third cases, as well as in the second case of Klingmüller to claim them as examples of their *Acrodermatitis chronica atrophicans*, so that, really, only the first cases of Pick and Klingmüller would remain as Erythromelie. With them our case seems to agree well enough, as a condition of infiltration or inflammation or one of atrophy cannot anywhere be demonstrated, and redness of the extremities is prevalent, only much more widely developed than in the other cases; in addition, we have a hyperkeratosis. Duhring[4] refers to two cases reported by John Cavafy[5] under the name of *Symmetrical congestive mottling of the skin*, which bear a great resemblance to the present case. This curious affection of the blood vessels occurred in women twenty-two, and twenty-one years of age. The first patient had attacks of rheumatic fever before and subsequent to the observation; the present condition began three years ago on the left shoulder and spread down the arm, soon afterwards on the right arm, the cheeks and both thighs with gradually increasing intensity. On the affected parts, *i. e.* principally the extensor surfaces of both arms, forearms and backs of hands, especially distinct over the left wrist, varied in tint from a bluish-red to a dull crimson, the skin appears faintly mottled with blotches and irregular rings and streaks of a dull red color, neither prominent nor depressed and covered by normal epidermis. No injected or tortuous capillaries could be distinguished, but the coloring was often more or less diffused. Although the mottling was not sharply circumscribed it contrasted strongly with the neighboring skin. The redness disappeared completely on pressure leaving behind in the most congested spots a delicate fawn-colored pigmentation. The markings were always intensified by cold and exposure; heat and great activity of the

circulation caused them to diminish very appreciably. The upright position favored their production. No pain, numbness, tingling, itching or other abnormal sensation was present. In the second case, mottling began eighteen months ago over the ankles and gradually spread to the legs and thighs, twelve months later the arms became affected and quite recently blotching has begun around the waist. The mottling became more extensive and of a deeper purple color over both legs and thighs, the condition was worse in winter and increased by exposure, diminished by exercise, warmth and the recumbent position. This case very much resembles the picture of Pick's first case, which differs only by a certain prominence of the veins, not mentioned in Cavafy's cases and likewise absent in our case.

Cavafy looks upon the condition as due to a venous stasis or passive congestion, as an exaggeration of the marbling often seen on the skin of children and young persons after exposure to cold. He finds it difficult to determine the cause as there is no proof of a mechanical hindrance to the venous outflow; probably it is a vasomotor neurosis allied to the local asphyxia of Raynaud. He is not any more able to explain the symmetrical distribution, but he believes that it is probably due to the anatomical arrangement of the blood supply of the skin.

Cavafy's remarks were published in 1883, previously to any of the cases collected in Herxheimer and Hartmann's tables, which apparently represent a complete review of the literature. Subsequent authors have not been able to shed much more light on the obscure origin of these conditions. Mechanical, thermal, chemical and bacteriological influences have all been considered by Herxheimer and Hartmann without decided or valuable results. Kaposi, Neumann and others have spoken of a vasomotor paresis, others of a tropho-neurosis, Klingmüller of a peculiar affection of the blood vessels. Rheumatic affections are mentioned in one case of Pollizzari,[6] in one of Cavafy and in the present case, without any possibility of showing a connection with the affection. Our case does not furnish any new points of view for the explanation of the true nature of the phenomena. On account of the absence of any distinct infiltration or atrophy it can hardly be classed under Acrodermatitis chronica atrophicans or idiopathic atrophy; it comes next to Pick's Erythromelie, without exhibiting any distinct phlebectasis. The wide and uniform extension of the redness over exterior and flexor surfaces of the extremities and the hyperkeratosis distinguishes the case from all others on record and make it appear almost unique.

Since the patient was admitted to the hospital and since he was

presented before the New York Dermatological Society, a considerable change has been effected in his condition. He has been treated with warm baths and thorough inunctions with a two and five per cent. resorcin and ichthyol ointment, of which lanolin is the principal constituent; the more resistant portions have, from time to time, been rubbed with the officinal (five per cent.) solution of caustic potash to favor the removal of the scales. Internally small doses of fluid extract of ergot, later of ichthyol have been given. After several weeks of this treatment great improvement of the keratosis has become manifest, principally on the back of the hands and feet and on the wrists. The bluish tint on this region and over knees and elbows has almost entirely disappeared. Even on the back of the hands and feet, where the surface was almost polished, dry and smooth, the natural furrows and lines begin to reappear; the stiffness around the ankles is so much reduced that movements are quite free, however, a slight desquamation is still present and a certain feeling of stiffness and dryness remain. Therefore daily subcutaneous injections of pilocarpine (from five to eight milligrams) have lately been given; purposely moderate doses have been employed, because the production of profuse sweating was not intended. (See the writer's "Notes on Pilocarpine in Dermatology," Jour. of Cutan. Dis., 1890, viii, 409). Nevertheless, the efforts of the drug have been distinctly felt and as the patient asserts, have produced a greater softness and pliability of the skin. Within the last week the examination of the urine, which on admission and for several weeks afterward had given negative results in regard to albumen and sugar, without any evident cause began to show distinctly the presence of sugar in increasing quantities up to five per cent. In Klingmüller's first case the presence of glycosuria is mentioned, but, probably, without the slightest influence on the affections of the skin.

REFERENCES.

1. Pick, T. F.—*Tageblatt der 66 Naturforscher Versammlung in Wien,* 1894, *und Festschrift für Kaposi,* 1900, p. 915.

2. Klingmüller, Victor—*Festschrift für Kaposi,* 1900, p. 629.

3. Herxheimer und Hartmann—*Ueber Acrodermatitis chronica atrophicans. Archiv. f. Dermat. u. Syph.,* 1902. LXI., p. 57, 255.

4. Duhring, Louis A.—*Cutaneous Medicine,* II., 239.

5. Cavafy, John—*Clinic. Society Transactions,* 1883, XVI., 43.

6. Pellizzari cited by Herxheimer—*Viertelj. f. Derm.,* 1884, XI. (XVI.), p. 504.

PITYRIASIS ROSEA.

By Harvey P. Towle, M.D., Boston.

Assistant Physician to Patients with Diseases of the Skin, Out-Patient Department, Massachusetts General Hospital.

I HAVE collected from the records of the Dermatological Department of the Massachusetts General Hospital one hundred and fifty-eight cases of pityriasis rosea. To these I am able to add, by his kind permission, forty-four cases from the private records of Dr. John T. Bowen, making a series of two hundred and two cases. In every case I have noted, so far as was possible, the character of the lesions, their distribution, the presence of a *plaque primitive*, the month of occurrence, the sex, the age, the presence of prodromata and signs of accompanying general disturbance, the presence of itching, recurrence, race and occupation. In five cases also, I have to record examinations of the blood and in two cases, a histological examination.

The eruption occurred in two forms, a macular and a circinate, with about equal frequency. In the macular form the lesions were roundish, varied in size from a pin's head to the thumb nail, were slightly or not at all elevated, were a pale red or rosy color and bore fine and not especially abundant scales. In the circinate form the lesions were larger, with a clearer center of a tawny or wash leather color, with the periphery more pronounced and scaling. Sometimes the lesions became confluent and covered quite large areas. In certain cases the scaling in the older lesions was quite characteristic. The scale was attached by the end toward the sound skin, while the end toward the center of the lesion was free. Therefore, to loosen it it was necessary to move from within outward. Blaschko[1] and Hollman[2] consider this an aid in differentiating pityriasis rosea from psoriasis, as in the latter the scale must be loosened from without inward. In some of these older lesions also the surface of the center of the lesion was crumpled like cigarette paper, an appearance which has been spoken of by Fournier,[3] Bureau,[4] Duhring,[5] and others as being of diagnostic importance.

An analysis of the distribution of the eruption in the cases of this series showed that the regions involved were those usually mentioned. In most of the cases the eruption was general over the trunk and upper parts of the extremities. In some of the milder cases, however, it was limited to one region as, for example, to one arm. Thus

I find in the records such notes as "limited to one arm," "from the hips down," "lower legs," "back only," "neck only." Many writers (Fournier,[3] Tandler,[6] Fiocco,[7] Stelwagon,[8] Hyde,[9] and others) state that the eruption occurs but rarely upon the face. In one case of the present series the eruption was limited to the face and neck, while in eight other cases of an extensive general eruption the face was also involved. In one of the cases the scalp was affected (compare Bazin[10] and Hyde[9]). The hands and feet were never invaded, which agrees with general opinion. Fiocco,[7] however, reports one very acute case which involved both hands and feet.

As regards the occurrence of the *plaque primitive* I found record of it in twenty-five cases, or in twelve and three-tenths per cent. of the total. In some of the cases there was a history of its having preceded the general eruption by a week or ten days, but in most of the cases it had escaped the observation of the patient and was found in the midst of the general eruption. In regard to this point I may state that Brocq,[11] in his article upon the *plaque primitive* says that "it may be found in the midst of the secondary eruption by its larger size." Unfortunately the records did not always give the location of the plaque, but from such data as are at hand, it apparently occurred most frequently somewhere upon the trunk. This agrees with Brocq, who also adds that it may occur upon the neck or arms. In one of the series it was found over the scapula, in another upon the middle of the back and in two upon the right thigh.

The disease was found to be rather infrequent as it occurred in but one out of two hundred and eighty-two cases, or in about three-tenths of one per cent. I could find but three writers, Crocker,[12] Fiocco,[7] and Weiss,[13] who gave figures upon this point. Crocker found the disease to occur but once in two hundred and fifty cases. Fiocco found it in one and twenty-seven one hundredths per cent. of all cases in Breda's clinic and polyclinic. Weiss put the frequency as high as from five to twelve per cent. It will be seen that the frequency, as shown by this series, is practically the same as found by Crocker. It also agrees with the statement made by most writers that the disease is infrequent.

The figures in regard to the month of occurrence are interesting as they show some variation from the figures given by several men. I found that twenty-six cases had occurred in November; twenty-five in June; twenty in February; nineteen in September; eighteen in January; seventeen in May; sixteen in October; fifteen in March; fourteen in April; nine in December; eight in July, and seven in

August. It will be seen that the largest months were November and June. If the figures be taken by seasons it will be found that by far the largest number of cases was in the autumn (September, October, November), i. e., sixty-one. There were forty-seven cases in the winter, forty-six in the spring and forty in the summer season. As already stated, this varies somewhat from the opinions expressed by other men. Thus Gibert[14] said that pityriasis rosea was seen frequently in the warm season; Bazin,[10] that it was seen in the spring; Tandler,[6] that it was most common in the spring and fall; Fournier,[3] that it occurred at the change of the seasons, while Crocker[12] and Fiocco[7] think that the season has no influence.

The results as to sex are in complete agreement with the accepted opinion that the disease is most frequent among females. Of the two hundred and two cases, one hundred and thirty-three, or about sixty-six per cent. were in females and sixty-nine, or thirty-four per cent. were in males.

The figures with regard to the age at which the disease appeared would seem to show that age is an etiological factor. It was found that nearly all the cases appeared between the ages of ten and forty. Divided into decades the figures are as follows: Twenty-one were under ten, forty-three between ten and twenty, seventy-seven between twenty and thirty, forty-six between thirty and forty, while only eleven were over forty. According to these figures, therefore, the disease was most frequent between the years of twenty and thirty. This conclusion agrees with Fournier's[3] and practically with Fiocco's.[7] Fournier states that pityriasis rosea is most frequent between twenty and thirty, while Fiocco gives the age as between twenty and forty. Hyde[9] and Lassar[15] both say that the disease is most frequent in young women. Crocker's[12] statement that one-third of the cases were among children disagrees entirely with the above.

Prodromata were almost entirely absent and in only a few of the cases were there any accompanying symptoms of a general disturbance. Gastric dilatation, as mentioned by Feulard[16] and several others, was never observed. In only one case were there any gastric symptoms of moment.

Itching, although present in a number of cases, was never a marked symptom and in the majority of cases was absent altogether. In a few of the cases in which itching was present the patient remarked that sweating or heating increased it. These observations agree with those of most writers although Bazin[10] stated that itching, slight at first, increased and persisted throughout. Lassar[15] also says that itching never fails.

Reports of recurrences are very rare in the literature of the disease. In this series, however, there was one undoubted case. The patient was a boy who had his first attack when five years old and a second typical outbreak five years later. Both attacks were seen by Dr. Bowen. The only other case of recurrence which I have found was one from Breda's[7] clinic.

Race and occupation were apparently without influence. In this connection it is interesting to note that twelve cases of the series occurred in physicians or in members of physicians' families or in hospital workers. I could not attach any significance to the fact however.

No report of an examination of the blood in pityriasis rosea appears in the literature so far as I have been able to find. At the Massachusetts General Hospital in five cases a blood count was made by Dr. Rowley, to whom I am indebted for the following reports. The cases in which the blood counts were made were typical and well developed as will be seen from the following short descriptions.

Case I. Female, aged thirty. Admitted to the Dermatological ward of the Massachusetts General Hospital, Oct. 30, 1903. Five weeks before admission an eruption had appeared over the sternum and thence spread over chest and shoulders. Feels well in every way. Denies cough. No itching unless she becomes heated. Patient was well developed and nourished. Heart, negative. Lungs, negative; except for an occasional click above right clavicle. Over shoulders, front and back, chest and flanks was a well developed, circinate eruption of pityriasis rosea. October 31 a blood count showed present: Polynuclears, 45 per cent.; lymphocytes, 46.5 per cent.; eosinophiles, 4 per cent.; mast cells, 4.5 per cent. November 5—Eruption practically unchanged. Blood—Polynuclears, 39.5 per cent., lymphocytes, 55.5 per cent.; eosinophiles, 4.5 per cent.; mast cells, .5 per cent.

Case II. Nov. 10, 1903. Male, aged thirty. Seen at Out-Patient Department. Eruption of five weeks' duration. Heart and lungs negative. Has ringed and gyrate lesions over chest in front, shoulders, arms, abdomen and legs. Blood: Polynuclears, 49 per cent.; lymphocytes, 41 per cent.; eosinophiles, 8 per cent.; mast cells, 2 per cent. December 1: Color of eruption less marked. Now present over thighs, front and back, buttocks, fronts of knees and the upper parts of lower legs. Blood: Whites, 7,100; polynuclears, 27 per cent.; lymphocytes, 69 per cent.; eosinophiles, 4 per cent.; mast cells, 0. This case also illustrates very well the point made by Gibert and Fournier that the eruption travels from above downward.

Case III. Nov. 13, 1903. Female, aged twenty-nine. Out-Patient Department. Is nursing a four months' old baby. Three weeks ago a circular patch appeared on radial side of left wrist. Several days later a general eruption came out. Itching, mild and occasional only. Eruption is macular and is situated on front of chest, on abdomen, on upper parts of arms, less on the back and slightly on the thighs. November 16—Larger lesions show clearing centers with scaling and slightly elevated borders. November 30—Numerous, fine, scale-capped papules have appeared since last visit. November 30—Older lesions over upper half of body paler. Over lower half and over thighs a fresh outbreak. December 7—General eruption has faded very much, leaving irregular tawny colored patches whose borders are outlined by flat scales which have their free edge projecting inward. Blood—Polynuclears, 53.5 per cent.; lymphocytes, 42.5 per cent.; eosinophiles, 3.5 per cent.; mast cells, .5 per cent.

Case IV. Male, aged twenty-five. Admitted to the Dermatological ward Nov. 17, 1903. Has had "stomach trouble" for over a year but has had less than usual during past two months. Eruption for about two weeks. Heart and lungs negative. Eruption of the macular type over chest, inner side of upper and lower arms, upper part of the back and around the neck and over abdomen. Blood: Polynuclears, 31.5 per cent.; lymphocytes, 63.5 per cent.; eosinophiles, 4 per cent.; mast cells, 1 per cent.

Case V. Male thirty-nine. Out-Patient Department. Dec. 16, 1903. Ten days ago an eruption of macular and circinate lesions appeared over the upper half of the body. December 28—Blood: Polynuclears, 61.5 per cent.; lymphocytes, 33.5 per cent.; eosinophiles, 4.5 per cent.; mast cells, .5 per cent.; whites, normal.

The most marked changes in the blood occurred in Case II., in which the eruption was also abundant. The slightest changes in the blood were in Case V., in which the eruption was also light. In all of the cases there was a lymphocytosis, eosinophilia and an increase of mast cells. Judging from the white count, which was made in two cases, there was no leucocytosis. I consulted Dr. Richard C. Cabot concerning these changes. He wrote that since in other diseases of the skin similar conditions arise, at times, the blood examination seems to be of no value as an explanation of the differences between pityriasis rosea and other dermatoses. The findings also seemed to him to point against the explanation of pityriasis rosea as an infectious process.

The histological changes found agree with the investigations of

Tandler [6] and Loewenbach.[17] The chief changes were found in the cutis with very slight involvement of the epidermis. The horny layer was normal and the granular layer preserved. There was a slight œdema of the lower part of the rete. In the papillary layer of the cutis and to a less degree in the deeper parts there was dilatation of the vessels and a cellular infiltration, most marked around the vessels. Hollman,[2] who examined sections from three different stages of the disease, states that these changes are those of the early stage. In an older stage he found the changes in the cutis to have increased and the rete to be more involved. He also found minute subcorneal vesicles in this stage as have Unna,[18] Sabouraud,[19] and others. In the final stage, according to Hollman,[2] there is a detachment of the old horny layer which leads to a drying and crumpling of the detached part. The active process, dilatation, infiltration, etc., was most marked in the periphery of the lesion, while the center appeared to be returning to a normal condition.

If now we use the results of the analysis of this series of two hundred and two cases to describe the disease we should find the following: Pityriasis rosea occurs in the two forms, the macular and the circinate with about equal frequency. The eruption affects most often the trunk and the upper parts of the extremities, but occasionally it is confined to one part. The *plaque primitive* is not always found. The disease is most frequent in the autumn months and is more common in women than in men. Although the disease may occur at any age it is most frequent between twenty and thirty. As a rule there are no prodromata or accompanying disturbances of the general health. Itching may or may not be present. Recurrences, although rare, do occur. Race and occupation have no influence upon the occurrence of the disease. The blood shows certain changes which, however, do not seem to be characteristic. Histologically, the chief changes are in the cutis.

I wish to acknowledge my indebtedness to Dr. John T. Bowen for his encouragement and aid and also to Dr. Rowley for the examinations of the blood.

REFERENCES.

1. Blaskko—*Berl. Derm. Gesell.*, June, 1899. Ref. *Monats. f. prakt. Derm.* 29.
2. Hollman—*Arch. f. Derm. u. Syph.*, 1900, LI. 229.
3. Fournier—*Ref. Monatsch. f. prakt. Derm.*, 30.
4. Bureau—*Gaz. Med. de Nantes*, 1903, XXI., p. 785.
5. Duhring—*Am. Jour. Med. Sci.* n. s. 80, 1880.
6. Tandler—*Archiv. f. Derm. u. Syph.*, 37, 1896.

7. Fiocco—*Ref. Monatsh. f. prakt. Derm.*, 34.
8. Stelwagon—*Diseases of the Skin.* Ed. 1902, p. 178.
9. Hyde—*Diseases of the Skin.* Ed. 1901, p. 289.
10. Bazin—*Am. J. Med. Sci.* (Duhring) n. s. 80, 1880.
11. Brocq—*Ann. de Derm. et Syph.*, 2 s. 8, 1887, p. 615.
12. Crocker—*Diseases of the Skin.* Ed. 1903, p. 405.
13. Weiss—*Jour. A. M. A.*, July 4, 1903, p. 20.
14. Gibert—*Maladies de la Peau*, 1860, p. 402.
15. Lassar—*Deutsche Med. Wchnschr.*, May 26, 1902.
16. Feulard—*Ann. de Derm. et Syph.*, 2 s., 10, 1889.
17. Loewenbach—*Wien. Klin. Wchnschr.*, 1889, No. 23.
18. Unna—*Lehrbuch*, 1894.
19. Sabouraud—*Monatsh. f. prakt. Derm.*, 36, 531.

SOCIETY TRANSACTIONS.

NEW YORK DERMATOLOGICAL SOCIETY.

321st Regular Meeting, January 26, 1904.

Charles T. Dade, M.D., President.

A Case of Chronic Symmetrical Diffuse Hyperæmia of the Extremities, beginning in the periphery and spreading upwards, accompanied by trophic, more or less hyperkeratotic changes in the skin, principally over the extensor surfaces of the joints, probably related to Pick's "Erythromelie" and to certain cases of atrophy of the skin. Presented by Dr. H. G. Klotz. (This case is fully described on page 170.)

Dr. Elliot recalled two similar cases to the one presented in young women. In one, the disease had been present for eight or nine years, developing after a severe septicæmia; in the other, for a period of twelve or thirteen years, and coming on apparently without cause. The condition occupied about the same distribution on the extremities, was worse in the winter and better in the summer. On the arms, legs and feet the skin was cold, of a dark-red or purplish color, and as in this case the only other changes seemed to be in the epidermis. There was no atrophy of the derma in these cases nor did there seem to be any in the case shown. He was unable to explain the pathology of these peculiar conditions.

Dr. Fordyce considered that there were cases of transition between the erythromelie of Pick and symmetrical atrophy. Both began in the extremities and both were preceded by hyperæmia. In this case the atrophy was not marked and the condition corresponded more closely to Pick's description. In these cases the trouble seems to begin by an alteration in the vascular supply.

Dr. Allen called attention to the pain in the lower lumbar region

and thought that the symmetrical distribution with well marked limiting line on thighs and arms was suggestive of a central nervous trouble.

Dr. Klotz (closing the discussion) shared the opinion of Dr. Fordyce that these cases and those of atrophy were due originally to the same cause; why in one case the condition led to atrophy and in others to hyperkeratosis was not easy to explain. In reading up the published cases one finds that as to the details they all greatly differ among themselves, but some features they all have in common; the restriction to the extremities, the tendency to spread from the periphery upwards, the redness and the production of some trophic disturbance of the skin.

A Case of Multiple Sarcoma. Presented by Dr. Jackson for Dr. Fox.

The patient was a man, thirty-three years of age, married and in good health until July, 1903, when the present disease manifested itself. The patient denies any previous skin trouble and states that there is no history of tumors in his family. The tumors were first noticed upon the abdomen, and have rapidly increased in numbers until at present there are tumors scattered all over the body. The tumors are of all sizes from that of a pea to a pigeon's egg. The skin overlying the tumors is unchanged in color except over some of the larger ones where the skin is of a bluish color. The tumors are firm and elastic to the touch and are freely movable under the skin. The largest tumors are on the trunk. There has been no change in his health until the past few weeks, since then he has had a severe itching of the legs sufficient to keep him awake at night. The patient presents a cachectic appearance, and states that he is much weaker. One of the tumors was excised for pathological examination and the pathologist of the Presbyterian Hospital considered it to be a large round-celled sarcoma.

Dr. Elliot considered the case as one of disseminated sarcomatosis. The circumscribed growths, their apparent encapsulation, their free mobility and their location in the subcutaneous tissue were in favor of this diagnosis. Besides, they were for the most part colorless, no redness, but on the contrary many had a peculiar bluish tint which he had often seen in cases of sarcoma.

He would hardly believe the case one of carcinoma. The patient was too well nourished,—there was an absence of cachexia. A case of such extensive distribution could scarcely be a primary carcinomatosis cutis, but would be secondary to some existing tumor, which, however, did not exist in this case. These cases were not necessarily malignant. The Kaposi type of multiple hemorrhagic sarcomatosis was very slightly so and even in instances benign in character. Hardaway reported a case that lasted for twenty years and then recovered.

Dr. Fordyce considered the case as a generalized sarcomatosis or carcinomatosis. He was unable to say from the clinical appearance alone to what form of malignant disease it belonged.

Dr. Allen considered the case malignant. In a disseminated carcinomatosis he thought there would be more involvement of the skin itself; in this case the tumors seemed subdermic. He therefore considered the case as a disseminated sarcomatosis. He considered the Röntgen ray indicated in the treatment, as had already been commenced. He called attention to several cases of sarcoma which had melted away under the ray. In a case of sarcoma of the jaw, now under treatment, there was a shrinking of the mass without a breaking down of tissue.

Dr. Lustgarten thought the case should be carefully examined for the primary tumor. A careful examination of the abdomen and rectum should be made. In some of these cases the growth was often extremely slow, but the cachexia would usually be more marked than in this case. In this case he particularly remarked the hardness, flatness, and the uneven nodulated character of the tumors. He was inclined to regard it as a scirrhus form of carcinomatosis, although the pronounced enlargement of the superficial blood vessels speaks for sarcoma.

A Case of Granuloma Fungoides Treated by the X-ray. Presented by Dr. Lustgarten.

The patient was a man forty-one years of age, born in Russia, who came to this country about twelve years ago. The disease began about five years ago, and he has been under treatment continually in various institutions. At Mt. Sinai Hospital he has been treated for a long time with increasing doses of arsenic given hypodermically. He has had in all about one hundred injections, amounting to more than forty grains of arsenic. Under this treatment the subjective symptoms improved slightly, but the objective symptoms grew gradually worse. The main subjective symptom was the itching, which was so bad that he was compelled to give up his occupation; could not rest at night and lost considerable weight. When X-ray treatment was begun, the lesions were scattered almost over the entire body, including face and extremities. They were most prominent on the back, both sides of trunk, both shoulders, back of neck, on left side of face, gluteal regions, pubic region, inner surface of both thighs, both knees and ankles. He had in all about thirty-two X-ray exposures, amounting to over 500 minutes. These were all given at a distance of about five inches with a medium vacuum tube. Practically, from the first exposure the itching in the exposed parts ceased, coincidentally with an evident flattening of the lesions. A mild dermatitis developed on various parts of the body. One on the left side of the face with a conjunctivitis of the left eye. This disappeared in a few days, leaving an apparently healthy surface behind. Quite a large area of superficial dermatitis developed on the right side of body and from the right gluteal region down to below the posterior surface of the right knee. This dermatitis was all of the first degree and disappeared within a week with a shedding of the epidermis, leaving a perfectly

healthy surface. There is present some alopecia on the back of head, without any apparent dermatitis, as the result of the ray applied to the back of the neck. At present the subjective symptoms have entirely disappeared, the patient feels perfectly well, and attends to his business. He has gained considerably in weight since the beginning of treatment, sleeps well, and as he himself expresses it, is beginning to live again. The patches have almost entirely disappeared, with the exception of a few small unrayed spots, for which he is still under treatment. Up to the present, there is no recurrence "in situ" in any of the parts where even a mild dermatitis was produced. A single twenty minute exposure will produce a dermatitis on any part of the body, followed by a complete disappearance of the lesion. While marked beneficial results can be accomplished with short exposures, without producing any reaction, I believe that to get the best results, and to give the patient the greatest chance against a recurrence, a dermatitis should be produced in every part of the body affected by the lesions.

The X-ray treatment was carried out by Dr. S. Stern in my dispensary department.

Dr. Elliott said the result was beautiful. He had seen several times a case of mycosis fungoides in consultation with Dr. Hope of Virginia during the last two years. Chaulmoogra oil, cacodylate of soda and various other preparations had all been tried with only slight benefit. Last May, in view of Jamieson's results, he had written to Dr. Hope advising X-ray treatment. Seventy-two exposures had been given by Dr. Gwathmey, and the result had been complete disappearance of all lesions. The itching, which had been frightful, had very quickly disappeared under the ray and so far there had been no return. How long the case will remain well it is, of course, impossible to say, ignorant as we are of the true pathology of the disease and of how lasting the effects of the X-ray may be. We do know that cases of mycosis have, however, cleared up and been free of lesions for long spaces of time without any known cause for the improvement and have then relapsed. Still, even to relieve the itching was a great gain in the therapy of the disease. It should not be forgotten, however, that some cases have not been improved by the X-ray. There was another instance of mycosis he would refer to. It was one he had seen off and on for about eight years, and which had been referred to him by Dr. Dyer. The process had been present for two years previous to Dr. Elliot's first examination. The eczematous stage had persisted all this time, with the exception that on the right thigh and left buttock small tumors had constantly appeared over a circumscribed space, but nowhere else. These small tumors had been variously destroyed as soon as they appeared with Paquelin cautery, or glacial acetic acid and the patient was even to-day in very good health. Dr. Elliot had recommended the X-ray for this case also, and for the previous one had advised that it be used once a week for a year at least, even though no lesions existed.

Dr. Allen recalled the terrible itching in the case under discussion when he had first seen the patient, then in the premycotic state. He had at that time, over two years ago, administered the ray with marked relief of the intense pruritus. He thought that for this condition the high frequency current was also very valuable. He advised keeping up the treatment for two years after the case was apparently cured.

Dr. Lustgarten (closing the discussion), said it was indeed remarkable the almost immediate relief from itching afforded by the X-ray in these cases of granuloma fungoides. One application was sufficient to cause the disappearance of this symptom. One exposure of fifteen minutes' duration was long enough to cause the disappearance of a tumor. In this case chaulmoogra oil had been given up to twenty minims t. i. d., with no improvement. This man has had some relapses, that is some new lesions have appeared, but there has been no local recurrences where the lesions had melted away under the X-ray. Even if the cure was not permanent the relief afforded was a great boon.

In regard to the treatment of X-ray burns he had found a combination of the acetate and the sulphate of aluminum to be the best thing to afford relief.

Superficial Epithelioma of the Nose and Eyelid Cured by the X-ray.

Presented by Dr. Fordyce.

The patient, James C., forty-three years of age, first noticed the growth on the side of the nose about thirteen years ago. Curetting had been performed twice, the last time was five years ago. The growth seemed to take on renewed activity and spread rapidly after the last curettage. Treatment was begun by the X-ray in June, 1903, but was discontinued during August and September. After eight seances the ulceration healed entirely and there is now no evidence of trouble. There was an opacity of the right cornea, the result of an old keratitis; under the ray the vision in the defective eye had considerably improved owing to the partial clearing up of the cornea.

Dr. Allen considered the X-ray as particularly valuable in rodent ulcer in the region of the eye. In carcinoma of the eyeball he found only benefit and does not think the danger of X-raying the normal eye serious, having seen only occasional mild conjunctivitis result. He would keep up the treatment for some time to avoid relapse.

Dr. Fordyce (closing discussion), said that the patient had reacted very quickly to treatment. That in regard to the treatment of X-ray burns he had found the Squibb's powder of camphor, alum and carbolic acid to be very efficient.

A. D. Mewborn,
Secretary.

NEW YORK DERMATOLOGICAL SOCIETY.

322d Meeting, February 23, 1904.

Dr. Fordyce, President, pro tem.

A Case of "White Spot" Disease. Presented by Dr. Sherwell.

The case presented to-night, Miss B, æt. 26, resembles one shown at the March meeting, 1902, of this Society, and reported in the Journal, June, 1902. Sections were made of the lesions thereafter and described fully in a paper by Dr. J. C. Johnson and myself in the Journal (July, 1903), under the title of "White Spot Disease." Reference was made to a case shown by Dr. F. H. Montgomery at the meeting of the American Dermatological Association held at Chicago, 1901, and to a case reported by Dr. Westberg of Unna's Clinic (*Monatsh. f. prakt. Derm.*, XXXIII, p. 355).

Dr. Johnston's report of the pathological findings may be summarized as "a nearly pure degeneration limited to the papillary body and the upper portion of the reticular layer. In the degenerated mass the collagen has altogether disappeared, its place being taken by a granular material which has lost its characteristic acidophile staining tendency. It has little or no affinity for eosin, orange or fuchsin. The elastic tissue is broken up into short lengths of fiber or granules which take the acid örcein stain more deeply than the normal tissue. The elastic network covering the papillæ has completely disappeared where the process is most advanced, and in some places shows beginning rhexis. The vascular changes showed a loosening from their attachments to the surrounding tissue and a dilatation with, in places, a narrowing of the lumen due to a swelling of the endothelial cells. The epithelial changes are secondary. The rete is reduced to a few layers of cells, four or five, which show hydropic degeneration." As to causation, Dr. Johnston advanced the theory that it is due to "an obliteration of the smaller branches in the reticular plexus. The obliteration may be congenital or acquired, due to failure of complete canalization or blocking by swollen epithelium."

The present case, to my mind, is an exact analogue; the location of the lesions, the mode of progress, etc., are identical. The only difference being a more rapid development.

In the first case (Miss M's) the lesions were slow in development, the first having appeared about twelve or thirteen years prior to her presentation before the Society (March, 1902). In the case presented to-night (Miss B.) the first appearance of lesions was less than two years ago. The ages of the two are about the same (twenty-six years). Miss B is decidedly more robust, having always had good health.

The abnormal areas in the patient presented to-night are of a dull, dead white by direct illumination and appeared first at the base of the neck at the junction with the sternum. The lesions have gradually in-

creased in number and enlarged in size until they now exceed the size of a ten-cent piece. Their extension has followed in general the lines of cleavage in the skin and now extend from a point some distance up on the neck down as far as the mammæ and behind down between the shoulders. The lesions are discrete in character at the outset and usually remain so. Even where patches seem to run together there is usually a line of demarkation of apparently healthy tissue around them. This tendency to non-coalescence seems directly opposed to the usual mode of progression in scleroderma and in morphœa, and in my judgment, as in the other cases, gives reason for considering it as a pathological entity.

Dr. Bronson considered the case an atrophia cutis maculosa.

Dr. Fordyce recalled a similar case which came under his observation about a year ago. In his case the lesions were mostly on the buttocks, sides of trunk, and breast. The lesions were at first hyperæmic and then became atrophic. In the case under discussion there had been no history of hyperæmia. The histological changes described in the case reported by Dr. Johnston in the Journal was a homogeneous degeneration of the collagenous fibers in the corium.

Dr. Sherwell (closing discussion) considered this case as the exact counterpart of the case which he had reported with Dr. Johnston in the July number of the Journal. In the treatment he had used local applications of resorcin in solution. There had been some exfoliation and the case was cosmetically improved.

A Case of Vitiligo. Presented by Dr. Allen.

The patient was a lady whose neck and trunk was covered with various sized white plaques surrounded by deeply pigmented areas. The condition had existed for ten years. Recently her physician had applied the X-ray. The result of six exposures was to deepen the surrounding pigmentation, but no change had occurred in the round white spots. He asked for suggestions in therapy.

Dr. Bronson stated that he had recently observed the effect of X-rays on several patches of vitiligo in a patient under treatment for another affection. Some of these patches came well within the area of irradiation, but no change had taken place in them after about twenty-five exposures except that the pigmented borders seemed deepened in color. He could see no reason why the X-rays should have any more beneficial effect than exposure to the sun's rays, which, as was well known, only had the effect of increasing the peripheral pigmentation, thus making the white spots more conspicuous.

Dr. Allen (closing discussion) had hoped some one would have mentioned his experience with the high frequence current in these cases. He thanked Dr. Lustgarten for the Finsen light suggestion.

Lichen Planus. Presented by Dr. Allen.

The patient was a woman of middle age in whom the disease began four months ago with an eruption upon the wrists and hands which was mistaken for "hives" for several weeks before a physician was consulted. The lesions rapidly extended over the entire body. The skin had been so vulnerable that the slightest blows, injuries and even pressure of the shoe buttons, when the other foot was rubbed over the dorsum, sufficed to bring out large bullæ. There are at present three such traumatic water blisters. No arsenic has been taken, at least not for two months. Under high frequency treatment during the past week the improvement has been very rapid; all other internal and external measures previously employed having been stopped.

Dr. Lustgarten said that in his clinic the X-ray had been used with benefit in lichen planus cases.

Dr. Allen (closing discussion) had found great improvement from the use of the high frequency current. He thought d'Arsonvalization was of value in stimulating a torpid liver, and thus indirectly of benefit.

A Case of Disseminated Lupoid Acne. Presented by Dr. Fox.

The eruption first appeared two years ago on the upper lip in an acute papular form. After a few weeks of headache and insomnia, it increased rapidly, affecting other portions of the face. The acute congestion of the lesions at the outset occasioned a severe burning sensation and a notable swelling of the eyelids.

A year ago, when the patient was presented to the Society (March 24), the face was nearly covered with small nodules of a dull red hue, some aggregated and showing a tendency to suppuration. A burr could be pressed almost through the skin and by means of a curette a rounded mass of gelatinous tissue could be dug out, followed by copious bleeding.

Treatment at intervals has improved the condition, but not effected a cure. The lotio alba produced a decided diminution of the inflammatory symptoms. The X-ray used on the right cheek has made it smoother and the use of a burr dipped in carbolic acid has destroyed wholly or partially many lesions on the other side of the face.

Dr. Elliot said that he considered the case one of lupus disseminatus follicularis or lupus miliaris. The fact of not finding tubercle bacilli was not of decisive importance. The younger the lupus the more readily could bacilli be found, the older the more difficult were they to be found. In any case, many sections must be examined before a definite conclusion could be arrived at, or animal inoculations had to be made. He regarded the case as a very typical one. In similar cases studied some years ago and called colloid milium, he had found bacilli in the granulation tissue constituting the miliary tubercle.

Dr. Sherwell said that he recalled a case of his own exactly like this one. These cases he considered very recalcitrant to treatment, some would improve for a time only to relapse. He did not think the case under discussion was one of aberrant or fugitive lupus erythematosus, as in that case the ears were often involved in a few weeks.

Dr. Fordyce considered the failure to find tubercle bacilli in one examination of the case as of no importance in the diagnosis. He suggested animal inoculations as a means of diagnosis.

Dr. Mewborn suggested in regard to animal inoculations that a much quicker result could be obtained by inoculating the suspected tissue directly into the mammary glands of a guinea-pig that was nursing its young. This method, proposed by Nattan-Larrier, was suggested by the experiments of Nocard who showed with what rapidity an experimental inoculation of tuberculosis in the mammary gland of a cow progressed. After such an inoculation in the guinea-pig, if tubercle bacilli are present it is claimed that a nodule will form about the fifth day and tubercle bacilli may be found in the secreted milk from the fifth to the fourteenth day.

Dr. Fox (closing discussion) considered the case as clinically the exact counterpart of a case presented before the Society some years ago and which resembled cases reported as colloid milium.

A Case for Diagnosis. Presented by Dr. Jackson.

Mr. C. æt. 47. Lawyer. Married. No previous history of any importance, excepting sluggishness of liver. The patient was first seen by me January 20, 1903.

He stated that the disease, for the relief of which he came, began in June, 1901, and appeared suddenly. Apparently the area involved has not enlarged to any extent since the beginning. When I first saw him there was a round patch on the right side of his neck about thirty mm. in diameter. This was the original patch. On the left side of the neck there was a very small patch of same character as the larger one. The large patch had been under treatment by another physician, which doubtless influenced its appearance. When first seen it was of brownish red color, and scaly. It was not a continuous patch, but showed islands of sound skin in it. In about six weeks' time under expectant treatment the skin became smooth and of brown color.

In February, 1904, the patient called on me again because he thought that the frequent attacks of "sore mouth," from which he had been suffering, had some connection with his skin lesion, the latter growing more pronounced as the former became worse. Since he was last seen he had done nothing to the patch.

The patch is now broken up into a number of large and small islands of disease. The color is rather on the purple, like that of vascular nævus.

There are a number of papular elevations as component parts of the patch. These are flattened and shiny. The patient states that there is some itching. Four days after this the papules had disappeared and there were only a lot of small lesions that were not elevated.

Acne Rosacea, Showing the Effects of X-ray Treatment. Presented by Dr. A. D. Mewborn.

While by no means wishing to be considered an opponent of the use of the X-ray in certain cases, this case is presented as showing the results from using the high frequency current and the X-ray alone for several months in a case of acne rosacea, which very quickly yielded to simple scaling lotions and the opening of pustules by surgical methods. The patient is a woman, forty years of age, who has suffered from seborrhœa and acne of the face since puberty. Last August there developed a severe nodular and pustular condition of the chin, for which she consulted a physician, who began using a high frequency current three times a week. The condition not improving, treatment with the X-ray was begun three weeks ago. The exposures were made three times a week in ten-minute séances at a distance of ten inches. There was not only no improvement, but a great many more pustules developed with a burning, reddened condition of the central portion of the face, extending from just below the eyes to the chin. Upon first examination, Dec. 22, there was apparently a mild X-ray burn on the chin and lower lip, which, several days later, became raw and exuding. The pustules were all opened with a fine bistoury and peroxide of hydrogen injected into the cystic sinuses leading down from the corners of the mouth. Local applications of kresamin on cotton swabs were made to some of the pustules. Then, after the denuded surface on the chin had become covered with epidermis, a strong scaling solution of resorcin 10., sulphur 10., and tincture of green soap 40., was used for three successive evenings, during each week. Attention was, of course, paid to the digestive tract.

Dr. Elliot said that the case showed beautifully the result of the scaling treatment. In his clinic, at Cornell, he had since Oct., 1903, many cases of acne, lupus erythematosus, eczema, etc., treated by the X-ray in the hands of an expert, and, as yet, not one case had been benefited. A number of burns had, however, resulted.

Dr. Lustgarten thought that it was possible that some of the beneficial effect in Dr. Mewborn's case might have been due to the X-ray.

Dr. Mewborn (closing discussion) thought that the unbounded enthusiasm for the results obtained by the X-ray should not blind us to the equally good results obtained by simple and comparatively harmless methods. The surgical indication to let out pus in acne pustules was certainly much more logical than to try to cause their absorption by the X-ray. The X-ray was a powerful agent both for good and for evil, and should not be used in mild affections until milder agents had failed.

A Case of Lupus Erythematosus Treated by the High Frequency Current. Presented by Dr. Lustgarten.

The patient was a man, thirty-eight years of age, born in Austria. His trouble began two years ago, remained stationary and afterwards improved up to eight months ago, when it began to spread rapidly. At present the areas involved are the sides and bridge of the nose, the cheeks in disseminated patches, and the maxillary and submaxillary regions extending to the upper part of neck and both ears. The older lesions show the typical atrophic seborrhoic character, while the newer ones, especially on the neck and cheeks are of a more inflammatory type. The case is chiefly shown to demonstrate the effect of "molecular destruction" according to Strebel (*Deutsch. Med. Wchensch.*, 1904, No. 2), by the high frequency current. A plain glass electrode is used, connected with a d'Arsonval apparatus, which held at a distance of ⅛ inch will produce a marked cauterization in one half to one minute. The surface treated becomes covered with a serous exudate, and the resulting crust remains adherent for eight to ten days and leaves, after falling off, a healed up or considerably depressed surface. The treatment is somewhat painful. The treatment is carried out by Dr. Stern of the dispensary service and after a few sittings is rather encouraging.

Dr. Jackson said that he had used the high frequency current in the treatment of these cases. He had had two patients with multiple patches, some of which were promptly cured, while others remained uninfluenced. He considered that sparking alone was not sufficient. On the patches that were cured, the small glass tube was directly applied and kept in position for about three minutes with as much current force as the patient would endure with comfort. In this way the skin would blister and the patch would improve. He had found but little benefit in the chronic thickened patches with great destruction of tissue, but thought that in recent, superficial cases it was a most valuable curative agent.

Dr. Fox thought that a simple lotio alba as well as a number of other applications would improve these cases temporarily. As to permanent beneficial results he had seen nothing so simple, speedy and effective in its action as liquid air. He intended in his next case to treat one side of the face with the high frequency current and the other side with liquid air and show the comparative results before the Society.

Dr. Bulkley said his results in such cases had been most favorable with high frequency currents. The results were better in chronic than in acute cases. He pushed the treatment rather vigorously, using preferably carbon electrodes, taking care not to cause a burn. This treatment was excellent for removing warts of the scalp.

Dr. Allen believed the high frequency spark the treatment *par excellence* in the treatment of lupus erythematosus. It was decidedly superior to the X-ray. He had not employed exactly the method of Strebel,

and considered a one millimeter spark the equivalent of actual contact. He used the carbon point and found it was necessary to blister in many cases. He considered the high frequency current superior to liquid air both in regard to the result obtained and as to the absence of pain and swelling following shortly upon treatment. Subjectively it was preferable, and the patients remarked upon the improved feeling in the plaques.

Dr. SHERWELL said that he had seen a great many of these cases of lupus erythematosus treated by the X-ray, in the hands of a most competent man, too, and he had failed to see the slightest benefit.

A Case of Lepra. Presented by Dr. Fox.

This patient, aged thirty-five, was born in Mexico and has been under observation for about thirteen years. When first seen there were a few small nodules on the face and a slight swelling and numbness of the hands.

Under treatment lasting several years he became apparently well and remained so for over three years. Macules and nodules then appeared upon the extremities. He was unable to tolerate chaulmoogra oil in doses larger than five drops, and, becoming discouraged with the result, dropped this treatment. One physician used a high frequency current upon the facial nodules and another gave him large doses of arsenic. Following this a notable change for the worse has taken place and he is now anxious to resume the treatment by chaulmoogra oil.

(*Continued in the May number.*)

REVIEW
of
DERMATOLOGY AND SYPHILIS

Under the Charge of JOHN T. BOWEN, M. D.

BACTERIOLOGY AND PARASITOLOGY.

By A. D. MEWBORN, M.D., New York.

DERMATOMYCOSES.

1. Kerion (Gigantic). DANLOS. (*Ann. de Derm. et de Syph.*, 1903, p. 298.)
2. Caraté, or an Analogous Dermatomycosis of South American Origin. DARIER. (*Ann. de Derm. et de Syph.*, 1903, p. 327.)
3. A Note on the Case of Mycosis, Presented by Dr. Darier. BODIN. (*Ann. de Derm. et de Syph.*, 1903, p. 332.)
4. Note on the Case of Caraté, Presented by Dr. Darier. BARBE, (*Ann. de Derm. et de Syph.*, 1903, p. 414.)
5. Multiple Subcutaneous Abscess of Mycotic Origin, DE BEURMANN and RAMOND. (*Ann. de Derm. et de Syph.*, 1903, p. 678.)

6. Human Inoculations of Favus of the Mouse (Achorion Quinckeanum). Bodin. (*Ann. de Derm. et de Syph.*, 1903, p. 834.)
7. Note Upon the Parasite of "Black Tongue." Roger and Weil. (*Ann. de Derm. et de Syph.*, 1903, p. 838.)
8. Trichophytine. M. Truffi. (*Revue Prat. des Mal. Cut., Syph., et Ven.*, 1903, p. 342.)
9. Labiomycosis. W. Evans. (*Brit. Jour. of Derm.*, 1903, p. 319.)

It is often difficult to demonstrate microscopically the existence of the trichophyton, especially where pus is present; this was shown in a most extensive kerion involving the entire scalp in a case presented before the French Dermatological Society by Dr. Danlos. The disease began about three months previously on the top of the head in a young woman and, at the time of examination, the entire scalp, denuded of hair, was covered with numerous nodular lesions from which pus exuded and into which a probe could be passed to a depth of five to eight centimeters. In spite of the suppuration and the doughy condition of the scalp, there was no fever or enlargement of the cervical glands. Neither by culture nor microscopical examination was the author able to demonstrate the suspected fungus. In a subsequent report, after a most painstaking study of the case, Dr. Sabouraud was able to demonstrate in pure culture the causal trichophyton. After several months' treatment by various antiseptics such as oxygenated water, iodine, and potassium permanganate, the case recovered with permanent loss of hair. The history of this case demonstrates the value of cultural methods in suspected trichophytosis in cases where microscopical examinations fail.

The case of caraté presented by Dr. Darier was a most interesting one, on account of the extensive involvement of the cutaneous surface including the nails, the extreme abundance of the fungus, the chronicity of the affection, and its resistance to treatment. The skin of the entire body except the scalp and ears was uniformly red, slightly thickened and covered with scales which were thickest in the axillæ and inguinal regions. In the palmar and plantar regions these scales were six to eight millimeters thick and of a dirty grey color. The nails were striated and raised by thick horny layers of epidermis. The hairs were entirely free of the fungus. Bodin, who made a very careful laboratory study of this case, considered that the fungus much more closely resembled the *lophophyton gallinæ* described by Matruchot and Dassonville as the cause of favus of the cockscomb. In conclusion he considered that it was another one of the many cryptogamic parasites found in caraté. Dr. Sabouraud agreed with Dr. Darier in considering chrysarobin as the most efficient agent in the treatment of all these tropical dermatomycoses.

Barbe, in a short note, objected to the diagnosis of caraté in the case presented by Darier on account of the fact that in the description of all writers upon this disease, the nails were never affected and that there

were always pseudo-vitiligo patches which succeeded the melanodermic patches, and also from the absence of the typical aspergillus in the scales he considered the case to be that of a tropical trichophytosis.

The interesting case of de Beurmann and Ramond emphasizes even more the fact that in an abscess caused by a trichophyton it may be extremely difficult to demonstrate the parasite by a microscopical examination which in cultures may be shown in abundance. The patient was a wine merchant of thirty-seven years of age, who, for about a month, had noticed the development of about thirty-three small, fluctuating, painless subcutaneous tumors disseminated without order over the body. One of the tumors near the elbow was removed for study, but in doing the operation the sac containing a thick pus was ruptured. A month later there developed numerous tumors at the site of operation due to reinoculations. Several other tumors were removed and the purulent contents examined microscopically without revealing any parasite. A number of culture tubes containing glucose agar were inoculated and all gave growths of a fungus which Ramond carefully studied in Sabouraud's laboratory and, while not definitely classifying it, found in drop-cultures an interlaced mycelium and round and oval spores, some of which were elongated into club-like bodies. On glucose agar, in from eight to ten days, there developed rounded white colonies with elevated borders and depressed centers. All these cultures upon the different media used, showed a tendency, in becoming old, to change in color from white to coffee-colored and to become powdery. Inoculations upon guinea-pigs were unsuccessful. The disease was auto-inoculable as shown by the development of tumors at the site of stitch holes, where one tumor ruptured during removal. The patient recovered under large doses of iodide of potash (six grams in twenty-four hours).

Bodin gives a description of the fungus causing favus in mice. The same fungus he has found only twice in 250 cases of human favus. In one case, a young girl, there were four typical favus cups on the cheek. In the other case, a young woman, the lesion was a circinate, erythemato-squamous patch above the right eyebrow. There was no vestige of a favus cup, but a few disseminated small vesicles. Cultural methods enabled him to identify the same fungus in the two cases as the *Achorion quinckeanum.* Upon the strength of this he claims to be the first to recognize the possibility of the same fungus causing in one case favus and in the other ringworm. [This claim shows a strange disregard of the case published by the reviewer in the JOURNAL OF CUTANEOUS DISEASES, Jan. 1903, p. 11, and translated in full in the *Revue pratique des Maladies Cutanées, Syph. et Ven.,* 1903, p. 112, in which the same fungus, with a trichophyton-like growth, was demonstrated to have caused, in the same patient, favus of the scrotum and ringworm of the thigh. It is quite possible that the fungus found in the reviewer's case was the *Achorion quinckeanum,* however, be that as it may, what was demonstrated in the

same individual was that a fungus with trichophyton-like characteristics might produce distinctly different clinical pictures in different parts of the body. This observation is now confirmed by the observation of Bodin.—A. D. M.]

Roger and Weil confirm the finding of Lucet (*Archiv. de Parasit,* 1901), in a study of the fungus of "black tongue." This fungus, which Lucet called *Saccharomyces linguæ pilosæ,* is found as round and ovoid double contoured bodies, 4 μ to 6 μ in diameter and which take basic stains. In culture it forms filamentous discs. Although not able to produce the disease from cultures, this does not invalidate their claim, as Chantemesse failed to produce the disease from inoculating the black villi upon the tongue of a healthy individual. The growth is pathogenic for rabbits, causing nodular formations in the kidneys from which pure cultures could be obtained.

Truffi, in order to test the results obtained by Plato with a filtered liquid in which a trichophyton had grown for several months, selected several varieties of trichophytons, such as the rose-colored fungus from a case of sycosis with deep nodositics; the yellowish-white trichophyton of animal origin found in a case of fungating sycosis of the lip; the red-violet growth from a trichophytosis of the scalp, and the pleomorphic form of the microsporon of the dog. All of these cultures were kept for months at a temperature of 30° to 35° C. The culture liquid was then passed through sterile filter-paper or through a Chamberland filter. When this liquid was injected into individuals suffering from lupus, favus, or sycosis due to staphylococci, no reaction was noticed, but if in an individual suffering from an infection due to one of the suspected fungi and markedly so in the fungating type of sycosis, a severe general and local reaction took place varying in different cases from a slight elevation of temperature to a chill, headache, temperature of 39° to 40° C., defervescing with abundant sweating. At the site of injection there was produced, in some cases, a severe inflammatory reaction with development of phlyctenules. At the site of the suspected lesions, although the reaction was not as marked as that produced by the injections of tuberculine in lupus vulgaris, there was produced an infiltration in the tissues, redness and the formation of pustules (rare). In the ordinary small-spored ringworm of children there was no reaction except in one case which was under treatment with croton oil. In that case there was a slight elevation of temperature and a reaction at the site of injection and at the site of the lesions. In the kerion type of trichophytosis the reaction was not marked. The author thinks that the difference obtained in reaction from using the various cultures was not great, but that the red-violet culture, the variety producing the greatest number of cases in the Italian children, was productive of the most active trichophytine. The author does not agree with Plato as to the therapeutic value of trichophytine, but suggests that further experimentation is in order, in view of the results obtained

in cases of small-spored ringworm where a local reaction has been previously obtained by using croton oil. The curative effects of the trichophytine being slightest in just those cases which are most rebellious to treatment, its use is not advisable on account of the severe general reactions. As a ready means of diagnosis in deep-seated lesions, where a demonstration of the fungus is not so easy, he thinks trichophytine may be of value. As the toxine is soluble in alcohol a dried product may be obtained to be mixed with a small quantity of distilled water when ready for use.

Wilmott Evans describes a form of patchy eczema affecting the skin, but not the mucous membrane around the mouth in a young girl who had the habit of licking her lips. The patches were red and scaly and gave rise to burning sensations which explained the child's efforts to moisten them. A microscopical examination of the scales obtained from scraping the patch revealed a large amount of mycelium. Evans considers this case, and about twenty others observed since, as quite distinct from the "perlèche" of the French authors. While unable to obtain cultures of the fungus he considers it as much larger than the *Leptothrix buccalis*.

MALIGNANT NEW GROWTHS.

By Elizabeth C. Jagle, M.D., New York.

The Bradshaw Lecture on Cancer and Its Origin. Delivered at the Royal College of Surgeons on December 9, 1903. By Henry Morris, M.A., F.R.C.S. (*Brit. Med. Jour.*, Dec. 12, 1903.)

Mr. Morris accepts Dr. Alex. Katz's grouping of alleged cancer formation into endogenous and ectogenous. Under the latter he mentions:

(1) Trauma, chronic irritation and chronic inflammation.

(2) Micro-organisms.

He epitomizes the views of the various observers identified with the parasitic theory, but thinks this is on the wane, as other workers have shown the so-called parasites to be degeneration products, including a typical mitosis and phagocytosis, and the yeasts in cultures from malignant new growths, according to Foulerton and Price-Jones, may be contaminations from the air of the laboratory.

Of transmission by direct inoculation, as "conjugal cancer," for instance, he considers the formation due to chronic or repeated irritation. The tumor products of microbic infection are the so-called granulomata—results of a chronic inflammatory process—and the tumors caused by the same kind of a microbe are always structurally the same. In endothelioma, spindle-celled sarcoma and carcinoma, the metastases are histologically identical with those of the primary neoplasm, but in round-celled sarcoma, which more closely resembles chronic inflammatory processes,

we cannot be sure whether the cells are derived from those of the primary tumor or from the tissues in which the secondary growths occur. The author asks: How can we explain, on the microbic theory, the fact that a tumor of one type of cell will produce in another person a tumor of a different type; and says auto-inoculation is comparable to the recognized mode of regional and metastatic infection of carcinoma.

He believes the "tumor germ" theory put forth by Durante in 1874 and Cohnheim in 1877 more consistent than any other. The latter taught that these embryonic inclusions or tumor-germs are portions of the germinal layers which are not utilized and remain in a quiescent state until excited into activity by some cause or other at some indefinite period after birth. He claimed a tumor never had its origin directly or indirectly from mature tissue, while Durante thought the elements preserved their embryonic anatomical characters or acquired them again through weakening of their chemical and physiological activity. To explain the formation of new growths in scar tissue and in parts after injuries and operations, Cohnheim's theory is extended so as to include groups of cells which become isolated beyond their own natural boundaries by post-natal processes. As proof of the existence of these congenital matrices of embryonic cells, one need only recall the many instances of vestiges and fœtal rests found in the human body. The occurrence of matrices of embryonic tissue of post-natal origin finds explanation in the sequestration of unused cells or unspecialized connective tissue during healing after various injuries or in parts the seat of chronic inflammation. That a matrix may remain quiescent and then suddenly start into active growth is witnessed under the physiological stimulus occurring at puberty. Pathologically, the same suddenly aroused activity is seen in certain epithelial tumors, as dermoids, branchial cysts, and mammary adenomata. Under exciting causes he gives heredity, age, traumatism and chronic inflammation, none of which, however, will by itself produce cancer without the presence of a matrix.

Mr. Morris thinks the points in favor of the "tumor germ" theory are:

(1) It escapes equally the objections raised against the local and the constitutional theories of cancer.

(2) It enables us to understand the long intervals that elapse before a recurrence.

(3) It explains so-called recurrences after varying intervals in parts out of the line of direct lymphatic infection and accounts for the development in the same person of two malignant tumors of different blastdermic sources, either simultaneously or after removal of one.

(4) It affords a better explanation of the local extension of carcinoma.

The evidence in favor of the microbic theory he does not consider sufficient for acceptance and thinks research has been directed too exclusively to microbes and too little to cancer. He believes that attention should be given to other questions—embryological, morphological, chemi-

cal and functional—and that arterial changes should be studied more. The only profitable and possible way to carry on these investigations is, in his opinion, by an organized body with relays of workers and sufficient funds to provide for the uninterrupted pursuit of the inquirers.

The Parasitic Theory of Cancer. H. G. Plimmer, F.L.S. (*Brit. Med. Jour., Dec.* 12, 1903.)

The author says the parasitic theory is by no means extinct and considers the increase in the number of cases during the last few years out of all proportion to any known general cause except a parasite. Predilection for low-lying damp districts and so-called cancer houses point toward a parasitic origin and he cites Behla's observations in Luckau, where the western suburb was dry, sandy and elevated and free from cancer, while the disease seemed to follow the course of a ditch of stagnant water which encircled the central town and eastern suburb. Behla considered this ditch the source of infection, as many of the gardens were watered from it and many of the vegetables washed in it were eaten raw.

Plimmer questions whether the increased number of sufferers have chance embryonal vestiges or whether it is a chance traumatic influence or chronic inflammation. He thinks it accords better with experience that a parasite should be at the bottom of it all, which in some places and in some years finds more favorable conditions of existence. He recalls to mind the protective function of normal epithelium against external influences, organized agents and chemical poisons, and then supposes that a cell becomes infected by a parasite which produces a poison. The neighboring cells react by proliferating to prevent its further penetration into the tissues and the absorption of the poisons. The organism and the cells multiply and eventually the fixed tissue elements in the vicinity are destroyed. He attributes to the stroma a phagocytic reaction.

As to metastases, he thinks many cells become detached which do not grow, but if one contained a parasite, it would possess the necessary stimulus to division and multiplication.

Microscopically, the parasites are definite round bodies embedded in the cytoplasm of cancer cells or in the nucleus or free between cells, are 0.004 mm. to 0.04 mm. in diameter, contain a very small, more or less, central body surrounded by a very delicate substance, which again is surrounded by a capsule often with a double contour. He says they are not to be confounded with degenerative products, etc., as they are found in the active growing parts and not at all in the degenerated portions, and will not accept any one's opinion on the morphology of this or any other organism or tissue unless examined in the fresh state. They often occur in patches and many sections may have to be examined before a positive result is obtained.

He calls attention to the recent experiments with *mycetozoa,* of which the *Plasmodiophora Brassicæ* produced in animals new growths of con-

siderable size formed from connective tissue cells or from endothelium from the lymph spaces. Prepared and stained by the same methods, this organism presents an appearance indistinguishable from the cell inclusions.

Regarding the rôle that injury plays, he draws a parallel between tubercle, osteomyelitis and cancer, and says that weak and new tissue cells are more easily attacked. He considers uncleanliness a factor in that dirt affords a better nidus for a parasite. That inoculation from man to animal has not proved successful does not, in his judgment, militate against the contagiousness of cancer, as the organism may not be in the stage for transmitting the disease or it can exist in but one kind of cell. The origin, growth and differentiation of the cells of cancer, metastasis, cachexia and recurrence, according to the author, can only be explained on the parasitic theory, and he thinks that the only hopeful outlook rests on this ground, for Pasteur said that the mind of man should become lord over all infectious and parasitic diseases.

INFLAMMATIONS.

By H. P. Towle, M.D., Boston.

Psoriasis Vulgaris and Pemphigus Vulgaris. Neumann. (*Wien. Klin. Wchnschr.*, 1903, XVI, 657.)

Neumann demonstrated a patient with both diseases in combination. The patient was a man of fifty who, when admitted to his clinic one year before, presented numerous pigmentations and heaps of scales, partly discrete and partly grouped, also vesicles, sometimes arranged in a circle, whose contents quickly became turbid. No new vesicles developed while he was under observation and the scaling eruption disappeared. One month ago the patient returned to the clinic. No vesicles were present, but he had a typical psoriasis eruption over the extremities, body and face. Under tar treatment the eruption diminished. Between the individual spots were numerous sepia-brown, irregularly contoured pigmentations. In the course of the last few days there has arisen on the back in the scapular region, on the face and on both upper arms bullæ varying in size from a lentil to a ten kreutzer piece, whose contents were at first clear, but which became turbid in a short time and dried into dirty yellow crusts. On the periphery of most of the lesions the rim of the bulla was still visible. Upon removing the crusts the papillæ were found to be slightly elevated and hypertrophied. The crusts were confluent on the right side of the back forming a patch the size of a child's palm. No eruption was seen on the mucous membrane. The patient was treated before his first entrance to the clinic with large doses of iodide of potassium and baths. He stated that the eruption had existed for thirty years.

Urticaria Pigmentosa. Swoboda. (*Wien. Klin. Wchnschr.*, 1903, XVI, 803.)

Swoboda reports a case in a girl of five months. According to the history the disease has existed since the first week. The child was well developed and, except for this eruption, healthy. A few days after birth an eruption of red spots appeared which looked like flea bites. After two or three days they became brown. From this time up to the third month scaling was present, but since then the spots have not changed. Examination showed an eruption over the whole body of thickly crowded spots varying from a lentil to a bean in size. On some places the pigment spots were confluent. The chief seats of the eruption were the back, lower legs and the feet, including the soles. The face, palms and backs of the hands, i. e., the unprotected parts of the body, were less affected. The lesions are of a sepia brown. On pressure a yellowish-brown stain remained. The spots are in the upper layers, project slightly, feel homogeneous and have a smooth surface with light single scales. For several days there was no trace of an urticarial affection on the unclothed child who showed merely an uncommon tendency to cutis anserina. Lately, on several days, and since the family has lived in a flea infested house, there has been on several places, redness, itching and turgescence of the spots. This last symptom one can call out artificially at any time. If the skin be rubbed with a cloth anywhere the pigmented spots become surrounded by a white seam and change into projecting urticarial wheals while the skin lying between becomes intensely red. This turgescence lasts over an hour.

Parapsoriasis en Gouttes. DuCastel. (*Bull. Soc. Franc. de Derm. et Syph.*, Paris, 1903, XIV, 265.)

DuCastel reports a case of a female, age fifteen. Duration of disease, three years. The eruption was on the trunk and limbs and consisted of macular and papulo-squamous patches formed of flattened papules without noticeable infiltration. The color was redder after a bath. No itching. Scales fine and dry, central rather than peripheral and detached by the nail with difficulty. The papule does not bleed beneath nor present the smooth and shiny appearance common in psoriasis. The papules are scattered irregularly over trunk, chest, back, abdomen, shoulders, the limbs, upper and lower, and the neck. The papules are discrete. The evolution of the disease is slow. At times the eruption is more abundant than at others, but it never disappears completely and is very rebellious to treatment. He considers psoriasis, seborrhœa and syphilis in the differential diagnosis, but rejects them all.

OBITUARY.

DR. GEORGE THIN.

Dr. George Thin took his degree in surgery in Scotland in 1858, and two years afterwards that in medicine. After graduation he practiced medicine in Scotland, and then spent a number of years in China and became well versed in tropical medicine. Returning to London, while still continuing his interest in tropical medicine and making a great reputation in that branch, he turned his attention to dermatology, studying that branch of medicine both in London and on the Continent. He won for himself an enviable reputation as a dermatologist, and was one of the original members of the Dermatological Society of London. Poor health recently compelled him to give up active work. About a year ago he went to the Continent, and died in Nice on December 27th, 1903, of cardiac disease.

He was a zealous and untiring worker on the scientific side of medicine and did a great deal of investigation with the microscope. He first published "An Introduction to Practical Histology," it appeared in London in 1877. This was followed by: "Cancerous Affections of the Skin," London, 1886; "The Pathology and Treatment of Ringworm," London, 1887; "Leprosy," London, 1891, and "Psilosis or Sprue," London, 1887. His investigation of Paget's Disease of the Nipple was one of the most important investigations of that disease ever made. It appeared in the *British Medical Journal* in 1881. To him also we owe the discovery of bacterium fœtidum as a, if not the cause of bromidrosis. G. T. J.

ALFRED SANGSTER.

Alfred Sangster, the distinguished dermatologist of London, was born at Streatham on October 24th, 1845. In 1865 he began the study of medicine at Guy's Hospital, London, and subsequently studied at the Aberdeen University and Cambridge, taking his degree in arts in 1871, and in medicine in 1875. He was a member of the Royal College of Surgeons, and of the Royal College of Physicians, and was made a Fellow of the latter in 1885. He held a clinical clerkship at the Blackfriar's Hospital for Diseases of the Skin, and later was elected physician to the Department of the Skin at Charing Cross Hospital. Was one of the founders of the Dermatological Society of London. He contributed many valuable papers on dermatological topics to the Transactions of the Pathological and other medical societies of London, the medical press, and Quain's Dictionary of Medicine. He gave the name of "Urticaria pigmentosa" to that disease in a paper entitled "Anomalous Pigmented Rash," that was published in the Clinical Society Transactions of 1878. Of broad general culture, this greatly helped him to bear the poor health under which he labored since boyhood, a valvular lesion of the heart. To this malady he at last succumbed on December 9th, 1903. His widow, one son, and two daughters survive him. G. T. J.

BOOKS RECEIVED.

THE JOURNAL OF CUTANEOUS DISEASES *acknowledges the receipt of the following new publications. Reviews of those possessing special interest for the readers of the* JOURNAL OF CUTANEOUS DISEASES *will shortly appear.*

Pityriasis et Alopécies Pelliculaires, Vol. II. Maladies du Cuir Chevelu. By R. Sabouraud. (Masson et Cie, 120 Boul. St. Germain, Paris, 1904).

Studien über die Hereditäre Syphilis. II. Teil. Knochenerkrankungen und Bewegungsstörungen bei der Angeborenen Frühsyphilis. By Carl Hochsinger. Price 25 marks. (Franz Deuticke, Leipzig und Wien. 1904).

Les Lésions du Rein et des capsules surrénales. By L. Hoche and P. Briquel. (Masson et Cie, Paris, 1904).

A Compend of Pathology, General and Special. A Student's Manual in one volume. By A. E. Thayer. Second edition. (P. Blakiston's Son & Co., Philadelphia, 1903).

Social Diseases and Marriage—Social Prophylaxis. By Prince A. Morrow, (Lea Brothers & Co., Philadelphia and New York, 1904.)

Progressive Medicine, December, 1903, Vol. IV. (Lea Brothers & Co., Philadelphia and New York).

BOOK REVIEWS.

Practical Handbook of the Pathology of the Skin. An Introduction to the Histology, Pathology, and Bacteriology of the Skin, with special reference to Technique. 8vo, 408 pages, with eight colored and thirty-two black and white plates. By J. M. H. MACLEOD, M.A., M.D., M.R.C.P,. Assistant in the Dermatological Department, Charing Cross Hospital, etc., London. Philadelphia: P. Blakiston's Son & Co., 1903.

This is one of the most important dermatological publications of recent years. As indicated by the title, it is wholly devoted to the elucidation of the scientific part of the subject—the basic part, we believe, of future practical and therapeutic advances. There are two ways of writing about and teaching this subject; one by which the student or reader is left in a maze from which he can scarcely extricate himself, and from which he learns but little; the other—as well exemplified in Dr. Macleod's work—is that of the born teacher or writer, hard to describe but which in the simplest manner possible, and without seeming effort imparts the essential facts and details.

The preliminary chapters of this book are devoted to a consideration of the necessary apparatus, of the methods of examination of material in the fresh state, of the methods of preserving material for histological examination, staining and other practical points. The normal epidermis is then clearly described and pictured, and this is followed by a description of the pathological changes involving its various component parts, and the lesions or conditions resulting therefrom. The corium, hair-follicles, sebaceous glands, sweat glands, muscles, blood vessels, blood, lymphatics, nerve terminations, fat, pigment and nails are taken up in the same manner—first the normal histology and then the pathological changes. The various diseases met with and the pathological conditions found are touched upon, briefly but sufficiently for a clear understanding. The remaining several chapters are given up to a consideration of the organisms found in the skin tissues, the methods of examination and of preparing cultures, and a consideration of the various diseases in which they are believed to be pathogenic.

Another feature of the book which cannot be too highly commended is the

excellence of the illustrations, almost all of which are original. A word should be said also of the author's fairness to other writers, important contributions often being referred to and their value acknowledged. In fact, we are pleased with the work, and are convinced by a careful perusal that the author has touched upon all essential matters, and has given us a clear, understandable, helpful text-book on this part of the subject, which will be appreciated, not only by students in dermatology, but also gladly welcomed and often referred to by those of us who have been plodding along the dermatological road for some years.

H. W. S.

Social Diseases and Marriage, Social Prophylaxis. By Prince A. Morrow, A.M., M.D. (Lea Brothers & Co., New York and Philadelphia).

Though its title is somewhat irrelevant the subject matter of Dr. Morrow's book is of the highest importance. It concerns the relations of gonorrhœa and syphilis to the marriage relation. Social Diseases is the author's euphemism for this, just as Social Evil is an euphemism for prostitution. But under whatever name the matter is presented the subject is one of the deepest concern to humanity and never has it been more effectively set forth than in this book of Dr. Morrow's. It had a great theme to deal with and matter and manner both are meet with the occasion. The air of performing a conscientious duty everywhere pervades it, and throughout it is marked by a tone of dignity and seriousness. Its style is good, though it suggests in some respects the influence of French reading and some of the terms used are decidedly French. For example, when referring in connection with syphilis to what are commonly called lesions, manifestations, appearances and the like, the writer invariably uses the expression "accidents." By accident ordinarily in English we understand something that happens suddenly and unexpectedly—often a casualty. Rarely if ever before has it been used in the French sense of a symptom, nor is its advantage over the terms in common use very easily apparent. But of the writer's English we have little cause to complain. To say it is above the average of what unfortunately we are accustomed to in medical writings would indeed be too faint praise.

As to the matter of the book, as outlined in the author's preface, the object was "to set forth clearly the dangers introduced by venereal diseases into marriage—dangers to the wife, dangers to the offspring, and dangers which come from their morbid irradiations into family and social life—and to indicate the most effective means to prevent these dangers or to limit and circumscribe their spread."

The book is divided into three parts. The first considers the dangers of gonorrhœa in marriage and the means of curtailing them; the second is devoted to syphilis, and in the third, under what the writer calls Social Prophylaxis, the evils and their prevention are discussed from the more general standpoint of the public at large.

The part that will probably be found most useful and new to the majority of readers is that relating to gonorrhœa. With the subject of syphilis and marriage we had already been made familiar in the excellent work of Fournier, translated by Morrow into English over twenty years ago. The essential features of this are represented in the second part of the present work. While most of us are sufficiently alive to the dire consequences of syphilis, few are aware of the vastly more extended evils that may attend the infection with gonorrhœa. When in 1872 the late Dr. Noeggerath of this city first called the serious attention of the profession to the enormous prevalence of latent gonorrhœa in married women with all its attendant ills, his statements were received with astonishment not unmingled with distrust. But time and more extended information have tended

to fully confirm the gravity of his charges, and the case as now presented by Morrow with the testimony of all recent experience shows the picture even darker than it was drawn by Noeggerath. To many in the profession the evidence will be new and even startling, but it is time the gravity of the subject was realized and seen in its true light. There is still too much disposition to make light of a venereal urethritis in contrast to the awe always inspired by the terrors of syphilis. *"On craint le verole mais on rit de la chaudepisse."* But a subject that so seriously concerns the life or well being of the wife, the hope and happiness of the family, indeed, the perpetuation of the race, has no room for levity. A writer or a lecturer earnest and convincing, has no need of such diversion.

The well written part on Social Prophylaxis deals discreetly with the general mooted questions relating to the best mode of educating the laity in the matters concerned, to sanitation and to the advantages as well as the difficulties pertaining to state interference. While approving a law that would make "punishable with severe penalties," the crime of transmitting venereal disease in marriage, he recognizes the necessity of previous development of "a public sentiment which shall sanction and sustain such a law." At all events—to quote the writer's closing words—"upon humanitarian principles, in the interest of virtuous wives, who should no longer be poisoned with foul infection; in the interest of children, who should no longer be deprived of their rightful heritage of vitality and vigor; in the interest of the race, which should no longer be decimated and deteriorated, the dreadful curse of venereal disease should be lifted from the marriage relation." E. B. B.

Thigenol Roche

Contains 10% Soluble Organic Sulphur

Your first thought, when you read the statement that Thigenol Roche contains 10% soluble organic sulphur, may be "It's only another ichthyol." To meet that thought we'll immediately say "Yes: Thigenol Roche is like ichthyol in all its *applications*, but *not in physical properties*."

Thigenol is odorless on use; ichthyol has a nauseous, clinging smell. Thigenol is almost tasteless; ichthyol is repulsive. Thigenol discolorations on linen can be quickly removed; ichthyol stains linen badly. Thigenol contains 10% soluble sulphur organically combined; ichthyol contains only 8%.

Dr. A. E. Neumann, director of a Berlin sanitarium, writes in Deutsche Aerzte-Zeitung, No. 19, Oct. 1, 1903: "Thigenol has these advantages over ichthyol: its anodyne action is greater; it is odorless, and easily removed from linen. With me, Thigenol has completely replaced ichthyol."

YOUR DRUGGIST can easily procure Thigenol from Jobbing Druggists if he hasn't it when you first prescribe it.

LITERATURE AND FORMULARY ON REQUEST.

The FENWICK AGENCY
51-53 Maiden Lane, New York

THE JOURNAL OF
CUTANEOUS DISEASES
INCLUDING SYPHILIS

VOL. XXII. MAY, 1904. No. 5

REPORT OF A CASE OF BULLOUS LICHEN PLANUS.

("Lichen Planus Pemphigoides.")

By MARTIN F. ENGMAN, M.D., St. Louis.

FOR some years I have been watching for the occurrence of vesicular formation upon lichen planus lesions, for in several microscopical sections from rather acute types of the disease I have seen small collections of serum under the epidermis, which suggested to me that macroscopic vesicles could form without much additional serum attraction. One must admit, after a close study of the literature of lichen planus, especially that of the last few years, that the plane papule may undergo various secondary changes and that lichen planus is a disease whose lesions may therefore be of a polymorphic character.* The following case, which came under my observation the 2d of last November, beautifully illustrates the so-called "bullous" type of lichen planus:

C. M., a country merchant in a small town in Missouri, came, on Nov. 2d, 1903, to the Polyclinic, Medical Department of Washington University, and was referred to the Dermatological clinic for treatment. He was a robust, well built man, forty years of age, of dark complexion and of a healthy, vigorous appearance. His father had died of dropsy; his mother of diabetes; his brothers and sisters were all alive and in good health. The patient had always enjoyed good health, except in childhood, when he had had the usual run of infections: measles, scarlet fever, etc.

Two months before coming to the clinic the present disease appeared upon both arms. The only preceding or concomitant symptom, which he can remember, was a heavy, sleepy feeling, which had more or less disappeared. He had, however, attributed his disease to "catch-

*See statement by Kaposi—Dis. of the Skin. 1895. p. 329. (English Translation.)

ing cold," as his business had exposed him, at that time, to the chilling winds and rains of that season.

In one month the eruption upon his arms had spread over his body and had become general; therefore, it had occupied the position it presented upon his first consultation one month. The eruption was generally distributed from the neck to the soles of the feet, being disseminated over the body and extremities leaving the palms and soles free. It was of an acute character, giving to the skin a rather purplish color in a certain light. When inspected from a distance the skin showed only this peculiar coloring, but upon close inspection the color was seen to be due to the presence of lines and patches of small papules which were so slightly raised above the skin that they seemed to be formed by a deepening of the natural furrows. These small papules —or the initial lesion, the individual papule—were about the size of a lentil; were flattened and many of them presented a central depression, but no visible horny plug or concretion. They were angular in outline, slightly raised above the surface; were glazed and of a pale purple color. They occurred in lines or patches leaving narrow lanes or irregular shaped areas of normal skin. A few places upon the arms, thighs, and legs the papules had coalesced into plaques of a deeper purple than the individual lesions. These plaques ranged from a half inch to several inches in their long diameter and were perceptibly thickened and slightly scaly.

It was often difficult to make out the lesions in certain areas as they were so small and of almost normal color, but a good glass plainly showed their characteristic color, shape and outlines.

The above description is that of a typical lichen planus, which the case presented when the initial plane papule and the patches formed from it were observed; but, when the patient was placed a short distance away, just far enough to obliterate the papular eruption, no doubt the impression then gained, from this casual view, would be that the disease belonged to the pemphigus group, as the various sized clear bullæ, which were distributed over the extremities, would lead one to that impression. These bullæ were scattered irregularly over the arms, hands, thighs, legs and feet in isolated groups or singly. They sprang from single plane lesions; groups of isolated lesions or from patches, and, therefore, ranged in size from the smallest perceptible vesicle to bullæ larger than a silver dollar. They were generally of an angular outline or partly round, with, at one or two points of their circumference, an abrupt angular projection. The cover of these lesions was tough and surprisingly difficult to rupture or pene-

trate, yet the large tense ones had the translucency of a bulla with thin walls, easily ruptured.

Most of the bullæ were tense and filled with a perfectly clear serous fluid, but a few of them contained a thin sero-purulent fluid or were filled with a bloody exudate. This vesicular formation was irregularly symmetrical, but was more profuse upon the *left side*, the probable reason for which will be given later.

Upon the sides of the feet several large bullæ had occurred, the coverings of which had been partly detached by friction of the shoe, leaving raw, denuded surfaces, which had not become infected and were giving the patient little trouble. The eruption was intensely itchy, but beyond this no other discomfiture was suffered from it.

To obtain a further detailed history of the case the clinical notes taken at each visit will be given.

It remains here to be said that a capsule of the protiodide of mercury, ¼ of a grain, three times a day, was prescribed together with a two per cent menthol salve.

A small bulla was excised from the left forearm near the wrist, without anæsthesia, and put immediately into alcohol. Smears were made of the patient's blood, also from the serum of the bullæ. Culture tubes of various media were inoculated from the clear and sero-purulent vesicles and bullæ, with a sterile platinum loop and sterile glass pipette.

November 16. To-day the patient presents many new bullæ; several very large ones upon the thighs (see photograph). Patient upon indirect inquiry, states that the bullæ are caused by even slight irritation and says he can produce them at will by friction, as in scratching. He, to verify this statement, energetically rubbed a non-vesicular plaque upon the forearm for half a minute; in ten minutes after the friction had ceased a bulla the size of a dime had formed, filled with a clear fluid. The redness produced by the friction was slight, but was more intense in the center of the area; this point evolved, by the gradual raising of the epidermis, into a flat bulla; the reddened areola soon faded into the former color of the part.

The salve and capsules were continued. Excised from the arm a small group of normal plane papules, without anæsthesia and placed the section in alcohol.

December 1. The patient returns much improved: there is less itching and the lesions show a marked tendency to general involution. In some areas they have disappeared leaving dark pigmentation at their former site; others have flattened and are of darker color. Bullæ

are, however, still appearing, but, to a less extent. On the feet and between the toes, where the bullæ have been ruptured or the contents absorbed, the site has a deep brown, glazed appearance, as if some powerful reducing agent had been painted over that circumscribed spot. The pigmentation at the site of involuted bullæ is much deeper than where the normal patches or papules have existed. Continued salve and capsules as before.

December 15. The body is markedly pigmented, and apparently few new lesions have occurred. On the forearms are several scratch marks and a few clear bullæ, oval in shape with no areola. These new bullæ are no doubt on the site of lichen lesions, but it is exceedingly difficult to determine, when each bulla is examined, whether slight friction upon the normal skin in this patient would cause vesiculation. But from a careful observation it seems most probable that a lichen lesion is necessary to produce that result. As patient complained of some griping from capsules, ½ of a grain of pulv. opium was added to each capsule; the protiodid was increased to 1-3 of a grain.

December 21. Several new bullæ, hard, tense, irregular in shape, have occurred since the last visit. To convince myself of the origin of the bulla, friction was energetically applied to several normal areas without producing vesiculation, thereupon the patient, who is a very intelligent man and is interested in our experiments with him, volunteered the following statement: To produce a bulla, a local pruritus, but of an intense tingling character must *precede* the friction or any amount of rubbing will not be followed by vesiculation. To illustrate this fact, he energetically rubbed a small patch of papules with his thumb with no effect, except the usual expected erythema. He asked then to be allowed to await an ante-bullous pruritus. In the course of a few minutes he called my attention to a small plaque, upon which he produced a bulla by friction. During and between the time of the two experiments he had not left my presence. The patient further stated that these isolated attacks of a localized stinging pruritus were more frequent at night, when his scratching and rubbing, in his sleep and at other times, produced the numerous bullæ. He felt now that he knew exactly when and where he could, or could not, produce the acute serous discharge. The patient had been told at each preceding visit to study himself and find out all he could about his case, therefore, his interest was an echo of our enthusiasm. From careful questioning it seemed probable that *all* of the lesions would not answer to friction *alike*. Capsules and salve continued.

January 3. Disease rapidly disappearing. No new papules or

bullæ. Skin is slightly itchy. Has had no treatment for several days. Renewed capsules and salve.

February 2. Skin free from all papules and bullæ, only pigmentation mark their site. No itching. Feels well. Renewed capsules.

Physical examination of internal organs of the patient discovered no pathological condition. The urine was normal.

The blood smears showed a slight eosinophilia. No blood count was made. The smears from the bullæ with clear contents showed a few eosinophiles and polymorpho-nuclear leucocytes. The tubes inoculated from bullæ with clear serum remained sterile except one agar tube, which produced a long thin bacillus—a contamination. The tubes inoculated from the bullæ with sero-purulent fluid grew the staphylococcus pyogenes aureus, no doubt due to the secondary infection of the bulla contents.

Histological Examination. Both pieces of tissue from the arm, one the small bulla and the other the small group of isolated normal plane papules were fixed and hardened in alcohol, cut in celloidin and stained after the following methods: Pappenheim's pyronin; Weigert's elastic tissue stain; Delafield's hæmatoxylin eosin; Van Giessen; Unna's acid fuchsin and picric acid; Unna's polychromemethylene blue; Polychromemethylene blue and orange-tannin; Ehrlich-Gram gentian violet-iodine, and polychromemethylene blue and neutral örcein.

The Normal Plane Papules. The portion of the diseased area from which this section was excised presented macroscopically no vesiculation, being from about the middle half of the arm, and consisted of a group of several very small plane papules, angular in outline and of a brilliant burnish in a certain light. The biopsy was performed without anæsthesia. The skin was gently raised by grasping it (not pinching) between the thumb and forefinger of both hands, one on each side of the place to be excised. A long sharp, double edged knife with a thin blade was quickly passed under the papules and swept outward; the flap then grasped with a blunt forceps and cut off. This method insures the least violence and deformity to the section. Cocaine or freezing always change the resultant, histological picture. Not as much pain is experienced by this method, if done with proper dispatch, as when the tissue is anesthetized.

The first thing to strike one's attention in the sections of this piece of tissue is the amount of œdema in the cutis. The histologic

details are typically those of lichen planus: the infiltration of various cells in the derma, just under the epidermis (the papillary and subpapillary portion); slight infiltration about the vessels; flattening out of the papillæ of the derma; acanthosis of epidermis, especially forming acanthotic, blunt wedged-shaped plugs of epidermis which push down into the succulent derma; some inter-cellular œdema of the epidermis; firm, resistant hyperkeratotic horny layer, with circumscribed increase in the thickness at certain points, especially about the sweat pores.

The histologic picture of lichen planus is as characteristic as the clinical and, when a section presents the above mentioned characters, there can be no doubt in the diagnosis. The sections were therefore evidence of the correctness of the clinical diagnosis and differed in only two points from the usual histological appearance presented by lichen planus in general, as I carefully compared them with sections from, what might be called, normal cases. These two points or details could also account for the unusual bullous feature of the case. They are: (1) an unusual firmness and resistance of the epidermis as a whole. (2) an unusual amount of effusion in the cutis.

(1) The amount of œdema in the epidermis is comparatively slight, especially so when the second feature is considered. Although the prickles are stretched and the canals dilated, yet, the former are not ruptured as is so often seen. The nuclear spaces are not dilated and in no place is there degeneration of any sort in the epidermis. The cells retain the stains, or, their tinctorial characters, perfectly. It must be remembered that the papule was quite young and the epidermis had not probably had time to become markedly changed, as all the epidermic changes in lichen planus are secondary. Yet if we had not a firmer epidermis than is usually seen we would certainly expect to see more distortion from the amount of serum effused in the derma.

The horny layer, as Unna says, is always resistant and firm in lichen planus and exerts a pressure through this resistance over the subjacent tissues. Here the horny layer is thickened (hyperkeratotic) and forms a firm band as usual over the papule.

(2) The upper portion of the derma is quite œdematous. The collagenous bundles deep down, to the level of and below the sweat coils, are pushed apart by this effusion. The vessels at this level also show widening of the lymph spaces about them, with more infiltration than is usually seen. The inflammatory or infiltrating cells about the vessels here, are arranged in a similar manner to that seen in syphilis, in the perivascular lymph spaces, yet these infiltrating cells are not

plasma cells, nor do they present any of their tinctorial characters. The œdema about all the vessels has caused some change in their staining qualities, as they take the color faintly.

In the upper portion of the derma, little lakes of serum are frequent, the largest ones forming just under the firm epidermis. The collagenous tissue stains faintly, but correctly and no hyaline degeneration could be detected. But this soaking of the collagen renders it somewhat granular, in places; yet, it retains its proper tinctorial qualities, though weakly; as, in the most infiltrated and œdematous areas it gives a normal chemical reaction. The elastic tissue in this case of lichen is particularly interesting, and, I venture to assert it offers a probably third feature in the explanation of the bullous formation, namely: a degeneration of the elastic tissue similar to that of the collagen, which occurs in the part of the derma where the pathological changes are most active, just under the epidermis, in the papillary and subpapillary portion of the derma.

In the first place, the elastic tissue is swollen, the bundles and fibers are thickened and on a level with and just above the coil gland region takes the stain greedily. The band of wavy fretwork of elastic tissue which is normally situated just under the papillæ and sends fibers upward, is, in the inflammatory areas, just under the papules, pushed downward by the infiltration and thus pressed or massed into a heavy, thickened line looking not unlike a hedge fence. The fibers that ascend from this fretwork soon refuse to take the stain as deeply as they normally do and with a high power (1-12 oil imm.) can be seen as very faintly stained threads, to be finally lost to view in the infiltration. In most instances they can be followed further, in a well darkened field, as swollen threads, larger than the better stained portion, but so slightly and faintly stained as to be barely discernible. From studying these fibers with Weigert's or Unna's elastic tissue stain it seems to me probable that they lose their office, through some form of degeneration. The principal office of the elastic fibers is to lend strength and support to the derma and its various structures, and, one is led to believe, from their distribution, in the upper portion of the derma, that the fibers that disappear in the basal layer of the epidermis assist in holding the two structures, dermis and epidermis, together. If, then, these fibers become degenerated the epidermis is more easily detached, which occurs in those diseases where there is a diffuse infiltration accompanied by mild œdema just under the epidermis. The peculiar loosening or shrivelling of the epidermis in old lichen planus papules, described by Brocq and later by myself,

can also be explained by this degeneration or loss of function of the elastic fibers, thus allowing the epidermis to lie over the derma in a loosened, easily detachable manner. In these sections, where the bullæ have not yet formed, the elastic fibrils can be seen faintly stained and broken into short bands.

The pathological process in lichen planus is of a specific and characteristic nature, extending from the papillary and subpapillary regions downward and upward and therefore causing secondary but specific and characteristic changes in the epidermis. The vascular changes are also secondary; the vessel involvement is perivascular and particularly affects the small veins and extends progressively deeper, the first changes being noticed in the superficial vessels. If the vessels are carefully studied with a good elastic stain, one is struck with the similarity to those vascular changes seen in syphilis, with the absence of the tinctorially characteristic plasma cells. The lymphatic vessels are dilated and in the sections under discussion proliferation of their lining cells is frequently seen.

The source and nature of the small round cell, so characteristic of lichen infiltration, is still unsolved. For one to enter into the plasma-connective-lymphocyte-cell discussion, now waging, would certainly be a rash step.

The Bullous Lesion. The lesion taken for this section was filled with a clear fluid and had existed probably 36 hours. It was ¼ inch in diameter, round and slightly flattened. The excision was performed without anæsthesia, in the manner above described. The piece was fixed and hardened in alcohol, cut in celloidin and stained by the methods above mentioned.

The bulla is formed by the lifting of the whole thickness of the epidermis. The cavity is partially filled with coagulated albumen, fibrin threads, in the meshes of which are many polymorphonuclear leucocytes, large mono-nuclear leucocytes, small round lichen cells(?) and a few eosinophile cells. No cell debris or naked nuclei were found. The horny layer is thickened and firm. The basal cells are flattened out into long thin lamellæ, their long diameters running parallel to the surface. The intervening cells are pressed into various shapes. Clinging to the under surface of the epidermis, or covering of the bulla, are here and there small bits of the derma, with the infiltrating cells; all the elements staining characteristically, but weakly, except the elastic fibrils, of which no trace can be found. At the sides of the bulla, the tissues of the derma are violently torn, by the sudden lifting of the firmer and more resistant epidermis. The collagen

is stained normally but faintly. The elastic tissue shows the same reaction as that described in the normal papule.

The floor of the bulla consists of faintly stained ragged collagen bundles and the cells always found in lichen planus, with the addition of numerous trifold leucocytes, large mononuclear cells and a few eosinophiles. No red blood cells are evident. Non-hematogenous pigment occurs in clumps, not in cells, throughout the upper portion of the floor. The sections of the bullous lesion do not differ in their histologic details from those of the plane papule, except in the amount of œdema. The epidermis, from the pathologic changes wrought by the lichen process, was rendered more easily detachable from the derma, therefore an additional irritation caused a sudden attraction of serum from the vessels, with the subsequent lifting of the epidermis, and, the formation of a bulla.

No microörganism could be found in the bulla or plane lesion.

From the study of this case I am forced to believe that friction or some other irritation was necessary to cause the formation of the vesicles or bullæ. A certain amount of serous exudate is part of the process in all lichen planus lesions, but there is rarely enough to cause vesiculation without additional injury. Whitfield tabulates eighteen cases and asserts, from his study of the literature, that the majority of these appeared *before* the administration of arsenic. Colcott Fox was the one, I believe, to suggest that, possibly, arsenic might be the exciting cause of the bullous formation.

The present case had had no arsenic and none was given him through the course of the disease. In the majority of the cases of "lichen planus pemphigoides" the bullæ have formed in the early and acute stages of the malady. Hans Hebra's case was unique in that they occurred in the regressive stage of the process.

It must be admitted, from the discussion of Allen's paper upon "Lichen Planus as a Vesicular and Bullous Affection" by the American Dermatological Association that vesiculation in lichen planus is extremely rare in this country, as none of the members present, except G. H. Fox and Allen had seen a case. It is surprising to then turn to the discussion of Crocker's paper upon "Lichen Planus: Its Variations, Relations and Limitations," by the members of the Dermatological Society of London, to find that eight of the members present had seen one or more cases.

From the study of the reported cases and that of his own case it seems to the writer that bullous formation in lichen planus is not part of the pathological process of the disease *per se*, but that it may

form in certain cases upon additional injury to the tissues through friction or accidental violence. The relative pathological condition of the epidermis and derma renders bullous formation a natural result of injury or violence, in those cases in which there is: (1) an unusual tendency to œdema; (2) a very firm and non-œdematous epidermis; (3) certain degenerative changes in the superficial elastic fibrils.

REFERENCES.

Allen—*Jour. Cut. and G.-U. Dis.*, 1902, p. 260.

Bettman—*Derm. Zeitsch.*, 1901, t. VIII., p. 1.

Brocq—*La Pratique Derm.*, Vol. III., p. 223.

Crocker—*Brit. Jour. Derm.*, 1900, p. 428—Diseases of the Skin, 1903, p. 434.

Discussion Amer. Derm. Ass. (*Jour. Cut. and G.-U. Dis.*, 1901, p. 475.)

Engman—*Jour. Cut. and G.-U. Dis.*, May, 1901.

Fox (G. H.)—*Jour. Cut. and G.-U. Dis.*, 1901, p. 395.

Fox (Colcott)—*Brit. Jour. Derm.*, 1895, p. 22; 1900, p. 445.

Hallopeau and Le Sourd—*Ann. de Derm. et de Syph.*, 1899, p. 379.

Hebra, H.—*Monatsh. f. prakt. Derm.*, Vol. X., p. 113.

Joseph—*Arch. f. Derm. u. Syph.*, L. XXXVIII., p. 3.

Kaposi—*Arch. f. Derm. u. Syph.*, 1892, p. 340—Dis. of the Skin, 1895, p. 330. (English.)

Leredde—*Ann. de Derm. et de Syph.*, 1895, p. 637.

Möller—*Monatsh. f. prakt. Derm.*, Vol. XVII., p. 156.

Makenzie—*Brit. Jour. Derm.*, 1899, p. 26.

Neuberger—*IV. Deutsch. Derm. Gesellschft.*

Pinkus—*Arch. f. Derm. u. Syph.*, 1902, p. 163.

Pringle—*Brit. Jour. Derm.*, 1900, p. 440.

Róna—*Monatsh. f. prakt. Derm.*, Vol. VI., p. 879, Vol. VII., p. 831, Vol. VIII., p. 245.

Sequeira—*Brit. Jour. Derm.*, 1900, p. 439.

Taylor—*Brit. Jour. Derm.*, 1900, p. 445.

Unna—*Med. Bulletin*, 1885, p. 145—Histopathology (English), pp. 307 and 308.

Whitfield—*Brit. Jour. Derm.*, 1902, p. 161.

DESCRIPTION OF PLATES.

PLATE XXIV.—Photograph of Case.

PLATE XXV.

Fig. 1. Section through a bullous lichen papule. (a). Bulla cavity almost filled with coagulated albumen, fibrin, leucocytes and cell detritus. (b) Epidermis, marked at places where hyperkeratotic plug is situated about mouth of sweat duct. (c) Hair follicle. (e) Lichen infiltration. (d) Sebaceous gland. Section stained with alum-carmine and Weigert's elastic tissue stain.

Fig. 2. (a). Normal plane papule. (b). Acanthotic epidermis with lichen infiltration under it and hyperkeratotic horny layer above it. (c). Microscopic vesicle under the epidermis with clear spaces from effusion near it. Section was stained with alum-carmine and Weigert's elastic tissue stain.

PLATE XXV.—To Illustrate Dr. Martin F. Engman's Article.

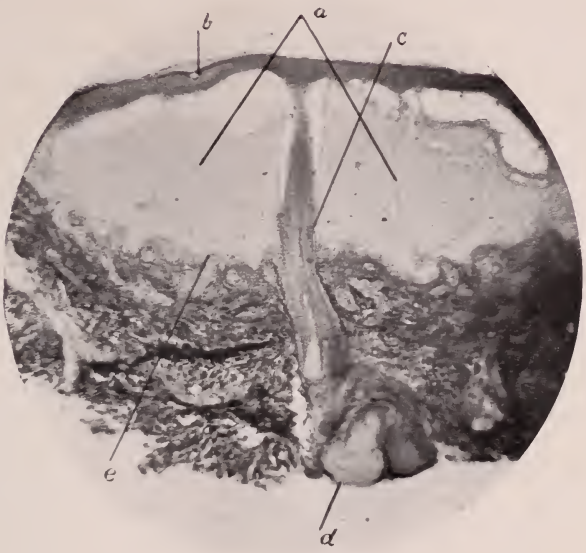

Fig. 1.

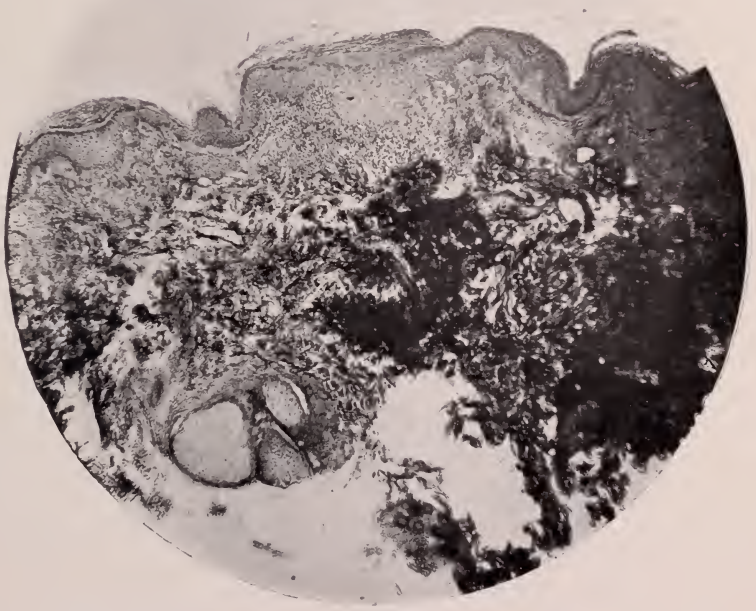

Fig. 2.

PLATE XXIV.—To Illustrate Dr. Martin F. Engman's Article.

A Case of Bullous Lichen Planus.

CREEPING ERUPTION: ITS RELATION TO MYIASIS.

By Louis P. Hamburger, M.D.,

Instructor in Medicine, The Johns Hopkins Medical School, Baltimore, Md.

Read at a Section Meeting of the Medical and Chirurgical Faculty of Maryland, October 16, 1903.

IN the *American Journal of the Medical Sciences* for September, 1902, Dr. Van Harlingen reported a series of cases illustrating a cutaneous affection, hitherto unrecorded in this country. He described them under the title of "Creeping Larvæ in the Human Skin," although he was unable to find a larva and did not refer to any successful attempts to discover the efficient cause.

During the month following this publication, I had the opportunity of observing a similar case.

The patient was an imbecile boy aged four years. The history of the eruption could not be obtained but an opportunity was afforded to study it while he was confined to the Union Protestant Infirmary. At the time of the examination, October 26, 1902, the following note was made.

A serpiginous line of eruption is situated on the right buttock about its central portion and traverses eleven centimeters, measuring the shortest distance between its two extremities. Its direction is approximately vertical, diverging slightly outward from below up. Starting from a point near the gluteal fold, the line runs toward the middle line, then up, then out and up, then upward towards the median line, then once again passing outward and upward, and ending in a hook-like process.

The "line" is about two millimeters in width, though its breadth varies a little at different points. It is in its upper half pale red, slightly raised, and is surmounted by a line of vesicular formation. At the extreme upper end the vesicular line makes several loops on its red base and a clear serous fluid oozes from it.

The lower half of the lesion, evidently the older, is represented by a curling line of purplish brown pigmentation. Some delicate crusts overlie this region, evidently representing the remnants of a former vesicular line.

As the skin is exposed, the child makes attempts to scratch the eruption. In the past twenty-four hours the line has traversed a distance measuring six and one-half centimeters.

October 28, 1902. The line has made an advance of only four or five millimeters since day before yesterday. Under Schleich's anesthesia, a small piece of skin is removed. The little piece of skin excised was examined microscopically and aside from evidences of an acute inflammation, nothing noteworthy was discovered. No parasite could be found in the sections. The subsequent history is brief. Following this little operation, the line faded and made no further advance according to letters received from the mother.

The history of this disorder dates from a communication made to the Clinical Society of London in 1874 by Dr. R. J. Lee under the title of "A Case of Creeping Eruption." It concerned a child three years old. A pale rose-pink line about one-sixth to one-eighth of an inch in breadth had extended in three weeks from its right ankle up the leg and thigh to the abdomen, meanwhile fading below.

Lee had the opportunity of observing its growth for almost two months. During this period, it migrated in a most bizarre fashion, traveling at a varying rate of speed, at one time traversing a distance of as much as four and one-half inches in twenty-four hours. Thus, it passed across the abdomen to the right side of the back, looping on itself several times. It ascended as high as the interscapular region only to return, recross the abdomen and pass up the left side of the back. Here the region of the lower dorsal vertebræ was traversed and the abdomen again reached and crossed and the spine once more attained and once more crossed, the line now being below the right nipple. Finally the back was again traversed and a point a little external to the nipple was reached.

At this end, a piece of skin was excised and there was no further growth, the rest of the line fading.

The eruption excited so much interest that a committee, composed of W. Howship Dickinson, Tilbury Fox and Dyce Duckworth undertook the microscopic investigation but its results were negative.

Lee reported a second case in 1884 and suggested that the linear eruption was due to an "active parasite or animalcule."

Crocker's text-book on "Diseases of the Skin" contains the only other detailed contribution to the English literature. Here, an instance of the affection under consideration is described as "larva migrans" but the hypothetical larva eluded capture.

It is also stated that Mr. Malcolm Morris has observed two cases of the disorder.

At the German Dermatological Congress in 1895, Neumann

showed a model representing "A new skin affection," which he viewed as of a nature similar to the Creeping Eruption of Lee. In the discussion following Neumann's communication, Dr. Petersen drew attention for the first time to some noteworthy Russian observations on what was presumably the same affection.

These Russian observations are contained in successive volumes of *Vratch*, dating from 1895, and their publication resulted from a letter addressed to the medical profession by Dr. Samson making inquiry concerning a skin affection which he had noticed in Southern Russia during the preceding two years and especially in the autumnal season. It consisted, according to his description, in a peculiar, serpentine, elevated, red line, its progress suggesting the creeping of a parasite under the skin. On using a magnifying glass, a black point could be detected in the unaffected skin about one-half centimeter from the actively growing end. After excision, it proved to be a motile parasite resembling the larva of a fly. This discovery is the first recorded contribution to a knowledge of the cause of the disease. It was not the first time, however, that the parasite had been obtained. Sokolow, like many of the provincial physicians, had been acquainted with the affection for many years. As early as 1888, he had extricated a little "worm" from the end of the line. In his paper published in answer to the request of Samson, the resemblance of the parasite to the larva of a fly is noted.

According to his account, it measures one millimeter in length and has ten segments. It is provided with hooklets, better developed at the head end, which apparently possesses also two suckers. At the tail end are two club-like processes. In the interior, two tubes are visible. Black nits, larger than those of the pediculus capitis, could be found adherent to the hairs in the neighborhood of the burrow or line.

The editor of *Vratch* submitted a specimen of this parasite from Sokolow's patient to Professor Cholodkowsky and an entomologist and according to their determination, it proved to be the larva of a bot fly or *Oestrus*, of the genus *Gasterophilus*, probably of the species hemorrhoidalis or pecorum, since they alone possess the black nits to which Sokolow refers.

In 1898, Kaposi demonstrated the eruption for the first time in Austria, designating it as "Hyponomoderma," a "skin passage" or tunnel, but he failed to discover the active agent.

It is astonishing that none but the Russian cases of Creeping Eruption have furnished parasites of a dipterous nature, although

independent and futile search for the cause has been made in other lands.

The clinical manifestations of the eruption, however, have so coincided that for the present it is justifiable to assume that the Russian disease with an established etiology and the Creeping Eruption of Lee, as exemplified by my patient, the Larva Migrans of Crocker and the Hyponomoderma of Kaposi, are caused by closely allied, if not identical, parasites. Yet, instead of adopting Kumberg's term and designating the process "*Dermamyiasis linearis migrans œstrosa,*" I have retained Lee's name of Creeping Eruption, until the parasite is discovered in countries other than Russia.

The disorder is particularly prone to affect children, although in Russia young peasants working in the field furnish most of the patients. It makes its appearance on portions of the body usually uncovered, yet, the buttock is a favorite site for its development. Thus of eleven cases, including the present one, observed in other countries than Russia, eight occurred in children and in five of the eleven the starting point was in the neighborhood of the nates. Samson also quotes the case of a Russian child who presented the eruption in the sacral region.

According to Sokolow, it first manifests itself as a small fissure or tear, but this lesion is not described by others. One of Van Harlingen's patients described the starting point as an "itchy pimple"; another, as a "water blister." In whatever way initiated, the subsequent course is very characteristic. A slightly raised pale red band, conveniently referred to as a "line," measuring one to four millimeters in width, winds its way in an irregular serpiginous manner across the body surface. In my case this line was capped by a vesicular formation suggesting the burrow of the itch mite. Such a vescicle is mentioned by several observers. In one of Samson's collected cases (that of Dr. Bruno) little irregularities along the track of the line were interpreted as points of defecation, thus heightening the resemblance to the lesion of scabies. It is this same beaded character that Lee refers to and likens to the appearance of a lymph canal.

The development of the line takes place with varying rapidity, now curving and looping, now adopting a straight course and traversing in a day from one to seventeen centimeters of the body surface. It does not branch. To this statement there is an exception in Olissow's case, but here the branch appeared after the treatment

was instituted to thwart the progress of the parasite along its original course. It may remain passive for hours and even days and then resume its march. As the red line proceeds, the older portion fades, leaving a pigmented track behind. Sokolow refers to the occurrence in brunettes of a white scar representing the healed area. Schmid is the only other observer who mentions a resulting cicatrix. Unlike other dipterous infections, a destructive or purulent inflammation never results. Pruritus at the actively growing end is a marked feature, so that the individuals attacked can localize the site of the larva by the point of itching. The territory involved in the migration may be very extensive, a fact illustrated by the description which I have given of Lee's first case. Bruno, too, has seen the parasite make a wide excursion. Thus, amid much restlessness on the part of the child affected, the line traveled in five days from the sacral region over the groin, to the inner aspect of the right thigh, from here to the chest, returning then to the back. On the other hand, in Matchinsky's patient, the gyrations of the œstrus larva were confined to a limited area inasmuch as it moved over one cheek for a period of two months. As to the duration of the affection, Kumberg concludes that it varies from a few days to five weeks, but this estimate does not agree with the facts in several of the recorded cases. In Crocker's patient, the larva moved about for two and a quarter years and only then did it come to an end through an accidental suppuration in the neighborhood of the linear eruption.

The diagnosis of Creeping Eruption is easily made from the cutaneous lesion. Its serpentine course and mode of progress immediately suggest the creeping of a parasite, while the absence of suppuration distinguishes it from other forms of dipterous infections. The detection of the larva in all but the Russian cases is still to be desired. Even some of the Russians have failed to find it. It must be sought with a magnifying glass not only at the active end of the creeping line, but, as has already been mentioned, a little beyond in skin apparently unaffected.

The treatment is obvious. With the excision of a piece of skin, including the larva, the cutaneous manifestation ceases, the red line fades and as only a single larva in each case has ever been found, the affection comes to an end.

The parasite accused of causing the Creeping Eruption, at least in Russia, is the larva of a dipterous insect belonging to the family of the *Œstridæ*, the bot flies, the species not being as yet definitely

determined. Of the *Œstridæ*, about sixty species are known, of which twenty-four are said to be found in North America. Their larvæ are practically all parasitic on mammals, each usually limiting its parasitism to one particular animal. Thus, the *Œstrus ovis* is the sheep bot fly, the *Œstrus* or *Gasterophilus equi* has the horse for its host, the *Œstrus* (hypoderma) *bovis*, the ox, and so on.

The life history of these insects is exemplified by *Gasterophilus equi*. This bot fly lays its eggs in the latter part of the summer on the hairs of the horse where they adhere in much the same manner as the nits of the pediculus until they, through the friction and moisture afforded by the horse's licking, are hatched and the resulting larvæ transferred to the animal's stomach. An explanation is that the larvæ crawling over the skin are a source of irritation sufficient to cause the horse to attempt to remove them by licking. On the other hand, it has been suggested in view of finding the Gasterophilus larva in the tract of Creeping Eruption that a similar condition may exist in the horse's skin. In other words, the assumption would be that the larvæ do not crawl over the skin, but in the skin and their removal is affected by biting rather than by licking. Such an eruption could be readily hidden by the horse's hair and it would be interesting if such a lesion were discovered.

In whatever manner this small detail may be settled, the larvæ find their way into the horse's stomach where they attach themselves in varying numbers to the mucous membranes, and there they remain through the winter season. The next summer they loosen their hold, pass through the intestine, and, burrowing into the ground, they undergo the further metamorphosis into a pupa from which the imago or adult bot fly emerges in a few weeks. It is thought that the larva in the Russian examples of Creeping Eruption is the *Gasterophilus hemorrhoidalis*. This species of *Œstrus* deposits its eggs on the lips and nose of the horse and its larvæ attach themselves to the bowel as well as about the anus, with great annoyance to the animal.

Just as the Gasterophilus larva inhabits the stomach and the intestinal canal, so other genera of the bot flies invade other cavities, the frontal and nasal sinuses and the œsophageal cavity. The subcutaneous tissue, however, is the favorite point of lodgment.

There is at present no evidence of the existence of an *Œstrus hominis*, but there has accumulated a collection of curious and remarkable facts relating to the accidental invasion of the larvæ of this family and of other dipterous insects, a state of pseudoparasit-

ism to which the term "myiasis" is applied.* An internal myiasis and an external myiasis are distinguished. The former has a general medical interest and is applicable to the condition caused by the presence of dipterous larvæ in one or other of the cavities of the body.

The eggs or at times the larvæ are swallowed with food or their mode of entrance may be undetected. The insects are subsequently vomited without necessarily causing any serious symptoms or an obscure febrile disorder with delirium and gastric disturbance precedes their evacuation. Again, the eggs or the larvæ so organized as to withstand the action of the gastric juices pass on into the bowel from which they are removed in the feces and by chance discovered in the stool. However, they may cause serious intestinal ulceration manifesting itself by a dysenteric disease which proved fatal to a patient of Schlesinger.

In gastro-intestinal myiasis the families *Sarcophagidæ*, the flesh flies, the *Anthomyidæ*, the larvæ of some of which feed on garden vegetables, the ordinary *Musca domestica*, and a privy fly, *Homalynia scalaris* are among the offending agents.

The nose, ears and conjunctivæ may harbor these pests. Almost always the seat of previous disease, the larvæ add materially to the gravity of the affection in these regions. Frantzius of Costa Rica, has described in detail the symptomatology of this complication in inhabitants of the tropics who suffer from ozæna. Attracted by the odor of the discharge, the blue bottle fly, *Musca* or *Calliphora vomitaria* or *erythrocephalia*, lays its eggs in the nostrils, the resulting larvæ causing widespread destruction to the nasal mucous membrane with severe constitutional symptoms leading to death in the case of one old patient.

As a medical curiosity the instance of myiasis of the urethra reported by D'Hænens may be mentioned. Five or six days after injecting some water into the urethra the patient experienced some discomfort in the canal and difficulty in micturition. The following day he voided a larva of *Musca domestica*. It was assumed that a fly had deposited its eggs on the tip of the syringe and that at least one of them had passed into the urethra in practising the injection. Finally, it is said that even the vagina is not spared in these dipterous infections.

---

*The term "myiasis" was introduced by H. Summa in a series of articles which were collected in pamphlet form and published in St. Louis, Mo., U. S. A., in 1889 with the title "The Pseudoparasitism of Diptera in Man or Myiasis." Summa considered myiasis as etymologically the correct form.

There is no substantial evidence that the *Œstridæ* play any part in internal myiasis. Kirschmann cites the history of a patient whose nostrils were invaded by the larvæ of the *Œstrus ovis*, the sheep bot fly, but subsequently his observation suffered criticism and it now seems more likely that he was dealing with a flesh fly, one of the *Sarcophagidæ* and not an *Œstrus*.

In external myiasis or myiasis dermatosa, a phase of the subject which is of particular interest in connection with Creeping Eruption, the *Œstridæ* are of more importance. In fact, Gustav Joseph classifies cutaneous myiasis into "myiasis dermatosa muscosa" and "myiasis dermatosa œstrosa," according as the *Muscidæ* or the *Œstridæ* are responsible for the affection. Dubreuilh has reviewed cutaneous myiasis from another standpoint, namely, from a geographical point of view. Limiting a detailed consideration of the attacks of dipterous larvæ on previously healthy skin he makes only passing comment on the infection of open wounds, a condition in which a fly attracted perhaps by the fetid odor of a discharging surface, lays its eggs there amid circumstances favorable to the development of its numerous larvæ. The larvæ of the blue bottle fly, *Calliphora vomitoria*, and of the flesh fly, *Sarcophila Wohlfarti*, and the screw worm, the larva of *Lucilia macellaria* are in this way the causes for the establishment of a "living" wound. The two last named may excite a most destructive inflammation with abundant suppuration and even gangrene. M. Dubreuilh considers that each clinical or zoological type of true cutaneous myiasis corresponds to a geographical territory and on this basis he has studied the literature bearing on the cutaneous diptera of Africa, Tropical America, Central and Northern Europe.

There is a certain similarity in the lesions, the description of which he has collected. The African Cayor worm, the larva of *Ochromya antropophaga* (Blanchard) with zoological characteristics of the *muscidæ* produces single or multiple furuncle-like tumors on the posterior aspect of the trunk or on the lower limbs and from these little tumors the larvæ, four to five millimeters long, emerge with a little pus. Similarly, the parasite known in Guiana and in the Antilles as "ver macaque" causes lesions resembling boils pierced at their summits by apertures through which the "worm," the larva of *Dermatobia noxialis* is extruded. Matas has pictured one of three such *Dermatobia* larvæ which he extracted from a man who was infected in Spanish Honduras.

The observations published from Central Europe relate chiefly to

the *Œstridæ* and here again the lesions bear a resemblance to furuncles. In this group is included Joseph's case in which the zoological evidence of the œstridean character of the larva, that of *Hypoderma Diana* is complete, adult bot flies having emerged from the pupæ.

The facts reported from Northern Europe relate supposedly to *Hypoderma bovis* although the zoological evidence is not complete. One type is represented by a disorder in Norway occurring chiefly in children and consisting of a series of furuncular tumors appearing consecutively and separated from each other by a distance of three to five inches. The final one gives issue to a larva after the disorder has lasted three and a half weeks. Fever accompanies the affection. The larva resembles the larva of a fly but the species has not been determined. The successive development of a series of tumors is explained by the progress of the parasite under the skin.

This cutaneous myiasis is closely allied to the oft quoted case of Smith in which the progress of a tumor could be clearly and continuously followed. A girl, aged twelve years, a patient of Dr. Whittaker of Valentia, Ireland, has been for two or three months the subject of a slightly painful tumor about the size of a pigeon egg which had traveled from the right foot up the leg and trunk to the right axilla. From here it proceeded to the breast on this side and finally reached the corresponding side of the neck. At this point the tumor discharged some semi-purulent fluid together with a larva. Later three other larvæ producing practically the same sort of lesions were recovered. The largest of these grubs measured nine millimeters in length and were two millimeters wide. The identity of the insect was not established but it was considered a dipterous larva.

A somewhat similar disorder is recorded by McCalman. The subject was a girl of nine years who suffered from a painful swelling of the left elbow. In the course of a week, the swelling diminished but now the forearm became affected. The swelling progressed to the arm where a vesicle formed and from it the larva of a dipterous insect was extruded on the twenty-third day. Three days later a bluish serpiginous track could be detected running from the middle of the forearm to the point from which the larva made its exit. This sinuous line recalls the characteristic feature of Creeping Eruption and to the latter it forms a transition from the more common varieties of cutaneous myiasis.

The transition is further accentuated by a series of cases reported from the Shetland Islands. In these, as in Creeping Eruption, the line is the essential feature. Most often observed from September

to April, the affection attacks young women who during the previous summer have been working with peat where cattle were numerous. It is the head and trunk that are especially involved. The lesions consist of a red or ecchymotic line which travels over the body at a varying rate, fading in its older portion and accompanied by a burning pain in the active end. The location of the parasite is sometimes marked by a little projection. When the larva is about to emerge, the swelling becomes more pronounced and stationary, a small opening is formed from which a little pus and serous fluid together with the "worm" exude. The larva, three-quarters inch in length, corresponds, according to Spence, to that of the ox bot fly, the *Hypoderma bovis*. The Shetland affection suggests Creeping Eruption but the disparity in the sizes of the parasites, judging from the Russian cases, is very striking.

M. Dubreuilh has unearthed in his literary investigations an account of an affection in Senegal (Africa), known as "*Larbisch*." It seems to bear a very close resemblance to Creeping Eruption. Thus, its lesion is likened to a large "itch mite burrow" and the attempts to find the larva have been futile. There are these differences, however: several burrows or lines are found very often on the same individual and the trouble is easily cured by bichloride of mercury lotions and baths, while in Creeping Eruption, if Schmid's case is excepted, only one line has been found and it is not amenable to antiseptic medication.

Dubreuilh refers to some North American literature on dermamyiasis which was not accessible to him. I have been able to review several of these contributions.*

In none of them is an accurate determination of the parasite recorded although to the invasion of the *Œstridæ* is usually attributed the lesion. The lesions themselves differ in no way from the usual type; they consist of tumors resembling furuncles.

I have considered the subject of Creeping Eruption worthy of attention because of its several points of interest. In the first place, it has a special dermatological importance. Secondly, it is worthy of note from a general medical standpoint because of its relation to the subject of myiasis. In the foregoing account, the rôle of the bot flies in the production of the Russian examples of the disease was emphasized. It remains for future investigation to demonstrate whe-

*Guerin, *Med. Chronicle,* Montreal, 1855-56, III., p. 330; Bethune, *Canad, Med. Jour.,* 1868-9, V., p. 110; Allen, *Boston Med., and Surg. Jour.,* 1872, LXXXVII, p. 306; The Band, *Hosp. Gazette, N. Y.,* 1877, Vol. II., p. 312.

PLATE XXVI.—To Illustrate Dr. Louis P. Hamburger's Article.

Creeping Eruption: Its Relation to Myiasis.

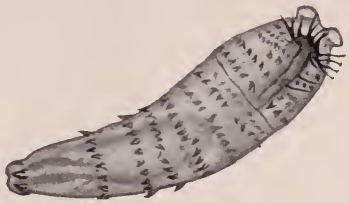

Fig. 1.

Fig. 2.

DESCRIPTION OF PLATES.

Fig. 1. Sokolow's drawing of the Gasterophilus larva is magnified forty times.
Fig. 2. The distinction between the fading older portion of the serpiginous eruption and the more marked active part is depicted.

ther all instances of similar eruptions are the result of the infection of *Œstrus larvæ*. Even if this particular family of the Diptera is not demonstrated, there can be little doubt that some dipterous larvæ is the causal agent. I have endeavored to show the probability of this conclusion by drawing from the literature examples with clearly established etiology, so far as the Diptera are concerned, exhibiting all gradations from the well-known furuncular type to cutaneous lesions closely resembling Creeping Eruption.

The fact that the buttock has so often been the seat of the trouble, would indicate that in some instances the toilet might be the source of infection. Yet, on the other hand, it is possible that the skin may be affected secondarily to an intestinal myiasis, the stool, in this event, being the carrier of the larva.

Finally, the fact that it is the second time, so far as I know, that the eruption has been recorded in this country, adds interest to the communication.

REFERENCES:

Bruno, see Samson. *Vratch.*

Cholodkowsky, *Vratch,* 1896, p. 59; 1896, p. 1268.

Crocker, *Diseases of the Skin,* 1903, third edition, p. 1388.

D'Haenens, *Cent. f. Inn. Med.,* 1899, bd. 20, s. 1144.

Dubreuilh, *Archiv. de Med. Exp.,* 1894, t. 6, p. 328.

Joseph, *Monatsheft f. prakt. Derm.,* 1887, bd. 6, s. 49.

Kaposi, *Wien. Kl. Woch.,* 1898, XI., s. 399; s. 428.

Kirschmann, *Wien. Med. Woch.,* 1881, bd. 31, s. 1370; 1882, bd. 32, s. 248. (Criticism by Loew.)

Lee, *Clin. Society's Transactions,* 1875, Vol. VIII., p. 44; 1884, Vol. XVII., p. 75.

Matas, Reference in "Insects Affecting Domestic Animals," *U. S. Dept. of Agriculture,* 1896, p. 112.

Matschinsky, see Samson.

McCalman, *Brit. Med. Jour.,* 1879, Vol. II., p. 92.

Morris, *Brit. Jour. of Derm.,* 1896, Vol. VIII., p. 145.

Olissow, *Vratch,* 1897, p. 191.

Petersen, *Verhand. der Deutsch. Dermat. Gesell. V. Congress.,* 1896, s. 95.

Samson, *Vratch,* 1895, p. 1364; *Archiv. f. Derm. und Syph.,* 1897, bd. 41, s. 367.

Schlesinger, *Cent. f. Inn. Med.,* 1902, bd. 23, s. 66.

Schmid. *Mitth. des Vereines der Arzte in Steiermark,* 1900, number 3, s. 48; Number 4, s. 65.

Smith, *Trans. of the Int. Med. Congress,* 1881, Vol. III., p. 181.

Sokolow, *Vratch,* 1895, p. 1456.

Spence, *Edin. Med. Jour.,* 1858, Vol. IV., p. 417.

V. Frantzius, *Virchow's Archiv.,* Bd. 43, s. 98.

Von Harlingen, *Amer. Jour. of Med. Sc.,* 1902, Vol. 124, p. 436.

REPORT OF PERSONAL CASE OF PAPILLOMA OF THE SOLE.

By T. D. Berry, B.S., M.D.

Assistant Surgeon U. S. Public Health and Marine Hospital Service.

SOME time since, while perusing the Journal of the American Association of July 11, 1903, my attention was attracted by the heading "Papilloma of the Sole"; an article written by Dr. Douglas W. Montgomery, of San Francisco. As I had been a sufferer from that affection for several months, and as this was the first literature on that subject I had come across, it is needless to say that I read the article with a good deal of interest.

I had searched our station library in vain, looking in Duhring's, Fox's, Jackson's, Kaposi's, Morrow's, and Shoemaker's textbooks of diseases of the skin for some reference to papilloma of the sole. I also looked in several textbooks and systems of surgery, hoping that it would be treated of in the chapters of tumors or skin affections. Warts in other situations were treated of at some length, but not a word was said about those occurring on the sole of the foot, where, because of their anatomical position their root or base is deeper, they are subject to more irritation and are, therefore, more painful and are harder to get at and treat than in any other situation.

The references in Dr. Montgomery's article are few, although as he wrote me he had figuratively "raked the literature of the subject with a fine-tooth comb." The reason, of course, is the fact that nearly all patients believe their warts are corns and go to a chiropodist, who will usually treat them himself. And unless a physician himself happens to be the sufferer and then takes the trouble to write about it, the profession at large is not apt to have its attention called to the subject.

The Louisville chiropodist, whom I shall again mention, told me that he sees on an average six or eight patients a year. If anything like this proportion holds over the country, the number of cases occurring all the time must be surprisingly large.

In my own case I cannot claim to have made the diagnosis, but supposed I had an unusually sensitive corn. It was situated about opposite the head of the second metatarsal bone of the left foot. It returned promptly after trimming, although I must admit I was too tender hearted to trim it very deeply. For this reason I betook my-

self to a chiropodist with quite a local reputation because of the deftness and neatness with which he removes corns. This gentleman soon found out the nature of the growth, since it refused to shell out but bled freely as he cut across the base. He at once advised me to go to a medical friend of his to whom he sent all of his papilloma cases and have the wart burned out with the galvano cautery, since he did not treat warts from fear of their turning malignant.

Having, however, great confidence in the efficacy of nitric acid, I burned the base thoroughly for two successive nights with that agent, and my mind was at ease as to the result. However, the wart was not, and was back again in two weeks as large as ever. I repeated this treatment after first trimming off the external portion of the wart, and treating the raw base with nitric acid to which had been added all the cocaine it would dissolve. I had read of this as a painless caustic, but I cannot say that I noticed any diminution in the biting pain caused by the acid. I repeated this cauterization for three successive nights, but the wart was back in schedule time.

At its recurrence I thought of the advice of the chiropodist and went to his medical friend. This physician, prefacing his work by the medical fable, customary in such cases, that it would not hurt, meaning of course himself, proceeded to burn out the wart with the galvano-cautery. The sensation caused by having a red hot wire thrust into one's anatomy is an essentially painful one, especially in a hyper-sensitive spot as a wart on the sole.

This treatment, too, went for naught, the wart again bobbed up serenely, and becoming disgusted with treating it, I contented myself with keeping the top trimmed off and with hoping that it would go away as these capricious growths sometimes do. The outgrowth from the wart was rapid and the counter pressure from the shoe flattened it out as it would come to the surface. This flattened portion would overlap the sound skin surrounding the base, and give the wart the appearance of being much larger than it really was.

This flattened portion, or head, would become the size of a split-pea in two weeks, could be easily lifted from the skin underneath and cut away at the narrow base level with the skin. The root, whose stroma was slightly translucent, thus being in contrast with the surrounding skin, was also faintly pink from small blood vessels. The root dipped straight down through the thick sole. Thus in shape the wart resembled very much a flat-headed carpet tack, and I may add felt very much like one. It acted very much like a foreign body, keeping up a constant irritation in that part of the foot, so that an area

the size of a half-dollar, with wart as a center, was painful on pressure and swelled slightly above the surrounding tissue. The pain on walking or standing was of a stinging or burning character, for the first half hour in the morning, after which it was not noticeable, unless I should step directly on a stick or stone when it would sting exquisitely.

I kept up this expectant treatment for several months and until I noticed that the root was increasing in thickness. About this time I came across Dr. Montgomery's article and gave a trial of his method of applying to the wart a ten per cent. salicylic ointment and then burning the base when exposed. The ointment softened the tissue and gave much relief from pain on walking. The cauterization was not so successful, though I admit I did not try it for over two or three weeks, for I was becoming easily discouraged.

I then determined to thoroughly eradicate the growth, disregarding the danger of a tender cicatrix in that situation, a contingency which had hitherto deterred me. After cocainization of that part of the foot, I had one of our hospital nurses burn out with Paquelin cautery point every vestige of wart, burning entirely through the skin of the sole and into the fatty cushion beneath, and then turning point round and round until there was a hole left in which the blunt end of a lead pencil could have been inserted. There was very little pain after the cocaine wore off, and contrary to my expectations I was able to stay on my feet during the next few days.

This treatment was successful, and although the tenderness in the almost cornified tissue surrounding site of former wart remained for a while, yet at the present time, six months afterwards, there is not the slightest tenderness, nor has there been any recurrence of the papilloma.

A RARE BROMIDE ERUPTION.

Lotta Wright Myers, M.D.

Chief of Dermatological Clinic at the Dispensary of the New York Infirmary for Women and Children; Clinical Assistant to the Chair of Dermatology, New York Post-Graduate Medical School.

THE patient, a female, aged six months, was first seen by me when the eruption was at its height. Being in doubt about the case, I asked Dr. Charles Warrenne Allen to see it with me and he diagnosed it a bromide eruption, though no history could be obtained from the parent. Later, the following history was obtained from the physician who had treated the child for a slight intestinal disturbance.

December 2d, 1903, potassium bromide in 2-grain doses was given every three hours. Two days later, the child returned with a rash, resembling varicella. The bromide was stopped but the lesions continued to appear and develop. On December 15th, when the case was first seen by me, the lesions were on the scalp, forehead, both cheeks, the legs from the ankles to the knees, and two or three small ones on the buttock. The lesions were in various stages of development. The new ones were small, yellowish vesicles, some resembling vascular tumors; others were discrete, rounded, semi-firm, and varied in size from a split-pea to an inch in diameter, with distinct, sharply-defined edges and a flat, uneven, prominently raised surface on which were numerous minute pustular points.

Those on the cheeks were confluent, especially on the right cheek. Later they were covered with a brownish crust. One lesion appeared on the tongue and as late as December 30th, four weeks after the drug was given, a few new ones appeared on the thighs, but these did not run the full course.

The eruption slowly disappeared and on February 13th the body was free from crusts, but the pinkish stains remained a month longer. At no time was there any irritation or itching. During all this time the general condition of the child was excellent.

The points of interest in this case were—the small amount of bromide given; that the height of the eruption was not reached until eleven days after the drug was discontinued; that new lesions continued to

appear for four weeks; the lesion on the tongue; and the length of time that the crusts and stains remained.

In examining the literature on the subject, I find nine cases very similar to this reported by Jackson, Hutchinson, Fox, Hall, Portis, and Pernet. All these authorities consider them of rare occurrence. No mention has been found of a bromide lesion appearing on the mucous membrane, but Arthur Hall mentions one case of iodide eruption with a similar rash in which he found one lesion on the tongue.

SOCIETY TRANSACTIONS.

NEW YORK DERMATOLOGICAL SOCIETY.

322d Meeting, February 23, 1904.

Dr. Fordyce, President, pro tem.

(*Continued from page* 194).

A Case for Diagnosis. Presented by Dr. Bronson.

The patient was a lad fourteen years of age, who, for four years had had persistent ulceration of the tongue. There was nothing in the patient's history or antecedents to account for it. There was no tuberculosis in the family and the patient himself, aside from the tongue malady, presented the appearance of perfect health. He was well formed, well nourished, with none of the stigmata of inherited syphilis. The ulceration began without known cause on the left side of the tongue opposite the molar teeth and about on a line with the circumvallate papillæ and had remained at the same side, slowly extending in area, and at the time it was presented, occupied a space about one-half inch in diameter. The surface which was but little depressed was grey in color, not especially sensitive and surrounded by tissue that showed some induration—more especially at the back. There was no particular roughness and no decay of the adjacent teeth, though some time before a dentist had given them attention; had probably smoothed the edges somewhat. Some time after the ulcer on the left side was noticed another smaller one was observed on the opposite side, the situation of the two ulcers exactly corresponding. That on the right side, when shown, had the appearance of a cleft in the mucous membrane, was not more than a quarter inch long and had the general character of the ulcer on the left side except there was no perceptible induration.

A section taken from the left ulcer had been submitted to microscopic examination and none of the elements of tuberculosis, nor of epithelioma, had been found. The report of the examiner was that the structure corresponded more nearly to that of a syphilitic lesion than anything else.

PLATE XXVII.—To Illustrate Dr. Lotta W. Myers' Article.

A Rare Bromide Eruption.

A Case of Morphœa. Presented by Dr. Whitehouse.

Dr. Whitehouse again brought forward his case with the circumscribed patch on the right cheek. This case was shown at the December meeting for diagnosis and he again wished to present her to show the failure to obtain any benefit from mercurial treatment. The patch was even more congested than before. He called attention to the fact that another indurated patch existed in the skin over the upper part of the left breast. The patient states that this began the same time as the one on the cheek.

Dr. Klotz did not consider the affection on the face as syphilitic, but, nevertheless, he did not think the specific treatment had been given long enough to justify a negative conclusion.

Dr. Allen considered that his former diagnosis of lupus pernio of the hands and face had not been altered by the developments in the case. The breast lesion, he thought, had nothing to do with the other manifestations, which he could in no way regard as luetic.

Dr. Lustgarten was even more convinced that the case was one of a gummatous infiltration. It was often the case that at the beginning of a mercurial treatment the lesion might for a time become worse. This had been well described by Herxheimer about a year ago. The increased local reaction was similar to the local reaction in lupus after the injection of tuberculine. He had often noticed that when treatment was begun in the roseola stage that the rash became worse for the first two or three days. In the case under discussion he did not think that mercury had been given in sufficient doses or for long enough to judge of its effect as a therapeutic test. He had observed that tabes cases, which had been submitted to an energetic mercurial treatment for two weeks, were often followed by pronounced aggravation of the lancinating pains and other symptoms, but that if the treatment was continued the cases improved.

Dr. Bulkley considered it a lymph and capillary stasis. It was not an inflammatory condition, nor could he see any reason for believing it to be syphilitic. He recommended an ointment of the iodide of lead, one-half dram to a dram to the ounce of diachylon ointment.

Dr. Sherwell did not consider it syphilitic. There was a lymph stasis of the nature of a lupus pernio.

Dr. Elliot said that, in his opinion, it was a case of what had been termed erysipelas perstans, etc., involving septum of the nose and the subjacent portion of the upper lip. In a similar case, observed at Cornell, a histological examination showed a chronic connective tissue hyperplasia and the histological diagnosis was "Elephantiasis."

The lesion of the breast he considered an interstitial mastitis, in no particular syphilitic.

Dr. Whitehouse, closing the discussion, did not feel that there had been the slightest suggestion of syphilis. He had used the oleate of mer-

cury, locally, and arsenic internally, since which there had been some improvement. His diagnosis was morphœa and he had not seen any reason to change it.

A Case of Syphilis in which a lesion of the lower lip had been removed under the diagnosis of epithelioma, cleared up under salicylate of mercury injections. Presented by Dr. A. D. MEWBORN.

The patient, whom I have the honor of presenting, through the courtesy of Dr. Fordyce, is considered interesting on account of the liability to mistake a syphilitic manifestation for a malignant growth, especially where the therapeutic tests of mercurial inunctions, mixed treatment, etc., were used, but not in sufficient dosage to give results. Mr. B., aged fifty-five years, a native American and a salesman by occupation, applied for treatment at the University-Bellevue Clinic about ten weeks ago. In his family history there is no record of tuberculosis. His mother lived to the age of seventy, during the latter ten years of her life she suffered from an epithelial cancer of the nose, but this was not the immediate cause of her death. His father died of old age. In his own history there is nothing noteworthy except frequent attacks of gonorrhœa between twenty and thirty years of age. He is a widower having a son thirty-two years old.

Twelve years ago he was exposed to a venereal infection and contracted a "sore" on the penis. No history of secondaries. One year later there developed at the site of infection a fungating and exuberant tumor with enlarged inguinal glands. His condition failing to improve for about twelve months he was operated upon for a carcinoma of the penis. The penis was amputated at the base and the inguinal glands were removed.

About seven months ago he developed a "sore" on the lower lip which he attributed to an infection from a dirty towel. This "sore" was not crusted or ulcerated, but hard, with a rather elevated edge. The glands under the jaw were enlarged, but not tender or painful. After two months waiting with no change in the appearance he was operated upon at one of the city hospitals and a "V" shaped piece of the lower lip as well as the indurated glands under the jaw were removed. Since the operation, eroded patches have appeared on the roof of the mouth, on the tongue and lips and split papules at the corners of the mouth. Three weeks ago a red and desquamating condition of both palms appeared. He had been treated with mercurial inunctions and iodide of potash without improvement.

At the first examination the patient, who is small in size and rather anæmic, presented a vertical scar on the lower lip to the right of the median line. The lip, which was somewhat tensely drawn on account of the shortening, showed some induration around the scar. On the inner surface of the lip was an eroded mucous patch with slightly elevated edges, about two or three centimeters in diameter. Inside of the cheeks,

on the dorsum and tip of tongue and on the hard palate were numerous eroded patches. The stump of the amputated penis was about one inch long and showed an eroded patch near the opening of the urethra.

For local treatment, applications of a twenty per cent. solution of nitrate of silver were made to the patches. Every week he was given a deep intramuscular injection of basic salicylate of mercury, ten centigrams to the cubic centimeter of sterilized benzoinol at a dose. Improvement was marked one week after the first injection and on January 19th, after four injections had been given, the patient was perfectly free of lesions. After the sixth injection the condition of the palms was normal. He has had no pain from the injections and only slight induration following the fifth injection, which soon passed away. There are two interpretations of the patient's history: first, that he was infected with syphilis twelve years ago and that the tumor of the lip was a gumma, or second, that the tumor of the lip was an initial lesion, which, taken with the history of a previous operation on the penis for carcinoma, had supported the idea of a recurrence of the carcinoma.

Dr. KLOTZ thought that the second diagnosis was the correct one and that the excised ulcer had been the primary syphilitic lesion. The nature and period of development of the other symptoms, the *plaques muqueuses*, and particularly of the papular affection of the palms, were in perfect agreement with this opinion. The enlarged glands already pointed to an initial lesion of syphilis and rendered a gumma very improbable.

Dr. FORDYCE said that he quite frequently saw cases of syphilis which had been diagnosed as malignant growths. Surgeons were too apt to overlook the possibility of syphilis in obscure conditions.

Dr. LUSTGARTEN said that such cases of mistaken diagnosis were very frequent. Muscular tumors, osteo-sarcomas as well as initial lesions, were removed from failure to recognize syphilis as the cause.

A Case of Mycosis Fungoides. Presented by Dr. BULKLEY.

The patient is an iron-moulder, aged forty-five, who developed a scaly eruption on the body about a year ago. After trying various remedies such as "Cuticura," chrysophanic acid, and sulphur ointments, he developed a dermatitis for which he applied to the Skin and Cancer Hospital. In addition to the exfoliative dermatitis present at that time, the underlying dark-red, circinate patches could be distinguished. There was an abundant exfoliation of the epidermis in large flakes. The body was quite generally affected with the exception of the elbows and knees. The itching has not been excessive. Under treatment the dermatitis has cleared up, while there has been no improvement in the mycosis fungoides.

Acne and pseudo-keloid cured by the X-ray. Presented by Dr. ALLEN.

This patient, previously shown before the Society, was again presented to illustrate the beneficial effects of the ray in inveterate acne and hypertrophic scars following the lesions.

A Case for Diagnosis. Presented by Dr. Allen.

The patient presented a kerion-like condition of the bearded part of the face and neck. There were no pustules, and epilated hairs showed no boggy root sheaths nor evidences of deep suppuration. The hairs had not been examined microscopically.

A Case of Psoriasis. Presented by Dr. Mewborn.

This patient was previously shown at the December meeting and was again presented in order to demonstrate the extensive recurrence of the eruption after its recent blanching under the X-ray. The hair was reappearing in the bald spots on the scalp.

A. D. Mewborn, Secretary.

BOSTON DERMATOLOGICAL SOCIETY.

Regular February Meeting.

Dr. J. T. Bowen in the Chair.

A Case of Syphilis and Pityriasis Rosea (?). Presented by Dr. C. Morton-Smith.

Ethel B., æt. 19. Says she had a sore on her vulva early in September, 1903. She came to the Boston Dispensary on September 28, with the stains of a previous itching eruption (which was undoubtedly scabies) and also an early syphilitic roseola accompanied by indurated glands in the groins, at the elbows and in the neck. She showed a small sore on the left labium minus with little or no induration. Subsequently, nocturnal headaches, alopecia and mucous patches in the throat and on the lips appeared.

The roseola entirely disappeared in due course of time and the present eruption began about ten days ago, showing first on the chest, arms and face, and has since spread to the abdomen and thighs. There has been but little itching accompanying this eruption and no febrile disturbance has been observed throughout its course.

Dr. J. T. Bowen considered the case to be pityriasis rosea as he had noted the so-called crumpled-up lesions so pathognomic of this disease.

Dr. G. F. Harding agreed with this diagnosis and added that there were still evidences of syphilis in the throat.

Drs. C. J. White, H. P. Towle and F. S. Burns regarded the case as one of urticaria.

Dr. James C. White looked upon the process as a possible drug eruption of the simple erythematous, non-exudative type, and stated that there were lesions too large to be classed as pityriasis rosea. He would call the disease urticaria or dermatitis medicamentosa of an urticarial type.

Dr. J. S. Howe, who had seen the patient by daylight, regarded the fawn-colored macules with wrinkled center as very typical of pityriasis rosea.

Dr. A. Post would not commit himself to the above diagnosis and considered the presence of the present macular lesions and the remains of the syphilitic and scabietic processes too puzzling a condition to be diagnosticated by artificial light.

Dr. J. M. Smith, in closing the discussion, said that in a good light the lesions did not resemble wheals but showed the smooth, "wash-leather" macules so characteristic of pityriasis rosea.

A Case for Diagnosis. Presented by Dr. Bowen.

The patient was a child two and a half years old, born in America of Italian parents. The present eruption had existed from four to six months, but it was impossible to determine the exact time. It was generally confined to the trunk and thighs and consisted of round or irregular scaling areas with some clearing-up in the center. There were also irregularly shaped areas, some an inch and a half to two inches in diameter, not sharply outlined, resembling patches of ordinary eczema, and connected with all these affected areas there was a marked accentuation of the follicles.

Many of the circinate, scaling areas suggested pityriasis rosea; but there were grades of inflammation from these circular lesions to the irregular eczematous-like patches. There was some itching and burning, but not to a marked degree, and the child had a healthy appearance.

From the parents' account, it seemed that no lesions were permanent, or, at any rate, that any individual lesion had a long period of life. Another feature of the case was the marked alteration of the nails of the fingers and toes, which consisted of a transverse furrowing with opacity and thickening and some exfoliation of the surface. The scalp presented a slight pityriasis.

Dr. James C. White said that this case suggested a series of cases observed during the last few years which at times made one think of psoriasis, at others of pityriasis rosea, and again of *érythrodermie pityriasique en plaques disséminées.* The present case demanded study and he would therefore hazard no diagnosis under the circumstances.

Dr. Towle thought that certain features of the case called to his mind a mild and clearing psoriasis, while other lesions suggested a seborrhoic involvement.

Dr. C. J. White regarded the case as belonging to the rather large group of diseases which had been observed with increasing frequency during the last few years at the Massachusetts General Hospital and which Brocq had placed together under the title of parapsoriases.

Dr. Bowen made the same diagnosis but thought that some of the lesions suggested strongly pityriasis rosea, but the sharp definition of

many of the plaques and the long duration of the disease were decidedly against this latter view.

A Case of Epithelioma. Presented by Dr. Burns.

The patient was an old man who had had keratosis senilis for some years followed by several epitheliomatous ulcerations upon the face. The case had been treated since last April by the X-rays and during the first six weeks one epithelioma had completely healed leaving a soft, smooth, pale scar, the size of a fifty-cent piece, which has remained unchanged ever since. The other two ulcers have refused to heal and at present the man presents upon his upper lip and over the broad part of his nose and extending down over the right ala a rather deep, healthy-looking ulcer with soft, sloping and, in places, crusting edges.

Dr. Burns exhibited this patient in order to emphasize the tendency of certain individuals to become tolerant of the X-rays.

Dr. Harding said that he had frequently noted this saturation of the tissues by the X-rays which in some patients went so far as to cause a positively deleterious effect by their further employment.

Dr. James C. White asked if it could be foretold by its clinical aspects whether any case of epithelioma would be favorably impressed or not by the X-rays. He had seen several cases of verrucous keratosis undergoing epitheliomatous transformation in parts in which such portions had quickly recovered under X-rays, but the original process remained unaffected. He asked Dr. Burns if he expected them to be made to disappear eventually.

Dr. C. J. White spoke of a case at present under his care where this saturation was well illustrated. An extensive and destructive lupus vulgaris had given way in two places on the face to epitheliomatous degeneration. The man had been exposed to the X-rays for three months with a marked amelioration at first. For the last month no progress had been made and the X-ray treatment had been stopped and ten per cent. salicylated soap plasters substituted. An almost immediate improvement showed itself and an open ulcer had diminished about one-half in size within two weeks. The purely tuberculous lesions on the arms, which had also ceased to improve under the rays, had shown a similar betterment under the cessation of the ray treatment and the substitution of the plasters.

Dr. Burns said that he had notes on five or six cases where saturation had shown itself. Cessation of the exposures and then a resumption of the X-ray treatment with or without intervening curettage had in all these cases been marked by immediate improvement.

A Case of Erythema Perstans. Presented by Dr. C. J. White.

The patient was a young electrician, twenty-four years of age. His skin disease began while he was working in an electrical machine shop

where he was not exposed to any electrical currents. During the last few years, however, he has been in rather constant relation with very powerful electric generators and has noticed that the fumes of acids have increased the itching of his affected skin.

The man looks well but complains of gas after eating and frequent greenish stools, and says that he has been often jaundiced, but not during the last two years. Since childhood he has eaten large quantities of eggs, averaging five dozen a week. On account of these digestive disturbances he has consulted, on several occasions, Dr. Franz Pfaff, who has kindly sent the following note at my request. "This case puzzled me last year, especially on account of the peculiar condition of his urine. At that time I made two analyses of the urine with the following results:

"I. Quantity	2280 c. c.	Albumen	slight trace.
Reaction	acid.	Sugar	none.
Sp. grav.....	1013.	Urea	1.39%.

Sediment—two to three hyaline casts per slide, many calcium oxalate crystals, much mucous and a few squamous cells.

"II. Quantity	3460 c. c.	Albumen	slight trace.
Reaction	acid.	Sugar	none.
Sp. grav.....	1012.	Urea	1.13%.

Sediment—two hyaline casts per slide, many calcium oxalate crystals, few squamous cells, few neck of the bladder cells and a few leucocytes.

"Thus the striking features are very marked polyuria with marked oxaluria denoting some error of metabolism, the cause of which as yet I have not been able to discover."

The patient, on his first visit to me about three weeks ago, presented a very conspicuous erythema. The forehead and both cheeks were almost wholly covered with large flat, raised, red, firm lesions out of which it was very difficult to express the blood. This condition began eight years ago, when the man was sixteen years of age, and has persisted ever since. During the summer the erythema disappears but with the advent of the cooler weather in the autumn, the disease reappears and, with occasional intermissions of a few days, remains constant and unchanging until the late spring.

To-night, after the administration of salol by Dr. Pfaff and the local applications prescribed by me, the erythemato-papular masses have greatly diminished and the patient presents a very different appearance, exhibiting only a suggestion of the condition present three weeks ago.

Dr. Howe agreed to the diagnosis of erythema and thought that the great improvement under the influence of salol pointed to the intestinal origin of the process.

Dr. James C. White regarded the term erythema multiforme inappropriate where the individual lesions persisted so long as in this case.

He raised the question whether the patient's constant exposure to the influence of powerful electrical apparatus of various sorts may not have produced such stimulation of the skin. He had seen cases among electricians of dermatitis of the face and hands produced by such exposure.

A Case for Diagnosis. Presented by Dr. J. S. Howe.

The patient was a young woman, aged thirty. About a year ago a scaling, slightly reddened lesion had appeared on the seat of an old vaccination scar and had apparently persisted ever since. Six weeks ago similar lesions began to appear on other parts of the body accompanied by pruritus and at present there are many small (largest area, size of five-cent piece), raised, slightly-scaling, reddened macules scattered over back, chest, backs of hands and thighs.

Dr. Harding regarded the case as one of psoriasis.

Dr. Burns favored the diagnosis of seborrhoic dermatitis.

Drs. Towle and C. J. White called the disease parapsoriasis.

Dr. James C. White remarked that if this case were but of two or three weeks' duration it might be regarded as a case of simple acute psoriasis in which the scales had not had time to accumulate. On the other hand if the woman's statement were true that one or more lesions had been present for many months then the diagnosis of parapsoriasis might be a proper one. The lesions seemed to be too small and too numerous to permit of the diagnosis eczema seborrhoicum.

Dr. Howe had thought of seborrhoic eczema, but on careful and prolonged observation he had noted minute pin-point scaling papules which had inclined him toward the diagnosis of psoriasis.

A Case of Nail Disease. Presented by Dr. Howe.

A young Irishman, who had been a bar-keeper for seven years and who had, among other duties, washed out brass sinks with potash, presented a very striking appearance of all his finger nails save that on the right thumb.

The disease began about six years ago and had not changed during the last three years. At first paronychia had developed on one finger followed by changes in the adjacent nail substance and in a similar manner the other eight nails had become involved.

At present the affected fingers present a deep and angry-looking tumefaction of the skin surrounding each nail. The nail plates themselves are very thick, dirty-yellow in color, spongy, covered with indentations and vertical furrows and show a marked degree of subungual hyperkeratosis.

Dr. James C. White would not regard such intense inflammation of nail tissue and immediate surroundings as due to the action of caustic potash. Such long exposure to its action would certainly have affected the integument of the hands as well in some measure. The case resembled much more the local action of arsenic characteristic of some occupations.

Dr. C. J. White said that in his recent observations on nail diseases, which he had carefully recorded for two years, he had seen many such conditions, varying in their extent and degree, following paronychia. He had particularly noted that people who have their fingers continuously in unusually dirty and irritating liquids, such as scrub-women and bar-keepers, formed the largest class of people affected by multiple paronychia and subsequent nail involvement. He regarded the suggestion by the patient of caustic potash as a probable cause simply as one more noxious substance in his daily work.

Dr. Howe was not inclined to incriminate the caustic potash and was at a loss to give a definite name to the nail affection.

A Case of Follicular Eczema. Presented by Dr. C. J. White.

The patient was an Italian and a carpenter by trade. Some years ago he had an eruption similar to the present one and an Italian doctor had attributed it "to the blood." The present attack began three months ago and causes a severe general pruritus, especially when the man is warm.

The face and neck are flushed and universally pink and finely scaling. The chest, as far down as the pectoral region, is free from papules, but suffused over the sternum. Below the nipple line, extending to the umbilicus, appear diffusely scattered, discrete, brown to dull red, round-topped papules, which are free from scales and not appreciably follicular. Over the back, from the neck down to the ankles, and down the arms to the elbows one sees closely aggregated, discrete, scarlet papules, which are absolutely follicular. Around the waist line the lesions have become confluent and a diffuse erythematous, slightly infiltrated condition exists. On the extensor surfaces of the upper arms, buttocks and backs of thighs every follicle is affected and the seat of slightly raised, dull red papules free from scales. The hands, feet and penis are free—the former two surfaces showing distinct passive congestion. The front of the thighs show a few, scattered, dull-red macules.

Histology. A small papule was excised from the chest below the nipple, hardened in Zenker's fluid, cut in paraffin and stained in various ways, but unfortunately the sections examined do not show the follicle at its orifice.

The stratum corneum is reduced to a minimum and in places absent. The stratum lucidum is not apparent. The stratum granulosum is represented here and there by an occasional horizontal cell always free from keratohyalin and often devoid of a nucleus. The rete is somewhat thickened and shows much pigmentation—in places the granules existing halfway up the layer. The cells have in many instances lost their nuclei, while mitoses are present in unusual numbers. As a whole this layer seems quite œdematous and receives the nuclear stains poorly.

The corium shows about its subpapillary vessels a universal condition of extravasated cells and many of the capillaries are dilated. The elas-

tic tissue persists in an unusual degree considering the signs of œdema everywhere present, while the corium as a whole is remarkably free from nuclear elements.

The sebaceous follicle, the true seat of the disease, appears in the middle third of the corium and is represented by a rectangular mass, comparatively wide, of newly formed œdematous elements resembling connective tissue cells more than any other structure. The sebaceous gland and the follicular walls have entirely disappeared, but the arrector muscle, rather free from nuclei, however, persists below the cellular mass.

Dr. James C. White said that the lesions suggested lichen urticatus although the picture as a whole certainly resembled eczema.

Drs. Howe and Harding spoke of the lichenoid features of the case.

Drs. Bowen and C. J. White believed the case to be one of follicular eczema.

Cases of Empyroform Dermatitis.

Dr. Burns reported the case of a young Russian Jewess who had been treated at the Massachusetts General Hospital for more than a year for an obstinate psoriasis. He finally gave the woman a weak empyroform ointment (gr. xv. to oz. 1) to try on one arm. She applied the ointment at bed time and several hours later was awakened by an intense burning sensation in the arm to which the ointment had been applied. The following morning the patient returned to the clinic with the arm presenting a diffuse, moderately reddened area corresponding to the site of the application. There was no vesiculation, but the skin still burned and was somewhat tender to the touch.

Dr. C. J. White added a somewhat similar example in a case of psoriasis which had been treated at the Massachusetts General Hospital since 1898 when the eruption was universal. The patient had used upon the left arm an ointment of empyroform 1, oxide of zinc 2, lard 30; while upon the other he had continued his applications of chrysarobin and ichthyol. At the end of two weeks the man, suspecting that a diffuse, erythematous condition of his left arm signified a general return of his psoriasis came to the clinic to show his condition. The arm to which the empyroform had been applied was universally reddened while the other parts of the body presented the usual characteristics of a patchy psoriasis.

Dr. C. J. White alluded to another case of empyroform intolerance in a young woman who had sub-acute eczema of the hands and wrists. On one side she was using an ichthyol ointment while on the other an ointment containing a drachm of empyroform to an ounce of lard. On the latter side a general redness and slight œdema with acute, pinkish papules developed while the former continued in its previous condition. Later the empyroform was reduced to ½ dr. to 1 oz. of lard and the eczema did so well that this application was extended to the other arm.

Charles J. White, Secretary.

REVIEW

of

DERMATOLOGY AND SYPHILIS

Under the Charge of JOHN T. BOWEN, M.D.

ACUTE EXANTHEMATA,

By H. H. WHITEHOUSE, M.D., New York.

Rubella Scarlatinosa. FREDERICK C. CURTIS and HENRY L. K. SHAW. (*Med. News,* Vol. 87, p. 1166, Dec. 20, 1902.)

Under the above title the author reports an epidemic of an exanthem of rather unusual features occurring at Round Lake, N. Y., in April, 1901. This is a village of four hundred inhabitants, half of whom, it was estimated, were affected. The majority of the patients were adults; out of 147 cases treated 81 or 67 per cent. were in persons over twenty years of age. No child under twelve months developed the disease. Eighteen cases occurred in persons over sixty years of age. The period of incubation averaged about nineteen days. The onset was generally sudden, in severe attacks attended by feelings of malaise, headache, sore throat, slight fever and enlargement of lymph nodes in region of neck, groin and axilla. In the milder forms, the rash and enlarged glands were the only symptoms observed. There was no sneezing or redness of conjunctivæ in any of the cases. Sore throat was present in every case and was often very severe. Cultures revealed no Klebs-Loeffler bacilli. Enlargement of the lymph glands was a constant manifestation of the disease in every instance. The chain of lymph nodes situated along the posterior border of the sterno-cleido-mastoid were invariably palpable. The pulse ranged from 80 to 100, and in no case examined was it over 120. The temperature was also much lower than would be expected from the intensity of the eruption and some of the symptoms. The average temperature was 100 degrees F. while in a few instances it rose to 102.5 degrees F. The urine was examined many times and in no instance was albumen detected.

The rash in the majority of cases was bright red in color like that of scarlet fever and would, not infrequently, be mistaken for it. Close observation, however, showed a macular quality and there was a greater intensity in spots, with fading to lighter hue between. Over some areas the mottled appearance was pronounced, showing spaces of clear or but slightly congested skin. In a few cases there was more dulness of color

like that of measles. The duration of the active skin lesion was about a week. The majority terminated in flaky desquamation at least on hands and feet and in the more marked cases the desquamation did not differ from that in scarlet fever. The desquamation of the tongue, which produces the characteristic strawberry appearance, was not observed in any instance. The eruption was general though there was not much on the face. It was most intense on the anterior trunk and the limbs.

There were no deaths. The complications were: rheumatism, 29; bronchitis, 4; pneumonia, 2; erysipelas, 3; erythema nodosum, 3; acute otorrhea, 12; quinsy, 3; pleurisy, 1; cystitis, 1; myocarditis, 1.

The affection was distinctly endemic, it began and ended there without spreading beyond its original confines as in scarlet fever. This fact, together with the long incubation period, absence of vomiting and rapid pulse, absence of strawberry tongue, involvement of the lymph nodes, and lack of fatality were sufficient to differentiate it from scarlet fever.

The authors take a stand against the existence of a fourth disease, a position which is highly commendable. The growing tendency to regard common or unusual variations in type of a well-known disease as separate disease entities cannot be too strongly condemned.

The epidemic here reported is a distinct example of such variation in type of a well known and easily recognized disease. We like the title Rötheln or German measles, however, instead of the one chosen; it conforms better to the present accepted nomenclature and is less confusing.

Redlight Treatment of Smallpox, An Examination Into the Claims of.

Jay F. Schamberg. (*Jour. Am. M. A.*, May 2, 1903, p. 1183.)

The author arrives at the conclusion that the red light treatment is entirely without effect in either influencing or modifying the course of smallpox, or in the prevention of scarring. He bases his views upon the results of treatment in two cases from which the chemical rays were entirely excluded. These were both unvaccinated young men, sixteen and twenty years of age respectively. They were both severe cases and the course pursued was no different from that seen in patients treated in the general ward. One was a private case who had a special nurse day and night and every possible attention, but he succumbed to the disease. The other recovered but with most disfiguring scars.

In speaking of Finsen's statistics of 140 to 150 cases of smallpox in which the method was inefficacious in only one case, the author considers other factors accountable for the good showing. He thinks the most important treatment of smallpox, for the prevention of scarring, is the prophylactic treatment—vaccination. Denmark, Sweden and Norway, countries from which Finsen's statistics were chiefly drawn, are the best vaccinated countries of Europe. The type of smallpox has been very considerably changed since the introduction of vaccination. If not

conferring immunity in all cases, it modifies the disease and the cases are much milder. In mild smallpox the lesions are superficial and scarring is, therefore, slight.

During 1902-3 there were treated at the Municipal Hospital of Philadelphia 2,300 cases, half of whom were not vaccinated, the other half were adults vaccinated in infancy; still, 60 per cent. had no indelible scars. He concludes that the character of the prevailing form of smallpox, whether mild or severe, is a matter of great importance in determining both mortality and disfigurement.

Bacteriologic Examination of the Blood During Life in Scarlet Fever, with Special Reference to Streptococcæmia. (Ludwig Hektoen. (*Jour. Am. M. A.*, May 14, 1903, p. 686.)

In view of the fact that many now regard streptococci as an essential factor in the scarlatinal process, Hektoen's observations upon blood examinations in the living subject are most interesting. It would seem that every possible precaution had been taken by the author in his method and technique to insure freedom from contamination and consequent false interpretations. The study is based upon the blood examination in 100 living cases of scarlet fever. Out of this number he found streptococci in only twelve. Three of these were from the examination of thirty-two cases between six and ten years of age, two in eleven cases between eleven and fifteen years of age, one in ten cases between sixteen and twenty years of age, four in twenty-one cases between twenty-one and twenty-five years of age, one in twelve cases between twenty-six and thirty years of age, and one in five cases between thirty-one and forty-three years of age. In three cases the first cultures gave negative results while later cultures gave positive. Of ten cases examined on the first day, only one gave growths. A further summary of these twelve positive examinations shows that in four instances the disease was mild, in five it was moderately severe, and in three it was severe, showing that the relatively largest number of streptococcal growths were obtained from the more severe cases.

In discussing the exact relation of streptococci to scarlet fever, therefore, the results of his observations would favor the view that the streptococcus infection is secondary, because absent in the large majority of cases, even severe ones, and because, though absent in the early part, it may appear in the later stages of some cases. He thinks the best hypothesis of the etiology of scarlet fever, is the one that in this disease two infections generally co-exist, the cause of the specific primary infection being unknown, the second being streptococcic. The theory that scarlet fever is a streptococcus disease does not seem to receive any direct support from this work.

Vaccination, The Complications of. T. Colcott Fox. (*Brit Med. Jour.*, July 5, 1902, p. 35.)

Before enumerating the various generalized eruptions which may complicate vaccination, the author dwells briefly upon the variations in the development of the vaccine pocks, the excessive degree of local inflammatory reaction, and the variations in the healing and formation of scars.

Under these headings he makes particular mention of the occasional assumption of activity under the influence of a revaccination at points where the inoculation performed a week or more previously appeared to come to nothing; the raspberry sore, looking not unlike a small nævus, which sometimes develops on the site of inoculation; the unhealthy phagadenic character of the sore in some instances and the hypertrophied scars, or even true keloid that occasionally result.

Outside of the generalized vaccinia eruption and auto-inoculated vaccine pocks, which the author regards as probably the only ones peculiar to vaccination, the group of complicating eruptions comprises all types from the erythematous to bullous and hæmorrhagic. He thinks all these are probably due for the most part to some chemical irritant, for they are occasionally observed after the injection of antitoxins, serums and physiological saline solutions (subcutaneous or intravenous) following enemata and the administration of drugs by inunction, subcutaneously, or by the mouth. He thinks idiosyncrasy plays a considerable rôle in their production.

His list includes urticaria, multiform erythema, herpes, miliaria, sudamina, certain nondescript papular, vesicular and impetiginous eruptions, certain bullous and pemphigoid eruptions (in connection with which he refers to Bowen's cases of bullous dermatitis), purpura, disseminated gangrenous lesions, the so-called vaccinia gangrenosa, impetigo, ecthyma, furuncle, erysipelas, psoriasis, eczema and strophulus.

Tetanus is also mentioned as a rare complication due to a probable secondary infection. The author has not been convinced from a study of his cases that there is any direct relation between "eczema" and vaccination. Syphilis, tuberculosis and leprosy are briefly disposed of. The introduction of vaccination with bovine lymph renders the invaccination of syphilis impossible. The danger from inoculation with tuberculosis seems infinitesimal when it is considered that tuberculosis is rare in calves, and in regard to leprosy, it is not proved that the disease can be communicated by inoculation and further by vaccination.

He concludes that there are very few complications that it is not in our power to avert by using pure lymph, conducting the operation in a proper manner, and preventing any secondary contamination.

SYPHILIS OF THE SKIN AND MUCOUS MEMBRANES.

By Walter C. Klotz, M.D., New York.

Syphilitic Phlebitis. E. Hoffmann, Berlin. (*Dermat. Ztsch.*, 1903. Vol. X., p. 470.)

Syphilis of the veins is not very fully discussed in reference books, nor is it frequently met with in current medical literature. The author's observation cannot fail, therefore, to be of considerable interest. He sums up the literature on syphilitic phlebitis, which includes thirty cases, and furnishes careful notes on two additional cases observed by himself. Both of his patients had been perfectly healthy before contracting syphilis, had never suffered from rheumatism, and presented no evidence of varix in any other veins. Both were males. The development of phlebitis coincided in time with the development of the secondary manifestations of syphilis, which were rather severe in both cases. The disease affected the saphenous veins, being more extensively distributed in the second patient. It was characterized by a hard, cord-like swelling corresponding to the course of the vein. It was not very painful or tender, was not accompanied by any œdema of the leg or foot, and subsided readily under anti-syphilitic treatment, without any noticeable permanent change having been produced in the vein. In one case a portion of the vein was excised and subjected to microscopical examination. The changes found consisted in an interstitial inflammation involving principally the intima and the media with secondary thrombosis.

Fungoid Syphilitic Ulcer of Testicle. By DuCastel. (*Bull. de la Soc. Francaise de Dermat. et Syph.*, 1903, p. 302.)

The history of the author's case was as follows: initial lesion two years ago, treatment very irregular, consisting of local applications of blue ointment; eight months ago there developed a syphlitic ulcer of the scrotum. At the same time the right testicle became enlarged, attaining within eight days the size of an adult fist. The lesion of the testicle was accompanied by gummata in other parts of the body. Two months ago the gumma of the testicle opened spontaneously, producing a fungoid ulcer, the testicle protruding and lying exposed. The case improved considerably under calomel injections.

M. Motz in discussing the case remarked that such cases were rare in France, but quite commonly observed in Algiers among the native Arab population.

M. Barthélemy stated that this condition might follow either a syphilitic sclerosis of the testicle or gumma, and that both forms had a tendency to break down unless early and vigorous treatment was instituted. He also urged the importance of supporting the treatment with iodides and by injections of gray oil.

Acquired Syphilis in Hereditary Syphilitics. By GAUCHER and ROSTAINE. (*Bull. de la Soc. Française de Derm. et Syph.*, 1903, XIV., 9.)

The authors describe two cases which are of interest from the fact that in both there were stigmata of hereditary syphilis, that both had developed syphilitic manifestations in infancy and each had acquired syphilis in later life by contagion. The first case was that of a man thirty-one years old, suffering from distinct symptoms of tabes; he had been infected eleven years before, the secondary manifestations had been very slight and treatment had been very superficial. Atony of the bladder and painful crises had set in four years ago. The signs of hereditary syphilis were a protruding forehead, eroded teeth, high palatal arch, sabre tibiæ.

The second case was that of a woman, twenty-three years old, who was born of a syphilitic mother, had syphilitic manifestations during infancy, acquired syphilis when sixteen years old, and subsequently gave birth to a syphilitic child. She also bore unmistakable signs of hereditary syphilis, presenting the typical deformity of the nose, *"nez ecrasé a la base,"* in which the nasal process of the frontal bone was markedly depressed.

In discussing these two cases Barthélemy made a careful distinction between signs of syphilitic heredity, and manifestations of hereditary syphilis. Fournier pointed out the fact that these stigmata of hereditary syphilis consisted entirely of a dystrophy of the bony structures taking place before birth, and were in no sense the result of an ostitis or gummatous process.

SYPHILIS OF THE NERVOUS SYSTEM.

By JAMES MACFARLANE WINFIELD, M.D., Brooklyn.

The Influence of Hereditary Syphilis on the Nervous System. JAMES GRAHAM FORBES, M.A., M.D. (*Saint Bartholomew's Hospital Reports*, Vol. XXXVII., 1902.)

The article is an exhaustive study of hereditary syphilis in general and of the effect on the nervous system in particular.

Unfortunately the article is too long for abstracting, but as the author's conclusions are derived from the careful study of the literature and personally observed cases, it is believed that the conclusions that directly relate to the influence of inherited syphilis upon the nervous system are important enough to be given verbatim.

A-1. Affections of the nervous system as the result of hereditary syphilis are rare, but cerebral cases are more common than spinal.

2. This rarity is due to the high infant mortality from syphilis.

3. Of all forms of hereditary cerebral syphilis, congenital idiocy is the most rarely met with, i. e., mental deficiency from birth.

4. Chronic hydrocephalus is a very uncommon result of hereditary syphilis.

5. In the majority of cases, previous to the onset of cerebral symptoms, the mind and intellect are well developed and unimpaired.

6. Cerebral symptoms, such as headache, mental failure, and epilepsy usually appear in the last half of the first decade of life, but patients may survive to reach the second decade.

7. Mental deterioration, in the form of imbecility or dementia, usually precedes paralytic symptoms in the latter stages.

8. Hemiplegia is uncommon except as a terminal symptom.

9. There are cases of epilepsy in late childhood due to hereditary syphilis in which the epilepsy is a premonitory symptom of cerebral disease. In but few cases does epilepsy persist without the appearance of graver indications.

10. The average duration of the disease from the first onset of symptoms is five years, its length depending on the extent and nature of the lesions.

11. The post-mortem conditions usually found include, adherent meninges, cerebral sclerosis, atrophy and softening. Arteriosclerosis and endarteritis are not uncommon. Gummata of the dura mater or brain may be present.

12. Cure by specific remedies is only possible in the early stages, before the appearance of profound mental failure or paralytic symptoms.

B-1. The relation between general paralysis of the insane and tabes dorsalis is a very close one.

2. General paralysis, and far less commonly tabes dorsalis, occur in young people between the age of eight and twenty almost certainly as a result of hereditary syphilis.

3. A few cases of adult general paralysis may be due to the same cause where no history of acquired syphilis is to be obtained.

4. Extravagant delusions are not present in the early stages of juvenile general paralysis, and a stated dementia is far more common than maniacal conditions.

5. The disease runs a progressive course and usually terminates in three or four years.

6. The post-mortem changes found are: Thickening of the meninges particularly of the pia-mater and arachnoid membrane, wasting of the convolutions and softening of the gray and white matter in places.

There may be distention of the lateral ventricle with fluid.

A Case of Late Hereditary, Cerebral, of a Cerebro-Spinal Form. RICHON. (*Nouvelle Iconographie de la Salpêtrière,* Vol. 16, 1903, No. 2.)

The history of the case was as follows: Boy, aged eleven years; there were no visible lesions or stigmata of hereditary syphilis; he had fistulous

lesions of the parietal bone and Jacksonian epilepsy; there were persistent convulsions, a decline in intellect, deafness, blindness and hemiplegia, general cachexia and death.

Autopsy. Fibrous meningo and syphilitic basal gummatous meningitis; cerebellar cavity, and infiltration of the spinal meninges.

The conclusions are that the brain, already deformed from a slight degree of hydrocephalus, became the seat of gummatous deposits, which extended to the cord, the base of the brain and the white matter of the cerebellum. The specific nature of these lesions is proved by their anatomical character and the evolution of the process, as well as by syphilitic stigmata in the cerebral malformation.

The Syphilitic Nature of Tabes and General Paralysis. Dr. M. Leredde, Paris, France. Translated by M. Ostheimer. (*Phil. Med. Journal,* April 18, 1903.)

Reasoning from a recent article of Renaut's the author states that in future we can admit that a certain number of the medullar lesions of tabes and general paralysis may be directly of syphilitic origin.

He further says that, as far as he knows, no attempts have been made to discover whether the lesions of general paralysis were syphilitic or not. He considers that the syphilitic nature of both tabes and general paralysis is made plain by the recovery of these patients under mercurial treatment. He emphasizes the fact that dermatologists use mercury as a diagnostic test to establish the nature of a doubtful cutaneous lesion, and that in neurology this should lead to the same deductions. He says that if there is any affection of the nervous system the nature of which can be decided by mercury that affection is syphilitic in character. A number of cases are cited in proof of his therapeutic theory. The article is too long for abstracting, but it is well worth careful reading by any one interested in the subject.

BOOK REVIEWS.

Die Vererbung der Syphilis (The heredity transmission of Syphilis). By Docent Dr. Rudolf Matzenauer. Supplement to the *Arch. f. Derm. und Syphilis,* 1903.

With every advance of bacteriology and pathology our conception of the hereditary transmission of syphilis was changed. Kassowitz in 1875, Finger in 1890, tried to explain the phenomena of the hereditary transmission of syphilis in the light of the knowledge of bacteriology and pathology prevalent in their times. Now Dr. Matzenauer claims that our present view of the hereditary transmission of syphilis needs revision, as it is not in accord with our present ideas of the bacteriology and pathology of infectious diseases.

In his opinion, neither clinical nor pathological facts entitle us to ascribe to syphilis a particular, peculiar place among infectious diseases, but on the contrary, the same laws of heredity which govern the hereditary transmission of other infectious diseases, are also attributable to the hereditary transmission of syphilis.

With this guiding idea he collected and studied the hospital and dispensary material of Prof. Neumann and of his own private practice, following up the

histories of mother and syphilitic infant for several years. At the same time he gathered all published cases relating to this subject, and viewing them from our present conception of bacteriology and pathology, he drew conclusions which are at variance with the accepted idea of hereditary transmission of syphilis. He claims that a syphilitic infant can be borne only by a syphilitic mother; that a mother who is not infected with syphilis cannot give birth to a syphilitic child. That every mother of a syphilitic infant is syphilitic and that the calling into play of paternal transmission of hereditary syphilis is neither necessary nor has it an analogy in any other infectious diseases. The transmission of syphilis is always brought about through the mother. Furthermore he denies the germinative mode of transmission—by spermatozoon or by ovum—affirming that every transmission of hereditary syphilis is effected through the placenta. Our present conception of paternal transmission was deducted from clinical observations, in which the mother of the syphilitic infant was found free from manifestations of syphilis, while the father either gave a history of syphilis or presented visible manifestations of it. Matzenauer claims that in his observations every mother of a syphilitic child presented visible signs of syphilis, because he examined them early—in the first weeks after confinement—and he was not satisfied with a superficial examination but always examined the generative organs,—a procedure neglected by nearly all previous observers. The absence of syphilitic symptoms in mothers of syphilitic children reported by other observers is mainly due to the fact that they examined the mothers a long time after confinement, when the early manifestations might have disappeared, and they neglected to expose to ocular examination the genital organs of the mother.

Furthermore he finds that there are no exceptions to Colles Law. In studying observations reported as exceptions to that law—observations which would speak for the possibility of a syphilitic child being borne by a healthy non-syphilitic mother—he found that those cases can not be regarded as exceptions, because either the report is faulty or other deductions can be drawn from the observation.

The practical conclusion from this conception of the hereditary transmission of syphilis is of great importance. In families where children are affected with hereditary syphilis the first attention must be paid to the mothers. They must be thoroughly treated while the treatment of the fathers is of secondary importance.

BOLESLAW LAPOWSKI.

Die Pathologie und Therapie der Unfruchtbarkeit des Weibes. Von Dr. FERDINAND SCHENK, 1st Assistant der K. K. Deutschen Universitæts Frauenklinik, Prag. (Berlin: S. Karger, 1903.)

In this somewhat exhaustive monograph, the author proves, we think, that gonorrhœa is the main source of sterility in women. Through marital infection, her generative organs become the seat of unconquerable disease; or, if this result is not achieved by the gonococcus, the fault may be due to the husband who, from his gonorrhœa, has impermeable *vasa deferentia*. So that this most widespread venereal disease is the most potent factor in the production of barrenness.

The author is very careful, however, to enumerate the other functional disorders in the female which may render her childless, such as malformations, inhibited development and diseases or neoplasms of the uterus or appendages. He condemns the resort to routine operations for the relief of sterility until the husband's seminal fluid has been examined, and until every other cause for the barrenness has been excluded except functional deformity or inactivity of the generative organs. As to results of operative treatment in other than selected cases, he is not enthusiastic.

The monograph is well written and abounds in references to the literature, but strangely enough, American writers who have contributed much to this subject, are ignored.

P.

Beiträge zur Physiologie und Pathologie der Haut (Die Stachelzellnerven-Hypothese). Von Dr. Fritz v. Waldheim. (Leipzig und Wien, Franz Deuticke, 1904, pp. 135.)

The reader who takes up this series of papers in the expectation of finding in them some contributions to the physiology and pathology of the skin, in the sense in which these terms are ordinarily understood, will be sadly disappointed. They contain nothing more solid than what the expressive language of the street calls "hot air." The author has been seized with the idea that the prickle-cells of the rete are, in a sense, the end organs of a system of nerves, and this idea he confesses would not let him rest until he had thrown himself feverishly into the work of testing the hypothesis—theoretically—and following it out to its—theoretical—conclusions.

The author has brought to his task a large amount of reading which he employs often with a sad lack of critical estimation, and it seems a pity that the conjunction of so much learning and such literary energy should prove so sterile. Those who like this kind of thing will find this book the kind of thing they like.

P.

Ueber die Prognose der Syphilis. Vier Vorlesungen gehalten in den Aerztlichen Fortbildungskursen zu Aachen, 1902-1903; von Dr. G. Mayer, (Berlin, 1904, S. Karger, pp. 87.)

These lectures, based on the author's experience with nearly five thousand cases of syphilis that came under his treatment in Aachen, constitute a human document of unusual interest; and, though the author presents little that is new, his careful observation, the excellent arrangement of his data, and the sound judgment of the experienced practitioner make the book well worth reading.

In the four lectures the author discusses the prognosis of syphilis in general, syphilis of the nervous system, of the circulatory system, and of the lungs, liver, and kidneys.

The two chief factors in the general prognosis of syphilis are the intensity of the infection and the extent and duration of the treatment. The intensity of the infection may be judged from the course of the primary lesion and the early appearance of hypertrophic and necrotic lesions of the skin and mucous membranes. Unusually extensive and destructive lesions in the early stage are, however, not an unmixed evil because they generally lead to very thorough and prolonged treatment and in that way improve the prognosis in respect to the later accidents. On theoretical grounds the author approves of early excision of the chancre.

As to prognostic indications to be drawn from the location of the chancre, the author's experience is in harmony with the general view that initial lesions on the finger give a rather unfavorable prognosis. He ascribes this fact to the circumstance that the virus in these cases is often mixed with septic matter at the time of infection and furthermore it is usually implanted deep in the cutis. Extragenital chancres in general, other than those of the finger, do not give an especially unfavorable prognosis.

On the importance of early and prolonged treatment in averting the later accidents of the disease the author is most emphatic. His own experience extending back to the period when visceral syphilis was but seldom recognized and the relation of tabes and many other lesions of the central nervous system to the syphilitic process unknown, affords a valuable lesson. He is distinctly of the opinion that tabes to-day is a much milder disease than it was forty years ago, and furthermore that it offers by no means the utterly hopeless prognosis that was once involved in that diagnosis. This improvement is to be ascribed not less to the more thorough treatment of syphilis than to the more prompt and general recognition of tabes and consequent treatment at an earlier stage of the condition.

The lectures are enriched by numerous illustrative cases drawn from the author's large experience.

P.

PLATE XXVIII.—To Illustrate Dr. John T. Bowen's Article.

Acute Infectious Pemphigus In A Butcher.

THE JOURNAL OF
CUTANEOUS DISEASES
INCLUDING SYPHILIS

VOL. XXII. JUNE, 1904. No. 6

ACUTE INFECTIOUS PEMPHIGUS IN A BUTCHER, DURING AN EPIZOOTIC OF FOOT AND MOUTH DISEASE, WITH A CONSIDERATION OF THE POSSIBLE RELATIONSHIP OF THE TWO AFFECTIONS.

By JOHN T. BOWEN, M.D., Boston.

Physician for Diseases of the Skin, Massachusetts General Hospital; Assistant Professor of Dermatology, Harvard University.

IT will be remembered that an epizootic of foot and mouth disease prevailed in New England during the winter of 1902-3. Its discovery was made in November, 1902, although it is probable that the disease had existed for several months before.

On November 25, 1902, there entered the Massachusetts General Hospital a man whose cutaneous lesions at once aroused interest, in view of the prevalent epizootic. He was admitted in the service of Dr. R. H. Fitz, with whom I had the privilege of seeing the patient in consultation, and to whom I am indebted for permission to use his records, as well as for his valuable suggestions.

The patient, a native of Prince Edward's Island, was thirty-five years old, married, and a resident of a Massachusetts city. Nothing of importance was obtained from his family history. He had had measles in childhood, typhoid fever at twenty-six, and he had been a regular drinker, although not to great excess. His work was that of a wholesale meat-cutter, and he stated that he often received cuts on his hands from his occupation. About three weeks ago, he received several cuts on his right hand, which soon after became swollen, and the apparently septic lesions were repeatedly opened by a physician and dressed with sulpho-naphthol. At nearly the same time

that the lesions appeared on the hand, he began to have an affection of the nose, which was greatly swollen and crusted, so that the nostrils were completely occluded. About eight days ago, there appeared, at first on the head and ears, multiple yellowish "blisters," which had steadily extended over the body up to the present time. There was considerable prostration and great discomfort from the extent of surface affected. He was vaccinated three months ago, but no reaction or soreness in the axilla followed.

Upon admission, a thorough routine examination was not made on account of the patient's condition. No signs were found in the lungs in front; heart apex beat in fifth space one inch inside nipple; the area of dulness was not enlarged; sounds regular and of good quality, no accentuation of the second sound, no murmurs; pulse was regular, of good volume and tension; the spleen was not made out to be enlarged.

The integument was covered with large and small bullæ on an uninflamed base, often sharply raised and very tense, distributed over the trunk, extremities, neck, and scalp. Upon the scalp many of the lesions had dried into crusts, which were often hæmorrhagic. Upon both ears there were hæmorrhagic crusts of considerable size, besides purely bullous lesions. There was crusting and occlusion of the nostrils, especially of the right nostril. The end of the nose was very hyperæmic and showed the remains of crusts. There was a crust upon the lip, showing the remains of a bulla, but it had not, apparently, extended to the mucous membrane of the mouth. On the sides of the neck, abdomen, back and thighs, there were numerous bullæ from half an inch to an inch in diameter. Some of the bullæ had ruptured, leaving small areas of skin denuded of epidermis. There were but few lesions on the chest. In the groins, there were diffuse areas of denuded skin. On the front and back of both hands and on the fore-arms there were bullæ and areas of denuded skin, circular, oval, or irregular in outline, from one to two inches in diameter. Upon the back of the right fore-arm there were distinct signs of lymphangitis, extending up the arm. Along the line of this lymphangitis a number of small bullæ were apparent. There was no especial adenopathy. His temperature upon admission was 101, pulse 120, respiration 24. Examination of the blood showed hæmoglobin, 80 per cent.; white corpuscles, 7,500. A differential count of 200 cells gave small basophiles, 10 per cent.; large basophiles, 6 per cent.; neutrophiles, 76 per cent.; and eosinophiles, 6 per cent. The urine was high, acid, specific gravity 1,026,

albumen absent, sugar absent, bile absent, diazo absent, chlorides normal, urea 2.65 per cent. In the sediment there was considerable squamous epithelium and a small amount of cells. In the bullæ, the serum contained rare epidermic cells, no eosinophiles, and a few diplococci. The patient was put on boracic ointment dressing and house diet.

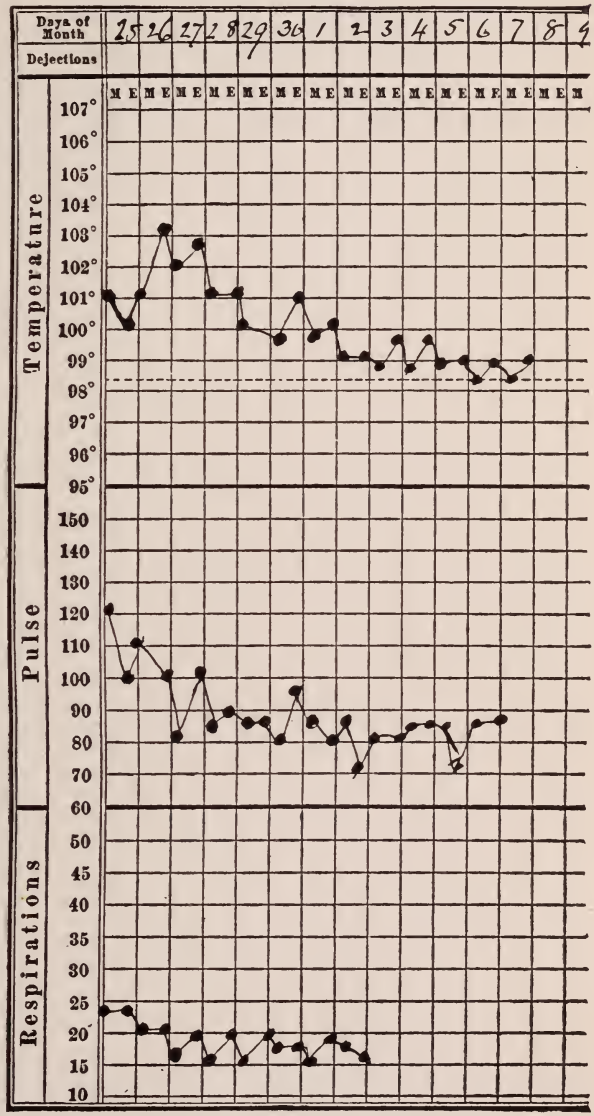

November 26. The temperature had risen to 103 degrees. The nose was completely occluded with hæmorrhagic crusts, and much discomfort was experienced from the large extent of denuded skin.

November 28. The temperature had been falling. The patient was more comfortable. No new lesions had appeared, and most of the older ones had ruptured. Bacteriological report of a culture taken from the lesion in the nose stated that innumerable colonies of staphylococcus pyogenes aureus and the streptococcus pyogenes were found. Citrate of silver ointment, one to two hundred, was tried as a dressing for the body. From this time on, the patient made an uninterrupted recovery, and on the sixteenth of December, was discharged from the hospital well; all the lesions

healing kindly, and no new ones appearing. His temperature, as will be seen by the chart, soon regained the normal.

In this case we have an acute bullous eruption evidently due to an infection from a wound in a man whose occupation was that of a butcher and who had received a cut while engaged in his work. On examining the literature, it will be found that a considerable number of similar cases have been reported, in a large number of which the occupation of the patient was that of a butcher. The most valuable contribution to this question is that of George Pernet, who published in the *British Journal of Dermatology* for May and June, 1896, an article entitled "Acute Pemphigus; a Contribution to the Etiology of the Acute Bullous Eruptions." His own case was that of a butcher of thirty-two, who developed an intense bullous eruption after a wound of the finger, accompanied by severe constitutional symptoms, high fever, and lesions of the tongue and lips; the affection ran an acute malignant course and ended with the patient's death four days after admission to the hospital. Pernet was able to collect from the literature seven similar cases, all of whom were butchers and actively engaged in their work. The age was from seventeen to thirty-three. In four cases there was a distinct history of a wound of the fingers made in the course of their work. The disease was rapidly fatal in six of the eight cases in an average period of two weeks. In three of the cases there was a history of alcohol. In all of the cases there was a high temperature, often decreasing for several days before death. In three of the cases, the wound had been inflicted three months, five weeks, and two months, respectively, before the eruption appeared. Hence it is assumed that the period of incubation is probably a long one, although it is impossible to say whether the infection took place at the time the wound was inflicted or subsequently. The eruption rapidly became general in all the cases and gave rise, when fully developed, in most cases, to an intense fœtor. The affection was in all cases purely bullous, the bullæ being usually of large size and often surrounded by an aureola. In some of the cases there were hæmorrhagic bullæ. It is noted that the mouth, palate, eyes, and nostrils were almost always more or less affected. A post mortem examination was made in three cases, but without throwing any light upon the etiology.

Besides these cases of acute bullous eruptions in butchers, Pernet was able to collect eight similar cases in people who were not butchers. In one case the patient was a tanner, who had infected his finger some weeks previously, and who died of what was described as malignant

pemphigus. In another case the disease was contracted from milking some cows which had a bullous eruption on the udders and teats. This case ran an acute course, but the patient recovered. In all these cases collected, the occupation of the patients brought them into contact with animals or animal products. Three of these cases were rapidly fatal.

In a bacteriological examination of Pernet's case, Bullock isolated from the contents of the bullæ a diplococcus resembling the gonococcus, but somewhat larger, which stained well by Gram's method and by hydro-alcoholic aniline stains. Previous to this, Demme had obtained pure cultures of a diplococcus from a case of acute pemphigus; and a similar organism was later described by Dähnhardt in a case of chronic pemphigus, which threw some doubt upon the etiological importance of Demme's discovery in acute pemphigus. Bullock regards his diplocccus as probably identical with that of Demme.

Pernet concludes as follows: 1. That there is a group of rare cases of acute bullous eruption, accompanied by severe constitutional symptoms, and generally terminating fatally, which affects butchers. 2. The disease follows a wound on the hands or fingers. 3. It is probably due to a micro-organism. 4. The same infectious disease probably occurs in other persons who are brought into contact with animals or animal products.

Whipham[1] reports two cases of acute pemphigus, one in a child who had been scratched by a cat five weeks previously and who had developed a wound at the site of the scratch. The child died. The sceond was that of a woman which followed a wound of the finger. In the child's case a diplococcus similar to that of Demme was found in the contents of the bullæ during life, and similar organisms in the lungs after death. Pure cultures injected hypodermically into guinea pigs or mice caused death.

Hadley and Bullock[2] report a case of a butcher of twenty-three who had wounded his finger while dressing the carcass of a sheep. Three or four days later bullæ appeared on the chin and anterior nares, still later on the tongue and roof of palate, finally becoming general. The case terminated fatally. In this case, also, diplococci resembling those of Demme were found in the serum, although they do not consider that this organism has been shown to be the cause.

Allen[3] has reported a case of acute, fatal pemphigus in a blacksmith.

[1] *The Lancet.* May 2, 1896.

[2] *Lancet.* May 6, 1899.

[3] Journal of Cutaneous and G. U. Diseases. April, 1888.

Brocq, in the third volume of *La Pratique Dermatologique, Paris,* 1902, under the article "Pemphigus," after referring to some of the literature, concludes that there exists at least a score of incontestable cases of an affection worthy of the name of "*pemphigus aigu, grave, fébrile, à forme infectieuse.*" Two facts of importance stand out in the etiology. First, the occupation of most of the patients, who were either butchers or persons who handled dead animals. This point, first accentuated by Pernet, Brocq declares that he had previously noted. Second, that many of the cases have had a wound on the hand previous to the appearance of pemphigus, through which the infection had undoubtedly taken place.

Hallopeau and Levy[4] report the case of a butcher of sixty who entered the St. Louis Hospital in November, 1897, affected with acute pemphigus. The bullæ were situated mostly in the axillary and inguinal regions and on the limbs; there were few on the trunk and head. No eosinophilia. The patient recovered in about eight weeks.

From the foregoing résumé of the literature, no doubt can remain that there exists an acute, febrile form of bullous dermatitis, caused by the infection of a wound, and occurring usually, if not always, in butchers or people who have to do with animal products. Furthermore, that this disease runs a rapid course, and that the mortality is very high. It will also be conceded by all that the case I report belongs, undoubtedly, in this category. It is certainly a rare affection, and few, if any, cases, have been reported in America, with the exception, possibly, of that of Allen, which occurred in a blacksmith.

It is very interesting, in this connection, to compare with these cases of infectious pemphigus the series of cases of acute bullous dermatitis following vaccination that occurred in Boston during the spring of 1902, ten of which were reported by Doctor Howe.[5] These were all cases of bullous dermatitis and all but one occurred in people who had been recently vaccinated. The average duration of the disease was six weeks from the time the first skin lesion appeared until death or recovery took place. Six of the ten cases reported by Howe died, as did several other unreported cases. The skin lesions began to appear, on an average, five weeks after vaccination, although in one case sixteen weeks had elapsed. The parts most often affected were the back of the neck, the region between the shoulders, the axillæ, buttocks, and inner aspects of the thighs, and there was a decided

[4] *Annals de Derm. et Syph.* 1898, p. 61.

[5] Journal of Cutaneous Diseases. June, 1903.

tendency to grouping. It is to be noted that in almost all these cases the mucous membrane of the mouth and throat was very much affected, many of the patients being unable to swallow on account of the bullæ and ulcers in these situations. Corresponding lesions were also found in the trachea.

In studying this series of cases following vaccination, many of which were seen by the writer, it is difficult to escape the conclusion that they belong in the same class with the case reported at the beginning of this paper, and with the acute, infectious pemphigus of butchers and people who have to do with animal products. The question naturally arises whether there is any ground for supposing that there may be a common etiology.

Turning now to the subject of foot and mouth disease, as it occurs in animals and in men, Frothingham[6] states that it is the most contagious disease known among animals, although the method of infection is often obscure. In cattle it has an incubation period of from two to five days, on an average, when the animal becomes dull, loses appetite, and shows signs of salivation. There is a sharp rise of temperature, and in a few days vesicles appear upon the muzzle, inside the lips and cheeks, on the tongue, or on any part of the mouth. The vesicles soon rupture, leaving erosions and superficial ulcers. In uncomplicated cases, recovery takes place quickly, and is complete in from two to three weeks. The feet are also involved in some cases, so that there is great difficulty in walking. Vesicles not infrequently appear upon the teats and udders. Occasionally there are gastro-intestinal disturbances, and vesicles and ulcers have been found in the gastro-intestinal tracts. The mortality is very low, only from one to five per cent., except in very young animals. Although much work has been done, and is still in progress, the true nature of the infection is unknown.

With regard to the occurrence of foot and mouth disease in man, comparatively little is to be found in most text books or in general medicine on this subject, although veterinary publications contain numerous references to it. Nocard and Leclanche[7] state that the contagiousness from animals to man was first reported by Segar in 1765, and has since been amply verified. In 1834, three Prussian veterinarians experimentally drank milk from infected cows, and developed bullæ in the mouth and on the hands. It has been produced by eating

[6] *Boston Med. & Surg. Journal.* Jan. 1, 1903.
[7] Paris, 1903.

butter made from the milk of infected cows; and in these cases there were vesicles usually in the mouth and on the cheek.

In the fifth volume of Ebstein and Schwalbe's *Handbuch des praktischen medicin*, Nicolaier deals quite fully with the literature of foot and mouth disease in man. The period of incubation is usually short, from three to five days, although, as will be seen later, this has been much prolonged in certain epidemics. The affection begins with constitutional symptoms, headache, backache, and malaise. As a rule there is moderate fever. After several days, in cases where the poison has entered by means of the mucous membrane of the throat and mouth, there begin to be changes of the mucous membranes of the lips, cheeks and tongue, in the form of vesicles and bullæ. After a day or two, these lesions break, leaving superficial ulcers and erosions, which cause great discomfort. In many instances there are manifestations upon the skin coincidently with those upon the mucous surfaces. These are usually in the form of small vesicles which finally become pustules. They are seldom situated upon the face, but are usually on the fingers and occasionally on the feet.

If the infection has taken place through an abrasion of the skin, as is often the case in milking, or in slaughtering diseased animals, the eruption appears first at the place where the poison has entered. Apart from the serious epidemics to be referred to later, foot and mouth disease in man usually runs a short and mild course, the average duration being from two to three weeks.

An important contribution to this subject is that of Siegel[8] who describes an epidemic in Britz, near Berlin, which occurred from 1888 to 1891, when foot and mouth disease was epizootic in Germany, in which two-thirds of the people were affected, with a mortality of three per cent., fifteen children and twenty-one adults. The majority of the cases ran a mild course with an incubation of from eight to ten days, beginning with chills, pain in the back, and slight fever. In from three to five days, they began to have inflammation of the mucous membrane of the mouth, swollen tongue, gums and jaws, and then vesicles appeared on the tongue and lips and corners of the mouth. These spread somewhat over the body, occasionally accompanied by purpura. In about a quarter of the cases there were severe complications. In some cases the tongue became greatly enlarged and later ulcerated. There was often salivation, and sometimes hæmorrhage from the stomach and intestines. In certain cases there was

[8] *Deutsche Med. Wochensch.* 1891.

a very extensive purpura. In some of the cases that ended fatally, there was a general outbreak of bullæ over the whole body, especially marked on the palms and soles. The heart was sometimes affected, and occasionally there were convulsions and tetanus. In several cases direct inoculation from an infected subject or from some utensil could be proved. A bacillus was cultivated from the internal organs, which, inoculated on pigs in pure culture, caused death, with the appearance of bullæ and petechiæ, especially of the mouth. When inoculated upon cows, foot and mouth disease was produced.

Siegel thinks the relationship between foot and mouth disease in animals and in man is the same as that existing between vaccinia and variola. In other words, that the disease in animals is a weakened form of that of man. In support of this, he shows that those who had the most intimate contact with the cattle in this epidemic were most lightly affected, and that there was no case of direct contact among those who died. He believes that the infection of man with the virulent form can occur only from man to man.

Epstein,[9] commenting on this epidemic, raises the question whether it is not probable, in view of the extraordinary character of many of the cases in this epidemic, that some other infectious material was at work in addition to that of foot and mouth disease.

Hulin has reported an epidemic in which of 1,000 inhabitants of a village, 23 died.

From the foregoing, it will be seen that here and there cases that have been considered foot and mouth disease in man, run an acute, infectious, and often fatal course. The symptoms in some of these cases resemble closely those present in the acute pemphigus of butchers and in the epidemic reported by Howe. Can we point with any probability to an etiological relationship between the foot and mouth disease of animals and these severe infectious forms of bullous dermatitis in man?

An important fact, brought out during the summer of 1903, may or may not have a bearing upon this interesting question. A full report of this occurrence will be found in the Fourth Semi-Annual Report of the Chief of the Cattle Bureau to the Massachusetts State Board of Agriculture, by Dr. Austin Peters, which has just appeared. Dr. Peters deals very fully with the epizootic of foot and mouth disease which prevailed during the winter of 1902-3. In August, 1903, several months after the last cases of foot and mouth

[9] *Deutsche Med. Wochenschr.* 1896, Nos. 9 and 10.

disease had been reported, a fresh outbreak occurred in the town of Wakefield. This resulted from some experiments which were being made by Dr. E. E. Tyzzer, Assistant Pathologist at the Harvard Medical School, upon calves, in the study of vaccinia. The extremely interesting report of Dr. Tyzzer, which is embodied in that of Dr. Peters, may be briefly referred to. Dr. Tyzzer states that, being engaged in the study of vaccinia with reference to its pathology, he bought several calves and kept them in a portion of his father's barn. It was intended to vaccinate these calves on various parts of the body, and to kill them at different intervals of time in order to obtain the lesions. The virus used was obtained from a vaccine establishment, and except at times when it was used for vaccination, it was kept in a refrigerator. Three calves vaccinated on July 31, sickened and died on August 4 or 5. The vaccine lesions were developed in all cases. Two other calves, which had not been vaccinated but which had been kept in the same stable, also died with the same symptoms a few days later. There was found a slight hypostatic congestion of the lungs in two of the calves; and in three of them there were opaque patches on the upper surfaces of the tongue, which were quite prominent during life. These lesions were limited generally to the epithelium, which had become necrotic over a considerable area. Twelve days after the death of the last calf, one of four cows, which were kept in the stable below, began to show lesions of the tongue and mouth, and later on vesicles developed on the feet. The following day, symptoms appeared in the other three cows. On account of these remarkable happenings, experiments were instituted, in a specially selected barn in another town, where the same virus was employed as in the first experiments. The vaccinia lesions developed in the usual manner except that on the fourth day bullæ appeared on the inner border of the vaccine lesions of the lip in all three calves. The fluid from these bullæ, when rubbed into the mouth of the cow, produced typical symptoms of foot and mouth disease, and this was carried to two other cows in the same barn which were not inoculated.

Tyzzer concludes that, after these experiments, there is no question that the disease originated from the vaccine lymph used in the inoculation. Further experiments were undertaken to determine whether vaccinia thus presented itself in an unusual form, or whether it was present together with another disease in the case of the cows. It was found that the mouth lesions and the vesicles occurring on the udders showed a special type of necrosis distinct from vaccinia; and

it was found that cows which had been affected by this disease were not immune to vaccinia. It was also shown that the lymph from these vesicles would not produce vaccine lesions in a rabbit's cornea.

In commenting on Tyzzer's report, Dr. Peters considers it possible that this accidental discovery may be the solution of the original outbreak. It was ascertained that a vaccine company was in the habit of occasionally using a few "control" points of virus placed on the market by other producers in order to compare theirs with others; and in 1902 they used the product of six different American manufacturers of vaccine, among others that from which Dr. Tyzzer's supply was obtained. As this company was in the habit of turning over the cattle they had used for inoculation to the farmer upon whose premises the outbreak of foot and mouth disease first appeared, it seems more than probable that the outbreak of foot and mouth disease may have been started by the inoculation of impure vaccine virus. Dr. Peters concludes that as the foot and mouth disease prevails extensively in France, Austria, Italy and Switzerland, and also, in less degree, in other European countries, it seems not impossible that the disease was imported from Europe in some fresh virus brought over to some vaccine establishment in the United States to renovate a product that was losing its vitality.

Whether or not the outbreak of foot and mouth disease in New England was started by the inoculation of impure vaccine virus, the work of Dr. Tyzzer proves conclusively that foot and mouth disease may be disseminated by means of vaccination, and that this actually occurred in the summer of 1903. We know of a well defined bullous affection which occurs in butchers and people who have to do with animal products, and which is very often fatal. We know that another series of cases with similar symptoms occurred in Boston from January to June, 1902, just before the outbreak of foot and mouth disease, in people of varying occupations, but who had all been vaccinated. In both of these series of cases there is abundant reason for the belief that the process was an infectious one, and caused by animal virus. What grounds are there for the supposition that foot and mouth disease may be in any way a factor in these cases?

As has been stated above, foot and mouth disease both in animals and man is usually mild and the symptoms are trivial. It is only in the epidemics, as reported by Siegel and Hulin, that cases of a severe or fatal form appear, and of these, as has been seen, only a certain number resemble the cases of acute pemphigus in butchers and fol-

lowing vaccination. With regard to the period of incubation it will be noted that foot and mouth disease usually declares itself much more quickly after infection than does acute pemphigus, which has a longer period of incubation as a rule. Nor is the localization of the eruption upon the hands and feet at all marked in acute pemphigus. On the other hand it will be noted that the mucous membrane of the mouth and nose is very frequently the site of lesions in acute pemphigus, as is the rule in foot and mouth disease. It would seem that there is sufficient resemblance between foot and mouth disease and acute pemphigus to warrant the belief that they belong in the same group of affections, and that they may possibly be allied. It is possible that some forms of animal virus may be rendered virulent by transmission through certain individual animals and not through all, thus producing a type of disease at variance with the original. The epidemic of acute pemphigus following vaccination began and ended before the outbreak of foot and mouth disease occurred, but the latter disease is believed to have been present some time before it was discovered, and Tyzzer's experience demonstrated that it was lurking in vaccine virus much later. It is also interesting to note that the first three calves inoculated by Tyzzer died, an uncommon occurrence in foot and mouth disease as a rule.

Upon the whole it must be admitted that we have not sufficient evidence to prove that the virus of foot and mouth disease was concerned in the etiology of the case reported in this paper nor with the bullous dermatitis following vaccination. It must be admitted, however, that there are many interesting similarities about the two occurrences, and the possibility of a relationship is far from a remote one.

In conclusion, I may be permitted to refer to a series of cases published by me under the title "Bullous dermatitis following vaccination and resembling Dermatitis Herpetiformis."[10] Six cases were reported occurring in children, and beginning from two weeks to a month after vaccination. The vesicles and bullæ were situated especially about the mouth and nose, wrists and forearms, ankles, and genitals. The affection was in some cases very persistent and recurrent, in one case lasting for several years. In none of the cases were there any constitutional symptoms nor was itching a pronounced feature. It was remarked at the time that these cases bore a strong resemblance to dermatitis herpetiformis, but that owing to the lack of unanimity of opinion as to the proper limits of this affection, and

[10] Journal of Cut. and G. U. Diseases. Sept., 1901.

to the peculiar features of these cases, it would be well to leave the question of their classification open. Since then I have seen three other cases in children and one similar case in an adult following vaccination, and two precisely similar cases in children *not following vaccination.* It was stated at the time that there was no positive proof that these cases were caused or influenced by the vaccination, and the fact that two precisely similar cases have since been observed that did not follow vaccination would accentuate this statement still more. I feel sure that this group of cases in children is quite distinct from the acute pemphigus that has just been discussed. The latter is a febrile infectious disease running an acute course. The former is a chronic affection, with frequent exacerbations, and without constitutional symptoms. Upon the whole it seems to me that these cases of recurrent chronic bullous dermatitis in children represent a variety at least, of dermatitis herpetiformis, and that it may be assumed that vaccination is one of many exciting causes. There is no reason for supposing that an infectious agent is inoculated in these cases of bullous dermatitis following vaccination in children. In acute pemphigus no other theory seems tenable.

PRELIMINARY NOTE RELATIVE TO THE MORE EFFICIENT UTILIZATION OF THE SPARK-GAP RADIATIONS.

By Henry G. Piffard, M.D., LL.D.

Read before the New York Dermatological Society, April 26, 1904.

IT was long ago ascertained that the radiations from a condenser-spark contained a relatively larger proportion of ultra-violet than any other natural or artificial source. So far as I am aware this fact was first utilized with therapeutic intent by Goerl, of Nuernberg, who used aluminum terminals with four spark-gaps. Later, a London manufacturer placed on the market a lamp with iron terminals and one spark-gap. Still later (1902), the writer introduced the lamp (iron terminals, three gaps) which bears his name.*

The ultra-violet rays, according to the dicta of physicists, are absorbed by glass, but are freely transmitted by quartz. It is also

* Exhibited at the N. Y. Academy of Medicine, Feb. 19, 1903. See *Medical Record,* Mch. 7, 1903, and Jan. 23, 1904.

stated that they will discharge an electroscope carrying a negative, but not a positive charge.

So far as I am aware there has been no accepted definition as to the spectrum limit of the ultra-violet rays. Commencing at the upper end of the visible spectrum with wave length of about 0.38 *micron* they extend still further upward for an indefinite distance. X-rays have a wave length approximating 0.02 *micron* while the *gamma* rays of radium are undulations of greater velocity and correspondingly shorter wave-length. What, now, is the character and what the functions of the radiations that fall between these extremes? Hertz, it is true, speaks of the "Hyper Ultra-violet," but without definite limit or characterization, but there still appears to be a gap that has not as yet been definitely mapped.

In view of the foregoing, some experiments recently made appear

Fig. 1. The author's spark-gap lamp.

to me to be of some importance as regards the practical application of spectrum and other radiations to the treatment of disease.

Briefly, they are as follows: If the spark lamp, actuated by a coil and with the customary quartz plate *in situ*, be applied to a piece of photographic printing paper (solio) and kept in contact for thirty seconds, the paper will be very greatly darkened. If now the experiment be repeated with the quartz removed, the active effect on the paper will be somewhat greater. Roughly estimated by the eye the difference in the two prints will hardly exceed 15 per cent. From this experiment we find that of the total radiations capable of decomposing the silver salt, 85 per cent. are able to traverse the quartz (1.25 mm. thick), while 15 per cent. are absorbed by it and fail to reach and affect the sensitive film.

The photographic test, however, is not the only means at our disposal whereby we may analyze the radiations from the spark-gap.

If an electroscope be charged negatively I find that the lamp will discharge it in ten seconds with the quartz plate *in situ*, but if this is removed will discharge it in less than a second. In other words, of the total radiations capable of affecting the electroscope, 90 per cent. are absorbed by the quartz plate, while but 10 per cent. of them succeed in penetrating it. The corollary of this is plain. When the quartz plate is interposed we thereby sacrifice nearly the total energy of this class of radiations (i.e., those affecting the electroscope). With the usual quartz compressors, some of which are 10mm. in thickness, we are virtually throwing these radiations entirely out of commission.

It is evident from the foregoing that the radiations from the spark-gap belong, so far as these manifestations of their energy is concerned, to two distinct classes: those that specially affect the photo-sensitive film, and those that affect the electroscope.

As to the nature of the first named we need have little doubt. They are transverse undulations belonging to the ultra-violet portions of the spectrum.

To what class, then, do the other rays belong, those which so prominently affect the electroscope and the greater part of which are absorbed by quartz? To this question I am unable at the moment to give a definite answer. To determine this point positively it is necessary to have the trained knowledge of the physicist and the instruments and conveniences needed for the research. As I possess neither the one nor the other, I can only speculate as to the nature of these rays and speculation has led me to the provisional conclusion, or rather hypothesis, that they belong to the same order of radiations as the cathode rays of a vacuum tube, or the *beta* rays of radium—in other words they are negative electrons. Up to a very recent period physicists have declared that the cathode rays of a Crookes' tube, being wholly absorbed by the glass, did not emerge from it. To-day, however, Sir Oliver Lodge states positively (*Archives of the Roentgen Ray*, April, 1904), that some of them at least do emerge, confirming a belief that I have long held.

The radium *beta-rays* (negative electrons) pass through glass and Williams' experiments (*Med. News*, Feb. 6, '04), seem to indicate that they are the chief factor in the production of the radium reaction.

Assuming for the moment the truth of my hypothesis, that the rays affecting the electroscope are negative electrons (and not ultra-

violet undulations), I believe their velocity will be found to be much less than the cathode rays of the vacuum tube and still less than the unimpeded *beta* rays of radium.

In further confirmation of my hypothesis I find that the radiations from the condenser spark discharge the electroscope when carrying a positive charge, which would not be the case if they were purely ultra-violet undulations.

Freund, referring to the period of latency that intervenes between the time of impact of the spectrum rays and the appearance of cutaneous reaction, lays down the law that this latent period varies *inversely* with the wave length of the impinging ray; or, as I would prefer to state it, varies *directly* with the frequency of the undulations.

If this also holds good as regards the velocity of electrons it would lead us to expect the cutaneous reaction to appear more promptly than with either the Crookes' tube or with radium. I further antici-

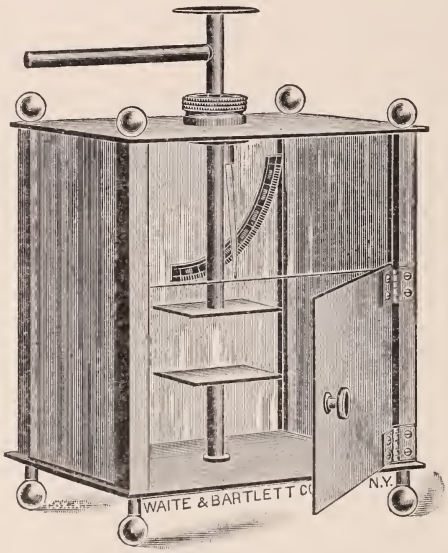

Fig. 2. The author's electroscope.

pate that the character of the reaction will resemble that which follows the use of a "soft" X-ray tube.

In testing these radiations on cutaneous lesions, all idea of compression must, of course, be abandoned, and the skin be rendered anæmic by the use of adrenalin in the manner formerly proposed by me.

The experiments here related were made with the writer's spark-

lamp, with suitable condenser, actuated by a W. and B. coil, rated at 12 inches, and a Wehnelt interrupter adjusted to give about 5½ amperes through the primary, and an electroscope specially constructed for me.

The matter is now before you. Two questions remain to be settled, namely: What is the nature of the rays and to what useful ends can they be applied? The first is for the physicist, the second is for us as clinicians to ascertain.

DERMATITIS EXFOLIATIVA NEONATORUM OR RITTER'S DISEASE.

By Arthur J. Patek, A.B., M.D., Milwaukee.

Lecturer on Diagnosis, Wisconsin College of Physicians and Surgeons. Physician to Milwaukee, Children's, Mt. Sinai and the Emergency Hospitals.

In 1878 Professor Ritter von Rittershain published in the *Central Zeitung für Kinderheilkunde*, 1878, Bd. 2, under the title "Dermatitis Exfoliativa Neonatorum," a clinical sketch of a hitherto undescribed skin affection of the newborn. The opportunity for a very close study of the disease was certainly offered, for in the decade from July 1868 to 1878, two hundred and ninety-seven cases came under Ritter's observation. Not without vigorous protest, however, was Ritter able to maintain the identity of his newly-named disease, and a spirited controversy arose between him and Behrend—the latter maintaining Ritter's disease to be identical with pemphigus foliaceous. This Ritter denied in a very acrimonious article, and showed many points of dissimilarity between the two affections. Kaposi conceded the non-identity of the diseases, but denied Ritter any priority in their discovery, claiming that the condition had been previously described by various other authors. Be this as it may, the credit of making the discovery more generally known through the publication of a detailed record of a large number of cases observed during a period of ten years—belongs to Ritter, and, therefore, the name "Ritter's Disease" is not undeservedly coupled with the disease which he himself styled, Dermatitis Exfoliativa Neonatorum.

(In Ritter's first report of the disease he called it Dermatitis Erysipelatosa, but later changed the name to Dermatitis Exfoliativa Neonatorum, this being more descriptive of its leading characteristics.)

The majority of Ritter's cases occurred during the second week

of the infants' existence, some at the end of the first, and a constantly diminishing number from the second to the fifth week.

So few examples of this rare and interesting disease have been reported (I have record of about twelve or fifteen), that it will be worth while to detail its symptoms, characteristics and course, and for this purpose I can not do better than follow out the plan of Ritter's original article.

The following stages of the disease are recognized:

1. Prodromal.
2. Erythema (hyperæmia) and exudation.
3. Exfoliation and exsiccation.
4. Regeneration of epidermis with desquamation.
5. Furunculosis and abscess formation.

The prodromal stage consists in a dryness of the skin and desquamation of branny scales. This stage usually follows the completion of the normal desquamation of new born infants, though independent of it.

Erythematous stage. This varies much in degree. It usually begins in the lower half of the face and about the mouth. The redness may be faint, but usually deepens and may be followed by a generalized erythema. At the same time rhagades form at the corners of the mouth, and soon the mucous membrane of the mouth shows characteristic appearances: it is hyperæmic, miliary plaques are present, and on the palate are large irregular patche s of denuded epithelium covered with a grayish white exudate. The turgescence of the skin continues, and parts previously free are involved—the extremities being the last to be affected. In the meantime progress is made at the original seat of the eruption, and often the process has become advanced in the face before the trunk and extremities have become erythematous.

Stage of exfoliation. Marked changes occur in the face. The hyperæmic areas give way to a formation of crusts and frequently rhagades radiating from the corner of the mouth. While these changes are in course of development progress is made on the trunk; the epidermis becomes somewhat thickened and is raised from the cutis. Vesicles may form separating the epidermis from the cutis, though this varies with the depth of the hyperæmia, i.e., where the skin has been profoundly hyperæmic large areas of epidermis are undermined by the serum and raised from the deeper layer even without the formation of much serum. The epidermis becomes dull in color, is

wrinkled into folds and is easily torn off at the slightest contact. In places the epidermis may separate itself from the cutis even without the exudation of any appreciable quantity of serum into the two layers. The almost denuded cutis is dark red and raw-looking, but soon dries and becomes dull, shreds of dry and dead epidermis clinging to the denuded surface. A thin yellowish scab may develop on these areas. The process extends to other parts, the same exfoliation of epidermis following on the neck, breast, back and abdomen. Wherever the hands touch the body at all forcibly, the epidermis is loosened, wrinkles into folds, and leaves the cutis exposed or covered with a non-protecting dead outer covering. The appearance is that of an extensive superficial burn—so complete is the maceration and exfoliation. The whole body is not always involved, for with great care in handling the infant some areas may remain intact. The extremities are usually affected last, and not so severely as the trunk. The hands and feet, however, suffer profoundly, and their entire surface may be laid bare—the epidermis stripping off like a glove and leaving the same moist raw surface as on the trunk. Various stages will now be present in different areas: beginning drying of the epidermis, a loosely lying covering, freshly denuded surface, and the paler red and dry areas of earliest involvement. In the epidemic observed by Ritter, the disease did not always follow the same course; at times the face was involved late in the course of the disease, and in place of being prominent in its symptoms, was only mildly affected. In other cases the initial dry scale formation and the localized or generalized hyperæmia usually so constant were insignificant or absent, though the desquamation of the epidermis of chest, shoulders, etc., went on, but with apparently less severity. In some cases thickly sown miliaria-like vesicles formed on the hyperæmic areas, in advance of the exfoliation, while in others larger vesicles developed—some oval, some ragged in outline, coalescing, leaving the cutis denuded as in the more typical cases. Occasionally an eczema-like appearance formed on the erythematous skin in advance of the separation of the epidermis.

The denuded surfaces desiccate and regenerate and in the order of their onset. The skin loses its raw, moist appearance, the deep red changes to a lighter pink, dry branny scales develop, and the regeneration of the epidermis is a rapid process, the skin having a hard parchment-like feel. This whole process rarely lasts longer than from seven to ten days, and in some cases hardly a week elapses from the first onset of hyperæmia to the formation of normal regenerated epidermis.

As sequelæ may be mentioned: dry, branny, or more extensive eczematous conditions, furuncles, abscesses, and phlegmonous infiltrations.

The general symptoms, when complicated by pneumonia, diarrhœa, etc., are often very mild, the febrile and nutritional disturbances being frequently of light character.

In the differential diagnosis we must consider pemphigus foliaceous, acute pemphigus, and syphilis.

Pemphigus foliaceous is a disease of long duration requiring months to become generalized, usually occurring in adults, and frequently is the final stage of a pemphigus vulgaris. Acute pemphigus of the newborn does not begin with an erythema, there is healthy skin between the affected areas, the vesicles are clear cut, appear either singly or in crops, are often round and are outlined by a well defined inflammatory border, while in dermatitis neonatorum exfoliativa, even in those cases in which the erythema is absent, the exfoliating areas are rarely round, but ragged and irregular in outline and are not surrounded by a hyperæmic zone. And, furthermore, in the latter the epidermis wrinkles and becomes separated from the cutis without, in many cases, the formation of an appreciable amount of serum, much less without any vesicle or bullous formation. The latter is the chief characteristic of pemphigoid eruptions.

Syphilis runs a course so different from the disease under discussion that it need hardly receive more detailed consideration.

As to the etiological significance of this disease, its clinical history surely justifies its being considered septico-pyæmic in origin. Though as great an authority as Kaposi denies this and attributes the whole course of the disease to an exaggeration of the normal desquamatory reaction of the skin of the newborn, this ground certainly seems untenable.

The clinical history seems to certainly point to the septic nature of the malady, and if we add that Ritter found the disease occurring in epidemics in his foundling asylum, the evidence is complete. There can also be no doubt of its infectious character, though Ritter has much evidence to show that contagion plays no part in its propagation. He believes the infection to be analogous to the puerperal variety.

Bacteriological evidence—a practically unborn science at the time of Ritter's studies (1872-78)—is not now wanting to testify to the infectious character of the disease. This will be considered later.

History of a Case of Dermatitis Exfoliativa Neonatorum. Female infant, born July 6, 1900. Labor was normal, without special difficulty. Child was apparently healthy at birth and well developed and was covered with a moderate amount of vernix, and its skin was otherwise in a normal state. On the fifth day after birth a vesicle was noticed on the infant's neck. Then it was recalled that there had previously been an erythema at this spot. On the following day this had advanced to the chin, and at the same time, upon the removal of the child's shirt, a large flake of epidermis was torn away from under the right axillary region, leaving a bright red, angry, weeping surface. The further course of the disease was marked by the appearance of gradually enlarging vesicles near those first developed. From the chin development proceeded upon the face—sparing the forehead, and down over the chest, back, arms—both flexor and extensor surfaces, hands and fingers.

Upon my first visit, July 19th, seven days after the first appearance of the eruption, the condition was noted as follows: face with exception of forehead free from epidermic covering, raw-looking and moist; chest, back, arms—both flexor and extensor surfaces—hands and fingers, buttocks, genitalia, lower limbs—posterior more than anterior —are, with the exception of a few small normal skin areas between the large excoriated surfaces, entirely denuded. The left hand is much swollen, phlegmonous, and emits a very foul odor. The epidermis in some places is rolled up into thin white bands, and at other places as on the soles of the feet and the toes—while still in place—lies loosely and in folds. The skin of the abdomen and back is almost normal in a circular area, about three inches wide, there being but one denuded surface about the size of a quarter on the abdominal surface. Large pieces of skin, representing the epidermic covering of several square inches of surface, can be easily removed. The general picture resembles closely a severe and general scalding.

July 20. The face and chest have lost their raw and moist appearance, and, while still red, are dry, and a new epidermis seems to be in process of formation. A similar condition prevails in scattered areas of the body. There are several small scaly patches on the denuded surfaces of chest and left arm.

The mother handles the child with great gentleness, having observed that slight pressure upon any spot was at times sufficient to cause an exfoliation.

July 22. The epidermis about the soles of the feet, including

toes, is loose. There is an additional denuded surface on the back, about 1½ inches in diameter. A furuncle has developed on the little finger of right hand. Disagreeable odor emanates from whole body. Temperature, 103.5. Face is dry and shows a tendency to the formation of fissures.

July 23. Face and buttocks quite dry and have many shallow fissures; the epidermal covering of both hands is gone, the skin hung so closely that the mother drew it off as one would a glove. Temperature 100.5. Respiration, 50. Died, July 25, fourteenth day of disease.

Microscopic and bacteriologic examination. For these examinations the serum of the vesicles was taken with the observance of the usual precautions.

Several cover glass preparations of the serum, stained with fuchsin and methyl blue, were made. One specimen contains only multinucleated cells, all, with few exceptions, containing diplococci, which, in their grouping and morphology closely resemble gonococci. In another specimen the cellular elements are very few, but the plasma is full of individual diplococci most of which are identical in appearance with those just described. Many of these bacteria, however, are very minute, and at first sight look like staphylococci, but closer examination proves all to be diplococci. Morphologically they are the same. There is but little grouping in the fields of this specimen, though some are found in twos, threes, or in chains of five or six.

Cultures resulted as follows: Agar stab: surface covered with creamy yellow growth; round colonies on surface; growth following whole length of stab in an irregular formation, with serrated, radiating margins and downy lateral outgrowths.

Agar streak: prolific growth, thick, faintly yellow, granular.

Potato: creamy, yellow, granular and thick growth.

Bouillon: turbid, and faint sediment.

Blood serum: a twenty-four-hour culture developed small, round, coalescent colonies, pearly surface, some white, others tinged with yellow.

Stained specimens made from the latter culture show a diplococcus, morphologically like that found in the serum preparations, but very minute, the size being that of a staphylococcus and easily taken for such at first sight. A forty-eight-hour agar culture has a similar appearance, though in each field there are a few bacteria larger than their neighbors, and in these their diplococcal character is easily distinguished.

It is evident, therefore, that the intra- and the extra-cellular diplococcus found in the serum was reproduced in the cultures, though in its morphology as to size it had suffered some alteration.

I wish to compare with the above findings certain bacteriological data referring to Ritter's disease and to acute pemphigus of the newborn.

Riehl has found a mould with long mycelia in the vesicles of a case of Ritter's disease, and thinks this to be the causal agent.

Winternitz (*Archiv. f. Dermat. u. Syph.*, Bd. 43 and 44, 1898) reports three cases, in the blood of one of which a staphylococcus was found.

Various observations have been made upon the bacteriology of acute pemphigus neonatorum. Almquist has isolated from the bullæ a readily staining micrococcus, 0.5 to 1 micron in diameter, arranged in pairs, resembling staphylococcus pyogenes aureus, and differing only by its specific pathogenic power (typical vesicles were experimentally produced).

Strelitz obtained from the vesicles a micrococcus resembling staphylococcus pyogenes aureus, and inoculation into his own arm developed pemphigus bullæ.

There has recently been reported (*British Journal Obst.*, Dec., 1903) an epidemic of acute pemphigus neonatorum in which eighteen out of twenty deliveries by one midwife were infected. In the bullæ which were common to all these cases, the staphylococcus pyogenes aureus was found.

Demme has isolated a non-encapsulated diplococcus, 0, 8 to 1, 4 micron in diameter, usually occurring in pairs like the gonococcus. It was aërobic, grew on agar in white spherical colonies with club-shaped rosette-like out-growths.

It is evident from the comparison of the findings in the reported cases of Ritter's disease (including my own case) and pemphigus, that a diplococcus has been found in both diseases, the recorders remarking upon its resemblance to the gonococcus. More observers have, however, isolated a micrococcus that in two cases reproduced typical pemphigoid bullæ upon inoculation.

It is probable that there is some confusion in the diagnosis of the two diseases, because there is a similarity in the general appearance of both affections. It is, however, possible to make a correct diagnosis, and ultimately more uniformity in the bacteriology of the disease will doubtless be reached.

THE WARFARE AGAINST VENEREAL DISEASES IN GERMANY.

By Prof. E. Lesser, of Berlin.

Translated by A. D. Mewborn, M.D., New York.

ON the sixth of March, 1904, the second Congress of the *Deutschen Gesellschaft zur Bekämpfung der Geschlechtskrankheiten* assembled at Berlin, with a large attendance of native and foreign members. Besides the discussion of the regular order of business, there were two themes in the regular order of the day of considerable interest: namely, a motion by the Silesian branch, that a petition be sent to the Chancellor advocating an amendment to the *compulsory guardianship law*, to the effect, that, contrary to the former judicial decision of the supreme court (Kammergericht), the education by guardianship be extended to all children up to the age of eighteen years, who are mentally or bodily endangered, or who must be separated from their parents for educational reasons. The second cardinal point in the proceedings was a proposition for changes in the *educational pamphlet* (*Merkblatt*) of the German Society, in which shall be stated in a short and easily comprehended form, the nature and dangers of venereal diseases, the methods of spreading and the remedies by which they may be guarded against. This was particularly important since there had been opposition from some members to the recommendation in the circular of the employment of protective agents against disease in extra-conjugal intercourse; since these agents were not only without assurance of protection, but the recommendation of such protective agents was itself an allurement to extra-conjugal intercourse. The objections offered were not recognized by the majority of those present as sustained, and they considered that, at least, an additional recommendation of the protective agents was necessary.

The second Congress, then, marks an important step in the rapid advance of the German Society for Combating Venereal Diseases, Although founded in October, 1902, it now numbers nearly 4,000 members scattered over the entire German Empire. The organization comprises numerous local clubs and branches, about twenty in all.

This rapid success is all the more gratifying and worthy of acknowledgement, since the obstacles to be surmounted were unusually great. Venereal diseases, in all ages, have been burdened, on one hand, with the odium attached to the practice of illicit intercourse,

and on the other, with the reluctancy of the people to speak of these subjects. These two facts have brought on all the unfavorable circumstances from which an effective warfare has hitherto suffered in such an extraordinary manner. No one dared to speak openly of these diseases or of the necessary laws affecting them. These circumstances explain well enough, but do not justify the reluctance of the authorities to take notice of these conditions in an energetic manner. And so it happened, that in spite of the great progress which has been made by medical science in the diagnosis and treatment of venereal diseases in the second half of the past century, nothing essential in any way corresponding to this great advance had been accomplished in prophylaxis.

Hence it was apparent to the men who took the lead in this movement, that the first and weightiest consideration was to remove all odium and to combat false prudery, and that it was most important to *sail under true colors.* The result has shown how wise this plan was, since not only the great mass of people, but also the official authorities have joined heart and hand in the new movement, and on the part of the latter, the work has been essentially advanced in many ways. Among the members of the Society may be counted high officials of state, municipal governments, government insurance companies, sick-fund societies (Krankenkassen), medical and other societies; from these as well as from the government, the Society has received considerable material support. The Society has not only tried to make itself felt by fighting prudery, and in directing the attention openly to the unsatisfactory conditions existing in the warfare against venereal diseases, but it has really attained positive results. It has been due to the efforts of the Society that the restrictive paragraph by which the sick-fund only had to pay part of the regular amount in cases of venereal diseases, was removed. And it is further to be expected, not without the influence of the Society, that the obligatory report of venereal diseases in certain cases will be stricken out of the new law, soon to take the place of the law of 1835.

In my opinion, the most difficult problem in the struggle against venereal diseases, and one which must be firmly grasped, is the *sanitation of prostitution.* There is not the slightest doubt that prostitution is exclusively, or at all events, the main source of all venereal infection. The means taken for a better adjustment of the existing conditions and a purifying sanitation of prostitution leaves much to

be desired. This is all the more calamitous since the great cities are the principal sources in the spread of venereal diseases, and in comparison with small towns, the number of infections in cities increases in a geometrical rather than an arithmetical proportion.

I do not wish to go deeper into this difficult subject, and only wish to call attention to the fact, that in the present evolution of morals and especially in the large cities, the police alone, even when their organization is of the best, is not under any circumstances sufficient to initiate real progress in this field. The number of prostitutes in the large cities is too great to permit even the majority to be inscribed, and besides, the reckless enforcement of the police inscriptions is not at present in accord with modern views and would encounter everywhere the greatest difficulties and obstacles. I believe, therefore, as I have already amplified in a lecture given in the winter of 1900 at the Charité, that institutions must be created, in which prostitutes may be received for free treatment, and, in order to encourage prostitutes to visit these institutions, all of those who follow the prescribed regulations and treatment should, *a priori*, be exempt from police inscription.

In this direction, the German Society for Combating Venereal Diseases has a rich field for labor, but before closing, permit me to call attention to a danger which can only be guarded against by the most careful advances. It is not possible, even when most unfounded, to push aside old prejudices and views. When these have arisen from false modesty it is hazardous to throw away all scruples. Too much zeal in this direction may easily cause opposite results, and it is of all things desirable not to alienate the influential portion of the public from the Society. Only through cautious and unremittent work of enlightenment can success be achieved in gradually overcoming the obstacles mentioned, and by a persistent endeavor, we may attain the goal of limiting the alarming spread of venereal diseases.

SOCIETY TRANSACTIONS.

NEW YORK DERMATOLOGICAL SOCIETY.

323d Regular Meeting, March 22, 1904.

CHARLES T. DADE, M.D., President.

A Case of Acne Varioloformis. Presented by Dr. Fox.

The patient was a middle-aged man (thirty-seven years of age) presenting an eruption on the face and forehead of a papular character, surmounted at the summits by dark necrotic crusts which were level with the surface of the skin. The nose was so thickly pitted by the scars of former lesions as to resemble the pits left by small-pox, which he denied having had. The eruption disappears at times and recurrences always seem to be accompanied by obstinate constipation. The eruption is now worse than ever before.

Dr. BRONSON said the case was different from the typical acne varioloformis. There was a more marked inflammatory reaction and the inflammation was deeper. The lesions in this case were usually not raised above the niveau, as Hebra described them. They were flat and the crust appeared as if imbedded. He was inclined to regard it as nearer to Barthelemy's acnitis.

Dr. WHITEHOUSE concurred in the diagnosis of acne varioloformis. The lesions and scars were quite characteristic, in his opinion.

Dr. SHERWELL said that in the cases which he had seen the eruption had not extended so far below the brow. He still believed it was an acne varioloformis of a peculiar type.

Dr. PIFFARD objected to the use of fool names such as acnitis. He recalled such a fool name that was flashed before the Dermatological Society some years ago and met with such a storm of protest that it had never been heard of since.

Dr. ALLEN said that he had seen a great many of these cases during his dispensary work at the Good Samaritan. In some cases there had been lesions on the chest and in the scalp. In many cases the lesions had been almost confluent on the sides of the nose. This was especially marked in individuals having oily skins and having hairs on the nose. He thought the case exhibited, with the flat, superficial lesions, mortised in crusts and the resulting scarring, was a typical one.

Dr. FORDYCE concurred in the diagnosis. Some of the lesions were typical. In the case under discussion the exceptional intensity of the inflammatory reaction was probably due to the individual reaction or the virulence of the infectious agent.

Dr. Fox, closing discussion, called attention to the very greasy skin of the patient and also to the periodicity of attacks which seem to depend

upon the state of the bowels. He considered that the amount of congestion around the lesions was unusual.

Dr. Mewborn said that the greasy skin, to which Dr. Fox called attention, was particularly the point which Sabouraud had emphasized in explaining the etiology of the disease. In other words, it was upon a skin severely infected with the bacillus of oily seborrhœa that an added infection of the staphylococcus aureus caused these peculiar crusts of acne necrotica.

A Case of Lupus Erythematosus of the Hands. Presented by Dr. Fox.

The patient was a young man whose disease began on the nose in November, 1892, as a superficially ulcerated lesion which slowly spread involving the entire nose. In the course of time the affection of the nose disappeared without leaving a scar. The ears were next affected about a year ago and at present show scaly red patches. The lesions on the hands, for which the case is considered interesting, are scaly, slightly elevated, reddish, sharply defined patches on the backs of the fingers of both hands. These patches extend over the knuckles to about the middle of the metacarpal regions. The thumbs are not affected. The eruption is very well marked and characteristic, only the location is unusual.

Dr. Bronson regarded the disease on the hands, judging from a cursory examination, as eczema seborrhoicum.

Dr. Jackson considered the case lupus erythematosus.

Dr. Whitehouse said the lesions on the ear had caused a distinct atrophy. He considered the whole process, both on the ears and hands, as lupus erythematosus. The primary lesion on the nose had probably ulcerated as a result of the treatment, at least, the statements of the patient would so indicate.

Dr. Klotz said he agreed with the diagnosis of lupus erythematosus. He had seen similar lesions on the penis with an elevated border and a slight scaliness of the surface which might easily be mistaken for syphilis.

Dr. Sherwell said that he considered the lesions on the backs of hands as the migratory type of lupus erythematosus. These lesions frequently disappear and recur without leaving scars.

Dr. Allen thought that the hand lesions were lupus erythematosus modified by an eczematization from his occupation in using strong acids and alkalies. He recalled having treated this patient, giving one seance of X-ray and curetting the borders of the lesion on the nose after which it had entirely disappeared.

Dr. Fordyce made a provisional diagnosis of lupus erythematosus. There was no evidence of atrophy but he thought a histological examination would clear up any doubts in the case. The degeneration of the

collagenous tissue and the reaction of the elastic tissue to Unna or Weigert's stain was quite characteristic in lupus erythematosus.

Dr. Holder thought the sharply defined margins were decidedly in favor of lupus erythematosus. A histological examination might throw some light on the subject.

Dr. Dade agreed with the diagnosis. The sharply defined margins and the increased inflammatory reaction around the border were in favor of this opinion.

Dr. Fox said that he gave Dr. Allen credit for having made such a prompt diagnosis.

A Case of Mycosis Fungoides. Presented by Dr. Sherwell.

In presenting this case for the third time before the Society, Dr. Sherwell wished to acknowledge that he had been mistaken in the diagnosis before, considering it a parakeratosis variegata. There were many points in its history, however, and in the symptoms, both subjective and objective, which were atypical. He proposed to submit the patient to treatment either by X-ray or the high frequency current.

Dr. Fox said that the distribution, the discoid form, the scaling of some of the patches, especially the ones in the inguinal region, all pointed to the diagnosis of mycosis fungoides. As to the X-ray treatment he had observed one case which had been treated with marked improvement by the X-ray, after other treatment had failed.

Dr. Piffard said that he would not think of using the X-ray for its local action, but for its constitutional effect in tissue metabolism. In that way he thought it might be of benefit, but the lesions were too numerous to justify that method. He would recommend two other methods: (1) phototherapy, and by that he did not mean Finsen's method, but turning the patient out to graze at Butler, New Jersey, or in a solarium. (2) D'Arsonval high frequency current. This latter method produced deeper changes in the constitutional system and after a year's experience he was convinced of its efficacy in such cases.

Dr. Allen thought that very little could be done for these cases except by the use of the newer methods. He was the first in this country, so far as he knew, to apply the X-ray in the treatment of this disease and call attention to possible benefit. This case he had reported at Madrid. Since then he has seen a number of patients who had been markedly improved. He considered the X-ray the best method in the treatment of these cases but he was inclined to apply D'Arsonvalization at the same time for its effect on tissue metabolism, just as he was in the habit of doing in his cancer cases and other severe constitutional diseases. He favored the combination of D'Arsonvalization and high frequency for its constitutional as well as local effect.

Dr. Fordyce said that after the striking results obtained in Dr. Lustgarten's case and in others reported, he thought there could be no doubt as to the marked influence of the X-ray in mycosis fungoides.

A Case of Alopecia Areata. Presented by Dr. Mewborn.

The patient is a slender, nervous type of a young woman, a stenographer by occupation, who presents nothing special in her previous history except that she has always suffered a great deal from toothache. In November last she had an abscess develop in the right upper molar for which the tooth was removed. She wears a gold crown on the left upper bicuspid and the left upper molar is badly decayed and causes much pain. The lower teeth have numerous fillings. She has been under a severe mental strain in preparing for a civil service examination and has worried considerably over the loss of a situation. About two months ago her mother drew her attention to a spot of alopecia over the left ear. Upon examining her head she found a corresponding patch over the right ear. There had been no burning or other sensations in the scalp previously. Upon examining the scalp a patch about one inch in diameter was found at the nape of the neck and another very small one at the vertex in addition to the other two mentioned. The case is presented as furnishing a sufficient number of nervous symptoms to at least bring under discussion Jacquet's theory as to the causal relation between nervous irritation and alopecia areata.

Dr. Jackson said that if there were any causal relations between diseased teeth and alopecia areaia, it was strange that alopecia was not more common considering the number of individuals having bad teeth.

Dr. Bronson said that since Jacquet's theories were first announced he had carefully examined the teeth in every case of alopecia areata with the result, as it happens, of finding that in most of the cases the teeth were more or less affected. In one very extensive case, the teeth were in a particularly bad condition. After a dentist had attended to them, the hair in the course of a few months was restored, but a year or so later, the teeth remaining in fairly good condition, the alopecia recurred. He was not yet convinced of the correctness of Jacquet's etiology though he believed it entitled to further consideration.

Dr. Sherwell referred to the case of total alopecia which he had shown before the Society about a year ago, and stated that as a result of marked changes in her physical condition, having become *enceinte,* there had been a decided improvement in her hirsute activity. At the present time, within ten days of the time for confinement, the eyebrows, eyelashes, pubic and axillary hairs had in part returned and the hair in the scalp showed some evidence of return.

Dr Allen thought that various systemic states had at times a great

influence in these cases. In a patient of his own suffering from exophthalmic goitre, a localized alopecia areata had developed, extending until it became a total alopecia.

Dr. Mewborn, closing the discussion, said that while the evidence as to the connection between diseased teeth, and other causes of severe irritation to branches of the cranial and cervical nerves, with alopecia areata was not convincing; nevertheless, it was gaining ground. The experiments of Jacquet and others in efforts at producing alopecia areata by inoculations, made from the scrapings of patches of alopecia, had been uniformly negative. These experiments have all the more weight from the fact that some of the inoculations were made upon Jacquet himself, who must at least be considered susceptible, as he had previously suffered from an alopecia areata of the beard.

A Case of Vitiligo. Presented by Dr. Fordyce.

The patient, a man aged sixty, gave a negative history. His mental state did not permit him to give a connected account of the development of his trouble. He complained of pain in his cardiac region and over his stomach.

His talk was incoherent and he repeated many short phrases. His appetite was good and he had no vomiting.

There were large areas over the chest, abdomen, lumbar and dorsal regions where the skin was white and devoid of pigment. The intervening skin was intensely pigmented, as were also the arms and legs, with only here and there a leucodermatous spot. There were some white spots on the face and scalp. The increase in the skin pigment was far in excess of the lost or displaced pigment in the leucodermatous areas.

The urine was acid; specific gravity 1,018; no albumin, sugar, or casts. Urea 1.3 per cent.

A blood examination gave the following results:

Red blood corpuscles	3,170,000
White blood corpuscles	7,600
Hæmoglobin	60-70 per cent.
Small lymphocytes	20 per cent.
Large lymphocytes	14 per cent.
Polynuclear leucocytes	7 per cent.
Basophiles and Transitionals	1 per cent.

Dr. Klotz thought it was a clear case of vitiligo.

Dr. Whitehouse thought there were no symptoms of Addison's disease; no crises or disturbance of the general health. It was rather an unusual case of vitiligo, the pigmentation being so intense and extensive.

Dr. Piffard said that it was, in his opinion, a case of vitiligo pure and simple. He considered that the pigmented skin was probably not far from the normal color of the patient. The most extensive case he had ever seen was in a negro woman in whom every particle of pigment had disappeared from the skin except two dark spots one over each cheek bone.

Dr. Fox said that in his opinion the skin around the patches was not only darker by comparison but that it was actually darker.

Dr. Sherwell had never seen so extensive a case in a white person. He had seen two-thirds of the body affected in a mulatto girl. In that case there had been no very marked increase of pigmentation of the surrounding skin, except perhaps just at the borders of affected areas.

Dr. Fordyce, closing discussion, said that while he had presented the case as one of vitiligo, he suggested the possibility of the existence of an Addison's disease on account of a case reported by McCall Anderson which had been taken during life for a case of vitiligo but was found on postmortem examination to have lesions of the suprarenal bodies. He had seen at the City Hospital a case of vagabond disease with extensive pigmentation; even the mucous membranes were pigmented. In that case the pulse was weak and there was excessive debility.

The possibility of the coexistence of the two conditions had been considered in the latter case.

A Case of Raynaud's Disease. Presented by Dr. Fordyce.

The patient was a man, fifty-eight years old, a salesman by occupation. He had been addicted to the moderate use of alcohol and tobacco, but of late years had been a total abstainer. He denied any venereal infection. For the past three winters he had suffered from occasional seizures which he described as lumbago and which were characterized by pain in the lumbar region of a severity sufficient to render motion almost unbearable. In the course of the winter three years ago he noticed that on leaving a warm house and encountering the outside cold the tips of his fingers became blanched and cold. Such attacks at first occurred daily but were never repeated the same day as a result of similar change of temperature. Brief rubbing afforded almost immediate relief.

The same state of affairs obtained during the succeeding winter. During the winter which had just passed the attacks occurred oftener, sometimes three or four times a day, and lasted longer. After exposure to cold the tips of the fingers of both hands became suddenly numb and quite blanched.

The stage of local syncope lasted a few minutes, and was then followed by a bluish or purplish hue which continued from a few minutes to half an hour. At times one finger only was white while the adjacent finger or fingers were deeply cyanotic. His method of obtaining relief

consisted in wrapping the hands in newspapers and applying them to the hot water radiators.

There was a marked diminution in the systolic blood pressure during the attacks.

His urine showed a specific gravity of 1010, a trace of albumin with a few hyaline casts and epithelial cells. Urea one per cent; no sugar. The blood contained the normal number of red and white cells and from seventy to eighty per cent. of hæmoglobin.

An attempt was made before the Society to bring on an attack by immersing the hands in cold water. It was not successful, as chilling of the entire body seemed to be required to produce the spasm of the arterioles.

Dr. Piffard made a few remarks concerning the different photo-therapeutic rays. He objected to the terms Finsen light, Finsen rays, etc., as there were no peculiarities in these rays that entitle them to a distinctive name. They were exactly the same rays that are utilized throughout the city to illuminate the streets at night. When referring to them they should be designated simply as carbon-arc rays. It was, of course, eminently proper to speak of the Finsen method or technique of using these rays.

Dr. S. Bang substituted iron for carbon and the radiations may properly be designated as iron-arc rays.

Goerl made use of the induction coil and condenser as a source of therapeutic radiations, and these may then form correctly termed spark-gap rays. As the radiations produced in these several ways, differ very materially in character, they should not be confounded under the general name of Finsen light treatment. The several rays alluded to are each made up in part of visible (luminous) and non-visible radiations. These last are commonly called the ultra-violet rays. In the carbon-arc the luminous radiations predominate, the ultra-violet occupying a minor place. In the iron-arc there is a lessened proportion of luminous rays, (as compared with the carbon-arc) and an increased proportion of ultra-violet. In the spark-gap the luminous rays are at a minimum, while the ultra-violet are greatly in excess. Dr. Piffard stated that there were two very simple and convenient methods of testing the comparative richness of ultra-violet in these several radiations.

The first was by means of the gold-leaf electroscope. It has long been known that the ultra-violet rays will discharge an electroscope that has been charged with negative electricity. In testing these rays he found that the radiations from the carbon-arc discharged the electroscope slowly, those from the iron-arc much more rapidly, while those from the barely visible spark-gap did so instantly.

The second method of comparing the different radiations depended

upon the power of the ultra-violet rays to cause fluorescence in certain willemites and calcites, the two being often associated in the same specimen. The majority of willemites would respond to the rays, but the majority of calcites did not. Dr. Piffard then exhibited some suitable radio-responsive minerals. Selecting a specimen of willemite, associated with calcite from Franklin Furnace, New Jersey, the rays from a carbon-arc were caused to impinge on it. The result was a fair greenish fluorescence of the willemite, but no change from the white color of the calcite. The rays from the iron-arc were next applied. The willemite responded by a bright green, and the calcite assumed a faint but distinct pink. When, next, the rays from the spark-gap fell on the specimen, the willemite exhibited a brilliant green and the calcite became an intense blood-red. Dr. Piffard stated that he had found the physiological reaction greater after the application of the spark-gap than after the iron-arc rays. He had not used the carbon-arc in the treatment of cutaneous diseases, believing it to be less effective than the rays from the iron-arc or from the spark-gap.

Note on Kerion of the Beard. By Dr. Mewborn.

Through the courtesy of Dr. Allen I have been able to examine the case shown at the last meeting of the Society. The case you will recall was an Italian fruit seller, aged thirty, who gave the history of having first noticed a circular patch on the left cheek about three months ago. In one month the infection had spread to the entire bearded part of the face and neck. The moustache and scalp were free. The lesions consisted of red and shiny patches from which the hair had entirely fallen, of nodular lesions and of crusted lesions. To show how difficult it is in these cases, so evidently due to a trichophyton, to find the fungus it was necessary to examine over twenty-five hairs before succeeding. The hairs taken from these nodules could be easily epilated without sheath but were all free of fungi. Near the crusted lesions, stumps of broken hairs could be found and were so brittle that they had to be dug out and yet these stumps were filled with fungi which not only formed long ectothrix chains, but were also endothrix. I made numerous cultures on glucose agar and succeeded in obtaining a pure culture of a trichophyton megalosporon. This growth is powdery, white, with crater-like center and feathery-like circumference. I have here a photograph of a ringworm of the beard in which the lesions were much less infiltrated and which showed an abundance of spores in chains both from the scales and in the hairs. Here are photographs kindly taken for me by Dr. Fordyce of cultures made from the scales and from the hairs by the Plaut method showing beautifully, the grape-like clusters of spores.

A. D. Mewborn,
Secretary.

REVIEW

of

DERMATOLOGY AND SYPHILIS

Under the Charge of JOHN T. BOWEN, M.D.

PATHOLOGY AND PHYSIOLOGY.

By CHARLES J. WHITE, M.D., Boston.

On the Plasma Cell, "The Small Round Cell," and the Cells of Chronic Inflammation in General: A Survey of Recent Literature, with the Results of Some Further Observation and Experiment. ARTHUR WHITFIELD. (*Brit. Jour. Dermat.*, 1903, XVI, pp. 7-17 and 63-69.)

These articles give one such a clear and concise idea of the history of the much-vexed plasma cell question that the reviewer has thought fit to give rather an extended statement of them.

Unna was the first to draw the attention of dermatologists to the plasma cell, which he observed in 1875 in abundance in the connective tissue and about the vessels in cases of chronic inflammation and especially in lupus. The chief characteristics of these cells were their richness in basophilic, granular protoplasm, their large size, their rounded or polygonal contour and their eccentrically placed nucleus which absorbed polychrome methylene blue to a lesser extent than did the protoplasm of the cell. At the same time Unna described a second variety of these cells, to which he gave the name of daughter cells, marked by their smaller size and the tiny rim of protoplasm which surrounded their relatively large nucleus.

The fate of these cells, according to Unna, was to degenerate and form epithelioid or even giant cells while their origin was in the fibroblast.

The next important paper upon plasma cells came from the pen of Marschalko, who noted the same characteristics but added to their description the presence of five to eight peripherally-lying chromatin granules. Marschalko asserted that these cells were to be found in normal tissue lying freely in the lymph glands and the spleen and ascribed their origin to the hæmic lymphocytes and denied Unna's claim that they could degenerate into epithelioid cells. Marschalko based his ideas of the birth of plasma cells from the hæmic lymphocytes and not from the connective tissue cells, on the fact that plasma cells could be observed in great numbers in the blood in twenty-four-hour-old inflammations—

a space of time far too brief to produce a proliferation of connective tissue.

These views were immediately accepted by the majority of pathological writers.

Schottländer seemed to have sided with both parties, believing that plasma cells were developed from hæmic elements, while they certainly resembled young connective tissue and could form granulation tissue and epithelioid cells.

Joannovicz's investigations led him to similar double-sided convictions.

Jadassohn's and Enderlen and Justi's conclusions were similar to those of Marschalko.

Hodara then appeared as champion of Unna's statements, claiming that the previous writers had confused two different classes of cells in their experiments, one, the true plasma cell, which was derived from the fixed connective tissue cells, and the other, the false plasma cell, which owed its origin to hæmic elements.

Krompecher, while agreeing with the Marschalko school, complicated the picture still more by adding another variety of plasma cell, degeneration products of the first variety, and by claiming that all varieties could become connective tissue cells, in other words, plasma cells were merely an intermediate stage in the metamorphosis of the wandering cells of the blood into fixed connective tissue.

Rippert next appeared with the novel theory that plasma cells were derived from normal minute lymph nodes or collections of lymph cells which needed only the stimulation of inflammation to cause their production in immense quantities.

Marchand's work provided another idea, namely, that plasma cells arose from the breaking up of large amoeboid phagocytic cells which in their turn were developed from adventitial cells in inflammatory conditions.

The polemics of Pappenheim and Almquist gave the world nothing new except the pyronin-methylin green stain of the former observer, which Whitfield considers the best method which we now have on account of its greater power of differentiating the basophilic tendency of the protoplasm and the curious punctate nucleus of the cell.

At the conclusion of this résumé Whitfield records the results of many experiments which he and Mr. Lenthal Cheatle carried out upon the subject of inflammation.

They noted that an inflamed tissue produced large quantities of cells by undoubted division within twenty-four hours. They also observed that polynuclear cells were present within a few hours of the injury, that other cells were present in small numbers at the end of four days, and that not until the end of six days did the cells become densely packed when for the first time cells resembling plasma cells were visible.

They could not believe in the hæmic origin of the plasma cells because they had observed these cells particularly abundant around vessel walls which were so thick that emigration would have been an impossibility and also because a local increase in the number of plasma cells was never attended by a similar increase in the mononuclear elements in the blood. Against the connective tissue (histiogenic) origin of the plasma cells they recorded the fact of the great quantity of plasma cells visible within the lumen of newly formed vessels and the further observation that in those processes where connective tissue cells played the most important rôle but few plasma cells were to be seen.

Finding, therefore, both the hæmic and the histiogenic theories wanting, Whitfield cast about him for another solution of the problem and in a perusal of the older writers found that Flemming had stated that the germinating centers of the lymph glands—the so-called lymph nodes—were not stable but rose and receded according to the demands made upon them. With this idea in mind Whitfield examined the lymph follicles stained by Pappenheim's method and found what he claims to be the fountain head of the plasma cells in the subdivision of the endothelium of the smallest central vessel of these lymph nodes. Such a theory would explain the prevalence of plasma cells about the vessels, large or small, and would find its analogy in the bone marrow—the leucoblastic marrow of Muir—which produces white as well as red cells under certain stimuli; and further in the lymph nodes, which appear invaded by cancer cells in cases of carcinoma, in places where, under normal conditions, such nodes are unknown; and finally in the newly formed lymph follicles which Mayon has observed in cases of follicular conjunctivitis.

Die X-Zellen des Spitzen Kondyloms. P. G. Unna. *Monatsh. f. Prakt. Dermat.*, 1903, XXXVIII, p. 1.

While working upon the study of the "Epithelfasern" in sections stained by his water blue-orcein-eosin-saffranin[1] method Unna discovered in every section of acuminate condylomata some peculiar cells. These cells suggested some unusual types of leucocytes on account of their presence in the rete and on account of their amœboid movements, and for these reasons Unna resolved to seek evidences of transition from leucocytes to these unknown cells or else to abandon the idea that they were related structures.

After the most minute investigations Unna noted the following differences between the leucocytes and the new cells to which he has given the provisional title of x-cells.

Leucocytes have neutrophile granules about their poles. These are absent in x-cells. X-cells have a homogeneous nucleus free from chro-

[1] See *Monats. f. Prakt. Dermat.* 1903. XXXVII., p. 289 et seq.

matin threads and appear dark cinnabar red under Unna's special stain, while the nuclei of leucocytes contain chromatin threads and under the same stain appear red at the periphery and pale in the center. The nuclei of x-cells are surrounded by a clear, faintly staining halo. Leucocytes do not present this feature. The nuclei of x-cells are larger than those of leucocytes—slightly larger in the small type of x-cells, four to ten times larger in the giant forms. In the amœboid movements of x-cells the nuclei assume corresponding shapes. In leucocytes the nuclei remain practically unchanged. The pseudopodia of x-cells have rounded tips and are often bent at right angles to the cell body, whereas the projections of leucocytes are always pointed and are never bent to such a marked degree. X-cells are always to be found near the basal layer of the prickle cells while leucocytes appear more toward the free surface and even in the stratum corneum. X-cells are never found in the lymph or blood vessels of the corium. Leucocytes are frequently seen in these structures. Finally, the size of leucocytes is constant while that of x-cells varies much, sometimes reaching eight to ten times the bulk of the white cells.

Having thus satisfied himself that these two types of cells were totally unrelated structures, Unna next conceived the idea that the x-cells were products of the prickle cells, but before allowing himself to be convinced of this relationship he promised that he would verify the following conditions, which he regarded as virtually necessary to his theory.

1. That the rete cells should lose their prickles and their connections with their neighbors.

2. That they should become rounder.

3. That they should change their protoplasm so that it could (under his special stain) become dark blue and lose its transparency.

4. That they should change their nuclei so that they could lose their light blue color and fine framework as well as their nucleoli, and

5. That their nuclei should become single or multiple, homogeneous, dark and opaque.

After minute study Unna was able to satisfy himself completely that the prickle cells did fulfil all these conditions and in the end become metamorphosed into x-cells, the first condition being the last to be fulfilled.

Unna thus came to the final "remarkable conclusion that although the x-cells were derived from prickle cells most probably, they did not behave simply like dying or dead degeneration products, but evidently—like leucocytes—took upon themselves immigration into the prickle cells—a peculiarity alone warranting the name of x-cells."

INHERITED SYPHILIS.

By C. Morton Smith, M.D., Boston.

Infantile and Juvenile Tabes. Marburg. (*Wien. Klin. Wochensch.* XVI, No. 47.)

Marburg reports a case of tabes in a boy of ten years who contracted syphilis in infancy from his nurse.

In searching the literature he finds thirty-four cases of tabes under the age of twenty-one years. All the symptoms of tabes manifested in the adult are observed in children.

All but four of the cases gave a positive history of syphilis, and syphilis was probable in those four cases. The disease was inherited in thirty-two of the cases, and acquired in the other two.

In children with a taint of syphilis the development of tabes seemed to be favored by an injury to the head or by a series of acute infectious diseases—scarlet fever, diphtheria, whooping cough and measles.

Some of the children showed an inherited predisposition to nervous affections, while in others the approach of puberty was apparently the contributing cause of tabes.

In twenty-one of the cases, lancinating pains were present, the girdle sensation was noticed in only four cases, while five cases had initial headaches.

Sensory disturbances were noticed in two-thirds of the cases and Romberg's sign and bladder disturbances were present in three-fourths of the cases.

In twelve there was either a complete atrophy of the optic nerve or a beginning blanching of the papillæ. In only a single instance were there no objective optic manifestations. In his experience the development of optic atrophy coincided with an arrest or improvement of the tabes.

He has met with fifty-five cases of genuine optic atrophy in his own ophthalmic service during nine months. Of this number twenty-two were tabetics and only twelve of these gave evidences of an antecedent syphilis, and the interval since infection varied from six to forty years. Romberg's sign was present in only seven of the twenty-two tabetics and there was no ataxia present in any of the cases The tabes had always been mild from the beginning, in some of the cases extending over a period of twenty or twenty-five years.

This confirms the experience of others as to the mildness of the cases in which optic atrophy is at any time in their course, a prominent symptom.

Inherited Syphilis. Boissard. (*Presse Médicale.* I, No. 15.) (*Jour. A. M. A.* XLII, No. 14.)

Boissard speaks of what seems to him to be a well established fact:

that in the case of a woman impregnated by a syphilitic man and bearing a syphilitic child, all her subsequent children are liable to show some evidence of a syphilitic taint although she may have had but the one connection with the syphilitic, the succeeding children having had a healthy father.

In his hospital practice he not infrequently sees children whose growth is stunted and who are poorly nourished, although they are always hungry and crave more than the normal amount of milk for their weight.

Their chart of weight fails to show the usual gain.

He thinks little dependence can be placed upon the mother's statements, but her past obstetric record may suggest inherited syphilis, and the way in which these children thrive when given mercury shows that it was needed. He gives the mercury in the form of van Swieten's solution—in the dose of from twenty to sixty drops, or even more. In his experience newborn babies bear mercury extremely well, probably due to the good kidney elimination and the absence of teeth.

His method is to give the mercury for twenty days at a time and then a rest of ten days—insisting that this treatment must be kept up for a long time—several years, suspending the treatment at intervals but always resuming it if the child shows any arrest in development.

Syphilitic Ulcer of the Umbilicus in the Newborn. Hutinel. (*La Syphilis.* Vol I, No. 2, p. 81.)

Hutinel in his service at l'Hospice des Enfants-Assistés has been seeking some very early reliable sign of inherited syphilis. Something that shows the disease in latent cases before the appearance of coryza, papules, mucous plaques, etc.

There are brought to this hospital annually about four thousand newborn babies, and their physician is called upon to decide the important question as to whether a child is free from syphilis or not. This is a matter of grave importance and must be decided quickly and often with little or no knowledge of the parents. If the child is *not* syphilitic it should be given a wet-nurse and sent to the country; if it is syphilitic it must be sent to the nursery and fed artificially, and, as he points out, the result of an error in either case is disastrous, for if a nurse is given a syphilitic child she and her family will contract the disease, and if a nurse is withheld and a healthy child is sent to the nursery to be bottlefed it is almost sure to die within a short time of some gastro-intestinal infection.

The question is easily decided in children showing the characteristic signs of syphilis early, but it is in the cases where the disease remains latent that some early positive sign is of greatest value, and he describes a manifestation to which he has been calling attention since 1900.

He had noticed in several cases a lesion of the umbilicus which he at first took to be a simple infection, but specific manifestations followed so often that he feels that the lesion itself is a manifestation of syphilis, and gives a very careful account of this umbilical lesion citing cases.

He says that in a newborn of from eight to twenty days, immediately after the falling of the cord the umbilicus swells, becomes prominent, with a bright red zone about it; the redness becomes darker and extends to a diameter of from two to four c.m., this redness standing out well against the paler color of the abdominal wall. The appearance is distinctly inflammatory and resembles an erysipelas except that the redness does not spread, has not a sharply defined border, is apyritic and does not affect the general condition of the baby.

There is no tendency to abscess formation. The mass is firm, indolent, and feels like a lardaceous infiltration which shades off gradually into the healthy tissue. He has never seen a peritonitis caused by this lesion.

In from twelve to fifteen days the process ceases to spread, the swelling goes down, the redness fades, but an ulceration remains, i.e., a fistulous opening into which a probe will pass to quite a depth. This ulceration resists local treatment for a long time so that one is surprised if before this lesion has healed other manifestations of syphilis do not appear, coryza, fissures of the lips, papules, etc.

In hospitals these babies frequently die and a gummatous ulceration of the navel is found locally and specific lesions in the bones, spleen, liver, kidneys, etc., to verify the diagnosis.

He cites several of his observations giving a careful description of the lesions as they appeared, the subsequent history and the autopsy report in several cases.

He says that at first the ulcer of the umbilicus has nothing characteristic in its appearance. The redness which appears at first resembles the zone about a furuncle; next the swelling and skin becomes shiny and sometimes desquamates. He has never seen inflamed lymphatics or dilatation of the subcutaneous veins.

The swelling is neither painful nor tender, feels firm to the touch, but does not pit on pressure. Often after the redness and swelling have disappeared an actual depression is left in the skin.

There is no disturbance of the general condition—no acceleration of pulse or rise of temperature.

He states that non-specific infections of the umbilicus in the newborn are more common than the syphilitic lesion. When seen at the beginning the simple infections would never be mistaken for the gummatous ulceration in the typical case, but there are times when he considers it wise to wait for a confirmation.

He does not consider the presence of this gummatous ulcer of more value than the majority of other signs of inherited syphilis, but it does

constitute a new sign and should be put alongside the other signs, its chief importance being due to its early appearance.

It is very rare that the autopsy fails to show the syphilitic nature of the umbilical lesion; an incision through the center of the ulcer shows the crater in which is the yellow deposit—the gumma. The tissues about the ulcer show a gelatinous infiltration, while the peritoneal surface is unchanged.

In speaking of the anatomical diagnosis from histological sections through the ulcer, he states that it is not always easy to make a diagnosis of syphilis, but in these cases a study of other organs generally removes all doubt. He finds more or less characteristic lesions in the liver, spleen, less often in the kidney and testicle.

The spleen is of most importance; this is often large, firm, mottled and covered with an exudate. These conditions while not constant are very frequent.

Quoting from cases that he has found in literature, the authors have studied the changes in the cord but not the navel.

Hecker (*Jahrbuch für Kindeheilk,* 1900, Vol. 51, p. 374.) "In certain cases where the diagnosis of hereditary syphilis is impossible, the umbilical cord is the only organ which, in the living child, can be utilized for histological examination.

"The lesions which are revealed are characterized by:

"1st. Peri-arteritis and end-arteritis.

"2d. Phlebitis.

"3d. Infiltration of small round cells in and about the walls of the vessels. The thickening above of the walls is not characteristic and is seen in cords which are perfectly normal."

More recently Bondi has reported thirty-four observations in babies most of whom were still-born and macerated. He examined the umbilical cord and found especially an œdematous infiltration of the vessel walls with a fibrinous exudate in the tissues or a pseudo-abscess.

Bondi says that in doubtful cases the histological examination of the cord assures the diagnosis with great probability. This is particularly important in babies healthy in appearance: the histological examination of the cord furnishing information sufficient to decide whether the child is syphilitic or not. Of course all positive evidence should be utilized in making a diagnosis.

Hutinel in closing says that he has not cited all the cases at his disposal, but feels sure that the number of reported cases will increase rapidly when medical attention is called to the relation existing between certain ulcerations of the umbilicus in the newborn and inherited syphilis.

Joint Affections in Hereditary Syphilis, The Frequency of. E. Hippel. (*Muench. Med. Wochenschr.,* 1903, p. 1,321.)

In his ophthalmological practice the author frequently encounters

cases of syphilis hereditaria tarda in which there is keratitis parenchymatosa accompanied by an effusion into a joint; usually it is the knee or elbow joint which is involved.

In seventy-seven cases in which there was sufficient evidence to establish the diagnosis of syphilis this combination was present sixty-eight times. These joint affections do not occur in association with cutaneous lesions of syphilis, hence they are not observed by dermatologists.

Where there is simply hydrops of a joint present in a child, this possibility of diagnosis should be borne in mind and careful search should be made for further evidence of syphilis.

SYPHILIS OF THE SKIN AND MUCOUS MEMBRANES.

By Walter C. Klotz, M.D., New York.

Pathology of Syphilitic Primary Lesions. By Prof. S. Ehrmann, (*Archiv. f. Derm. und Syph.*, 1904; LXVIII-1—p. 3.)

The above article contains the results of careful histological study. The author's opinions are in accord, also, with more recent ideas in regard to connective tissue inflammations in general, in so far as he ascribes to the lymphatics the principal rôle in the pathological process of the primary chancre. In order to distinguish the lymphatics from blood vessels in the cut sections he has injected each with different substances. He has also made it a special point to stain for elastic fibers. These two features he considers most important in arriving at a correct idea of changes that are produced in the development of the primary lesion. From a study of serial sections of dissected preputial chancres, prepared according to the above method of technique, he finds that the principal mass of infiltration surrounding the point of entrance of the veins is traversed and encompassed by a network of new capillaries, that the strands of infiltration extending from the principal mass follow the course of the lymphatics, and that the form of the primary lesion depends largely upon what portion of the lymphatic system is involved in the process of infiltration. The infiltration surrounding the larger lymphatics may extend to the subendothelial connective tissue, and usually forms an outer and an inner layer of infiltration where muscular tissue is present in the wall of the lymph vessel. A network of new capillaries surrounds the perilymphatic infiltration as in case of the principal mass of infiltration. It is only exceptionally that infiltration surrounds the arteries, and where it does occur, it never involves the wall of the vessel, but is always limited to the periosteal lymph space .The infiltration surrounding lymphatics may be continuous or interrupted, and may form nodular enlargements, particularly at the junction of several lymph vessels. These enlargements are simply excessive collections of lymphocytes or plasma cells, and in no sense, preformed lymph nodes or gummata, as has been variously held by other authors. Taking up his histological findings the author presents the

following principal conclusions: the first changes take place in the lymph spaces, at the site of entrance of the virus and are followed by a new growth of capillaries, the subcapillary and capillary lymphatics being surrounded by infiltration which is traversed by new capillaries. At the same time some of the lymph vessels show subendothelial infiltration. It must be assumed that the virus makes its way out of the tissue spaces into the lumina of the lymph vessels, producing a reaction in the subendothelial, and perivascular tissues. The outer layer of infiltration, surrounding the lymphatics may form nodes. Other conclusions arrived at by the author will be taken up by him in a subsequent paper.

Justus Test for Syphilis. (Uber die sogenannte Justus Probe, etc.) By Dr. Leon Fenerstein. (*Archiv. f. Derm. u. Syph.*, 1903, LXVII, p. 363.)

The above article, originating from Prof. Neisser's clinic at Breslau, appears to definitely dispose of the question regarding the practical significance of Justus' test in syphilis. Justus has claimed that in cases of florid syphilis, there was a marked sudden fall in the amount of hæmoglobin, as soon as mercury was administered. The author has carefully compared with all Justus' postulates, and attempted to apply the so-called hæmoglobin test in forty-five cases. Thirty-two of these were in the florid stage of syphilis, five showed a distinct fall in the amount of hæmoglobin, twenty-six showed little or no variation, and two showed an increase. In six cases, with primary lesion, the test was negative, two showing a decided rise in hæmoglobin. The test was applied to seven non-syphilitic cases. In five of these, there was only a slight or no variation in the amount of hæmoglobin. In one of these cases there was an increase, and in one, a distinct fall in the amount of hæmoglobin. The author concludes, therefore, that there is no characteristic variation in the amount of hæmoglobin, in Justus' sense, and that any claim of a specific syphilitic reaction cannot be accepted.

Tertiary Syphilitic Gumma of the Urethra. By Alex. Renault. (*Bull. de la Soc. Francaise de Derm. et Syph.*, 1903, XIV-9, p. 330.)

This case presented an extremely rare condition, one which seen for the first time might easily lead to a mistaken diagnosis. The patient had been infected with syphilis about twenty years ago, the subsequent treatment being rather neglected. During the last year he had developed tertiary syphilitic lesions in various parts of the body. He stated that about one year ago he had had a perineal abscess which opened spontaneously. At the time he was presented before the Society, there was a hard tumor the size of a walnut, situated in the perineum, behind the scrotum, adherent to the skin at one point, and continuous with the bulbous urethra. The entire urethra was thickened and indurated from the glans

as far posteriorly as the perineum, where it was continuous with the above described tumor. It caused no pain or annoyance, although the stream of urine was somewhat diminished in size. In the discussion of the case, Fournier observed that it was a very rare condition and that he had seen only about six cases in his entire experience. Barthélemy was of the same opinion as the author, believing it to be a hard gumma of the urethra.

VISCERAL SYPHILIS.

By Frederick J. Leviseur, M.D., New York.

Heart Syphilis. T. Adler. (*Med Record,* Feb. 20, 1904.)

Adler's important paper on this subject is valuable both for the general practitioner and the specialist. Syphilis should be considered as a possible factor in every case of heart disease, and on the other hand a possible heart disease should be considered in every case of syphilis. One must not look for very pronounced physical signs—murmurs, dilatations, endo- or pericarditic symptoms. All that is to be expected in the early stages are slight arhythmia, an occasional dropping of the beats, roughened or diffused systolic sounds, accentuation or reduplication of the second aortic or pulmonary sounds. At every examination of the syphilitic patient the closest attention should be paid to the condition and function of the heart, and he should be discharged from treatment only when there is assurance not only that all palpable signs of syphilis have been removed, but also that the heart is, as far as possible, in its normal condition. Very large doses of iodide of potassium are not necessary but very moderate doses will be sufficient, provided that they are given for a sufficently long time and are supported by mercury best employed in the form of inunctions or hypodermic injections.

The ex-juvantibus diagnosis is firmly established in the domain of syphilis and it holds also good in specific heart disease with the following modification: Whenever antisyphilitic treatment results in complete and permanent cure, the conclusion is justified that the disease is of syphilitic origin. On the other hand, an incomplete cure of the lesions and symptoms, or even the entire failure of the treatment to influence the pathological conditions does not necessarily exclude syphilis as the primary cause of the disease.

According to Runeberg, out of a total of 734 deaths on the list of a single life insurance company, 84 were certainly syphilitics and died of diseases in all probability attributable to lues. Of these 84, 33, or nearly one-half, died of diseases of the central circulatory organs (heart and aorta) and 24 of these 33 died of sudden heart collapse. Grassmann found in two-thirds of 288 cases of syphilis disturbances of the normal heart's action during the secondary stage. Adler thinks it possible to recognize heart syphilis as such with some degree of probability. If,

for instance, we find typical attacks of angina pectoris in individuals between twenty and forty years without other evidence of arterio-sclerosis or contracted kidney, the syphilitic character of the disease is highly probable. If in addition to this there is proof of previous syphilitic infection, the diagnosis becomes almost a certainty. Lastly, if antisyphilitic treatment effects a permanent cure the diagnosis of syphilitic heart disease may be considered as absolutely certain. A very interesting case is quoted in detail to illustrate this. In reviewing the pathology of heart syphilis Adler calls attention to a form of syphilitic myocarditis which does not appear to be generally known. The study of a rather considerable number of hearts of syphilitics of all ages has led him to believe that there is a primary interstitial myocarditis associated with a clearly defined panarteritis, the so-called arteritis productiva obliterans. This form of myocarditis is probably one of the most frequent occurrences in constitutional syphilis and is by no means limited to the tertiary period. It is not unusual to find, especially in the walls of the left venticle, cellular proliferations in the adventitia of the small and smallest arterioles. From these proliferations as starting points, strands of cellular infiltration traverse the neighboring myocardium, the muscle fibers are crowded apart and connective tissue is formed, at first loose and containing an abundance of cells but gradually becoming firm and more and more fibrous in character. The muscle fibers, at first quite normal, gradually degenerate, are atrophied and absorbed, and their place is ultimately usurped by fibrous tissue. Coincident with this is the proliferation in the little arteries, the media becomes fibrous, the muscle cells being crowded out and replaced by connective and elastic tissue, and the intima proliferates vigorously. The lumen of the little vessel is more and more obstructed until it is finally entirely obliterated and the process thus ultimately culminates in the total destruction of the arteriole and the surrounding myocardium. These fibrous patches are, as a rule, but very small at first, but gradually invade more and more of the muscular territory until quite extensive fibrous degeneration of the heart is produced. The article contains many more points of great interest.

TREATMENT OF SYPHILIS.

By Frederick J. Leviseur, M.D., New York.

Hydrargyrum Hermophenylicum. Georg Seegall. (*Berliner Klin. Wochensch.* No. 42, p. 962.)

This remedy is a solution of mercury oxide in sodium carbolicum bisulfurosum, containing forty per cent of mercury. It is easily soluble in water. Dejace, Mornaud, Boudin, Nicolle, Martinet, Hallopeau, Leredde, Sava, Reynes, and others have used it with more or less success. Wolff expressed himself favorably in regard to its action. The author made use of a watery solution of one-half per cent. strength, of which

he injected four cm. every other day. Subcutaneous injections at first resorted to were later on replaced by intra-muscular injections. The doses were increased gradually until two grammes of a two per cent. solution were used every day. Only a few patients thus treated showed any ill effect, consisting of moderate pain during and one-half to one hour after injection. Symptoms of mercurial intoxication appeared in nine cases out of thirty-five. The author concludes that the remedy is not uniform in its action and quite unreliable.

BOOK REVIEWS.

Ueber Das Syphilom des Ciliar-Korpers. *Eine Anatomisch-Klinische Studie.* (Syphiloma of the Ciliary Body; a Clinico-Anatomical Study.) Von. Prof. Dr. Th. v. Etwetzky. (Berlin, 1904. S. Karger.)

Etwetzky has carefully studied four cases of syphilitic growths of the ciliary processes and presents a complete picture of this interesting and not altogether unusual condition. One division is devoted to an analysis of the cases mentioned in literature with a complete table of details which may be consulted with profit for a thorough understanding of the clinical data. Separate chapters are devoted to symptomatology, course of the disease, final results, secondary changes in other intraocular tissues, the relation of these tumors to syphilis in general and to its various stages, and to the pathological anatomy of the syphilomata. A complete review of the literature, with critical analysis of each case, closes the work, which is an important contribution to the differential diagnosis of an affection which, perhaps on account of the inaccessibility of the ciliary processes to our examinations, is still but rarely recognized. P.

Les Lesions du Rein et des Capsules Surrenales. (Lesions of the Kidney and Suprarenal Capsules. By L. Hoche and P. Briquel. (*Masson et Cie,* 120 Boulevard Saint-Germain, Paris, 1904.)

This volume of 328 pages, containing 168 illustrations, is a veritable *chef d'œuvre* upon the gross pathology of the kidney. The specimens, richly illustrating the subject, were collected during several years' service at the Laboratory of Pathological Anatomy, Faculty of Nancy, preserved in Kaiserling's fluid and photographed by means of a camera held vertically over the specimens which were submerged in water contained in an opaque vessel. This avoided all surface reflection and gave photographs which are marvels of half-tone shading. The photo-micrographs, while not so beautiful as the gross pathology photographs, are sufficient to elucidate the brief but admirable descriptive text accompanying the lesions.

Die Mikroskopische Technik. (Microscopical Technic.) Dr. R. Lederman. (*Alfred Holder,* Wien. 1904. Price, 4.40 Marks.)

This convenient little manual, intended especially for the laboratory table as a working guide in staining methods, is unusually good in the portion devoted to staining methods as applied to skin histology. This excellence in a branch of histology, so commonly slighted in a general manual, is, perhaps, accounted for by the author's well known devotion to the field of dermatology. In a manual of some two hundred pages many of the illustrations might as well have been omitted, as well as the usual description of microscope, tools, etc., which is not full enough for a beginner and an absurd waste of time for one capable of following the author in the intricate staining methods given in other chapters of the book.

NOTICE

Provisional Program of the American Dermatological Association at its Twenty-eighth Annual Meeting to be held at Niagara Falls, N. Y., June 2-3-4, 1904.

FIRST DAY,

Morning Session.

1. Address by the President, ...	Dr. Joseph Zeisler.
2. Rhinophyma—a Pathological Analysis of Four Separate Tumors Occurring in One Patient, ...	Dr. G. W. Wende. and Dr. C. A. Bentz.
3. Granuloma Pyogenicum (Botryomycosis of the French authors)	Dr. M. B. Hartzell.
4. A Peculiar Eczematoid Eruption of the Lip Region, ...	Dr. H. W. Stelwagon.
5. Notes on Certain Post-Vaccinal Eruptions,	Dr. W. T. Corlett.
6. Parasitic Sycosis Communicated from Cattle, ...	Dr. W. F. Breakey.

Evening Session.

7. A Case of Reinfection of Syphilis, . .	Dr. H. G. Klotz.
8. Reasons for Considering Dermatitis Coccidioides an Independent Disease, . .	Dr. D. W. Montgomery. and Dr. Howard Morrow.
9. Some Notes Concerning Domestic Remedies Formerly Used in Skin Diseases,	Dr. J. C. White.
10. Xanthoma Multiplex — Histology of the Palmar Striæ, ...	Dr. H. H. Whitehouse.
11. Erysipeloid, ...	Dr. T. C. Gilchrist.
12. Exhibition of Lantern Slides Illustrating Certain Histological Features of Skin Diseases, ...	Dr. J. A. Fordyce.

SECOND DAY,

Morning Session.

13. General Discussion — Affections of the Mucous Membrances in Relation to Skin Diseases, ...	Dr. J. A. Fordyce and Dr. M. F. Engman.
14. Lichen Planus Verrucosus, ...	Dr. A. Ravogli.
15. An Inquiry into the Etiology and Nature of Toxic Erythemata, ...	Dr. J. F. Schamberg.
16. A Further Report of a Case of Multiple Myomata of the Skin, ...	Dr. W. A. Hardaway.

THE JOURNAL OF
CUTANEOUS DISEASES
INCLUDING SYPHILIS

VOL. XXII. JULY, 1904. No. 7

PRESIDENT'S ADDRESS.

By JOSEPH ZEISLER, M.D., Chicago.

Read before the twenty-eighth annual meeting of the American Dermatological Association, Niagara Falls, June 2 and 3, 1904.

FELLOW members of the American Dermatological Association: I could not well begin my official relations to this distinguished body without expressing to you my profound gratitude for the well meant honor bestowed upon me while absent from last year's meeting. In contemplating a variety of subjects suitable for this occasion, I had originally planned to present to you a picture of the dermatologist of the future, an idealized portrait which I saw gradually taking shape before my mental eyes; but my hopes for the future were rudely shattered and my thoughts turning to the past, dwelt upon a figure which always had seemed to me to represent the best of our department of medicine, my late teacher, to whom I owed so much of the enthusiasm and inspiration which I brought to my work. But were I to devote this address to the life and work of our former honorary member, Moritz Kaposi, I might easily be accused of partiality.

May I not then be permitted to offer a few suggestions intended for the best interests of our Association; suggestions more of a technical nature than touching upon the scientific life of our organization. I am sure that all of you feel with me that the American Dermatological Association must be retained as the one distinguished exponent of American Dermatology, and that it must remain a sort of areopagus situated on a high plane. But we must be alive at the same time to the possibility of competition, which may gradually make itself felt. It will not do for us, after the manner of the ostrich, to ignore what is going on around us. It is not many years since the mere mention of the American Medical Association would cause, at least with an important part of the profession, mostly in the

East, a peculiar shrug of the shoulders; when participation in the assemblies of that body would be considered good ground for ostracism, and when, as a result of that pronounced feeling of antagonism, the Congress of American Physicians and Surgeons was formed sixteen years ago. At that time conditions may have justified the action of the Secessionists, but a gradual and very noticeable change has taken place since then. For several years past we find at the head of what is to-day easily the largest aggregation of physicians in the world, men of unquestioned scientific attainments, who, themselves, are recognized leaders in the smaller Congress. The general tone in the sections has continually improved, and medico-politics have been left to a smaller body of delegates. As to the section of Cutaneous Medicine, it is but fair to acknowledge that very creditable work has been done by it, due in no small degree to the active participation of late, by members of our own Association, several of whom have been selected, not without a good deal of political tact, as the Chairman of that section, thus giving it additional prestige.

We are thus confronted with a very peculiar state of affairs which is liable to gradually reflect upon the efficacy of our own meetings. When, as it happened last year and again this year, our own sessions and those of the aforenamed body follow each other closely, the temptation may arise for some of our members to ignore our own and rather attend the session of the other body, where a larger audience and the publication of their papers in one of the most widely distributed journals may be their reward. And for those who would be quite willing to be present at both, attendance for two consecutive weeks may mean, if you pardon the slang phrase, "almost too much of a good thing." No better illustration of the timeliness of these remarks could be given than a comparison and scrutiny of the programs of the present meeting, and the one to be held next week at Atlantic City. Of our membership of 51, only 16 have announced contributions. The other meeting shows a varied program of 24 numbers, 13 of which are furnished by members of our Association. *Caveant Consules!*

I should like it distinctly understood that I personally have such an exalted idea of the dignity and scientific eminence of this Association that I do not fear the possibility of its deterioration from that possible competition. The exclusiveness of our own organization with its fixed and permanent membership, as compared to the open door character and constant changeability in the makeup of the other, are

quite a safeguard against that danger; but, would it not be wise for us to select for our meetings, a time when no other disturbing influences can interfere? A date like the present one interrupts of necessity, the college work, and the busy practice of many of our members. Were we to meet, for instance, during the period between Christmas and New Year all the difficulties alluded to would be entirely obviated. It is a time when the colleges are closed and when few of us are overburdened with private work, and when, in the case of meeting in a large city, clinical material can easily be secured. Even the last week in September, directly before the commencement of college work, would seems decidedly more advantageous than a Spring meeting.

To try to increase our efficiency by a considerable enlargement of our membership would seem to me to be very hazardous. We must preserve the traditional character of this body by insisting upon undoubted scientific qualifications. As in the past, membership here must constitute a coveted distinction and applicants for our Association must have earned their spurs elsewhere.

I hope that the clinical demonstrations which, during the past few years, have easily formed the chief attraction of our meetings, will be retained as a distinctive feature, and if possible, be given even more room. It is not a sufficient attraction to travel far and lose much precious time in order to listen to the reading of ever so valuable papers, which, in due time, can be found in published form and then read with so much more profit. The informal discussion and exchange of ideas resulting from the personal examination of interesting clinical material are now being recognized to surpass in interest by far, all the rest of the program, and it is essential under these circumstances that as a rule our meetings should be held in the large cities. The Triennial Meetings in Washington in connection with the Congress of American Physicians and Surgeons have therefore seemed to me, on account of absence of clinical material there, to be a source of some disappointment, and it may behoove us, without necessarily severing our official relations with that body, to earnestly consider the propriety of again and again meeting in that city.

I have made reference above to the questionable profit in listening to the reading of papers, and in this connection would venture to make a remark which applies by no means to our Association alone, but to almost all medical gatherings. Occasionally we are privileged to listen to scientific communications which are thoroughly enjoyable.

This is due not so much to the intrinsic value of the paper, but in a large measure to the form of delivery which attracts our attention. Many a valuable contribution, the result of earnest labor, remains unappreciated at the time of reading, unless the speaker possesses at least a moderate amount of oratorical ability. I am certainly in favor of every paper presented before a scientific body being carefully written out ready for the printer, but it should not necessarily be read word by word. The writer, who should be master of his subject, should be prepared, particularly in the case of a lengthy report, to present his ideas in abbreviated form and without continuous reference to his manuscript. There are few people who cannot easily be followed when they speak in ordinary conversational tone, but the moment they try to read, it becomes quite difficult to follow them. I believe that a good delivery is one of the most valuable and delightful qualifications of a speaker in a scientific gathering, and I think we should encourage it, without necessarily resorting to the regulation which obtains in many assemblies on the European continent where the speaker is expected to deliver his address from memory.

I should like also to use this opportunity of urging a return, at least in a measure, to the manner of conducting the discussions in our meetings as they obtained in years gone by, when participation in them was encouraged rather than repressed. The attempt which so often is made in some medical gatherings to get through with a program by all means, at the expense of what seems to me a very attractive feature, namely, the discussion, has often appeared to me a great drawback. If the idea suggested before of presenting a paper rather in abstract, omitting, for instance, histological details, which should be preferably demonstrated before or afterwards under the microscope; omitting also minute details of case histories, with dates and so on, which rarely the listener can follow intelligently, were carried out, there would remain more time for discussion. Of course, I mean discussion which should add to the elucidation of the subject presented, without shifting into domains foreign to the contents of the paper.

In conclusion let me express the sincere hope that my remarks may be taken as an earnest expression of my best wishes for the welfare of this Association, which I trust will remain for a long time to come an important factor in repressing dilettanteism and charlatanism and fostering earnest and legitimate work in scientific dermatology.

TUMOR-LIKE FORMS OF TUBERCULOSIS OF THE SKIN.

By Walther Pick, M.D.,

Assistant to the Clinic.

(From Prof. Riehl's Clinic for Dermatology and Syphilology at Vienna.)

Translated by Herman G. Klotz, M.D., New York.

THE etiological unity of the tuberculous affections of the skin has been well established since the discovery by Koch of their causative agent. Nevertheless, it is important to insist upon the peculiarities of their clinical appearances, particularly as we meet with types so different that some of them hardly suggest their affinity with the tuberculosis group, and especially in the absence of all other typical manifestations of that disease.

Why does the skin react in one case with the picture of lupus vulgaris, in another with that of tuberculosis verrucosa cutis, etc.? Is it due to different species or modifications of the same infectious agent; or is it that mixed infections or other factors are responsible for these various reactions and what part is played by the diversity of the affected tissue? All these are questions which have not yet been satisfactorily explained. Recent experiments by Krompecher and Zimmermann (*Centralblatt f. Bacteriolog.*, 1903, Bd. xxxiii, p. 580) have established equal virulency for rapidly developing cases of lung phthisis and for the benign chronic tuberculosis process in the bones. If inference from analogy is admitted it may also be assumed in regard to the skin, that the difference in the clinical pictures is due to differences in the nutrient soil rather than in the source or the virulence of the causative agent.

One of the rarest and most remarkable tuberculous manifestations of the skin is tuberculosis in the shape of tumors, which by Riehl has been designated as *Tuberculosis fungosa cutis.* The clinical picture of this form of tuberculosis presents considerable variety and renders the diagnosis exceedingly difficult. Therefore it seems justified to report two new cases which have come under observation in our clinics.

Case I. F. K., age twenty-six, laborer's wife, was admitted January 29, 1903.

History: Parents are living, sixty-five and sixty-four years old respectively, and in good health, as are six brothers and sisters. One sister died at the age of thirty-four after an operation in connection with a confinement. Patient has been married five years; three children aged five, three and one year, as well as the husband, are strong and healthy. At ten years of age the patient had scarlet fever, but enjoyed good health afterwards until after her second confinement, when she began to lose flesh. About Christmas, 1900, there appeared a swelling of the right cheek, originating, it is claimed, from a tooth; it was painful and lasted three weeks. After the swelling had subsided under the use of moist applications, the patient noticed a pea-sized nodule over the right inferior maxilla. This, the patient reports, grew into a fungus, rising above the level of the skin; within a year it opened spontaneously and healed, leaving a depression. In the meantime other lesions of the same character had appeared in the neighborhood, but up to one year ago the entire affected area had not exceeded the size of a half dollar; since then, however, it began to grow more rapidly.

Several months before the appearance of the lesions on the face, but after the confinement, a swelling of the left ankle joint had appeared, around which the skin became red and broke down, forming a deep ulcer. This healed, leaving a scar which is still visible. About the same time superficial ulcers, accompanied by swelling, formed upon the left thigh.

In February, 1902, the anterior portion of the left foot began to swell, and small breaks occurred which healed while other new ones would form. Two months later the affection of the right eye commenced. This at times entirely heals, and exacerbates only if the patient works and strains the eye. Six weeks ago on the inner aspect of the left thigh and in the left inguinal region several pea-sized tumors were noticed, which softened in the center and broke down.

A scar on the back of the right hand dates back to the patient's early childhood, and no account of its origin can be obtained. Within the last year the patient has frequent cough, as she asserts, principally preceding menstruation. No night sweats.

Examination showed the patient to be of medium size, slender, fairly well nourished, skin pale, well oiled, elastic; scalp pale, moderately scaly. Along the horizontal branch of the right inferior maxilla a flat elevated tumor presents itself, about six centimeters long and two and a half centimeters wide, with a red, rough surface.

This area is sharply defined towards the surrounding portion, but in its neighborhood, within apparently healthy skin, deposits of thin lamellar scales are found. Similar deposits, but so firmly attached that their removal is followed by bleeding, are found upon the surface of the tumor, besides several accumulations of crusts, partly yellowish, partly of a blackish color owing to the extravasation of blood. After their removal irregularly defined, readily bleeding ulcers with sharp, here and there undermined edges, become manifest, varying in size up to that of a "kreutzer" (penny), and larger. Although the single protuberances of the tumor do not feel particularly firm, on palpation of the entire mass one feels an extremely resistant plate extending beyond the perceptible outlines of the diseased area. It seems to be embedded in the skin and adherent to it, but freely movable over the underlying bone. This plate likewise shows several hazelnut sized protuberances; some of them reaching down to the mucous membrane of the cheek, without, however, adhering to it.

The region of the left ankle joint is swollen, soft, doughy, measuring thirty-one centimeters (the right ankle measuring twenty-five centimeters). The skin itself is normal with the exception of a linear scar over the center of the articulation; its surrounding skin appears slightly reddened and reveals several dark pigmented millet seed-sized macules which resemble cicatrices resulting from lupus nodules. The region of the left metatarsal bones and of the toes also appear swollen; within these limits the skin is of a livid color and densely infiltrated, partly diffused, partly in circumscribed penny-sized foci. Some of these foci show a central, irregularly defined and coated erosion, others are covered in the center with scales or crusts, others again exhibit a central cicatricial depression. The skin between the toes is highly macerated; over the entire affected portion intense secretion of sweat takes place, so that the perspiration remains visible in drops, while on the right foot secretion is not augmented. The left leg is thickened, with numerous varices in the skin; along a line running from the internal malleolus on its inner aspect several slightly depressed, circular, pale scars are found, varying in size up to that of a half dollar, which have partly pigmented borders. On the inner aspect of the thigh, closely above the knee, there is an elliptic, about half-dollar-sized rigid area, of a livid color, which in the center shows a rectangular cushion-like protuberance. This is densely infiltrated; on the upper margin there is a pinhead-sized abrasion, from which on pressure oozes a small quan-

tity of clear serum. In the left inguinal region, below Poupart's ligament, there are also present several infiltrations of a livid color, some still slightly prominent, some already sunk below the level of the skin. One of them appears to be softened in the center and on pressure discharges thick, bloody-colored pus.

Within the skin of the right upper eyelid, a pea-sized redness and infiltration is situated in the center above the tarsus; the ocular conjunctiva is in a state of high injection; the cornea, diffusely clouded, shows in the inner lower quadrant a pinhead-sized whitish opacity.

The inguinal glands, principally the left ones, besides the cubital and cervical glands, can be felt as small, firm nodules; one submaxillary gland in the neighborhood of the patch of the right cheek is enlarged to the size of a pigeon's egg. The skin which covers it is normal. The visible mucous membranes are normal, no change of the heart or lungs can be demonstrated, the appetite and the functions of the bowels are normal, menstruation regular.

A Roentgen examination demonstrated on the right hand, in the proximal third and fourth metacarpal bones, the remnants of a former destructive process, accompanied by chronic atrophy of the bones. On the foot, not fully authenticated, two circular foci of absorption in both inner cuneiform bones (caries?); otherwise no changes in the skeleton.

The area on the right cheek, together with two pathologically changed glands of that region, were excised under narcosis. As far as possible the wound was united by sutures. Part of the focus and of one gland were hardened in alcohol and after embedding in paraffin, were histologically examined. In the principal piece the following conditions were found:

In the center of the section there is a large superficial area of infiltration; above the same and in its immediate neighborhood, the interpapillary processes are increased often to double their normal length; the epithelium in these localities shows a high degree of œdematous infiltration and the presence of numerous migratory cells, so that the demarkation of the connective tissue is often absolutely obliterated. In some places the deeper layers of the epithelium have already totally perished and only the corneous layer extends as a narrow strip across the infiltrated area. This itself is not sharply defined and occupies the entire space between epithelium and fat tissue, so that the fibrillar connective tissue has been absolutely lost,

and its place is occupied by a dense accumulation of cells. The larger majority of these cells are round cells, between which, here and there, small aggregations and streaks of epithelioid cells are found. Within the area blood vessels are met with, the walls of which often seem to be highly affected by the inflammatory infiltration, in parts their remnants only, which are distinguished by the parallel arrangement of the cells surrounding the obliterated lumen. But particularly striking is the abundance of lymph spaces and lymph vessels, mostly dilated, which traverse the area in the most diverse directions. In the superficial portion there is an extensive hemorrhage, in consequence of which the infiltration with leucocytes appears less dense in this spot.

Again, within this diffuse area of inflammation, smaller portions become defined in such a way that an extremely dense inflammatory wall of small cells surrounds a group of epithelioid cells, already partly necrotic and fused into giant cells. Their circular, sharp demarkation suggests, indeed, a vascular process, but this could not be positively proved; in particular, no elastic fibers could be demonstrated, though this need not cause surprise in the presence of such a high degree of inflammatory infiltration. This superficial area, then, exhibited a mixed structure; besides a few tubercles, mainly products of a non-specific inflammation were found within its bounds, in the deeper layers of the cutis and penetrating deeply into the fat tissue, foci of typically tuberculous structure. These foci were closely aggregated and separated only by scanty connective tissue, showing in their interior numerous giant cells and extensive cheesy portions. Therefore the zone usually occupied by fat tissue was taken up by a tuberculous infiltration. The genesis of these foci cannot be determined any longer on the larger ones, but the initial stage of the process could be distinctly recognized in the small foci situated in the fat tissue and within the connective tissue bundles. There may be seen, in two neighboring blood vessels, that the artery is perfectly intact, with rarely a single leucocyte within its walls, while the vein forms the center of an infiltration of small cells which only spares the lumen. The finest processes of this infiltration extend further between the fat cells in the shape of leucocytes arranged like a chain of pearls, thus forming a network, the lumina of which are represented by the fat cells. Primarily then the perivascular lymph sheaths and lymph crevices are the seat of the inflammatory process.

The connective tissue, so far as not crowded out by the infiltra-

tion, has preserved its reticular character in the upper layer of the cutis; except where the superficial focus of infiltration is located we find a broad band of straight, parallel, closely adjacent connective tissue fibers, with extremely rare nuclei, rising perpendicularly from below. From this connective tissue bundle, which evidently has to be looked upon as a cicatrix, processes spread into the surroundings and enclose the single tuberculous foci. The elastic fibers appear compressed in the papillary portion of the connective tissue, in places inflated into more compact masses. They are entirely missing within the infiltration, in its surroundings they are visible only in scanty fragments. Tubercle bacilli, notwithstanding numerous examinations made for that purpose, could be demonstrated neither in the sections from the skin nor in those from the gland; the latter presented the picture of a large cheesy tubercle with numerous giant cells.

The case was certainly a remarkable one, because we met with so many different manifestations of tuberculosis of the skin in the same patient; but the form which it assumed in the focus on the cheek could not fail to awaken our special interest. We found an exulcerated lupus on the foot, typical "*gommes scrophuleuses*" on the thigh; in the inguinal region, forms reminding one of tuberous syphilides, some fully developed or already cicatrized, others in the early stages of development; finally we found in the submaxillary region a partly ulcerated, tumor-shaped patch. Its tuberculous nature is *a priori* established, but it can not successfully be arranged in any one of the ordinary forms of tuberculosis of the skin. Prof. Riehl identified this form with a disease observed and designated by him before as *Tuberculosis fungosa cutis.* How far this identification is justified will best appear from the consideration of Riehl's case. Therefore I shall briefly report its history, the more so as it is the only case of this kind heretofore recorded in literature. (Riehl, *Beiträge zur Kenntniss der Hauttuberculose; Verhandl. d. deutschen dermatolog. Gesellschaft,* IV., —— 1894.)

The case is one of a woman fifty-three years of age, whose right leg had been amputated about five years ago on account of a fungous affection of the knee joint. On the anterior and interior aspects of the stump an ovoid patch, eighteen centimeters long, was found, the surface of which was covered with abundant crusts. After their removal the skin appeared thickened, prominent, bright red with moderately dense infiltration, nowhere attached to the underlying tissues. The surface of the patch presented in places shallow, irregular ulcer-

ations formed by the confluence of smaller losses of substance, and some exuberant granulations with recently overspreading skin. The borders of the plaque, sharply defined from the healthy skin, appeared on closer inspection almost everywhere composed of pinhead-sized ulcers, which were covered with gray-yellowish pus. Near the point of the amputation stump there were two similarly affected, detached patches, also one near the vulva, covered with rupial crusts, not larger than a florin, which in part presented undermined edges. On the left thigh as well as over the left trochanter, there were irregularly defined scars which disclosed small, soft, brownish infiltrations, partly covered with crusts. The glands of the inguinal region were hardly enlarged.

Histologically, an extraordinary dense infiltration was found, tubercle ranged against tubercle, numerous ones in the state of caseous degeneration; in every second or third section one to three bacilli.

We have then in both cases an infiltrating form of tuberculosis of the skin, which shows absolutely no analogy with *tuberculosis propria* or with *tuberculosis verrucosa cutis*, neither in the clinical nor in the histological picture. From lupus vulgaris and in particular from *lupus tumidus*, it is distinguished clinically by the absence of the primary lesions, the circumscribed lupus nodule, and histologically by the extensive cheesy degeneration. The affection shows the nearest resemblance to scrophuloderma, and forms similar to our case have heretofore been placed under this class. Indeed, *tuberculosis fungosa* might well be included with scrophuloderma, insofar as we comprehend under that name all cases of secondary tuberculosis of the skin; that is, those which result from tubercular processes developing beneath the skin. But, surely, the present definition of the term scrophuloderma is going too far, so that entirely different clinical forms, which do not agree with the established picture of scrophuloderma, are included in one group by the authors. Not to mention that all kinds of tuberculosis of the skin may under certain circumstances develop secondarily, attempts, principally initiated by French authors, to eliminate exact types of disease from the group of the scrophuloderma, have been highly successful, so that at the present time the term appears considerably narrowed. The erythema induratum (Bazin), for instance, has almost universally been acknowledged, and quite a number of types of disease which formerly were included under that heading, are now found united under the term of the tuberculides. In like manner the case under discussion

reveals sufficient diversities in the clinical and histological picture to justify its withdrawal from the scrophuloderma. As the type of this class we must regard the "*gommes scrophuleuses*," those moderately firm nodes, slightly raised above the level of the skin, which, rapidly softening, form shallow ulcers with irregular, widely undermined edge. On the contrary we find in *tuberculosis fungosa cutis* a plate of infiltration within the cutis and above it an intumescence caused by granulation tissue, the best part of which has become cheesy. Its perfect analogy with the fungous process of the bones and joints is also proved by the formation of fistulous perforations, which pervading the entire tumor, lead to the formation of crateriform ulcers on its surface.

In Riehl's case the genesis of the process could easily be traced; the fungous inflammation of the knee articulation, which had preceded, distinctly pointed to the bone as the primary focus. In our case it was impossible to demonstrate such a focus, unless we are inclined to credit the patient's report that the affection commenced with a painful swelling starting from a tooth, and to accept it as supporting the assumption that possibly a tuberculous ostitis and periostitis may have preceded the cutaneous process. But even if such a clue were missing, on the strength of the clinical picture—the wide extent of the focus, the multiple fistulous openings, and finally in consideration of the patient's age, at which we but rarely see the scrophulous inflammation of the glands involving the skin—we would be led to a tuberculous process of the bones as the starting point from which the inflammation spread by way of the lymph channels towards the surface, as, indeed, taught by the histological examination. This mode of transmission of the inflammatory process, which quite uniformly, parallel with itself, pushes through all layers, must be looked upon as one of the characteristic features of the process. Still, as Riehl asserts, it has been incorrectly forced into the scheme of the scrophuloderma on the part of the dermatologists, while it displays every analogy with the fungous inflammations of the surgeons. And from the dermatological standpoint we must separate, on the strength of the clinical picture alone, the firm tumors of tuberculosis fungosa with their tendency to the formation of multiple fistules, from the diffuse soft infiltration of the scrophuloderma, leading to the formation of abscesses, notwithstanding their identical etiology.

While in this first case the tumor-like appearance of the tuber-

culous focus was caused by the excessive development of the specific inflammatory process, the tumor-shaped feature in the second case, to be immediately reported, was due to essentially different anatomical conditions. The history of the case is as follows:

History: The patient's parents are alive and in good health; he has neither brothers nor sisters. The patient himself, aged twenty years, has never been sick, does not cough nor perspire at night. Four years ago he suffered an injury above the right ankle joint, ostensibly from a fall; subsequently there occurred a swelling of the foot, which extended from the malleolus internus to the region of the metacarpo-phalangeal articulation of the big toe, and, about three weeks after the injury, was laid open by a cut fifteen centimeters in length, whereupon a copious quantity of pus was evacuated. (Inquiry made at the surgical clinic of St. Elizabeth's Hospital, where the incision had been made, revealed that at that time the diagnosis of a simple cellulitis had been made.) Later on, in the scar and its surroundings, nodules would appear over and over again, which opened, discharged some pus and healed again. Since six months the affection has attained its present extent.

Present Condition (March 19, 1903): Patient strong, well nourished; skin moderately pigmented, well oiled, elastic. Over the back of the right foot, from the malleolus internus forward to the metacarpo-phalangeal articulation of the big toe, there stretches a protuberance, about thirteen centimeters long and three centimeters broad, which rises above the level of the surrounding skin by the width of a finger and broadens in its center in the region of the head of the talus. The surroundings of this tumor are slightly reddened, its borders are abruptly sloping, in places even overhanging; owing to numerous cicatricial depressions which cross each other and are interlaced in various directions, the surface of the tumor attains an irregular lobulated aspect. The tumor in its entirety is of a livid color, the epithelium along its surface is thickened in some places, in others thinned, glistening, in parts entirely missing. Here and there small, shallow, up to lentil-sized ulcers with sharp edges, are visible, besides numerous small, poriform canaliculi, from which, by pressure on the spongy tissue, partly opaque serous fluid, partly thick creamy pus and cheesy masses are discharged. In some places within the limits of the bluish-red tumor there are interspersed lentil-sized, dark brown infiltrations.

Under chloroform narcosis on March 30, the entire area was

excised. On April 7, the operation wound was covered with Thiersch flaps and on April 25, the patient was discharged; the wound was completely covered with epithelium except a small islet about the size of a penny.

Histological Examination: The corneous layer is quite variously developed in different places; in some it appears thinned, reduced to the limit of one layer of cells, in others thickened, often considerably, surpassing the combined height of all other epithelial layers together. Everywhere it contains numerous stainable nuclei; only in a few places, principally where the corneous layer is not thickened, it shows a decidedly lamellar structure, while in other places, with thickened epithelium, we are still able to perceive distinctly polygonal cell contours. Within these, vesicular nuclei with well stained nuclear bodies and also granules of keratohyalin and flakes of eleidin are visible. The stratum granulosum is everywhere distinctly developed, notwithstanding the nucleate corneous layer. Within the remaining layers of the epithelium we find more or less numerous migrating leucocytes, the interpapillary processes considerably lengthened, in places branching, but only very rarely do we meet with nuclear divisions.

The corium is the seat of an extensive small-cell infiltration which, in the papillary layer, principally attached to the blood vessels, has assumed quite diffuse proportions in the deeper strata. The intensity of this infiltration is varying; here the single cells, clearly distinguishable, are lying loosely next to each other, there they form dense heaps and lumps. The infiltration is mostly composed of mononuclear round cells; however, there are also present some polynuclear leucocytes, particularly in the small abscess cavities, which, scattered through the corium, appear as small hollows bordered by a dense infiltration wall and containing besides leucocytes nothing but cell detritus and scanty remnants of fine connective tissue fibers. In methylene blue stained sections it is surprising to find the infiltration rich in plasma cells, and particularly in the upper layer of the corium, numerous well stained mast cells are found. The œdema which accompanies this infiltration in some places becomes so excessive that the infiltration cells are embedded in a loose meshwork.

Besides these evidences of an acute inflammatory process there are also conspicuous those of a chronic one. In some places of the specimen, particularly in the region of the hair follicles, there are foci, which present in the center a cheesy area with giant cells, surround-

ed by a more or less broad infiltrated border. The blood vessels, particularly the deeply seated ones, appear enormously dilated and show walls greatly thickened in proportion to the lumen. Still more pronounced changes are exhibited in the lymph vessels; besides being considerably increased in numbers they form *large cavities*, which by the palisade arrangement of the endothelial cells distinctly indicate the participation of the wall elements. With decreasing intensity the inflammatory conditions can be followed deeply into the fat tissue. Staining for bacteria showed scanty diplococci, principally around the abscess cavities; no tubercle bacilli.

Certainly in this case the clinical aspect of the diseased area suggested much rather a tumor (sarcoma, mycosis fungoides) with conditions of a secondary inflammation. The history and the fact that, notwithstanding the persistence through a number of years, the focus of disease remained single, pointed to a "chronic granuloma." Taking into consideration the limpness and softness of the tumor masses, and the absence of all other manifestations of lues, there would only be the question of tuberculosis. This diagnosis could be confirmed by the histological examination. In this connection we have principally to rely upon the undisputed occurrence of typical tubercular foci, and must not put too much weight on the unsuccessful search for bacilli, since from other forms of tuberculosis of the skin we are well acquainted with the difficulties of their demonstration. Nor is the pronounced acute inflammation, which in our case accompanied the chronic tuberculous process, a new phenomenon. Do we not see this very same picture in every form that is excised during the tuberculin reaction? With the excessive interstitial œdema, with the abundance of migratory cells; the small circumscribed foci of necrosis; with the typical dilatation of blood vessels, it is such a typical picture that Unna could use it as the paradigma for his "sero-fibrinous inflammation of lupus." What, in our case, has been the cause of the secondary inflammation, cannot be decided with absolute certainty. Possibly the causes were purely mechanical ones, as the stasis in the lower extremities, the permanent irritation by the foot covering, the preceding phlegmonous inflammation, which created unfavorable conditions of nutrition and thus favored the secondary colonization of pus organisms. Although such an occurrence is rendered plausible by the demonstration of diplococci in the tissues, and by the abundant suppuration, we are also aware that the tubercle bacilli and their toxines alone are sufficient to cause such a reaction of the tissues. In consequence of these con-

tinued acute attacks of inflammation, a further atypical condition has arisen which becomes manifest in the histological picture: the multiplication and dilatation of the lymph vessels. This condition I find mentioned in literature but once, in a case published by Doutrelepont. Clinically it showed a picture perfectly analogous to the one in our case; the affection was seated on the ear and on the nose, and the establishment of the diagnosis clinically was possible from other typical lupus foci present. Histologically, between typical tuberculous foci, round, oval or channeled cavities were found, lined with endothelium and more or less filled with leucocytes, so that Doutrelepont at first thought of a combination of lupus and congenital lymphangioma. This opinion he dropped on account of the definite statements of the patient, to come to the conclusion that the lymphangioma originated from other causes independent of the lupus. In our case the explanation of this inflammatory formation of lymphangioma became essentially easier by the evidence of a condition of intense inflammation, and we do not doubt but that this was the principal cause of the tumor-shaped picture of this form of tuberculosis.

Conditions similar to the case here reported seem to occur with greater frequency in the countries along the Rhine, as appears from a remark made during a discussion by Doutrelepont and from a perusal of the literature. For instance, we find five cases published by Doutrelepont,[1] one by Hahn,[2] from the clinic in Bonn; one case has been reported from the clinic in Prague by Pick.[3] In all these cases the similarity to sarcoma and mycosis fungoides has been insisted upon; however, in most instances the diagnosis was rendered easy by other lupus foci; but in three cases, where these were not present, Doutrelepont made the emphatic statement that he was surprised by the histological demonstration of tubercules. All authors assign this affection to *lupus tumidus*, in order to make any assignment possible; we, ourselves, on the strength of the clinical and histological picture, accept the case as an atypical form of lupus tumidus, for the origin of which a phlegmon has created the *locus minoris resistentiae*.

Therefore, we see that, in the first of the reported cases, which as tuberculosis fungosa cutis has to be assigned to the processes with a tuberculous basis, the powerful development of the tuberculous tissue itself is responsible for the tumor character. In the second one,

[1] *Deutsche Med. Wochensch.* 1892, p. 1033; *Archiv. f. Dermat. u. Syph.*, 1894, Bd. XXIX., p. 211.

[2] *Archiv. f. Dermat. u. Syph.*, 1890, p. 483.

[3] *Verhandlz. u. Congr. d. Deutsch. Dermat. Gesellsch.*

which belongs in the lupus group, the tumor formation is based on the secondary inflammation which accompanies the process and on the changes in the lymphatic system. It was the purpose of this communication to call attention to these rare manifestations of tuberculosis, so that they may be early recognized and receive the benefit of a radical cure.

I am greatly indebted to my esteemed chief, Professor Riehl, for the use of the material and for his kind assistance in the working out of the same.

A CASE OF REINFECTION OF SYPHILIS.

By Hermann G. Klotz, M.D., of New York.

Read before the twenty-eighth annual meeting of the American Dermatological Association, Niagara Falls, June 2 and 3, 1904.

IN this era of histological and bacteriological studies and of radiotherapy, syphilis does not offer an attractive field to the dermatologists. Its study, however, is still full of interest on account of, or in spite of, its mysteriousness, which so far has baffled all endeavors to reveal its true nature. If we could only find some means by which we could prove beyond doubt at any time that syphilis has been entirely eradicated from the organism of an individual heretofore infected with the same, the disease would at once be freed of its most offensive and oppressive feature. So far, the assurance that a patient was cured can be obtained only by the demonstration of a new infection, certainly a questionable advantage to the patient. Nevertheless, the proof of the actual occurrence of reinfection must be accepted as establishing the fact that syphilis can be cured, or, as I should rather express myself, can be entirely eliminated from the human organism. If even a small number of patients have again been rendered susceptible to the infection of the syphilitic virus, others besides this small number must be in the same condition, for we can hardly assume that every person that has been cured is bound to again become infected. The question of the reinfection of syphilis is therefore quite an important one. The number of cases of reinfection which have been reported as such is not a small one, but on carefully and critically sifting but a very slight percentage will stand above doubt or suspicion. R. W. Taylor up to the edition of 1900 of his book had observed but five cases. E. L. Keyes in 1890 confesses that he had himself not observed a single case. Under these circumstances it

seems justified to report the only case that has come under my observation and to subject it to your critical judgment, the more so as the history itself of the case presents some interesting and unusual features.

F. K., born 1847, in Germany, a furrier by trade, came first under my observation in the summer of 1882, in the German Hospital of New York. He had been admitted for a large gummatous infiltration over the middle portion of the sternum and the adjoining ribs of the right side, several gummatous periosteal intumescences of the right tibia and a number of peculiar firm strands and plates imbedded in the extensor muscles of both thighs, principally the left quadriceps femoris. He was at that time in a rather anæmic, almost cachetic condition, although originally of strong build and well developed muscles. He had generally been in good health; when 17 years of age he acknowledges having had gonorrhœa but does not give a history of any other infection, chancre or secondary symptoms whatever. All the important organs were found to be in good condition, particularly the kidneys, as the urine was always found to be free of albumen or sugar. I have later on had the opportunity of seeing the patient's two children, a boy born in 1872 and a girl born in 1874. They were both well developed and free from all stigmata of hereditary syphilis; they both had enlarged tonsils and were subject to attacks of acute tonsilitis.

Soon after leaving the hospital after an extensive and successful treatment by mercurial inunctions and iodide of potassium, the patient began to complain of pains in the right side of the thorax, aggravated by sneezing, coughing, etc., for which a cause could not be found in the internal organs or in the wall of the thorax; they were not materially influenced by iodide of potassium until about December the fifteenth, when a swelling of the right third rib rapidly developed simultaneously with a swelling of the inner margin of the right tibia, very sensitive on pressure, and pains in the muscles of the left thigh. Early in December, on both legs, more prominently on the left one, a number of small, slightly infiltrated, scaly patches had made their appearance. After taking iodide again, combined with local applications of mercurial ointments, within several weeks this eruption had entirely disappeared, the swelling of the tibia and the pains in the thighs were greatly reduced and the rib was nearly reduced to its natural size after showing at one time quite considerable enlargement. The treatment was continued with but slight intermis-

sions until the end of April, 1883. By that time the sternum, the rib and the tibia showed a moderate thickening of the bone, without any abnormal sensitiveness; in the muscles of the left thigh some not sharply defined resistant nodes could be felt. In October, 1883, after the iodide had been omitted for several months, the inner border of the tibia remained thickened; in the thighs a certain feeling of tightness remained. Although the iodide was resumed, by the end of November the tibia suddenly began to swell more rapidly, a circumscribed area became red, softened and broke down. After the evacuation of a small piece of bone these symptoms subsided and on January 7th, 1884, only a small fistulous opening remained; no rough bone could be detected on probing.

In October, 1885, after twenty-one months, the patient presented himself again, stating that he had felt quite well except for occasional pains in the back and in the right thigh; the latter within the last month had begun to swell considerably, causing much pain and difficulty in walking. Over the inner aspect of the right femur the skin appeared red and swollen; underneath there was a firm infiltration of the muscles, apparently not affecting the bone, quite painful on pressure. Iodide of potassium, ice-bags and iodoform ointment were ordered. This condition assumed quite an acute character within the following weeks, at one time, and after a greater muscular exertion, accompanied by œdema of the leg and some fever. After November the 15th, mixed treatment was given. Then the pain and the symptoms of acute inflammation had almost disappeared, but a hard, diffuse, not very sensitive swelling remained, extending rather deeply between the muscles, though apparently not attached to the bone. On closer examination the swelling seemed to be composed of several smaller tuberous tumors. Mixed treatment and mercurial plaster locally were ordered. This affection of the muscles, probably gummatous, extended its very variable course through 1886 and 1887 into the spring of 1888, sometimes under the symptoms of a more or less acute inflammation, sometimes without any pronounced symptoms. Iodides were regularly continued from November, 1885 to June, 1886. Between June 27th and October 10th, six injections of calomel *à vapeur* were made, containing from 100 to 50 milligrammes (0.10 to 0.05) of calomel. Some of them caused considerable local swelling but no abscess; only after the first injection of the full dose the general effects were somewhat severe. The curative effects of the treatment, however, were quite satisfactory; the swelling greatly

diminished, and the division into several smaller tumors could be distinctly felt. After the injections iodide was resumed.

After about six weeks, by the end of November, the skin again became red and infiltrated with œdema of the entire lower leg. On December 15th over the lowest portion of the tumor, which itself appeared smaller and less tense, the skin to the extent of a dime became scarlet red and bulged out like a bulla. On account of an intercurrent acute tonsilitis this condition was not interfered with, but on December 20th the area had become much harder and finally two small openings had spontaneously formed, from which a considerable quantity of a clear watery fluid oozed out; only after continued squeezing the liquid became turbid. This wound continued to discharge a more or less watery, yellowish fluid, free from any odor, in spite of frequent irrigations with solutions of permanganate of potassium, etc. Early in April, 1887, a small piece of bone had been discharged from the wound, followed by a decided decrease of the secretion. About the same time the patient suffered from an infection of a finger, probably derived from an unclean skin on which he had been at work, and accompanied by rather high fever. Otherwise the general health was not much affected throughout this period and he usually attended to his work. In the fall of 1887 a larger flat piece of bone was removed through the wound, which temporarily healed up. Some swelling and occasional pains persisted until after the elimination of another small fragment of bone during the summer of 1888. Since the injections had been stopped iodide of potassium in moderate quantities had been taken with short intervals.

The year 1889 passed without any important events, except on several occasions some pain and slight intumescence on the right side of the sternum. They were easily controlled by iodides. In September, 1890, the gummatous periostitis of the sterno-costal region became again aggravated, so that over a small area fluctuation could be felt, but iodide again prevented its further development and in the spring of 1891 the symptoms had entirely subsided. Soon after, however, the left thigh began to swell under considerable pain, apparently due to a periostitis of the os femoris, as the muscles remained soft and free of tumors. Early in 1892 the skin over this swelling broke down, leaving quite a large cavity, discharging a purulent and sanguinolent fluid. Under drainage and appropriate dressings the wound closed in June, after a small piece of bone had been removed.

In April, 1893, there appeared another hard lump near the lower

portion of the right thigh, with a decided tendency to softening. In spite of the administration of iodide the skin again broke down, and a large amount of purulent fluid was evacuated.

Until the spring of 1894 no symptoms were observed of the former affections. On June 9, the patient presented himself with a large, red, fluctuating swelling on the right side of the sternum, which threatened immediate breaking down of the skin and the formation of a large ulcer. It had begun to form within a few weeks, notwithstanding the immediate resumption of the iodide. To prevent, if possible, the ulceration, I immediately made an injection of 10 centigrammes of calomel. On June 17th swelling and redness had so far subsided as to allay the fear of ulceration, but as the injection had caused quite some discomfort further injections were deferred. The patient waited until July 7th. A perforation of the skin had occurred and a small quantity of pus was discharged. After two more injections of the salicylate of mercury the gummatous swelling had entirely disappeared on August 26th; only the right thigh had temporarily caused some trouble. Another injection of the salicylate was administered and the patient was advised to take iodide of potassium for some time. He was seen again October 23rd of the following year, 1895, when he reported that he had not taken any more medicine since February. There was no longer any active trace to be found of the gummatous processes; some œdema of the left leg had been observed, probably due to mechanical obstruction of the circulation. Bandaging was recommended; the urine was found to be normal.

I did not see the patient again until July 3rd, 1901, after the lapse of almost six years. About ten days previously, somewhat more than a week after exposure by sexual intercourse, he had noticed a small blister on the prepuce, which soon opened and left a sore. This slowly increased, accompanied by swelling of the prepuce. I found a pea-sized flat erosion, surrounded by slightly indurated tissue, the typical picture of a "normal" primary lesion of syphilis, œdema of prepuce, no swelling of the inguinal glands. I abstained from all cauterization, dressed with bichloride solution and ordered moist applications of sulphate of copper 1:500 (about 1 grain to the ounce). Two smaller erosions were seen to the left of the larger sore. On July 7th the swelling of the prepuce had subsided; the smaller erosions were not changed; the larger sore still indurated though slightly less. July 13th, little change in the appearance of the sores, the smaller ones slightly indurated, the inguinal glands distinctly enlarged,

but hardly sensitive on pressure. Nosophene ointment (ten per cent.) was used.

On August 11th the larger sore was almost entirely covered with epidermis. It appeared as a bean sized typical induration; the enlargement of the inguinal glands had not much increased, but a distinct indolent scleradenitis was undoubtedly present, somewhat more pronounced on the left side. Since about a week the general health had been impaired; pains in the throat and chest, sleeplessness, headache, followed within the last few days by an eruption on the skin of the face and trunk. Indeed, a quite numerous maculo-papular syphilide covered the forehead, cheeks, chest, and in a particularly characteristic way the bald scalp, some solitary papulo-macular lesions were on the forearm and on the palms; in the throat the condition of a moderate angina was found; altogether a combination of symptoms as typical and characteristic of the stage of development of secondary syphilis as you ever can expect to find, appearing within six to eight weeks after infection. I prescribed bichloride of mercury, 20 centigrammes; iodide of sodium, 12 grammes to 100 grammes; a teaspoonful three times a day. On August 17th, the primary sore was entirely covered with epidermis; the swelling of this sore and of the inguinal glands was somewhat reduced; the general symptoms had disappeared with the exception of the headache, which he had felt now and then since a spell of very hot weather early in summer. The bichloride was continued without the iodide. On September 2nd, the syphilide had almost disappeared on the scalp as well as on the chest; very little induration remained on the site of the primary lesion; the inguinal glands were reduced to almost normal size; in the throat no specific conditions could be found. On October 3rd, the residua of the symptoms were still less pronounced.

On November 25th, 1901, when the bichloride had been taken quite regularly, no trace of the former affections could be found, but since two days there had appeared a diffuse congestion of the conjunctiva of the left eye, most pronounced around the cornea, and a slight cloudiness of the iris accompanied by moderate pain. The medicine was continued and atropine applied locally. These symptoms continued somewhat aggravated until on December 3rd, when an injection of the salicylate of mercury (0.10) was made; within two days all objective and subjective symptoms were greatly reduced and after two more injections on December 29th the eye appeared perfectly normal. Injections were repeated on Dec. 11th, 20th, 29th, Jan. 11th, 25th, 1902.

On February 10th the patient reported generally good condition, now and then slight trouble in the throat, but he complained of the continuance of a dull pain in the left temple, which appeared from time to time with varying intensity, usually not at night and without disturbing the sleep. The injections were continued in intervals of about two weeks until May 5th, when the 13th injection since December 3rd was administered. In March, a number of slightly scaly papules had appeared on both forearms, but had entirely disappeared within four weeks; no other symptoms of syphilis could be found except slight abrasions on the lips on several occasions; the headache, however, continued its intermittent attacks of not very severe character, not influenced by citrophene, iodide of sodium and quinine; only within the last few days it had become less severe and had almost disappeared. Throughout this entire period the urine was regularly examined, always with negative result. The pupils and eye muscles were regularly examined and always acted normally; pulse and heart were regular. All other functions and organs were in good condition, so that no cause for the persistent headache could be found. The patient had been a moderate smoker, but had restricted smoking to a minimum. The application of the 13th injection on May 5th was not accompanied by any unusual symptoms. Those of embolism are quite well-known to me and would not have escaped my attention.

On May 7th, I was informed that on the morning of the 6th, while standing in front of his washstand, the patient suddenly fell to the floor and became unconscious. When after a short time he regained consciousness, the left upper and lower extremities were found to be paralyzed, with some irregularity of the speech.

The patient was left under the attendance of the physician of his sick lodge, who kept me informed of the progress of the condition; but on April 23rd, 1904, at my request, he called at my office. The symptoms of the hemiplegia have gradually disappeared, leaving an impairment of the movements and of the muscular strength, but no disturbance of speech. He has not taken any specific medicine and is otherwise in fair health. Within the last few weeks he has felt some pain in the epididymis on both sides. Here small but rather sensitive nodules can be felt; on the glans penis and on the scrotum a number of slightly infiltrated, scaly patches are found, sufficient reason to recommend a course of mixed treatment.

R. W. Taylor has treated the question of reinfection of syphilis more carefully and more critically than most authors of books on

syphilis which I have consulted. In the older edition of 1883 he says:

"Before we can admit a second attack of syphilis, we must have an undisputed history of the first infection; we must have proof beyond doubt of a second chancre, which is followed by well marked enlargement of the inguinal ganglia, and later on by secondary manifestations of an undoubtedly syphilitic nature. Without the occurrence of lesions similar to those of the first attack, we cannot admit the claims of any case of syphilitic reinfection."

In the later edition of 1900 he says:

"Before a given case shall be accepted as true and beyond controversy, the following facts must be established as clearly as possible: In the first attack, the existence of a true hard chancre followed by characteristic adenopathies and a clear history of the secondary stage and its lesions and perhaps a tertiary stage. Then a sufficiently long period of time should elapse in order to show that the diathesis has become extinct. (Cases where only 1, 2 or 3 years have elapsed are apocryphal.) No case is worthy of consideration in which the interval between the cure or apparent cessation of the first attack and the onset of the second one is at least not under 5 or 6 years. Very long intervals inspire one with moderate credulity."

I am perfectly willing that the case here reported be adjudicated by the standard of Taylor, although I should prefer a combination of both editions. Notoriously in many cases of undoubted syphilis, more frequent in women than in men, we see secondary symptoms, or more commonly only the so called tertiary manifestations, where there is absolutely no history, and no vestige whatever of an initial lesion or of secondary eruptions, etc. I, therefore, believe that we only need the proof of undoubted symptoms of syphilis at a certain time before the appearance of the second chancre, by actual observation, but not a vague and unsupported history of syphilis. Now in my case there is no flaw in the second infection. More than six years after symptoms of the previous disease had absolutely disappeared we find a typical primary lesion within a certain time after exposure, a moderate but distinct enlargement of the inguinal glands, not less than I have observed in numerous cases. Then follows in due time a typical syphilide, later on an iritis and another papular eruption. Of the hemiplegia I shall speak later on; it is not essential to the paradigma of early syphilis. The decision will then depend upon whether the chain of symptoms and manifestations which were observed on the patient during 12 years were unquestionably syphilitic or might have

been produced by some other cause. I waive all claims to the admission as a syphilide of the scaly maculo-papular eruption observed at one time on the legs. It would be important to produce the existence of one of the usual secondary symptoms, and it is well known that such eruptions may accompany well defined tertiary manifestations. My notes show that at the time the eruption impressed me as a syphilide, but after such a long time I do not recollect its appearance with sufficient exactness. However, the affection of the sternum and of the adjoining ribs and the swelling of the third rib hardly admit of any other interpretation than that of syphilitic gummatous periostitis. Only a tuberculous affection could be thought of, but it would surely not heal under anti-syphilitic treatment alone without an energetic surgical interference and without more effect on the general health of the patient during such a long period. The process which affected the tibia was of the same character. The changes which occurred on both thighs are perhaps, more obscure, uncommon and uncertain though it would be very difficult to say what they really were if the diagnosis of muscular gummata and gummatous periostitis was rejected, particularly under consideration of the effects of the energetic treatment with mercury. But with the diagnosis of the different manifestations as syphilis sustained, there can be little doubt that the patient had once been infected with primary and secondary syphilis, unless Dr. Taylor will accept the hypothesis which I proposed several years ago, that tertiary manifestations of syphilis may be directly produced through inoculation from tertiary lesions of some other individual.

There is also a wide difference of opinions on the question of the gravity of second infections of syphilis. Some authors, mostly those who report reinfections within a short interval after the first disease, report a very mild course as the usual one. Taylor observed in all his five cases a very severe attack of the disease. In two instances it ended promptly in death. In our case, the final opinion must largely depend on the interpretation of the hemiplegic attack. I am not inclined to look upon it as directly connected with or caused by syphilis, not so much because it was not prevented by energetic treatment, but because the patient was at an age, 54 years, at which apoplectic attacks are not uncommon; he had been a hard worker, had been smoking and drinking beer, when in fair health not immoderately, but probably without much restriction after the subsidence of the original infection. Nor can I believe that the apoplexy was caused directly or indirectly

by the injection of the preceding day, as in the patient's experience, the injection of the salicylate usually produced but very slight disturbance of the general health.

Finally, I wish to call your attention to the decidedly greater and more lasting influence of energetic mercurial treatment on tertiary manifestions in comparison with iodides alone.

SOCIETY TRANSACTIONS.

BOSTON DERMATOLOGICAL SOCIETY.

Regular Meeting, March 29, 1904. Dr. G. F. Harding in the chair.

A Case of Dermatitis Medicamentosa. Presented by Dr. Harding.

A baby girl, five months old, presented a number of scattered tubercular lesions, varying in size from a pea to a five-cent piece, situated on the left side of the scalp and left cheek, on both legs from the buttocks to the ankles and about the anal and vulva regions. The trunk and arms were absolutely clear.

The lesions were considerably raised above the surface on a reddened base, and for the most part capped by a crust. About the arms they had become confluent forming plaques somewhat over an inch long and a quarter of an inch broad. These plaques were free from crusting and of a bright red color. About the vulva there was the suggestion of subcutaneous papules. None of the lesions showed any moisture and there was no evidence of pruritus. On the scalp over and in front of the anterior fontanelle there was a mass of thick brown crusts the size of a dollar.

The mother stated that the eruption began at the site of this crust as "a yellow fester" three weeks before, shortly afterwards lesions appeared about the anal and vulva regions, then the tubercles on the legs developed and finally the eruption broke out upon the cheek. The child had always been well, although somewhat fussy and before the outbreak occurred she was given some medicine to act on the bowels and also another preparation—for what purpose the mother did not know.*

There are three other children in the family, aged respectively sixteen, twelve and seven. They have never had any skin trouble and the mother has always enjoyed good health although at the present moment she has a papule at the left corner of her mouth.

All the members present considered the eruption to be due to some

* Subsequent to the meeting Dr. Harding learned that these prescriptions were as follows: 1st, a mixture of cascara and syrup of figs, and 2nd, Potass. Bromid. 4.; Syr. simp. Ess. Pepsin aa 30.; Aq. Cinnamon ad. 120. Of the latter preparation two bottles were taken.

bromine salt, but Dr. James C. White wanted, nevertheless, to consider iodine as a possible ætiological factor, remarking that although bromides usually caused these larger lesions, iodides could also produce similar lesions.

A Case for Diagnosis. Presented by Dr. C. J. White.

A Russian Jewess, aged thirty, married, was operated on one year ago, while nursing a baby, for an abscess in the left upper quadrant of her right breast, the scar of which can now be seen. A few weeks after this operation an inflammatory condition of the skin developed and has gradually spread until it has now attained the diameter of three inches with a totally retracted nipple as its center.

The skin is dull red in color, moist, slightly crusting, infiltrated and in two places shows moist, very superficial, ulcerations. The edge of this circular area is raised, somewhat vesicular and papular, sharply defined and more infiltrated than the enclosed skin. There has been some pruritus and at present a few hard glands can be felt in the back of the axilla.

A piece was excised from the border at the lower outer edge where the infiltration was the greatest. Hardened in alcohol, cut in paraffin and stained in various ways it shows the following characteristics. (Plate XXIX.)

The *stratum corneum* consists of a thin homogeneous layer showing in its deeper part elongated darkly staining nuclei which at times present small granules of kerato-hyalin.

The *stratum lucidum* is absent.

The *stratum granulosum* is absent, being fused with the horny layer just described. As one approaches the more normal parts of the sections this layer reappears as a single line of cells.

The *stratum spinosum* is greatly enlarged, showing broad interpapillary downgrowths, in places forty rows of cells in depth, with occasional indentations where the papillæ reach well up toward the surface. The germinate layer is intact along the dermal border, but as one examines the upper margins of the papillæ one notes the gradual loss of columnar arrangement and the final disappearance of the line of demarcation between rete and corium. In these places the nuclei of the spinous cells are wanting and many mononuclear leucocytes have filled the vacant spaces.

Examining minutely one of these interpapillary plugs one finds that midway between corium and stratum corneum the inter-epithelial spaces begin to widen while in places peri-nuclear halos appear and occasionally the nucleus is gone. From this point upward there is an abundant infiltration of mononuclear leucoytes. Despite these abundant signs of œdema the nuclei and the protoplasm receive the stains sharply everywhere.

Corium. The papillæ are separated by wide epithelial downgrowths. Between these pegs the papillæ extend up toward the horny layer and are filled with dilated capillaries whose endothelial cells are often swollen

and vesicular. Outside of these vessels are mononuclear leucocytes which in some instances almost fill up the entire papillary space, the supporting framework of which seems rarified.

The sub-papillary vessels are everywhere dilated and in some places are surrounded by mononuclear elements. The lymph spaces are markedly stretched and in some areas form wide lacunæ which are filled with coagulated, granular fibrin. The connective tissue is formed of slightly swollen and somewhat separated fibrillæ. Although œdema is thus so abundant throughout these sections the elastic layer is well preserved, but appears as rather straight and long fibrillæ.

Dr. Post regarded the retraction of the nipple as suggestive of malignant disease, but such retractions did not necessarily mean cancer.

Dr. Smith spoke also of the possibility of epithelioma, but would not commit himself to the diagnosis of Paget's disease.

Dr. James C. White said that he would call the case Paget's disease unless the microscope failed to reveal the characteristic changes now associated with this condition. He would expect to find, however, more intense inflammation than was present in this case.

Dr. Harding considered the case to be Paget's disease.

Dr. C. J. White said that this was the third case which he had seen during the last nine years where all the clinical characteristics of Paget's disease were present, but when he had subjected the skin to microscopical examination he had in each case failed to find the histological changes now considered pathognomonic of this disease. Here, as in the other two cases, he had been unable to detect the epithelial degenerations once believed to be psorosperms and the deep and compact cellular infiltrations described by Wickham. He was, therefore, obliged to call this case chronic eczema.

A Case of Raynaud's Disease. Presented by Dr. F. S. Burns.

The patient was a Russian Jewess, forty-four years of age. She had had diphtheria when twelve years old, but otherwise had always been well.

The present condition began four years ago during the winter. The fingers began to grow cold and red and continued in this state throughout the cold weather, the local asphyxia becoming aggravated when the temperature fell below 60° F. These symptoms subsided during the summer, but recurred with greater intensity with the advent of the following winter. Since her first attack the disease has returned with ever increasing severity as soon as the cold weather begins.

When first seen the hands presented the following appearances: Both hands were decidedly cold to the touch becoming gradually colder towards the finger tips. The skin of the fingers was smooth, shiny and of a pinkish-white hue, the color varying from the latter to a deep red as the fingers were exposed to a lower temperature. The nails of most of the fingers showed atrophy, those of the thumb and index finger of the right

hand being partly lost with the finger tips rounded, smooth and of a waxy-white tint, while the tip of the second finger of the left hand presented an ulceration which had resulted in exfoliation of the nail and was covered with a brownish-black crust. Flexion of the fingers of both hands was impeded. A radiograph showed atrophy of all the terminal phalanges.

Sensation to pain from pin-pricks was absent in all fingers and tactile sense diminished over the other parts of the hands. There were no vaso-motor changes elsewhere and the neurological examination was otherwise negative.

On entrance the patient was thin and poorly nourished. The general circulation was feeble, the pulse small and of low tension (90 m.m Hg.) Visceral examination was negative. Under the influence of digitalis, local mild stimulating applications and the general beneficial regime of the hospital, the patient's condition has improved considerably.

A Case of Acne Rosacea. Presented by Dr. Harding.

A man, a driver of trotting horses, aet. thirty-nine, shows on both cheeks deeply seated papules the size of small shot which simulate insect bites without any hyperæmia. The face is, however, somewhat diffusely reddened. Above the eyebrows there are small papules, while on the chin the lesions suggest a dry chronic eczema. These conditions have existed for two years, but more recently the process has developed upon the nose and the ears. The man is well and complains of nothing but the sensation of burning associated with his skin disease.

The members present considered the case to be one of rosaceous acne due in all probability to the man's constant exposure to the weather.

Dr. Harding said, in conclusion, that the lesions which suggested acne pustules had a very different look by day and when put upon the stretch resembled insect bites. On the other hand some of the erythematous lesions reminded him of lupus erythematosus. The papules, again, led him to think of a possible adenoma or some allied condition, for, according to the man's story, these same papules have existed without change for two years.

A Case of Lichen Planus. Presented by Dr. C. M. Smith.

The patient was a boy, ten years of age. The disease began just before Christmas, 1903, with intense itching about the knees followed by a red or purple eruption where the pruritus had been. The outbreak spread fairly rapidly and now covers the whole trunk and extremities with no lesions present on the face or in the mouth.

With the exception of the areas about the knees the eruption is discrete. There are several almost perfect circles found in different parts of the body, especially over the lower portions of the scapulæ. These circles seem composed of individual, small, flattened, dull red papules

which have coalesced. On the wrists are the most typical individual lesions which consist of discrete, flat, angular, shining papules, lilac to purple in color.

Dr. C. J. White considered the case to be lichen planus, basing his diagnosis on the individual lesions seen on the anterior aspect of the wrists. Elsewhere the lesions were very indefinite and he had never before seen lichen planus in so young a patient.* He also thought the small oval and circular lesions observed in the present case were somewhat suggestive of syphilis.

Dr. Burns thought that the diagnosis lay between lichen planus and syphilis.

Drs. Bowen and Towle called the case lichen planus.

Dr. James C. White added the diagnoses of pityriasis rosea and parakeratosis variegata to the possibilities and said that he thought that all the lesions were in an involuting stage and that the whole history was of too short duration to allow of the positive diagnosis of lichen planus.

Dr. Post made the diagnosis of lichen planus and said that he had seen nothing in the case to suggest syphilis.

A Case of Lichen Planus. Presented by Dr. C. M. Smith.

Mary L., forty-six, married. Previous history good.

Present illness. Was operated on last December for a lacerated perineum and while in the hospital noticed an itching over the sacrum but no change in the skin. The itching continued and after leaving the hospital the skin in this region began to grow red. These two conditions have persisted and have extended rather rapidly, until, at present, the trunk from the lower level of the scapulæ downwards is covered with a light red to purple eruption, which in places has coalesced and formed large areas of deep purple color. Over these areas there is quite a marked condition of cornification of the skin, most prominent over the original site of the eruption.

The outbreak is present also over the extremities. On the wrists one finds numerous, discrete, flat, angular, shining papules of the characteristic purplish hue. Thus far there has been no eruption on the mucous membranes of the mouth.

Dr. C. J. White thought that one should consider in this case eczema, a beginning mycosis fungoides and lichen planus, but was strongly inclined to the latter diagnosis.

Dr. Towle considered the case to be eczema.

Dr. James C. White made the diagnosis of lichen planus on account of the characteristic individual lesions on the wrist and on the lower legs

* Regarding the rarity of lichen planus in the young see The Meeting of the Berlin Dermatological Society, *Monatsh. f. Prakt. Derm.*, 5 Jan., 1904. Also *Brit. Jour. Dermat.*, vol. xvi., p. 137.

and also because of the cornification over the back, which, in this position, he looked upon as extraordinary, usually associating this change with the lower extremities. In regard to the suggestion of granuloma fungoides, Dr. White said that he had never seen such uniform, generalized, flat tubercles so crowded together in that disease.

Dr. HARDING called the disease lichen planus.

Dr. SMITH spoke of the unusually rapid development of the large uniform area on the back, which was very uncommon in his experience, but Dr. J. C. White said that he had observed a case where the whole surface had been covered within a fortnight, but this had occurred in a relapse.

A Case of Lupus Vulgaris. Presented by Dr. C. J. White.

The patient was a man, aged thirty-nine, a machinist by trade and in perfect health. So far as he knew there had not been any tuberculosis in his family.

About fifteen years ago an explosion of gunpowder filled his forehead, eyelids and upper face with grains of powder, many of which were removed, but some can still be seen in these regions. After the operation a few of the scars remained red and later began to scale. Various ointments were prescribed from time to time but the small papules gradually increased in size. A few years ago these lesions were bored into with nitrate of silver, but in a short time they reappeared.

At present there are four dull, brown-red, soft nodules deep in the skin of the forehead varying in size from a pea to the little finger nail and covered with a thin scale or crust. Cervical glands are to be felt.

Dr. JAMES C. WHITE doubted that these lesions could have existed practically unchanged for nearly fifteen years.

Drs. BOWEN and BURNS considered the case to be one of lupus vulgaris.

A Case of Lepra Anæsthetica. Presented by Dr. C. J. White.

The man was born in Antigua, of negro parents, twenty-six years ago. On the island there is a lazaretto where about one hundred lepers are confined. The family history is apparently negative although the cause of death of the father and one sister could not be determined. Until the age of twelve the patient went about bare-footed. Lately the man has been a servant in an English family and came to this country for a little vacation nine months ago.

About a year and a half ago the patient noticed numbness on the dorsum and toes of the left foot. This feeling gradually spread upward and in four months reached its present extent and has not increased since. Fourteen months ago a similar sensation developed on the right foot, but has remained much more localized, as we shall see. Two weeks ago (?), according to the man's story, the soft nodules about the left eye began to

appear. During the last few months the man has been losing weight and even while under observation—a period of three weeks—he seems to have grown thinner, although he feels perfectly well.

The present appearances are as follows: On the left leg beginning on the plantar surface of the foot and extending upward in front of the inner malleolus to the middle of the leg, then horizontally outward and almost around the leg, then downward and parallel to the anterior line until the foot is again reached behind the inner malleolus, runs a band about a half inch wide, infiltrated, dark pinkish-purple in color and covered with thin small scales with loosened edges. Enclosed within this continuous line lies a skin paler than the normal integument, much paler than the limiting boundary and dotted with occasional hairs, which are drier, shorter and less curly than the abundant hairs on the normal adjacent skin. This area of skin is dry, glistening and shows accentuated lines of cleavage. Finally this area is anæsthetic to pin pricks and is incapable of distinguishing between heat and cold.

On the little toe, over the meta-tarso-phalangeal joint, is a deep sulcus, anterior to which the skin is hard and calloused and the nail is gone. On the dorsal surfaces of all the other toes of this left foot are ulcers of varying sizes and depths, due to burning the foot by exposing it to the fire, one inch from an open stove door, and it was on account of this accident that the man came to the hospital.

The right foot. Here a well defined border is wanting because the whole dorsum of the foot up to the malleoli is involved. The skin is deeply pigmented, dry, practically free from hair and covered with large superficial scales. The posterior part of this abnormal skin is pale, free from scales and somewhat atrophic. The sensory disturbances are similar to those on the left foot.

The neck. On the left side near the clavicle appears a leucodermatous area with a periphery for the most part pinkish, but in one spot melanodermatous. This area shows no sensory changes and according to the patient's story has existed since childhood.

Left orbital region. The lower lid shows a tubercle and extending from this to the outer border of the orbit appears a red infiltrated area, which is continued on to the upper eyelid in the form of soft, yellow-red tubercles. Above, in the left eyebrow, is a firmer red nodule, the size of a pea. The patient says that "a darkness" appeared before the left eye after the appearances of these lesions and lasted for two to three days.

Nerves. The peroneal nerve can be felt as a firm elastic cord above the fibula of the left leg. The ulnar nerves are apparently normal in size but all the nerve trunks show some anæsthesia to firm pressure. The internal cutaneous nerve of the lower right arm appears as a firm, elastic, cord greatly increased in size and running downward and inward.

Dr. J. J. Putnam, of the neurological department of the Massachusetts General Hospital, kindly examined the electrical reactions and makes the following report: To Faradism there is no response in the left leg from the peroneal or the tibial group of muscles, while the gastrocnemius replies feebly and slowly to a strong current. In the right leg the reactions are normal, prompt and strong. To galvanism the responses in the two legs are quite similar to those obtained by Faradism. There is, on the left side, a typical reaction of degeneration in the anterior tibial group of muscles and an imperfectly developed reaction of degeneration in the gastrocnemius muscles. Here a current of ten milliamperes will excite a contraction anywhere.

Dr. A. Coolidge, of the Throat department of the hospital, kindly examined the patient's nose, pharynx and throat, but found nothing abnormal.

Dr. E. H. Smith, dean of the Harvard Dental School, kindly examined the man's mouth, which showed an extraordinary absorption and recession of the alveolar processes which, in some places, left the roots of the teeth exposed for almost their entire length. This condition, however, Dr. Smith would in no way attach to the fact that the man was a leper.

Dr. F. S. Burns, of the dermatological department of the hospital, kindly excised one of the small tubercles under the left eye and reported that the man felt practically no pain when the effects of the freezing mixture had vanished.

To all these gentlemen I wish to express my thanks for their part in this investigation.

The piece excised was hardened in alcohol, cut in paraffin and stained in many ways.

Epidermis. The stratum corneum consists of several layers of delicate fibrillæ. The stratum lucidum is absent. The stratum granulosum is present but poorly developed. The stratum spinosum consists of three to six layers of cells showing almost universally perinuclear halos with an occasional empty space from which a nucleus has disappeared. The columnar layer shows everywhere abundant, light brown pigment granules.

Corium. Papillæ are practically absent. Vessels appear at infrequent intervals and when present are surrounded by leucocytes in moderate amounts.

Below the papillary layer there is an abundant, evenly distributed infiltration of leucocytes. The connective tissue consists of swollen fibrillæ showing everywhere the presence of œdema, which, at frequent intervals, separates the bundles widely, thus forming empty lacunæ. Lymph vessels, however, as such do not appear. Sweat glands are present in large numbers and their supporting connective tissue shows the same characteristics of abundant lymphocytic infiltration and œdema observed

generally throughout the corium. The elastic system is practically absent showing only here and there in the region of the sweat glands a few disintegrated fibrillæ and granules.

Below all these structures appears the collection of cells which suggest strongly the presence of leprosy, but which, as we shall see, contain no bacilli whatever. (Plate XXX.)

These nodules consist in the center of slightly granular protoplasm poor in nuclei. When present, these nuclei are elongated, rather vesicular and suggest the nuclei of connective tissue running in all directions and planes; or again they are oval and vesicular and simulate the nuclei of the rete. Around these inner cells appears a wall of moderately densely packed lymphocytes, between which occur at intervals small vessels, which at times show endothelial changes—the whole structure suggesting a whorl.

Despite conscientious search, alone and with the aid of Dr. Christian of the Harvard Medical School, variously stained sections failed to disclose the presence of a single bacillus. This unexpected result stimulated still further research and a bacterial examination of the nasal secretion was undertaken with a similar and surprising negative result. The nasal discharge was clinically very slight and, after staining, revealed only cocci, diplococci and short, thick bacilli, sometimes occurring in pairs. As for leprosy bacilli or anything suggesting them the examination was totally negative.

All the members present regarded the case as anæsthetic leprosy.

Dr. James C. White suggested that the man be interrogated as to the presence of prodromal symptoms which seem to have been wanting. He did not believe that the failure to find the leprosy bacilli should necessarily exclude this diagnosis. Dr. Bowen, on the other hand, felt that this failure was a serious stumbling block in the way of such a diagnosis.

Charles J. White, Secretary.

DESCRIPTION OF PLATE XXIX.

Section under low power. Illustrates the depth of the rete, the invasion of mononuclear leucocytes, the œdema and the dyskeratosis.

DESCRIPTION OF PLATE XXX.

Fig. I. Low power. Shows the rather flattened epidermis, the general cellular infiltration and œdema, the lymph lacunæ and the deep nodules.

Fig. II. High power. Illustrates one of the nodules in detail, showing the central, enlarged and at times a-nuclear, cells and the surrounding wall of mononuclear elements, containing frequent blood vessels which on the right show some endothelial changes.

PLATE XXIX.—To illustrate Dr. C. J. White's Case for Diagnosis.

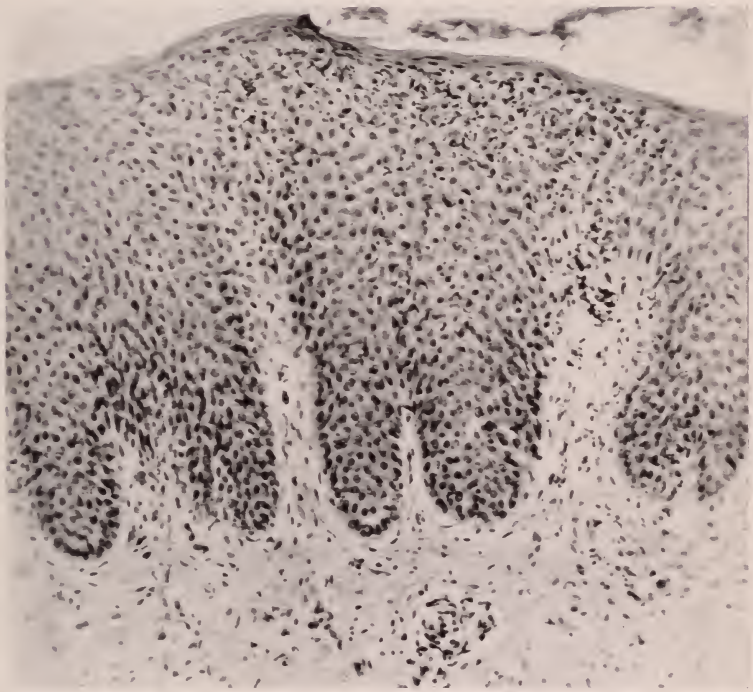

PLATE XXX.—To illustrate Dr. C. J. White's Case of Lepra Anæsthetica.

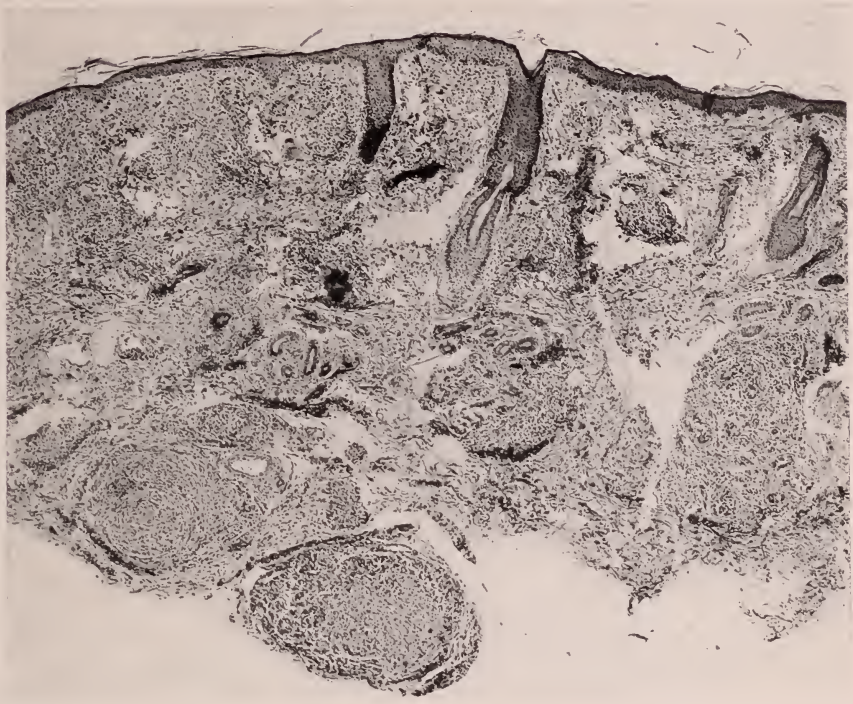

Fig. 1.

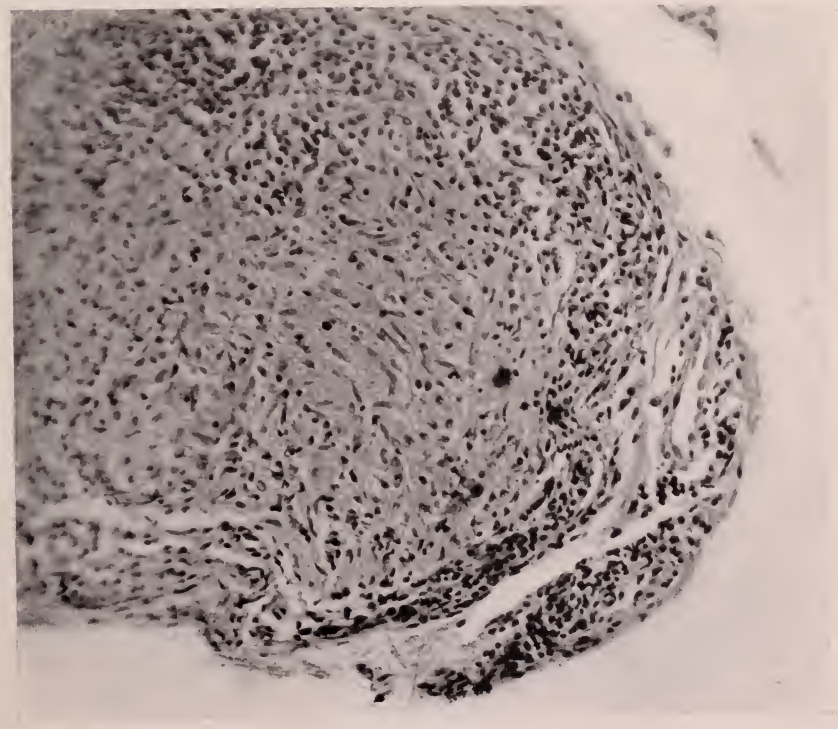

Fig. 2.

SOCIETY TRANSACTIONS.

BOSTON DERMATOLOGICAL SOCIETY.

Regular meeting, April 26, 1904. Dr. Charles J. White in the chair.

A Case of Verrucous Tuberculosis in a Child. Presented by Dr. J. T. Bowen.

The patient was a little girl of four, who came of a healthy family with healthy brothers and sisters. Two years previously, after an attack of measles, the present lesions made their appearance. The mother, a very intelligent woman, is quite sure that they all appeared at the same time, small at first, afterwards increasing in size. The child is otherwise perfectly well, with a bright color and has never had any illness or cough beyond that due to slight colds. The lesions are all of a verrucous character. There are two large rounded lesions on the back of the middle finger of the right hand, extending over on each side upon the lateral surface of the finger. The verrucous element is very pronounced and the lesions project from one-half to two-thirds of a centimeter. The base of the lesion is reddened and moderately firmly organized. Upon the same hand is a rounded, verrucous lesion situated over the first metacarpal bone, and another lesion completely surrounding the nail of the little finger. There is a similar lesion extending about the nail of the thumb of the same hand. On the inner side of the same hand there is another lesion rounded in shape, depressed in the center, where the process has evidently undergone involution, with a distinctly verrucous margin. This lesion is about one and one-half centimeters in diameter. There is still another rounded verrucous lesion of the palm of the same hand.

On the left hand there is but one lesion, which is situated on the palm and similar to that upon the palm of the right hand. There is one large lesion on the sole of the foot and several on the back and side of the toes. There is also a lesion on the inner surface of the right wrist and on the inner side of the right thigh just above the knee. The latter is small and deep-seated.

The lesions individually present all the characteristics of a verrucous tuberculosis, such as is commonly seen on the hands of adults from direct inoculation. The possibility of blastomycetic dermatitis was considered but microscopical examination was unable to demonstrate any fungus growth nor were there present the characteristic abscesses in the epidermis. The only possible source of infection that could be discovered might be drawn from the fact that the father had been operated upon for fistula in ano when the child was about one year old.

Dr. Harding considered the case to be tuberculosis, but thought the palmar and plantar lesions suggested the possibility of syphilis.

All the other members regarded the case as tuberculosis.

Dr. C. J. White alluded to the verrucous elements in the case which he regarded as distinctly uncommon in so young an individual.

Dr. James C. White said that the case was especially interesting in presenting so many foci of disease of apparently the same age and he was inclined to attribute the inoculations to the father before the time of his operation for fistula. In view of the frequently unexplained cases of cutaneous tuberculosis Dr. White thought it might be well to question whether domestic animals, as cats and dogs, might not be tuberculous at times.

Dr. Bowen spoke also of the numerous synchronous lesions which were distinctly unusual and alluded to McCall Anderson's series of juvenile cases of tuberculosis cutis described before the discovery of the tubercle bacillus.

A Case of Erythema Induratum? Presented by Dr. H. P. Towle.

The patient was a young woman, aged twenty-three, and an embroiderer by profession. The family and her own previous history revealed nothing of importance.

The present conditions have existed on the legs for two years. The lesions have never quite disappeared during this time, but are always worse during the spring and summer and grow better as the cold weather appears. Individual lesions have gone away, but new ones have always succeeded them. None have ever broken down. In the morning they are smaller than at night after a long day on her feet. When new lesions appear they cannot be seen but are discovered only by the touch. As they grow older the skin over them gradually becomes red. The lesions have always been limited to the lower legs.

Examination shows a well developed and well nourished woman of good healthy color, who, apparently, is quite free from other pathological conditions than the lesions about to be described.

On both lower legs are found subcutaneous nodules varying in size from a half inch to an inch in diameter. These nodules are chiefly on the sides of the legs but one on the left leg is over the tibia. On the right leg there are four such areas and on the left ten. Over the smaller lesions the skin is less red than over the larger. They are tender on pressure and are rounded with well defined borders and are firm to the touch. They are attached to the skin, but freely movable over the deeper tissues.

The general consensus of opinion of the members present was that the disease was a rather atypical erythema induratum.

Dr. Burns, who had seen the case during the summer of 1903, said that at that time the skin was of a deeper red and the lesions more infiltrated and confluent.

Dr. Harding said that the lesions were small for erythema induratum and wondered if some other tuberculide were not present.

Dr. Bowen said that the case under discussion was very similar to one shown by Dr. Towle at the December meeting of the Society (see Jour. Cut. Dis., 1904, p. 134), where the lesions were also small and numerous.

Dr. James C. White differed from the other members and said that there were present no lesions typical of erythema induratum. The case did not coincide with the description of the affection originally given by Bazin, nor with the series of cases reported by Dr. White, in 1894, as the first occurring in the United States. If the definition of the disease was to be extended so as to embrace such insignificant lesions as appeared in the present case, then no line could be drawn between erythema induratum and the general tuberculides of small type. Dr. White preferred to reserve the term erythema induratum for the nut-sized, discrete, deep-seated nodules which tend to break down and cause loss of substance.

A Case for Diagnosis. Presented by Dr. H. P. Towle.

The patient was a man, fifty years of age and a gardener by occupation. The family and past history of the man contains nothing bearing upon the present disease which began, perhaps, with an attack of scabies in August, 1903. In December the patient went into the New Hampshire woods to dig out pine trees for transplanting. Throughout this time he itched, although he had been treated for his scabies, and on January 18th he returned from the woods complaining of an eruption on the back of both hands. This outbreak has remained in situ ever since. The eruption began as a small papule which grew larger and larger and finally broke and discharged pus. This attack lasted five or six weeks and before the old lesions had disappeared new ones had come and are still present. These have been incised several times and pus evacuated, but the general condition of the hands did not improve.

At first there was no redness about the lesions, but after the constant use of various poultices the surrounding skin grew red and thickened. At present there is considerable pain, especially at night.

On entrance to the Massachusetts General Hospital (Dermatological ward) there were three lesions on the back of the right hand and one on the dorsum of the left. The smallest was about one-half inch in diameter, the largest an inch. They were round, elevated, about an eighth of an inch, with a flat top covered with friable, yellow crusts and with dark red, sloping edges. Upon pressure a drop of yellow pus exuded from several points in the crust. On removing the crusts a rough surface was exposed which was made up of closely-set hummocks of skin. These hummocks were round and had rounded tops; they were pale and glistening and free on all sides, being attached by their bases only. Between them, at several points, pus could be seen on pressure. The borders of the lesions were smooth and showed no pus-points. On the right hand from the knuckles

to the wrist and from side to side the skin was much reddened, thickened and slightly scaling. The lesions were tender when pressed. On examination the pus revealed the presence of ordinary cocci only. Apart from these cutaneous eruptions the man is quite free from pathological conditions, as far as can be learned from careful physical examination.

Drs. Burns and C. J. White thought that clinically the case resembled tuberculosis, but refused to make this diagnosis on account of the history of the case which was certainly against such an opinion.

Dr. Harding agreed with the above remarks and suggested the possibility of blastomycosis. He regarded the superficial dermatitis as due to the prolonged use of poultices.

Dr. Smith, who had seen the patient in the early stage of his disease, said that at first the eruption looked like a deep pustular dermatitis and was very painful. The man was given creolin soaks and poultices. Later the verrucous condition appeared.

Dr. James C. White said that tuberculosis should be excluded on account of the brief duration of the disease. He would call the condition an aggravated, follicular dermatitis of intense grade.

Dr. Towle, in conclusion, said that he had considered, in making his diagnosis, three diseases as possibilities: blastomycosis, verrucous tuberculosis and an unusual pustular dermatitis. His continued studies and observations upon the case had led him farther and farther from the first two diseases and more and more toward dermatitis.

A Case for Diagnosis. Presented by Dr. C. J. White.

The patient was a United States marine who had recently come home from the east, where he had seen service in the Philippines and at the siege of Pekin. In reply to the question he said that he had often gone about barefooted while in the Philippines and while there, about a year ago, a shallow, superficial ulcer developed on the instep of his foot which incapacitated him from work, and he was, therefore, sent home to the marine hospital in Chelsea. Treatment in this institution had caused the exulceration to heal, but when first seen by Dr. White the man could not put his foot to the floor on account of the pain and discomfort.

At this time the man presented, on his right foot, beginning at the base of the fifth metatarsal bone, extending backwards two inches and upwards on to the dorsum of the foot, an area smooth, pigmented, dry, glistening and pruritic, the upper edges of which seemed to be composed of old papules atrophied and sunken to the level of the skin, while the plantar periphery was broad, horny and slightly eroded. The lesion was everywhere anæsthetic to the touch, but seemed to produce a crawling sensation subjectively.

The feet were markedly hyperidropic except over this area where the skin was abnormally dry.

Treatment was given for three weeks and consisted of a mild, drying wash, tannoform powder and pastes containing ichthyol and later tar. The lesion improved and before going to his home in Virginia the man was able to walk, but the area remained practically the same as far as appearance went.

Histology. A piece of the upper border was excised, hardened in alcohol, imbedded and cut in paraffin and stained in various ways.

Epidermis. The horny layer varies in thickness and compactness in various parts of the sections. The granular layer seems to differ also—where the horny layer is thick and compact, the granular layer shows only a single line of small, flattened cells; where the upper layer is open and mesh-like, the lower layer contains two rows of swollen and vesicular cells. The rete presents a very regular wall of columnar cells above which the spinous cells soon tend to assume an oval shape with their long axes lying horizontally. As a rule the nuclei of these cells are surrounded by a clear space out of which an occasional cell has fallen.

Corium. The papillary layer is quite wanting. The connective tissue fibrillæ below the epidermis appear rarified and contain scattered and grouped cells and support occasional capillaries which are dilated and show greatly swollen endothelial cells. Below this level the corium shows alternating strata of swollen and coarse collagenous bundles and longitudinal masses of extravasated cells which, for the most part, are lymphocytes with an occasional plasma cell. Between these layers of collagen appear lymph channels which separate the bundles widely from one another.

Deep down in the sections appear clusters of sweat glands which show the presence of œdema in their separation from their supporting fibrous tissue, in the very vesicular character of their nuclei and in their diminished power of color absorption. Surrounding these glands there are solid masses of lymphocytes varying in their abundance. When, as occasionally happens, the fibrous trabeculæ can be seen, their nuclei appear almost spherical and quite watery in consistency.

Elastin is normally abundant throughout the sections except in those areas where the lymphocytes show foci of invasion. There the elastic tissue is totally wanting, both in the mid-corium and throughout the sweat gland regions. Scrapings from the corneous plantar border were examined in hydrate of potash but revealed no abnormal appearances.

Dr. Bowen said that the color of the lesion, its anæsthesia and the Philippine history might, perhaps, suggest the possibility of anæsthetic leprosy.

Dr. McCollom had thought of leprosy also, but the fact that the man had grown better during the last few weeks was rather against such a diagnosis.

Dr. Burns had seen the case at the Marine Hospital where the

lesion had appeared to him like one of chronic eczema, but the government surgeons had not committed themselves to any diagnosis at that time.

Dr. Harding felt that the marked hyperidrosis might be at the bottom of the trouble and was inclined to call the case chronic eczema.

Dr. James C. White said that the appearance of the lesion did not suggest any tropical disease with which he was acquainted. He thought there was more a suggestion of tuberculosis than of leprosy, but was far more inclined to regard the case as one of chronic eczema modified by neglect and the debilitating effects of the Philippine service.

Charles J. White, Secretary.

REVIEW
of
DERMATOLOGY AND SYPHILIS

Under the Charge of John T. Bowen, M.D.

INFLAMMATIONS.

By F. S. Burns, M.D., Boston.

Bullous Dermatitis. (*Dermatite bulleuse congénitale à kystes epidermique.*) Balzer et Fouquet. (*Ann. de Derm. et Syph.* 1904, p. 250.)

The subject of this unusual eruption was an infant of twenty-one months, in whom the cutaneous affection began during the first weeks of life. Since the first outbreak, crops of bullæ have appeared at fortnightly intervals. There were two elementary lesions; bullæ and epidermic cysts. The bullæ started on the elbows and then became generalized. The face was the site of a few small bullæ. Itching frequently preceded the outbreak.

The bullæ were tense, varied in size from a pea to a small nut, arose from a healthy skin and were not surrounded by an areola. In the clear serous or slightly hæmorrhagic contents were found mono- and polynuclear leucocytes, but no cosinophiles. A few bullæ were also seen on the buccal mucous membrane. Resolution occurred without cicatrices.

Associated with the bullæ in certain places were small, hard, whitish nodules, the size of a pin head, resembling milium. They occurred with noticeable frequency on the hands and feet at the borders of the phalangeal joints. Cysts were absent on the palms, and were not pruritic.

There had been one other child in the family that had a similar bullous eruption in early infancy, and which died at four months. Both parents' history was negative.

Erythema Exfoliativa. (*Exfoliating erythema due to absorption of protoiodide of mercury: investigation for mercury in the scales.*) Balzer, Dugros et Fouquet. (*Ann. de Derm. et Syph.*, 1904, p. 165.)

The case presented occurred in a man fifty-three years old, who in Nov. 1903, acquired an initial lesion followed in two weeks by a roseola. At the hospital where he was treated he was given two or three pills a day of .03 gram each of protoiodide of mercury. The pills were well tolerated and taken regularly until Dec. first, when redness and swelling of the face appeared, followed by a generalized scarlatiniform erythema. On Dec. seventh the patient went to the St. Louis hospital where a diagnosis of dermatitis medicamentosa was made. There were no other symptoms of absorption of mercury. The exanthem gradually resolved with desquamation. After the erythema subsided the specific roseola again became visible.

It was noted that the drug eruption did not appear until some time after mercury was prescribed. The dose capable of producing an exanthem need not be large.

In the examination of the scales for mercury the possibility of extraneous contamination was eliminated. The drug was successfully recovered from the desquamated scales.

As to the possible cause of such a drug eruption the authors advance two hypotheses:

First: That the skin manifestation may be of the same nature as dermatitis exfoliativa produced without mercury. The eruptions resemble each other clinically and may be due to an intestinal intoxication favored in the former case by irritation of the drug.

Second: That an interference with absorption and elimination of mercury in some way directs it toward the skin where it becomes concentrated and causes a dermatosis.

The present state of knowledge of the subject is very uncertain.

Gangrene of the Nipple. (*Gangrene du mamelon d'origine probablement pheniquée.*) Du Castel et Nocton. (*Ann. de Derm. et Syph.* 1904, p. 73.)

The patient was confined the sixth day of last October. Fifteen days later she developed an abscess of the right breast. Under the advice of her physician she used carbolic acid applications which were continued for eight days and were very painful. At the end of this time the nipple and its areola became blackish, then formed an eschar. Over the breast and neighboring thorax there existed an eczematous dermatitis.

The urine was not black at any time.

Complete disappearance of the nipple and areola occurred, leaving in their place a crateriform depression. From this depression there was an incessant flow of milk.

From the destruction of the nipple and areola it seems a plausible conclusion to the writers that the condition was consecutive to the carbolic acid applications.

Herpes Progenitalis. (*Zur pathologischen anatomie des herpes progenitalis.*) W. Kopytowski. (*Archiv. für Derm. und Syph.* 1904, p. 55.)

Twenty-four cases were studied clinically and pathologically. They occurred entirely in women who developed herpes incidentally to hospital sojourn.

The disease occurred with greatest frequency in Spring and Autumn. The commonest sites of the affection were on the inner aspect of the thigh and the neighborhood of the genitalia. Nearly all cases presented typical vesicles.

Biopsies were performed in various stages of the disease; usually when the vesicles were well developed. The author found considerable analogy in the histological picture of herpes progenitalis and zoster, and hints at the probability of a similar infectious cause.

The chief pathological changes occurred in the epidermis and papillæ, consisting in circumscribed foci of inflammation of various size with the blood vessels of the papillæ as a starting point. The inflammation causes cellular degeneration and coagulation necrosis with a simultaneous infiltration of polynuclear leucocytes, augmented especially by the degree of cell necrosis. The change in the epithelium consisted in degeneration of the cellular constituents and contents of the vesicles. The latter, cell necrosis, Kopytowski considers characteristic of herpes progenitalis and zoster.

From a pathological standpoint the author believes that both diseases are identical.

Pemphigus Vegetant of Neumann. (*Contribution a l'etude du pemphigus vegetant de Neumann.*) Stanziale. (*Ann. de Derm. et Syph.* 1904, p. 15.)

In this article there is a brief review of previous bacteriological observations made on this disease, a clinical report of a well marked case, and a pathological and bacteriological study of the several types of lesions present.

The patient, a strong, robust woman, in Nov. 1902, began to have a painful sensation of burning during deglutition accompanied by copious salivation. These symptoms persisted until the end of April when a sensation of heat and burning began to be felt in the submammary regions. By the following month the disease had sufficiently manifested itself to allow the diagnosis of pemphigus vegetans to be made.

The buccal mucous membrane became generally affected; the lips

were covered at different points with small blackish crusts, and the inner surface of the cheeks by a whitish exudate. The tongue was swollen and the voice hoarse.

The axillæ presented several vegetating plaques varying in size from 2-6 centimeters in diameter, of a rose brown color, rather flat and soft, and secreting a sero-purulent liquid of disagreeable odor. There was usually a red excoriated periphery with a macerated epidermic edge. In the neighborhood of the plaques, on the thoracic wall and inner surface of the arms, were isolated vesicles and bullæ varying in size from a pin head to a bean, the contents in some, purulent; whitish and turbid in others. On the breasts were scattered vegetating and versico-bullous lesions. The umbilicus was the site of a vegetating plaque.

In June some of the lesions had undergone involution, leaving an area of hyperpigmentation to mark their site. By the first of July the general condition became grave. There had been repeated chills; the patient was somnolent, had hæmorrhagic diarrhœa, and deglutition became very painful. The patient died the last of July.

Stanziale made a careful bacteriological study of the bullæ, vegetating plaques and the blood. A small diplobacillus was isolated from the fresh bullæ, and blood drawn from the median basilic vein; and a pseudo-diphtheritic bacillus from the vegetating lesions, and blood taken from the skin at their periphery. Both organisms grew well on rabbit's blood agar.

A positive agglutination reaction was obtained with the diplo-bacillus, but inoculation experiments were negative.

Stanziale considers his diplo-bacillus probably identical with the small diplo-coccus of Waelsch; his more accurate identification of the bacterium being due to the greater facility with which it grew on media made with blood. The general results agreed in great measure with those of Waelsch.

While the writer does not desire to draw definite conclusions from an isolated case, he believes that pemphigus vegetans may ultimately be found to be due to a mixed infection of a diplo-bacillus associated with a pseudo-diphtheritic bacillus; the diplo-bacillus probably being a causative factor in the production of the bullæ, and the pseudo-diphtheritic bacillus playing a role in the evolution of the bullæ and production of the vegetating lesions.

Pilocarpine dermatitis. (*Sur une nouvelle forme de dermatose papulo-exudative provoquée par la pilocarpine.*) HALLOPEAU ET VIELLIARD. (*Ann. de Derm. et Syph.* 1904, p. 233.)

The case was that of a male aged fifty-two, affected with episcleritis and glaucoma. The patient was treated with .005-.01 gram pilocarpine per diem. In two weeks the eyes improved and the pilocarpine was reduced to .005 gram. p. d., but ten days later there was an exacerba-

tion of eye symptoms, when subcutaneous injections of pilocarpine .01 gram p. d. were resumed for eight days.

Shortly after the last injection the dermatosis appeared; at first on the ears, cheeks and lids, as a polymorphous eruption of papules, pustules and impetiginous crusting areas. Some of the lesions were umbilicated suggesting the appearance of variola. On the anterior surfaces of the arms were numerous confluent vesicles and pustules. On the face the lesions were most numerous about the nose, at the margins of the ears, the cheeks and the canthi of the lids; they were papulo-pustular, varied in size from a millet seed to a small lentil, and were usually acuminate, some surmounted by a hair, the center the site of a punctiform depression.

At the edges of the thenar and hypothenar eminences were small pruriginous lesions situated on a reddish base resembling dysidrosis. There was an agglomeration of centrally depressed papules on the backs of the arms, anterior aspects of both legs, groins, and dorsal surfaces of the feet. The lower portion of the abdomen was also affected.

The patient was troubled a good deal with vertigo; the tongue was reddish brown and dry; vesicular lesions were seen on the hard palate.

All symptoms gradually increased for a month, at the end of which the patient died in a condition of stupor.

At the autopsy both lungs were found congested and the pleura adherent. There was a little pus in the calyces of the kidneys and small cysts with fluid contents in the cortical portion. The liver was pale and hypertrophied.

This case seems to be unique in dermatological literature. The writers make the following conclusions: That pilocarpine can give rise to an eruption of umbilicated papules which are localized in the sebaceous glands; the face and limbs being sites of predilection. The eruption differs in its clinical characteristics from all dermatoses described up to the present time. It is accompanied by a grave cephalic and functional cardiac disturbance. The course is afebrile.

Zoster, hæmorrhagic. (*Sur un cas de zona hemorrhagique.*) H. Hallopeau et Vielliard. (*Ann. de Derm. et Syph.* 1904, p. 76.)

This case was remarkable for the confluence of its numerous lesions.

Hæmorrhagic exudation does not occur at the outset of the vesicular stage but appears only after some days, and is situated centrally in the vesicles. The hæmorrhagic vesicles are black and surrounded by young vesicles with purely serous contents.

The authors consider the hæmorrhages to be passive and due to prolonged capillary distension from the exudative process.

LEPROSY.

By Isidore Dyer, M.D., New Orleans.

A Romanist View of the Fish-Eating-Leprosy Theory.

The *Messenger* for March, 1904, a periodical of more than ordinary literary and polemic merit, editorially handles the theory of Hutchinson and its application to the Catholic church. The resurrection of the theory is suggested as possibly stimulated by the Lenten and *"carne vale"* season. The writer of the editorial is evidently a physician and was present during the discussion of the paper of Hutchinson read by Abraham at the Berlin Conference. There the theory was not taken seriously. There were arrayed against the notion almost every one present at the conference, made up of leprologists whose life in leprous centers permitted authoritative opinions.

The editorial chiefly takes issue with the statistics of Hutchinson adduced from countries under Catholic rules. In rebuttal the countries of South America and those of vegetarianism are instanced. The discussion published in the London *Lancet* is quoted and the negative result so far as the theory was concerned. In discussing Hutchinson's plea that the Protestant countries were free of leprosy because of the relegation of abstinences, the writer suggests that Continental countries, Catholic in practice, were also exempt from the disease except in sporadic groups of cases. The article summarizes the idea that in trying to force a theory which has impressed him for nearly a quarter of a century the protagonist, Dr. Hutchinson, has appealed to the current of emotion in religious thought to open up another way.

Catabolism in Leprosy.

In a paper on Syphilis and Leprosy as Subcatabolic Diseases, Dr. Wakefield, in the *Medical Record* of January 2, presents a very interesting field of study to the leprologists and brings home many ideas of the disease which here and there have appealed to the individual worker, but which probably have never been so tangibly put as they are here.

To the author, leprosy is among the highest types of extreme catabolic stasis. The bacillus of leprosy is saprophytic and can act only in degenerated tissue, due to general or local subcatabolism. The conditions which act as determinative of the disease are held to be cold, fatigue, strain, worry, irritation, suboxidation, subelimination, gastro-intestinal hyperacidity, vitiative influences of association, excesses, in potative habits and in venery, etc. By these the intensity of the disease is governed and not by the intrinsic character of the microbe, except as to the general property of excretion of a toxin of great irritative power, and to the number of bacilli involved, which governs the vicious cycle.

The degrees of the manifestations of the disease are accordingly determined by the different causes of subcatabolism and wherever the primary degeneration is located, there the bacilli become established and the tubercular or anæsthetic varieties are predestined as typical vicious cycles. Climate must of necessity present some claim to importance in the role of determining types: "No true student of tropical maladies," says the author, "will fail to recognize as a factor in the etiology of leprosy, and in particular of the sluggish anæsthetic form, that general disposition of such climates to relaxation, lassitude, lethargy, torpor, and with it extreme sedentation."

The site of the ingress of the bacillus has no determination of the type. As the nerve structures are invaded, the circulatory apparatus involved, it makes no difference what the initial form, tubercle or not, the entire body sinks into that subcatabolic depravity which is known as the anæsthetic form. ["Trophoneurotic" of Leloir-Dyer.]

Insusceptibility on the one hand brings immunity and depends on the physical tone or race habit of the individual; while, again, among the races most addicted to vices and where narcotic habits and excessive venery play their parts, there is more prevalence of leprosy.

More than anything else in the paper is the value of the deduction from the argument that treatment depends far more on a restoration of the physiological balance than upon the microörganism of the disease. In this the experience of the reviewer bears out the argument—patients always respond to any remedial measures directed at establishing resistance and at increasing the metabolic balance. Says the author in conclusion, anent this point: "The rational basis of treatment, however, must be the accomplishment of the one end, namely, the restoration of normal catabolism and the combustion and elimination of the accumulated and decaying refuse of past subcatabolism, and not any attempt at independent parasitic destruction."

Leprosy in Hawaii.

Wayson in the *Medical Record* of December 19, gives a running commentary on leprosy in the Hawaiian Islands, presenting also some excellent photograph cuts of assorted cases, showing types of the disease, and interesting as indicating to what stage the disease may arrive before it is recognized.

Considerable agitation has of late been stirred up over leprosy in the colonies of the United States, and notwithstanding the apparent reduction in the number of cases on the Island of Molokai, it is generally believed that through the habit of concealing these patients, the disease is really spreading in these Islands. There have been many attacks made upon the methods employed at Molokai, and the criticism seems deserved from all accounts, particularly so far as treatment is concerned.

Study of Leprosy.

The Board of Health of Hawaii some time ago formulated a plan for the systematic study of leprosy at the settlement of Molokai. The plan included a request for an appropriation from Congress for suitable provision for a bacteriological laboratory at the leper settlement, and for residences for investigators. The Territory of Hawaii would provide maintenance and assistance, and an invitation would be sent to the leading institutions and societies in the world which provide for original research into such subjects, to send capable investigators. Surgeon-General Wyman, in pursuance of the same object, has invited Dr. Charles B. Cooper of the Board of Health of Hawaii, Dr. J. F. Smith, Secretary of the Superior Board of Health of San Juan, P. R., and Dr. J. C. Nolte of the State Board of Health of Louisiana, to become members of a committee to undertake an exhaustive investigation and study of leprosy. This committee is to suggest lines of investigation to competent observers willing to undertake the work, and also to collate the results of experiments and observations made in connection with its work, and to report at suitable times on the progress of the work." *Medical Record,* March 5, 1904.

Mosquitoes and Fish as Factors in the Spread of Leprosy.

The *Sei-I-Kwai,* of January 31, 1904, carries a discursive article of Ashmead's, reviewing Hutchinson's theory and venturing opinions as to the *reductio ad absurdum* of the same; while the writer believes the relation of fish as a diet is of material importance in the progress of the disease. He takes up the same line of argument in a paper in the *St. Louis Medical and Surgical Journal* for March, in discussing the faulty care of Hawaiian lepers. He suggests a method of experimentation which Hutchinson might adopt, viz: Cultivate the lepra bacillus in fish, the one suggested being the Japanese goldfish which is susceptible to parasites. "Jonathan Hutchinson and myself are the principal combatants for the theory of an insidious connection between fish and the propagation of leprosy," says Ashmead, and further, "it is not alimentation of fish which produces leprosy, but that fish and mosquitoes (or other insects) serve together as intermediary hosts for the transference of bacillary spores; that mosquitoes which have sucked the blood or discharges of lepers are afterward eaten by fish, and that this fish when eaten uncooked will propagate the disease to man."

NOTES ON LEPROSY.

The Louisiana Leper Law has been enforced a number of times in recent years and each time the law has operated the person suspected of leprosy has been duly committed and sent to the Leper Home in Iberville Parish. An exceptional occurrence in this matter of legal control of the disease was brought to public attention during the month of March.

On the affidavit of a representative of the New Orleans Board of Health, John Noveh, aged 57, Mrs. Odile Chandler, aged 47, Joe Chandler, aged 22, Annie Chandler, aged 19, and her infant, aged 4 months were summoned and made to appear before the District Court and on the evidence of the Board of Health were on the point of being committed, when Mr. Thos. J. Maloney, an attorney, prayed a stay of proceedings and asked the Court to appoint experts to examine the cases. The infant was not held as a leper, but being a suckling was, in the law, of the body of the mother.

The testimony brought out at the second trial declared the danger to the infant and the Court allowed the child to be taken by relatives. All the others except Joe Chandler were held as lepers, the two experts (Drs. Mandeville and Dyer) finding no evidence of the disease and the Secretary of the Board of Health declaring him a leper on certain physical signs in which the others could not concur. A subsequent bacteriological examination was made of the nasal secretions and of specimens selected from parts of the body claimed as presenting lesions.

The interesting points are those relative to the nursing child, and the right of habeas corpus in a suspected leper. The precedent is a good one and must weigh where a law exists which classes all lepers alike, making no distinction between the simple or advanced types so far as their segregation is affected.

Sporadic Tubercular Leprosy. It is interesting to read Dr. Heidingsfeld's report of a sporadic case of leprosy, seen by him in Cincinnati, and especially for the stress he lays upon the occurrence of the case. No direct contagion can be usually traced in these cases and the fact that Mr. H. (of Omega, Ark.) lived in a state where leprosy occurred, namely at Hot Springs, travelled to New Orleans, argues against the conclusions drawn. No history of the daily life of the patient is given, nor the possibility of a casual infection. The particular case itself, evidently of tubercular type from the photograph, may have infected people in Cincinnati, Atlantic City, Pine Bluff, &c., and they in turn could be instanced as "sporadic" cases, just because of the impossible relation of the origin of the case.—*Lancet-Clinic.*

Leprosy in New York. Dillingham reported a case of nerve leprosy to the New York Post-graduate Society in March. The patient was a native of the United States.

The International Dermatological Congress to be held at Berlin in the middle of September proposes reviewing the status of leprosy in the world. A series of propositions have been formulated by the Section directing the question, all aimed at the control of the disease. Statistics of asylums and colonies; measures against the disease; government regula-

tions; places of isolation or segregation; occupation of lepers in institutions; methods of transporting lepers; the condition of lepers in the hospital and clinic. (Parenthetically Dr. Dyer would be glad to have the report of any case seen from 1880 to 1904 inclusive, with history, &c.; also the personal views of any observer of leprosy as to contagion, government direction and jurisdiction, quarantine, and the types which should be segregated, &c. The report for the United States and North America is to be made by Dr. Dyer, hence the request. Write him at No. 124 Baronne Street, New Orleans, La., before June 15.)

New Zealand and the Cook Islands. J. M. Mason, in *Lepra,* (Feb. 1904, Vol. IV., fasc. 2) presents a most interesting review of leprosy in these islands, where there are now but five known cases, in New Zealand, four of them natives and one a Chinaman. The natives all present nodules; the case of the Chinaman is of exact nerve type. None of these were of long standing. Ten cases are related in the Cook Islands. The origin is traced to a probable infection from the Hawaiian Islands. The only treatment practiced by the natives was that of wrapping the patient in the leaves of a native shrub and roasting him over a slow fire—said to be effective where the patient survived the treatment.

Tahiti Leprosy. Senn has written a series of papers on Tahiti (Society Islands) and it is interesting to note (*Jn'l. A. M. A.,* Apr. 9, 1904) his commentary on the occurrence of leprosy:

"Leprosy is not as prevalent as in the Hawaiian Islands, but isolated cases are found in nearly all of the Islands belonging to this group, being more prevalent in some than in others. Segregation has never been attempted. The lepers mix freely with the members of their family and neighbors and are not shunned. I was informed that many of the lepers, much disfigured by the disease, seek an island where many of these unfortunates have founded a colony for the purpose of escaping from public gaze."

Leprosy in New South Wales. Under date of December 31, 1903, J. Ashburton Thompson makes a report on leprosy conditions in New South Wales for the year 1901. On January 1, 1901 there were 11 persons in the lazaret; 9 were added during the year. Five patients died during the year, leaving 15 on December 31, 1901. Of these, 9 were whites, 5 natives of New South Wales of European descent, 1 a native of Germany, 2 were natives of England, and 1 was a native of the United States. Of the colored lepers, 1 was Javanese, 4 were natives of China, and one was a native of Aoba Island (New Hebrides).

Since 1883, when notification of leprosy was first compulsory, a total of 78 cases have been segregated. The nationality of these was as follows: Natives of New South Wales, 21; Queensland, 1; England, 2; Ireland, 2; New Zealand, 1; Fiji, 1; Germany, 2; Belgium, 1; United States, 1; all of these were whites of European descent. The others were dis-

tributed among the following nationalities: China, 37; India, 2; West Indies, 1; Java, 1; Tanna (New Hebrides), 1; New Caledonia, 1; South Sea Islands, 1.

It is interesting to note that two of these patients were released, 21 Chinamen were returned to their own country and in the 18 years related, 38 died.

The average cost for each inmate of the lazaret, under government control, was about $695.00 per annum.

BOOK REVIEW.

Roentgen Ray Diagnosis and Therapy. By C. Beck, M.D. (D. Appleton & Co., New York and London. Pp. 469. Illustrated.)

This is one of the latest treatises on the use of the Röntgen rays. It is an eminently practical book. Unlike many of his predecessors the author plunges at once into his subject without a long disquisition on the physics of light, and the sources of electricity. Nor does he devote many pages to a description of many apparatuses. His chapter on "The Apparatus" occupies only 23 pages. He favors the coil as the means of producing the Röntgen rays, and says that one with a twelve to fifteen inch spark is ample for all purposes. The subjects of technique, fluoroscopy, and skiagraphy are discussed in a short and practical way. The greater portion of the book is given to a description of the methods of examination for diagnostic purposes; 280 pages. Then follow chapters on the medico-legal aspects of Röntgen rays; therapy; Becquerel rays and radium; and photo-therapy.

As the author is a surgeon, the larger part of the book is devoted to surgical matters and the book will be of most service to surgeons. Dermatological matters are treated of mostly at second hand, quotations from the writings of others. To show the effect of the rays in the treatment of lupus erythematosus a picture is given that seems rather to be one of lupus vulgaris.

The author very properly regards Röntgen rays as appropriate to the treatment of inoperable cancer, advising surgical measures in all operable cases. He gives two pictures showing a case of epithelioma and the cure obtained by X-rays. They show very well how the rays will heal the ulcer and leave the thickened edge. The reviewer has seen many such *cures,* which really are not cures, and can be produced by much simpler methods of treatment.

The chapter on radium is a perfunctory one. The author's estimate of the Finsen treatment is: "All in all this mode of treatment can not, ingenious as it is, in its present state, compete with the Röntgen method." This seems to the writer the only conclusion that can be arrived at.

The full bibliography, and the 332 illustrations that illustrate are valuable features of the book. G. T. J.

PLATE XXXI.—To Illustrate Dr. H. W. Stelwagon's Articles. (Fig. 1) Eczematoid Eruption of the Lip. (Fig. 2) A Second Case of Creeping Eruption.

Fig. 1.

Fig. 2.

THE JOURNAL OF
CUTANEOUS DISEASES
INCLUDING SYPHILIS

VOL. XXII. AUGUST, 1904. No. 8.

A PECULIAR ECZEMATOID ERUPTION OF THE LIP REGION.

By HENRY W. STELWAGON, M.D., Philadelphia.

Read before the twenty-eighth annual meeting of the American Dermatological Association, Niagara Falls, June 2 and 3, 1904.

IN recent years a limited number of cases of eruption about the region of the lips have come under my observation that have presented some peculiar characters. It has had many of the aspects of eczema, but with such unusual features as to give it a distinctive stamp. The eruption may, and usually does, begin on the vermilion of the lips, and shows at first as a slight superficial eczematous irritation with scanty exfoliation, and in some cases, or at times in the same case, variable crusting. There never seems, however, on these or the other external parts of which I shall speak, to be any evident liquid exudation. At this stage of the case a mild eczema of the lips is suggested, and the affection can remain more or less limited to this region for a long time, and scarcely overstep the vermilion of the lips. During this time it may vary considerably in degree, not only as regards redness, but also as to the scaliness or crusting; the amount of the latter symptoms is never so well marked as in a frank eczema of these parts. There is, moreover, rarely any distinctive thickening or infiltration, certainly never beyond a slight or moderate degree. Some burning and heat are sometimes complained of, but seldom any troublesome itching; in fact, pruritus is usually wanting. Slight fissuring is not uncommon, especially at the angles of the mouth, and these may be painful. The condition may retrogress and fluctuate or even relative or complete recovery take place, to be followed, as a rule, sooner or later by relapse. More commonly this retrogression is not complete, and the affection after variable quiescence presents strongly again. In this way exacerbation and improvement may be noted from time to time at irregular intervals.

As remarked it may remain limited to this region a long time, but generally after some weeks or months the disease extends somewhat on to the skin proper, either more or less evenly or with a slight or pronounced segmental border. Usually after some duration or sometimes coincidentally with the lip involvement the malady spreads inward to the contiguous mucous membrane. In this latter region it appears at first as an ill-defined pinkish discoloration, which later looks somewhat thickened, of a deeper red, and with or without a superficially abraded or coated surface, sometimes slightly roughened. It rarely extends more than one-fourth to one-third way down the mucous lining of the lower lip, and to a much less extent on that of the upper lip. In fact the upper lip in its vermilion, inner mucous lining and cutaneous parts is rarely affected to any marked degree, always much less than the lower lip. In two or three instances the tongue on its upper surface to the extent of a-half to one-and-a-half inches became likewise invaded. The condition on these mucous parts varies considerably in different cases and even in the same case, exhibiting resemblance to a slight opaline patch, to a patch of lichen planus and even to a syphilitic mucous patch. It never has, however, the distinct white and thickened appearances which commonly characterize leukoplakia. As a rule these mucous parts are only slightly sensitive or tender, except when the patient takes very hot drinks or acid fruits.

Coincidently with the progress of the disease here or independently of its mucous extension, the neighboring cutaneous surface becomes invaded. In the immediate proximity of the mouth, contiguous to the spreading lip disease, or slightly beyond this, one or more reddish small pea-sized flattened or rounded lesions appear, showing as a rule but slight or moderate elevation, and but insignificant infiltration. They are persistent, exhibiting at first but trifling, if any, scaliness; later showing epidermal scaling, and in some instances what almost appeared as actual crusting, but there is never any liquid exudation. They are almost of the same color as the eruption on the lips, possibly a darker red, but always, as a rule, with a distinct yellowish cast. They are more than simple erythematous spots, although they can scarcely be said to be pronounced tubercles or nodules. Such lesions may remain thus or later grow larger as to area by peripheral extension, and exhibit a slight or marked tendency to central clearing; in a few instances spreading peripherally and clearing up centrally, quite similarly to a ringworm patch, except that the spreading border is wider and more band-like; its peripheral spread is, however, much slower and never so extensive as observed in ringworm. It is not un-

common to find several lesions grouped somewhat closely together, and sometimes with an ill-defined or clearly recognizable segmental or circinate configuration. There is never the least disposition to atrophy or ulceration; in fact, no permanent textural change is ever observed. The redness largely disappears upon pressure, bringing out more distinctly the yellowish aspect. When several lesions are present, one or two of them spreading peripherally, there is a resemblance to several diseases, more particularly, probably, to eczema seborrhoicum, but also, especially upon cursory examination, to a superficial tubercular syphiloderm, to an ill-defined lupus vulgaris, and to a possible lupus erythematosus. In a few instances I found slightly similar spots, in scant number, and as a rule, without spreading tendency, upon the scalp; with, however, no hair loss, no atrophy, and possessing here the usual features of a patchy eczema seborrhoicum. The face lesions or patches are rarely seen higher up than the level of the alæ nasi, their most common region being just beyond these parts and near the angles of the mouth and on the chin. The old spots may gradually disappear while others are presenting, so that a case seen now and six months hence might show a complete shifting of the exact seat of the cutaneous eruption, but always about the same parts. After a duration of months, however, and when well established, the process seems to be more persistent as regards the individual lesions, although even then capriciousness as to variation, extent and disappearance is observed. Notwithstanding that the disease is striking in appearance and disfiguring it is evidently of a benign character, and as previously stated, it never shows the slightest destructive action; and old spots when gone leave absolutely no trace.

The interest of these cases naturally centers itself in the question of diagnosis. Is it an eczema of an unusual type, an eczema seborrhoicum, a lupus erythematosus or a disease sui generis. It is true that when the case is well marked, with the often circinate or segmental grouping tendency of the cutaneous eruption and the peculiar involvement of the mucous membrane, one can not avoid at first glance a suspicion of syphilis, but the superficial character of the eruption, the absence of all destructive nature, its evident benign character, and its course and behavior, and especially the sometimes capriciousness of the skin lesions, negative this conclusion. Moreover in two instances, especially suggestive in this direction, I was led to put the patients experimentally upon antisyphilitic treatment, with, if any effect, an aggravation rather than improvement. It is certainly not a frank eczema, although in one instance the patient, in whom the

lips alone were then involved, spent some time in Vienna under Kaposi's care, who, the patient had informed me, regarded it, as it really seemed then, as an eczema of the vermilion of the lips. His treatment was successful, and the patient remained free for several or more months after his return. Later it again developed, and since then has gradually invaded cutaneous and mucous surfaces, with, as in other cases, periods of exacerbation and partial or complete quiescence. The invasion of the mucous surfaces is, to say the least, exceeding uncommon in ordinary eczema, although one can not deny that it is sometimes observed, and the possibility of these cases being examples of such can not be wholly set aside. The features, course, behavior, and limited character of the disease, as well as other symptoms described, would make, however, the acceptance of such diagnosis exceedingly questionable. Lichen planus was suggested to me by the appearance of the eruption on the mucous membrane, but the skin lesions and lip eruption were totally lacking in any of the characters of this disease, and moreover other parts of the body other than the regions just described were entirely free from any manifestations.

Lupus erythematosus can not be dismissed so readily. In one of these cases on a visit toward the west—the one in fact that had been previously considered by Kaposi as an eczema—the patient, at my suggestion, consulted Dr. Hyde and Dr. Montgomery; the disease at this time had involved mucous membrane and cutaneous surface (the condition of the latter is shown in the accompanying photograph). Dr. Hyde, and I believe Dr. Montgomery also, the patient informed me, were inclined to believe it an example of lupus erythematosus, although not expressing themselves positively. Another somewhat similar case that has been under my observation was seen at one time by Dr. Duhring, who also was inclined to consider the disease at first glance as lupus erythematosus, but who, at a subsequent examination discarded this view. It seems to me that the lack of all tendency to atrophic changes, the total absence of all the ordinary classic objective appearances of the disease, the often nodule or tubercle-like character of the cutaneous lesions, its more or less uniform involvement of the vermilion of the lips and usually primarily, its absence from the ordinary regions of lupus erythematosus, and its behavior and course, make this view, in my judgment at least, certainly somewhat improbable. The same features or characteristics just named would also give the consideration of the possibility of a lupus vulgaris even less support. If it were not for the involvement of the mucous membrane of the lips and sometimes of the tongue also, I should not hesi-

tate to place it as a probable eczema seborrhoicum of unusual type and obstinacy. The yellowish tinge, the disposition to segmental configuration or grouping and the occasional conjoint presence of seborrhoic lesions upon the scalp, and the sometimes capricious behavior would favor this. I am not sure, however, that such a diagnosis could be accepted, admitting as we must that the mucous membrane condition and the skin eruption are the same disease, unless we change our views as to the nature of the so-called seborrhoic process. Microscopical examination of the scrapings made in two instances did not throw any light on the character of the eruption. Unfortunately I have not been able to obtain a section of tissue for examination.

The disease on the skin is rebellious, and that on the mucous membrane is more than this, as it seems almost irremediable. The treatment of the cutaneous lesions that seems to be more generally useful is similar to that of eczema seborrhoicum; sulphur, twenty to sixty grains or more to the ounce of Lassar's paste, and occasional paintings of an alcoholic solution of resorcin, ten to fifty per cent. strength, being as a rule the most efficacious. On the vermilion of the lips, occasional mild superficial cauterization with liquor potassæ, and the subsequent application of a soothing ointment such as the zinc oxide or unguentum diachyli will have a curative influence. As to constitutional management beyond the maintenance of a free action of the bowels, and caring for the digestive functions little else seems called for or of any distinct service. After relief is afforded attention to the digestive tract will, I believe, do much toward warding off relapses, which are quite the rule.

DISCUSSION.

Dr. Zeisler said that Dr. Stelwagon, in his paper, has described a class of cases which many of us have met with at one time or another. He was exceedingly interested in his report, because he had before his mind two similar cases which tally exactly with his description, and a third case in which the eruption involved the scrotum. He could sympathize with Dr. Stelwagon in regard to the difficulty of diagnosis, because he had never been able to satisfy himself thoroughly as to the true nature of the eruption. The suspicion of syphilis has again and again entered his mind, and he has never been able entirely to eradicate the idea that it was a mixed affair—symbiosis of seborrhoic eczema and syphilis, such as Unna some years ago pointed out.

Dr. H. G. Klotz remarked that what he had to say in regard to this paper had practically already been said by the President. He was much interested in Dr. Stelwagon's paper because it reminded him of a case that had puzzled him a good deal. The patient was a middle-aged woman

with whom he had long been acquainted. She had an eruption similar to that described by the reader of the paper; the lesions were not as contiguous, but the patches were more rounded and circinate, especially at the angles of the mouth. The appearance of the eruption, together with the fissures of the mouth, was so suggestive of syphilis that he was not surprised, subsequently, to learn from her family physician that he had tried the effect of mixed treatment. He was convinced that she had not had syphilis, and treated the case as one of seborrhoic eczema. The fissures he cauterized with nitrate of silver, which he thought was always necessary, no matter what their origin might be. The effect of the treatment in this case seemed to confirm the opinion that it was not syphilitic. The lesions disappeared and there had been no relapse. He made the diagnosis of some irregular type of seborrhoic eczema.

Dr. Fordyce said that while not asserting that the cases described by Dr. Stelwagon were syphilitic, they recalled a case of a very superficial squamous syphilide of the lip in his experience which was very similar to those reported by Dr. Stelwagon. He had the opportunity of following this case very carefully. The patient now had a sharply marginated patch on the lip.

Dr. James Nevins Hyde said that one of the patients whose cases were reported by Dr. Stelwagon had been seen by Dr. Frank H. Montgomery and himself. The case was one of unusual perplexity. When the patient was subsequently seen by Kaposi, he made the same diagnosis as that given by Dr. Stelwagon. When Dr. Hyde saw the patient, some years ago, he thought there was no question that the affection was a non-syphilitic one. All recognized the fact that ten or fifteen, or even twenty years after the onset of syphilis, there might be cutaneous manifestations of the disease, but in his experience the very late manifestations of syphilis were usually of gummatous type, could be easily recognized, and yielded so readily to appropriate remedies that it was generally easy to eliminate specific disease, especially when the lesions were limited to the skin or some of the adjacent mucous membranes.

He had long held that the generally accepted clinical features of lupus erythematosus did not include all the varieties of that disease. He believed, and he had put himself on record to the effect, that many odd-looking, atrophic patches in the scalp, which were unaccompanied by facial lesions, were examples of lupus erythematosus; and not infrequently he had seen a group of cases which suggested this condition, where the symptoms were both similar and different. In one case there were lesions of the lips and adjacent mucous membranes; these represented a pronounced type of lupus erythematosus, and there were, coincidently, odd-looking lesions of the prepuce and about the tips of the fingers. We have had one or two cases also in which there were circular scaling patches about the mouth.

The more we observed lupus erythematosus, the oftener we found minute atrophic discs about the mouth, which did not correspond with

the classical descriptions of that disease. The conclusions which Dr. Stelwagon made were justified by the facts. He did not think we could dogmatize respecting so rare a group of cases, with such curious symptoms.

Dr. James C. White stated that the photograph shown by Dr. Stelwagon was almost a *fac-simile* of a case that he was treating at the present time. One saw these puzzling eruptions about the mouth and upper and lower lips which closely resembled some forms of syphilis, eczema and lupus erythematosus, and it was very difficult to make a clear diagnosis. This case he referred to was one of that kind. The expression of the disease upon the chin and upper lip was very loosely drawn; one could not say what it was, but there was a similar lesion on the cheek which was somewhat depressed in the center and had an elevated border. He had no doubt that it was a lupus erythematosus, and therefore interpreted the lesions on the chin and lip as being of the same character. They were alike in duration, and he thought we were authorized in such a case to interpret the lesser expression of the disease about the mouth also as legitimate lupus erythematosus.

Dr. William T. Corlett said he had a case under observation at the present time, which he expected to refer to later, which seemed to be related to one of those reported by Dr. Stelwagon, and for that reason he might call attention to it. He was going to speak of that case because the alleged cause was vaccination, although he did not think it had anything to do with it. The patient was treated for lupus erythematosus for six months before he saw her, and the treatment had possibly modified the character of the eruption. The mucous membranes were involved, but to a lesser extent than the skin. In that case he was inclined to regard the eruption as syphilitic.

Dr. S. Lustgarten said that he would like to refer to the remarks of Dr. Hyde about the character of late syphilitic lesions. He thought it was very misleading to refer to them as being usually gummatous in character, and the occurrence of very superficial lesions in a late stage of syphilis was more common than was generally supposed. Leukoplakia was a superficial lesion of the mucous membrane, and we found similar conditions on the skin. He had seen several cases of eczematous forms of eruption on the hands and palms in very late stages of syphilis, and these frequently went unrecognized. His impression of these cases was that they were of syphilitic origin, and demanded energetic specific treatment.

Dr. Hyde said that he would call Dr. Lustgarten's attention to the fact that perfectly typical patches of leukoplakia occurred in non-syphilitic individuals.

Dr. Frank H. Montgomery said that while perhaps Dr. Hyde, in his remarks, accentuated the rarity of superficial eruptions in late syphilis, the differential diagnosis in the case referred to by Dr. Stelwagon was based upon the appearance of the lesions, which did not correspond with those of parasyphilitic lesions sometimes met with on the lips and

mucous membranes. The possibility of seborrhoic eczema was considered. With that case still in mind, Dr. Hyde and the speaker studied quite recently two very interesting cases in which there was an unquestioned seborrhoic eczema of the scalp, nose and skin of the lips together with involvement of the mucous membrane of the lip. In both instances, the patients were neurotic young women who had the habit of moistening the lips with the tip of the tongue. The lesions on the skin disappeared promptly, and the condition of the vermilion border of the lips improved greatly under treatment with sulphur ointment.

Dr. Schamberg said that the patient whose case was reported by Dr. Stelwagon had at one time been under his care. At that time in addition to the condition of the lips and the mucous membranes described, he had an affection of the hairy region of the face, which was of the nature of sycosiform eczema.

On this account he sacrificed his beard and mustache. Dr. Schamberg had also treated the patient for a vesicular eczema of the hands and feet, which had developed during his return from Europe.

Dr. Gilchrist said he had seen lately a marked example of an eruption of the lips which apparently belonged to this class of cases. The patient was a girl of sixteen, with two patches of the eruption on her upper lip. He did not think we could elucidate the pathological condition of these cases by merely taking scrapings from the lesions. The proper method was to excise a small portion of the lesion, and on microscopical examination one could then differentiate between lupus erythematosus of the lip, syphilitic patches on the lip and the disease first described by Dr. Fordyce.

Dr. Stelwagon, in closing the discussion, said that Dr. Zeisler referred to a similar eruption to this involving the scrotum. He had never observed it there. No one, in looking at this photograph, would deny the possibility of lupus erythematosus, but no one who watched such a case for any length of time would not be willing finally to discard that diagnosis. The lip was usually universally involved, and there was never any tendency to atrophic change. In the case photographed there was no resemblance whatever to lupus erythematosus at the first time he saw it.

As regards syphilis he said that of course we knew that syphilis could do almost anything in connection with lesions of the skin, but it was rare for a syphilitic disease of the mucous membrane to remain so benign for four or five years, and it was also unusual for a syphilitic eruption to be capricious, and disappear here only to re-appear somewhere else. Furthermore, in the cases reported, there was an entire absence of a syphilitic history. In spite of this, he was so strongly impressed with the possibility of syphilis that specific treatment was instituted in a few instances, but it had absolutely no effect on the lesions or course of the disease.

A SECOND CASE OF CREEPING ERUPTION (Lee), LARVA MIGRANS (Crocker), HYPONOMODERMA (Kaposi), DERMAMYIASIS LINEARIS MIGRANS ŒSTROSA (Kumberg); with brief reference to three other cases unpublished.

By Henry W. Stelwagon, M.D., Philadelphia.

Read before the Section of Cutaneous Medicine and Surgery of the American Medical Association at the Fifty-fifth Annual Meeting, held at Atlantic City, June 7 to 10, 1904.

IT is apparently only recently that this extremely curious and distinctive malady has come under American observation. It would seem, in fact, likewise rare in other countries, Russia, judging from published reports, recording the most cases. In our own country, so far as I am aware, but few cases have been observed. Van Harlingen[1] was the first I think, of our American colleagues who, a few years ago, reported some cases. His paper was followed by my own report[2] of a case before this section at the June meeting of last year. More recently Hamburger[3] added one case, and reviewed those previously reported. Inasmuch as both Van Harlingen's and Hamburger's excellent papers go into the subject of the literature and speculations as regards the particular parasite, and the latter discusses its relation to myiasis, I shall content myself by simply presenting a brief record of my second case. In my paper of last year the larva discovered in some of the Russian cases was referred to. I might add that excepting the Russian findings no others have succeeded in getting hold of the organism.

The features of these remarkable cases are pretty much alike, varying as to the amount of inflammatory reaction, the surface traversed, and the duration of the malady. The notes of the second case that came under my observation last June at the Skin Dispensary of the Jefferson Medical College Hospital are necessarily brief. The patient, a male adult, a Pennsylvanian, had just returned from South America. It was before reaching here that his attention was called to a slight irritation on the dorsal aspect of his left foot, toward the inner side. This at first consisted of a short elevated slightly red

[1]Van Harlingen. Report of three cases of Creeping Larvæ in the Human Skin (Hyponomoderma, Kaposi), *Amer. Jour. Med. Sci.*, September, 1902.

[2]Stelwagon. A Case of Creeping Eruption, *Trans. Section of Cutaneous Medicine and Surgery of the A. M. A.* for 1903, and Jour. Cut. Dis., November, 1903.

[3]Hamburger. Creeping Eruption: Its Relations to Myiasis, Jour. Cut. Dis., May, 1904.

line. It extended slowly from day to day. When the patient came under my care the eruption had, according to his statement, lasted ten days. The line was at this time about four to five inches long, and, as shown in the accompanying photograph, somewhat tortuous and irregular, and extended from the lower part of the instep up to a little above the ankle, having begun, as already noted, in the former region. As to its characters it differed but slightly, if at all, from the case reported last year, except as to its limited extent and the presence of but one parasite. It will be recalled that, in the case of last year, both the back and the lower leg region were the seats of a similar eruption; on the back it was extensive, but had ceased to be active when the case came under my observation, while on the lower part of the leg there was an active and extending line. As the back eruption, according to the boy's father, was still active when that on the ankle began, it was evident in that instance there were two parasites present. In the case I am now reporting there was but one extending line, and inferentially but one parasite. When this case was first seen by me the beginning part of the line was already almost sunken to the normal skin level, and the redness here in great part had gone, leaving behind slight pigmentation. Further along, the line-like ridge was quite noticeable, looking in some parts solid, in others vesico-papular, and in others distinctly like a narrow irregular linear vesicle, having, roughly speaking, a chain-like or bead-like aspect. Toward the extending end it was more of an erythemato-papular nature, and at the extreme end merely showed as a thread-like erythematous line, scarcely elevated. In this case by pressing a piece of glass upon the region of the extreme end of the line, and then using a magnifying glass, I could detect what seemed to be the parasite, appearing as a minute grain-like grayish-black speck or dot just beyond the recognizable end of the line. Examined thus on three consecutive days the same grain-like speck was seen and always slightly ahead of the extremity of the still extending line. Attempts made to secure it, however, were not successful, but the attempts were not of a very active kind, inasmuch as the patient would not permit an excision of a small section for this purpose.

The treatment of the case of last year consisted in the administration of asafœtida, the cataphoretic application of a solution of corrosive sublimate to the suspected region, and touching the suspected site of the parasite with nitric acid. Although this poly-therapeutic method was successful, it left me in doubt as to the effective agent. This being the fact I began first in the present instance by employing the daily cataphoretic application of the corrosive sublimate solution for

a period of three days, but with no apparent effect, the line continuing to extend as before, a fractional part of an inch daily. This was then discontinued and an application of a minute droplet of nitric acid made to the suspected site of the parasite; this was followed by complete cessation of further progress, and the subsequent gradual disappearance of the ridge.

The opportunity of including brief descriptive references to the three other cases referred to in the title I owe to the kindness of Dr. Grover W. Wende, of Buffalo, New York. In regard to these Dr. Wende's letter may be quoted as follows: "I saw the patient but once and wanted to make further examination before reporting. This was however denied me as the patient was not again brought under my notice. The patient was a boy aged nine. The condition began upon the dorsal aspect of both hands, near the cleft of the thumb and forefinger, and in the space of about five months had traveled over the entire arms and chest. The boy's mother said that the disease began in the fall, after a stay at a summer resort. She, too, had contracted the malady, which affected the sole of her right foot; it remained four weeks, disappearing after repeated applications of vinegar and gunpowder. She also tried this home combination on the boy, but without result. It was then that she called at the Buffalo University Dispensary, but seemed to be suspicious of our intention when we wanted to remove a piece for examination, and left and failed to return. The aspect of the eruption was so characteristic of the cases reported by Lee, Crocker, Neumann, Sokolow, of larva migrans, that I did not hesitate to make such a diagnosis. The lines were irregular and serpentine, and the epidermis elevated and roughened. They ran from the hands to the shoulder joints, and then upon the chest, sometimes passing almost completely around the arms, the lines being broken in places. I regret that I was not able to follow up this interesting case." As to the third case, Dr. Wende continues: "In July, 1901, Dr. F. B. Green, of Elmira, New York, wrote me about a case, which from its description was undoubtedly one of larva migrans. In this instance the entire back was involved in such a way that the lines strangely crossed and recrossed each other."

It will be observed that in the extensive case which came under Dr. Wende's observation, beginning on both hands, there were evidently two parasites present. Possibly it is only a curious coincidence and scarcely worth particular mention, but it will be noted that in one of Van Harlingen's cases, and in two of my own, the malady began at or after a visit to the sea or seashore; in the two cases noted by Dr. Wende,

at or immediately after a visit to a summer resort; whether, however, this last was a watering place is not stated, but being in the neighborhood of Buffalo, it probably was. Another point of interest as shown in these cases as well as in others reported, is that the infection is almost always observed to have its origin on those parts most exposed to inoculation and invasion—hands or lower part of the forearm, the feet or lower part of the leg, and the buttocks or adjacent part of the back.

SOME NOTES CONCERNING DOMESTIC REMEDIES FORMERLY USED IN SKIN DISEASES.

By James C. White, M.D., Boston, Mass.

Professor of Dermatology, Emeritus, in Harvard University.

Read before the twenty-eighth annual meeting of the American Dermatological Association, Niagara Falls, June 2 and 3, 1904.

A HALF century ago, before the introduction of the thousands of proprietary preparations at present employed by the household, and by physicians as well, in the treatment of skin diseases, and before the days of universal cheap newspapers, largely sustained by the millions of money paid for the advertisement of such popular remedies, and when the resources of the general practitioner in the management of such affections were confined chiefly to arsenic and the application of lead water and oxide of zinc salve, there were certain well-known domestic measures mainly depended upon for the cure of cutaneous diseases. It may be desirable to put some of them upon record before they are entirely displaced by the inventions of the modern caterer to the credulity of the public in such matters, and interesting to consider how far their efficacious properties, if existent, rested upon any basis of action now recognized as well formed. It is impossible to attempt to present them to you in any duly classified order, as you will understand.

Some of these remedies were survivals of the surgery of past centuries, just as many of the popular theories regarding the nature of diseases held by the present generation were the doctrines held by our profession generations ago, but now discarded, as Friar's Balsam, for example; others were of indefinite age, and some had perhaps but a restricted and short lived reputation. The list I shall present might be indefinitely extended, were I to mention all the native plants which have been used in earlier days for disturbances of the skin, especially

in the country and where medical aid was not abundantly attainable. It would vary, too, according to the experience of observers in different regions of our diverse country. Such an exhaustive list I shall not attempt to record.

It is interesting to note that many of these vegetable remedies seem to have acquired their reputation in the treatment of skin diseases from the intensity of their color or that of their juices, as yellow dock (*Rumex*), poke weed (*Phytolacca*), saffron (*Crocus*), bloodroot (*Sanguinaria*), etc. Such conspicuous properties would influence naturally, and in no small measure, popular belief in their efficacy. On the other hand great numbers of our native plants received their popular names from real and fancied medicinal properties they possessed—as *Lobelia syphilitica*, etc.

Mechanical injuries of a superficial nature, bruises, excoriations, slight cuts, etc., were treated by various lotions always at hand in the family medical closet. Among these none was held in higher esteem in the country than the bottle of Balm-of-Gilead leaf buds preserved in rum or alcohol. Its penetrating and not unpleasant odor no doubt added to its reputation, but it had positive properties. It was a powerful irritant when used too freely, and upon some skins a single application would produce one of the most intense grades of dermatitis that we are acquainted with, as I have described elsewhere.[1]

It has not yet wholly disappeared from the household materia medica of New England.

Later tincture of arnica came into general use as an embrocation in the family, and was supposed to possess magical powers. If its virtues approached in minutest degree its positively dangerous qualities when applied to the skin,[2] its reputation was well founded. It has been largely banished to the province of veterinary medicine, and its domestic employment has been supplemented by the extract of hamamelis. The attributes of the tincture of the leaves and bark of this tree, Hamamelis, in the popular mind, when applied to the integument, are almost as marvelous as those of its twigs when used as "divining rods." It may be readily understood how the two embrocations first mentioned may exert some influence upon the cutaneous surface through their stimulating properties, but it is difficult to see why hamamelis extract should do more than simple alcohol and water similarly applied. The supernatural common title of the tree, witch hazel, must be a large element in the popular reputation of its products.

For fresh contusions, especially those of the "black and blue" type,

[1] "Dermatitis Venenata," Boston, 1887.
[2] *Ibid.*

the application of a raw beef steak was often resorted to. It retained the animal heat of the tissues and, like warm fomentations, favored, no doubt, the preservation or restoration of normal circulation in the part, thus preventing the deposit, or favoring the resorption of blood pigmentation.

Deeper, open lesions were generally treated by balsams and adhesive plasters variously medicated, thus sealing the wound to the entrance of germs and keeping severed parts in close apposition. When in spite of such unconsciously employed anti-bacterial measures, healing by "first intention" failed, the suppurating and ulcerating conditions were treated by all sorts of domestic poultices, such as those of bread and milk, slippery elm, flax-seed, yeast, etc. Exuberant granulation, or "proud flesh," was controlled by burnt alum or alum curd.

In deep seated inflammations, boils and abscesses, attempts to dissipate the process, or to favor the escape of the "matter" without the lancet, were made by painting with tincture of iodine, which sterilized, or applying slices of salt pork, or cloths smeared with brown sugar and soft soap, which stimulated, by a cranberry poultice, and the like. Poultices were used in boils; in runarounds and felons the offending finger was immersed in a cup of wood ash lye or stuck into a lemon over night, maceration.

Mild burns and scalds were often treated homœopathically by holding the part to the fire for a short time. This was supposed to "take the fire out" and to relieve instead of adding to the pain. Even in those days it was known that cooking soda, or salæratus, thickly strewn over a burned surface, after moistening, gave great comfort; sweet oil, and linseed oil and lime water, the carron oil, were also commonly used, cotton wool or cotton batting being saturated with them and bound about the part.

"Issues," so-called, on the theory of derivation, were employed not only to bring the peccant humors from important inner organs to the surface, as croton oil and tartar emetic ointment for similar purposes, but also to exert favorable influence on the course of chronic skin diseases through "counter irritation." A small abrasion of the skin, of the outer surface of the lower leg generally, was made, and over this a pimento, or black pepper seed was firmly bound until a small deep cavity was established. This little ulcer was kept open to discharge freely, and was often dressed with a peeling, two or three inches square, of the delicate inner portion of the outer bark of the white birch, so as to excite and sustain a secondary dermatitis of this dimension.

"Salt rheum" was treated by a variety of household remedies, some

of which may well be styled bizarre. For example: men, while urinating, would wash their affected hands in this excretion; affected parts were also bathed in cow's urine; a scorched cotton cloth shirt was worn in contact with the skin in infantile eczema of the trunk, and bandages similarly treated were applied to the limbs. That was undesigned sterilization, certainly. The most remarkable dressing coming within my experience was a case of acute eczema of the scalp in an adult, in which a live angle-worm poultice was applied. Mutton tallow, melted and spread upon linen cloth, was the favorite household dressing. It was bland and excluded the air. Perhaps it did as well as any treatment we now employ in many cases of this disease, unfortunately. It was often medicated with tar, or sulphur, or rosin in the kitchen laboratory, and this mention leads to the question: Why linen cloth was held to be so superior to cotton cloth for such purposes in the popular mind? It seems to be a groundless prejudice.

The number of domestic remedies used for ivy (*Rhus*) poisoning was large. Among those always at hand were soft soap, and salæratus, and vinegar. The parts were bathed freely with solutions of the first two in water, and if used at once they were of good service in washing away the unabsorbed poisonous principles. But there were many native plants supposed to exert specific action upon the poison and subsequent dermatitis, such as serpentaria, grindelia, comptonia, dulcamara, gelsemium, sassafras, cephelanthus, collinsonia, lindera, etc. As they were used in the form of decoctions, it was the much washing with them, rather than the individual constituents in them which availed chiefly. Lead water was also generally used both by the faculty and the physician.

It seems to me that warts were of much more frequent occurrence upon the hands of children, especially boys, in the days I write of than now, and the domestic materia medica employed for their removal is interesting to recall in view of our modern studies upon the influence of suggestion. There were various methods in vogue of "charming away" these disfiguring growths, and some persons were held to possess especial powers in such directions, often some well known old woman in one's circle of acquaintance. One way was to tie knots in a piece of twine or thread, as many as the warts present, and to bury it in some place unknown to their bearer. When the string had rotted away the warts were gone also. Other charms were employed, but they need not be mentioned. In all of them the imagination was impressed and faith in the success of the cure conveyed by the ceremony. So of sulphur and magnesium sulphate lately recommended. In fact, warts were often observed to disappear sooner or later at least after such incantations,

and the patient could not say just when, but warts are fickle things, and often disappear spontaneously. On the other hand, they often remain obstinately resistant to the most prized remedies of modern professional practice. The uncertain results of treatment may be learned by consulting the Index of Therapeutics of the National Dispensatory, where, under the heading, warts, twenty-four substances are enumerated supposed to possess curative power over them. Other popular methods were rubbing their surface with the juice of green bean pods or leaf-stems, or the thick white juice of milk weeds. I frequently use the latter in summer now with wonderful success at times. Lunar caustic was much used, and a large number of boys in every school could be seen with hands blackened by its application. It was a general belief among them that the blood of "seed-warts" would beget others wherever it came in contact with the skin.

There were but few household remedies in use for troubles of the scalp and hair. Was there less occasion for them then than now? The care of these parts at that epoch was very unlike that of the present, in the male sex at least. Boys and men wore their hair longer. Facilities for washing the head and bathing were far less universal than at present, for few homes, either in city or country, had internal plumbing arrangements. Finetooth combs were in general use for the removal of dandruff, and children's heads were customarily combed with them once a week on general principles, whether any visible cause were present or not. Hair oils and pomades, especially bear's grease, were universally used to make the hair sleek. The seat of the head of the family in pews of the country churches was conspicuously marked by a large grease spot on the plastered wall behind. Perhaps these measures were more conducive to the longevity of hair than our frequent shampooing. In loss of hair the application of sage tea and tar water was commonly resorted to.

Pediculosis capitis was a frequent condition in children of all grades of society, communicated through the schools, and there were then but few immigrants to introduce or excuse its entrance into the family. Here, too, the finetooth comb was relied upon as efficient treatment. The animate objects were removed by it, and the nits were crushed by the nail of the operator against the body of the instrument. Sunday morning was generally devoted to this performance, all the children of the family submitting to it in turn. In this way only was the pest of lice kept under control.

Scabies, too, was very prevalent in New England in early days. It was commonly called "Jackson itch," a title probably conferred by the Whigs. Sulphur ointment, pretty strong, was the popular remedy for

it. The patient was smeared with it, and then sometimes laid down before the open fire to melt it thoroughly into the skin. That extensive dermatitis frequently followed such roasting may well be understood.

In ringworm, domestic empirical experimentation hit upon the efficiency of parasiticidal treatment long before the vegetable nature of the affection was known. Even to his last days, you will remember, Erasmus Wilson, the only recognized authority in matters dermatological by the profession at that period, denied the parasitic character of this and kindred diseases. The household remedies most in use were: a paste made by rubbing together gunpowder and vinegar; burning a cotton rag between two cold shovels, and applying the thick, black, oily empyreumatic product of smothered combustion, containing creasote and pyroligneous compounds: a copper cent was "soaked" in vinegar and the resulting solution applied. Painting with ink was resorted to, but writing-ink in those days was quite unlike our present diverse fluids, so-called: it was a solution of tannate of iron. Some of these remedies are still employed occasionally. The use of tincture of iodine for this purpose, now so popular, was then unknown.

I have thus briefly enumerated many of the household remedies employed in the middle half of the last century in the most common diseases of the skin. What a contrast do these days of the thousand advertised proprietary agents in dermato-therapy present. Take up any evening or society paper and read the columns devoted to the announcement of such remedies. I read in one, published in Boston a few days ago, eleven advertisements relating to the removal of superfluous hairs by electrolysis, and many others of cures for baldness and scalp affections. Many also for making the "complexion" beautiful, and the usual extensive list of the familiar proprietary remedies for all the common cutaneous and "blood" diseases. Before long, no doubt, similar advertisements regarding radio-therapy will be added to this list.

In the last Report of the Massachusetts Board of Health a list of twelve well-advertised "hair restorers" containing acetate of lead was published, also nine cosmetics for the face containing corrosive sublimate in the proportion of one to fifteen grains to the ounce, and thirty-three "sarsaparilla remedies" and "blood purifiers" holding iodide of potassium in solution. The fact that the innumerable newspapers and popular journals of our country are largely supported by such advertisements, and that enormous fortunes are often made by the manufacturers of such nostrums, shows how extensively diseases of the skin are treated among us independently of professional advice.

REASONS FOR CONSIDERING DERMATITIS COCCIDIOIDES AN INDEPENDENT DISEASE.[1]

By Douglass W. Montgomery, M.D., Professor of Diseases of the Skin, University of California,

and Howard Morrow, M.D., Assistant to the Chair of Diseases of the Skin, University of California.

Read before the twenty-eighth annual meeting of the American Dermatological Association, Niagara Falls, June 2 and 3, 1904.

A NUMBER of writers have made the mistake of considering dermatitis coccidioides and blastomycosis identical diseases, and many circumstances have contributed to this error.

Our knowledge of both diseases is new;

Most of the cases of both diseases have been reported from the United States;

The first cases of dermatitis coccidioides were reported at about the same time as many of the early cases of blastomycosis;

The mould causing blastomycosis and that causing dermatitis coccidioides have many points of striking resemblance, both in their growth on culture media, and in their growth in the tissues.

Some of the vegetating lesions on the skin in blastomycosis resemble in a general way those of dermatitis coccidiodes;

And finally the name, Montgomery, of one of the men active in developing our knowledge of blastomycosis is apt to be confounded with the name of one of the writers of this article, who has aided in reporting two of the five cases of dermatitis coccidioides reported in the United States.

Although there are the above opportunities for error, making it perfectly natural that the two diseases should be confounded, yet they are in reality very distinct, and the object of the present paper is to bring out the points of distinction as clearly as possible.

The organism causing dermatitis coccidioides has a double cycle of growth; one as seen in the tissues, the other as seen on culture media, and these two cycles of existence have no features in common. No such well marked, absolutely distinct cycles of existence have ever been noted in blastomyces.

[1] There is a question whether this disease should be called coccidioidal infection or dermatitis coccidioides. In one of the cases reported, that of Moffit and Ophüls, there were no skin lesions, and therefore it was not a dermatitis. In another case, now under observation by a confrère, there is only one cutaneous lesion on the tip of the nose, all the other lesions being deep seated.

On culture media the organism of dermatitis coccidioides grows as a mould, and in its gross appearance resembles the growth of blastomyces. There are points of difference, however. On agar the aerial hyphæ of the coccidioides organism are not high and furry, while in mature cultures of the blastomyces organism the aerial hyphæ are frequently very high. In the coccidioides organism the growth on agar is well circumscribed, and it sits in the media like a button with a sharply bounded periphery, while the growth of the blastomyces extends out into the surrounding media as a gradually diminishing haze (Morrow). The coccidioides micro-organism grows far faster than the blastomyces, and it liquefies gelatine more readily. These features are so constant as to enable one to separate the culture tubes with certainty. In the coccidioides cultures small spore-like bodies are present, but no double-contoured capsulated forms have been found and no budding forms have ever been seen, while budding forms are characteristic and frequent in the yeast fungus, and capsulated bodies are frequently seen.[2]

Both the blastomyces and coccidioides fungi seem to be fatal to the same kinds of animals. Large doses of both are necessary in order to insure success in the inoculations. Inoculations into guinea pigs of a fatal dose of coccidioides fungus tends to implication of the testicles which are greatly enlarged and turned into caseous masses. In none of the experiments of blastomyces has this been observed.

In the tissues the organism of dermatitis coccidioides increases by endogenous spore formation, and no budding has ever been seen in it; while the blastomyces multiply in the tissue only by budding. This is a well marked toxicogenic difference and divides the organisms sharply from one another. As seen in the tissues the most common form of the coccidioides micro-organism has a perfectly clear capsule

[2] The series of experiments were carried out, as regards the blastomyces, with cultures received from Drs. J. Nevins Hyde and F. H. Montgomery. Drs. Hyde and Montgomery kindly sent us these cultures taken from cases one, four and six, as reported in the *Journal of the American Medical Association,* June 7th, 1902. As regards the coccidioides, the experiments were made with cultures taken from three cases observed by us.

No budding forms have been found in the organism of dermatitis coccidioides by either Rixford, who first found the disease in California, by Gilchrist, or by Hyde and Montgomery, or by Moffit, or by Ophüls, or by Ryfkogel, or by Erich Cohn, or by either of the writers of this paper.

Erich Cohn has recently worked over this subject with material sent by us (Morrow and Montgomery), to v. Wasielewski. This material was taken from the case reported in the *Journal of Cutaneous and Genito-Urinary Diseases,* Jan. 1902.

with a double contour. This capsule encloses a sphere of protoplasm having a granular dark periphery and a lighter somewhat granular center. In another form the capsule encloses a vast number of small spherules, evidently due to endogenous spore formation; some of these organisms have their capsules broken and the spores can be seen escaping from them. Others are entirely empty and pieces of broken capsules can be seen scattered in the tissues. In others the contents seem to be dead and shrivelled without forming any spores whatever. Out of other broken capsules ray-like filaments spread out in a fan shape resembling strikingly the rays of the ray fungus, but not clubbed. Furthermore the rays grow out of a defect in one side of the capsule as out of a cup, and not from the center in all directions as in the ray fungus.[3]

This is the only indication of anything resembling a filament or mycelial thread in this growth as seen in the tissues. In fresh specimens the double contoured spheres may often be seen to be surrounded by a halo of short filaments like the cilia of ciliated epithelium. The coccidioides bodies are much larger than the blastomyces bodies. The coccidioides bodies are frequently 30 microns in diameter, while the blastomyces average about 12 microns.

The only resemblance between the coccidioides organism, and that of blastomycosis as seen in the tissues lies in the double contoured capsules with the granular contents that may or may not be vacuolated. The blastomyces has no cilia-like halo, no filamentary outgrowth, and no endogenous spore formation, but on the other hand the blastomyces has budding forms, which the coccidioides absolutely lacks. Furthermore the double contured coccidioides capsulated bodies are almost always as circular as if turned in a lathe, while the blastomyces bodies are frequently oval.

When a droplet of pus containing some of the above mentioned double contoured encapsulated spheres is taken from a lesion of a patient suffering from dermatitis coccidioides, and put into a hanging drop of culture medium a curious change may be seen. A filament will begin to grow out on one side of a capsule, and this fila-

[3] Spherules of uniform size suggesting spores are said by Hyde and Ricketts to be found in the periphery of the protoplasm of the capsulated bodies of blastomyces both in cultures and in the tissues, but they are always referred to in the above way as suggesting spores, and never seem to appear as the positive endogenous spore formation as seen in the organism of dermatitis coccidioides. (A report of two cases of blastomycosis of the skin in man by Drs. J. Nevins Hyde and Howard T. Ricketts, *Journal of Cutaneous and Genito-Urinary Diseases*, Jan. 1901.)

ment constitutes a mycelial thread, and all the subsequent extracorporeal growth of the organism is that of a fungus, and differs entirely from its intracorporeal growth that so much resembles a coccidium. (Ryfkogel). Nothing like the above phenomena has ever been observed in blastomyces.

All the cases of blastomycosis bear a striking resemblance to one another, while on the other hand the cases of dermatitis coccidioides although few in number, are characterized by a great diversity in the clinical picture presented. For instance, there is at least one case of dermatitis coccidioides reported that presented no skin lesion at all; all the lesions were either subcutaneous or in the internal organs.

The clinical resemblance between the diseases consists in the warty rotten growths that resemble somewhat the lesions of tuberculosis verrucosa. Dermatitis coccidioides frequently appears, however, to be an internal infection and therefore exists first as an internal disease, usually of the pleura or lungs. The lesions on the skin are in such cases secondary to the internal malady, and are scattered widely over the skin or give rise to subcutaneous abscesses. Apparently, however, the infection may take place in the skin and remain localized for a long time in this organ before attacking the internal organs. After the disease has existed for some time as a localized malady, it invariably spreads, always causing death. The spread of the disease is usually rapid, occupying from a few months to a couple of years. But in two instances where the disease appeared to begin in the skin and remain localized in the skin for a long time, the patients lived for years after infection.

Blastomyces is always chronic and has a preference for the outer surface of the lower eyelids, where it tends to form crescentic shaped granulating sores. No such preference is noted in dermatitis coccidioides. A characteristic of blastomycosis is the presence of miliary abscesses that form in the raised wall of the granulations—these are not seen in dermatitis coccidioides, where the skin lesions resemble the rotten tomato-like lesions of the tuberous iodide of potash eruption. Blastomycosis appears always to be in the first place a disease of the skin.[4] It has a tendency to remain localized in its place of origin, and it has little tendency to cause metastasis.

Blastomyces may exist for years in a favorable locality without causing any serious inconvenience. It has caused death, but this is

[4] Busse's case is an exception to this as it began by a swelling over the left tibia, followed by effusion into the left knee joint. Next it appeared in the skin of the face. Then generalization and death.

exceptional. In many instances of blastomycetic infection there is under appropriate treatment complete recovery; in all cases there is improvement, and death is the exception (J. Nevins Hyde and H. T. Ricketts, *Jour. of Cut. and Genito-Urinary Diseases*, Jan., 1901), while in dermatitis coccidioides there has, up to the present, been an invariably fatal termination.

In blastomycetic infection iodide of potash, as above indicated, is strikingly beneficial, while in dermatitis coccidioides it has no effect whatever. The possibility of recovery in dermatitis coccidioides must, however, we suppose, be granted because lesions in the skin do heal spontaneously, and because healing sometimes takes place in internal organs.[5]

The following points are characteristic of coccidioides and coccidioidal infection, as against blastomyces, and blastomycetic infection.

The cultures are characteristic;

The organism has a double cycle of development, the one cycle differing absolutely from the other;

There are no budding forms either in the cultures or in the tissues;

There is endogenous spore formation in the tissues, and this appears to be the sole mode of reproduction in the tissues;

The capsulated bodies in the tissues are comparatively large, and are almost always circular;

In animal experiments, the testicle is a favorite seat of the disease;

The infection tends strongly to become generalized;

The prognosis is absolutely bad;

The administration of iodide of potash has no control over the disease.

DISCUSSION.

Dr. Gilchrist said he did not quite agree with some of the statements made by Dr. Montgomery. Wernicke, of Buenos Ayres, was really the first to describe these cases of protozoic infection. Posados in working up Wernicke's case had been able to reproduce the disease in monkeys, but never obtained any cultures. Dr. Rixford, of California, and he (Gilchrist) had the second and third cases, and the disease was entitled for the first time a *dermatitis protozoica*. Sanfelice had, previous to this, demonstrated that blastomyces could develop by endogenous sporulation and since Ophüls had investigated another case in San Fran-

[5] See healing of the testicle of a guinea pig in Erich Cohn's experiments. (*Zur Kenntnis des Erregers der "Dermatitis Coccidioides"* von Dr. Erich Cohn, *Die Hygienische Rundschau* No. 2, 1904.).

cisco and shown definitely that these sporulating organisms grew on media in pure culture, direct from the lesions as well as demonstrating the endogenous sporulation in animals, he (Dr. Gilchrist) had accepted the fact that these cases probably belonged to the blastomycetic group. Dr. Montgomery was now arguing that this group (sporulating) were coccidiidial without any sufficient and solid reasons, certainly without any experimental or scientific proof. Even admitting that the organisms were of animal and not of plant origin, the name Dermatitis protozoica had already been applied. No reasons had been offered why the name should be changed to dermatitis coccidioides. Coccidia was a subgroup of protozoa. Dr. Gilchrist did not think Dr. Montgomery had made out his case.

Dr. Frank H. Montgomery thought the situation would have to be worked out on its merits. He thought some recent developments would lessen the distinction between blastomycosis and the cases described by Dr. D. W. Montgomery under the name of dermatitis coccidioides. The speaker said that in three of the cases of blastomycosis referred to by Dr. D. W. Montgomery there were subcutaneous lesions containing blastomycetes. In the case reported by the speaker, and later by himself and Dr. Walker the subcutaneous lesions, which resembled those of erythema nodosum, were carefully watched during their development into typical lesions of blastomycosis. In the two other cases, the systemic symptoms preceded by several months the cutaneous lesions. In a case of systemic blastomycosis recently reported before the Chicago Pathological Society there were no cutaneous lesions whatever. Aside from these four systemic cases, in others typical metastases have been demonstrated. These facts, the speaker thought, lessened the clinical differences between the two conditions under discussion. There were now four fatal cases of blastomycosis on record, in one of them the death occurred but a few weeks after the first symptoms of the disease were recognized.

As to the cultural features of the blastomycetes, while as a rule the growth was quite uniform on a given culture medium, the organism differed considerably in different cases and on different culture media. The speaker did not think that the size, shape or number of the organism, or the appearance of the culture were sufficient grounds for a differential diagnosis. Certain important differences, however, still existed. In the protozoan infections the organism did not develop in the tissues by budding, but always by endogenous spore formation. In blastomycosis budding was the only demonstrated method of development, though organisms were seen, in some instances, which contained spore-like bodies.

The speaker said he wished to correct an impression which prevailed with reference to the influence of potassium iodide on the lesions of blastomycosis. A few patients had recovered under this treatment alone, but in the large majority of cases the improvement continued only to a certain point, a little short of complete recovery. Dr. Hyde and he had two

cases under observation at the present time, one a very extensive case of cutaneous blastomycosis dating back four or five years; this patient had neglected treatment and was now slowly dying of cachexia, with all the symptoms of systemic blastomycosis. In another case, which was rapidly approaching a fatal termination, the patient had been treated thoroughly with potassium iodide and the X-ray, without preventing metastases and extension of the disease.

Dr. Hyde, after congratulating Dr. D. W. Montgomery upon his excellent presentation of his side of the case, said that while the subject was still obscure, he thought eventually it would be proved that they were dealing with an organism having a different mode of development and growth. Dr. Hyde said that when he demonstrated his first case, some years ago, he was asked by Dr. James C. White why he called the affection blastomycotic dermatitis, and the reason he gave was that it was first described under that name. He thought now, however, that the term should be abandoned. The disease was a blastomycotic infection, and the fatal cases he had since observed had profoundly impressed him. Potassium iodide, he thought, had simply an inhibitory action on the growth of the organism. Patients would be almost cured by its use, but a recurrence could be confidently looked for.

Dr. Hyde said he could corroborate the statements made by Dr. D. W. Montgomery in regard to the cultural features of the organism he had described. In the sections which the speaker saw in San Francisco, there was certainly no budding formation. The speaker said he could not explain why so many cases of blastomycosis were met with in Chicago. As bearing on the possible etiology of the disease, the case reported by Drs. Ormsby and Miller was very interesting. This patient stated that he had always enjoyed perfect health up to the time that he took a room in a hovel, with a window directly over a manure pile, the stench of which he constantly inhaled. This recalled to Dr. Hyde's mind a number of other cases of blastomycosis in which the patients gave a history of having been more or less constantly exposed to the ammoniacal effluvium of manure, and some experiments were undertaken to discover whether this was possibly an etiological factor in the disease. A number of culture tubes were exposed in a well-kept city stable, with negative results. Some tubes were then exposed to the very manure pile under the window of the room which had been occupied by the man who had developed blastomycosis. Three of these tubes became infected and were sent to the botanical department of the University of Chicago, where the professor of botany reported that the infection was due to a budding organism. (Drawings of the organism were exhibited by the speaker.)

Dr. Schamberg referred to an ulcerative case of blastomycosis which proved utterly refractory to the use of potassium iodide and the X-rays. There was not only no improvement but a gradual extension of the disease during the employment of these measures.

Dr. F. J. Shepherd said he could also testify to the inefficiency of potassium iodide in at least some cases of blastomycosis. During the past four years he has had a patient under his observation who was still uncured, in spite of very faithful treatment with potassium iodide. In another very mild case, however, a complete cure was apparently effected.

Dr. Stelwagon said that in a case of blastomycotic dermatitis that was under his care some years ago there was marked improvement at times under the use of iodide of potash. The improvement only continued up to a certain point, however, and the patient died in the course of two or three years from some lung complication. No autopsy was obtained.

Dr. Gilchrist said that in one of his cases, the patient was a negro, and the disease had started while the man was an inmate of the penitentiary, where no other cases were reported.

Dr. Frank H. Montgomery, in reply to a question as to whether iodine had ever been injected locally in these cases, said that it had not, to his knowledge.

Dr. Douglass W. Montgomery, in closing the discussion, said that while he was fighting with one hand, in that the only cases of blastomycosis he had seen were those shown by Drs. Hyde and F. H. Montgomery, in Chicago, his opponents were also fighting with one hand in that they had never seen a case of coccidioides dermatitis. If the symptoms of blastomycosis were so well defined that the diagnosis could not be questioned, then surely it was distinct from coccidioides, and the speaker said he did not think this distinction between the two affections would ever be broken down. Blastomycosis and dermatitis coccidioides were two separate diseases, although the respective micro-organisms resembled each other. As far as potassium iodide was concerned, it invariably gave no results in coccidioides, whereas it frequently gave good results in blastomycosis.

A FURTHER REPORT OF A CASE OF MULTIPLE MYOMATA OF THE SKIN.

By W. A. Hardaway, M.D., Saint Louis, Mo.

Read before the twenty-eighth annual meeting of the American Dermatological Association, Niagara Falls, June 2 and 3, 1904.

In August, 1885, I reported to this Association the case of a man the subject of multiple myomata of the skin,[1] and now after the lapse of eighteen years, having the good fortune to meet the patient again, I thought it might prove interesting to give some account of his intervening and present condition.

[1] Read before the Am. Dermatological Ass'n Aug. 27, 1885, and published in the *Am. Jour. Med. Sciences*, April, 1886.

As concisely as may be, the history of the case as given at the time of the first report was as follows:

"J. B., aged thirty-six years; family history good, is married and has two healthy children. Present affection began about a year ago, when he observed that at any change of weather he experienced a drawing pain, lasting about five minutes, where the lesions are now situated. These pains were not constant and sometimes would be absent for three or four days or as many weeks. Later, but he cannot say exactly when, he became aware of the presence of a few lesions, and from time to time, he was conscious that others developed.

"The patient is a strong, hearty man, a peddler by occupation, and exposed to all kinds of weather. The neuralgic pains mentioned above come on mostly at night, when in bed; each paroxysm lasts from three to five minutes, but is not repeated the same night. When a paroxysm occurs the patient says that he feels as if he were being crushed together, and he tosses about in great agony. The pain, he thinks, makes its appearance without any premonitory warning, and is confined to the region of the growths.

"The parts are not at all hyperæsthetic, but moderately deep, direct pressure with the fingers will induce intolerable pain; this pain, however, is but temporary and altogether different in character from the vice-like pressure of the spontaneous attacks.

"The infiltrated patch is situated on the right side of the back in the mid-dorsal region. It commences at the spinal column, and takes an oblique downward course. It is four-and-a-half inches long by two-and-a-half inches wide. It passes over to the left side of the spine by two small tubercles. The patch is made up of an aggregation of variously sized growths and infiltrations. Some of these are round and decidedly elevated above the skin, at least three being as large as hazel-nuts; others are elevated a few lines only and are spindle-shaped, or else dispersed in lines and streaks. The growths seem to involve the skin only. The overlying epidermis appears normal. The patch is of a reddish color, resembling flesh moles. None of the growths is pedunculated."[2]

Present Condition. I may state that subsequent to the extirpation of one of the small tumors for microscopical examination, the whole offending patch was cut out (see photograph) in the hope of procuring some relief from the intolerable pain.

[2] Dr. L. Bremer who made the microscopical examination of one of the extirpated growths said that the "tumor is a conglomerate of interlacing bundles of smooth muscular fibers. These bundles are formed by the proliferation of the muscular elements of the arteries and veins of the original derma."

PLATE XXXII.—To Illustrate Dr. W. A. Hardaway's Article.

The patient declares that for eight or nine years after the operation he had complete relief; gradually, however, other tumors appeared about the original site, and again the pain returned, and soon became as severe as in former years. On comparison with drawings made at the time of his first visits, I find that growths have appeared in the original area, and also around and about it and in greater numbers. A small growth may be noted directly over the line of incision. Crocker states that these tumors never recur after excision, and it does not follow in this instance that there has been a recurrence of the extirpated growths, but probably that the lesions now present at the original site are new formations in the skin flaps. During the past year new tumors have made their appearance on various other parts of the body. For example, on the left side of the abdomen are about a dozen small tumors, roughly grouped, varying in size from a pea to a hazel-nut. On the upper portion of the right arm are some tumors that date back at least ten years. They were very small in the beginning, but have gradually increased in size.

The patient suffers greatly from spontaneous pain in these various lesions. The pain is said to be much worse at night and more severe in the winter than at other seasons of the year. There is also the same pain on pressure as in former times. There are some symptoms that he now presents that I did not note in my earlier account, and which the patient claims are of more recent development; namely, intense burning, tingling and itching in the tumors.

The man is now fifty-four years of age, of powerful build, and apparently in rugged general health in spite of his sufferings. His social condition has greatly improved in the past eighteen years, and, consequently, he is no longer exposed to the vicissitudes of wind and weather as in his early life, which, at the time, I was disposed to regard as accounting in a measure for his pains.

I could not induce the man to part with another piece of his skin for microscopical purposes, nor could I persuade him to keep on with an X-ray treatment from which I had expected much in the way of relief.

SOCIETY TRANSACTIONS.

NEW YORK DERMATOLOGICAL SOCIETY.

324th Regular Meeting, April 26, 1904.

Dr. Charles T. Dade, President.

A Case for Diagnosis. Presented by Dr. Geo. T. Jackson for Dr. Fox.

The patient was an Italian girl of seven years of age. Nothing could be ascertained of her parentage or previous history. The attendant of the child stated that the disease was first noticed some five or six weeks before coming to the Vanderbilt Clinic, as round, flat, dark-red lesions, about the size of a fifty-cent piece. There was one on the left thigh, and two on the right leg.

When seen by us a week ago these three lesions were present, and of about the size indicated. They were flat, round, raised slightly with depressed centers. One of them showed an uneven surface. They were dull red in color. There was no enlargement of lymph glands. No pain was complained of.

Dr. Klotz said there was no reason why it might not be syphilitic, the elevated margins, the color, and the kidney shape lesions all were in favor of the diagnosis, even in the absence of other symptoms.

Dr. Piffard considered it a case of pemphigus and suggested arsenic in the treatment.

Dr. Lustgarten considered it a form of scrofuloderma.

Dr. Allen thought that the appearance suggested a bromide eruption.

Dr. Bronson said it was pretty evidently an infectious process of some sort, but could discover no definite signs of syphilis.

Drs. Sherwell, Fordyce, Elliot, Jackson, and Mewborn considered the lesions to be a scrofuloderma.

Dr. Johnston made the diagnosis of ecthyma gangrænosum. This diagnosis he based upon the history of rapid development, the circular form and the punched out appearance of the lesions.

Dr. Lustgarten objected to the diagnosis of ecthyma gangrænosum, which usually presented uniform lesions, whereas the lesions in the case under discussion were not uniform. He considered it a form of scrofuloderma.

Dr. Fox said, in closing, that the typical lesions at the beginning were disk-like, firm, scaly patches, with an atrophic center. There was a rather deep infiltration with no signs of pustules. The ulceration on one leg had been caused by the treatment with liquid air.

A Case for Diagnosis. Presented by Dr. Fox.

The patient was a woman. For fourteen years she had suffered from an eczematous patch on the left leg. The patch would present a covering

of silvery white scales at times, but there was no infiltration. No evidence of scarring. There had been one application of liquid air.

Drs. Mewborn, Johnston and Holder considered the case one of psoriasis.

Dr. Fordyce was inclined to look on the case as a very superficial squamous syphilide because of its long duration, its polycyclic margin, and the absence of other lesions pointing to psoriasis.

Dr. Sherwell agreed with the diagnosis of syphilis. He thought, in fact, that the manifestation on the lower leg was quite typical of that condition in some people. He strongly advised specific treatment as a deciding factor in the diagnosis.

Dr. Klotz said that the unusual features were due to the atrophic condition of the skin, which was often present in varicose areas of the leg. It was not syphilitic.

Dr. Allen considered it a chronic psoriasis kept up by the varicose veins.

Dr. Lustgarten said that we ought not to stretch the term psoriasis to cover these lesions on the leg, that while they might be psoriasiform they were nevertheless eczematous.

Dr. Piffard considered it a varicose eczema.

Dr. Jackson said he was glad to hear so many opinions of the case. He was uncertain what it was when he first saw it, but now thought it was neither syphilis nor psoriasis, but eczema.

Dr. Elliot said that the eruption was of a slow, chronic type spreading and healing as it progressed and leaving atrophy on the surface primarily affected. He could not imagine a psoriasis which advancing in a serpiginous manner left such indelible traces of its existence, nor one which was so absolutely unilateral. He considered the case one of syphilis.

Dr. Whitehouse at first was inclined to consider it a parasitic eczema, but said that there was too much change in the central area, and the outline was more characteristic of syphilis.

Dr. Dade said that when unmolested the patch showed heaped up scales, perfectly typical of psoriasis. The redness and appearance of spreading at the edge had been caused by a very strong chrysarobin ointment. The clearing up in the center was certainly not atrophic—the thinning being more apparent than real, owing to the superficiality of the varicose veins.

Dr. Fox, closing the discussion, said that at the Vanderbilt clinic the case had been diagnosed as lupus erythematosus, psoriasis, eczema and syphilis. There was no evidence of syphilis, in his opinion, no great amount of infiltration, no scarring. There had been thin micaceous scales, but he considered one could not have a single patch of psoriasis lasting four or five years. There had been slight atrophy such as is often seen in varicose eczema.

A Case Showing the Effect of X-rays in Eczema Seborrhoicum of a Peculiar Type Upon the Backs of the Hands. Presented by Dr. Bronson.

The patient, F. H., was fifty-seven years of age, a cigar maker by trade, and had suffered from his present ailment for four years. When the patient was first seen, about a year ago, beside the affection of the hands, there were red, scaling patches on the scalp along the borders of an area of alopecia senilis. These patches had yielded to treatment by resorcin and by an ointment of ammoniated mercury. Upon the backs of both hands were sharply circumscribed red, scaling patches that showed no sign of vesiculation, had never been moist or exuding and were not attended with much itching. There was, however, decided thickening of the tissues. The color was a deep red or vermilion and the surface resembled somewhat a dry mucous membrane. There were, here and there, thickish scales, especially at the borders, and occasionally deep fissures would form. There was a history of a similar condition affecting the palms, but during the past four years they had been free from disease. In many respects the affection on the backs of the hands was more like a keratosis than an eczema, though evidences of inflammation were sufficiently apparent. The treatment had included Lassar paste with various ingredients, resorcin, salicylic acid, chrysarobin with ichthyol, tarry preparations and rubber gloves. Though from time to time much improvement was observed this disease still remained. On March 13th the back of the right hand, which appeared to be the worse of the two, was exposed to X-rays with a rather low tube at eight inches for eight minutes. Subsequent exposures, the time being gradually diminished to five minutes, were made—in all eight in number—up to the present time. The improvement became noticeable after about the fourth or fifth exposure and had continued steadily since. The redness had almost entirely disappeared and the appearance generally was in very marked contrast to that of the left. There was less thickening and scaling and all fissures had healed, while the other hand still remains in about the same condition as before. He expected now by the same treatment to get similar results in the left hand.

Dr. Allen thought that the diagnosis of seborrhoic eczema, as made by Dr. Bronson, might be accepted on account of the presence of a seborrhoic eczema of the scalp. He thought the benefit from using the X-ray had been very satisfactory.

Dr. Lustgarten considered the X-ray as the ideal treatment for these obstinate cases of seborrhoic eczema of the hands as well as in cases of psoriatic and tylotic processes of the same region. The results were quicker and better than by any other method. In this case he thought it would lead to recovery. He objected to the term seborrhoic eczema in these cases, clinically they were not seborrhoic nor yet a true psoriasis.

There was a somewhat deep infiltration and he preferred to call it psoriasiform eczema as a compromise.

Dr. Winfield was also inclined to take exception to the name seborrhoic eczema and thought that psoriatic eczema would be better and give a better idea of the clinical picture. He considered the rapid effect of the X-ray remarkably good, especially when there had been so few applications.

Dr. Klotz would rather call it a parasitic eczema and would not identify it with seborrhoic eczema. Eczemas were not infrequently found on the hands, which showed considerable infiltration and unusual tenacity, particularly in the sharply defined borders.

Dr. Jackson would not call this case one of seborrhoic eczema, nor did he think that Dr. Bronson had presented it as such. He regarded it as a chronic eczema.

Dr. Elliot remarked that a characteristic feature in Unna's description of seborrhoic eczema was the lack of infiltration. In this case there was a marked infiltration. He did not see how the term seborrhoic could be applied to it and would rather class it as a psoriatiform eczema.

Dr. Whitehouse agreed that there was a marked infiltration, too much so for a seborrhoic eczema. He considered it a parasitic eczema.

Dr. Fox concurred in the opinion that it was an eczema, but thought the term seborrhoic was not usefully employed in these conditions.

Dr. Fordyce said it was not so unusual to meet with the type of chronic scaling eczema, which had been presented by Dr. Bronson.

In predisposed individuals, such lesions might develop on a seborrhoic base but were met with, as a rule, independent of such a condition.

Dr. Johnston agreed in this opinion, especially in answering the question as to the parakeratosis.

Dr. Bronson, closing the discussion, said that he was surprised that so much discussion had been aroused with reference to the diagnosis of this case. The name under which it had been presented, as stated at first, was only a provisional one. That the affection was eczematous, of course, there could be no question and very likely it was more eczema than it was eczema seborrhoicum. He confessed that what eczema seborrhoicum was he did not know and doubted if anybody else did. But considering the peculiar and typical characters of the markedly circumscribed lesions on the hands, without even any surface exudation, little or no itching and this correspondence in many respects to lesions that in the first place were observed on the scalp and which seemed reasonably typical of what had been described as eczema seborrhoicum, it seemed to him that the designation was fairly admissible. But the chief point he had in view in presenting the case did not relate to its exact diagnosis, but to the very marked effect produced by the X-rays.

A Case of Paget's Disease of the Gluteal Region Cured by the X-ray. Presented by Dr. Fordyce.

The patient had been previously presented to the society and a brief report of the case was published in the December, 1903, issue of the JOURNAL OF CUTANEOUS DISEASES. Since that time she had had ten applications of X-ray with an entire disappearance of the disease.

Photomicrographs were shown illustrating the histopathology of the affection before, during and after treatment with X-rays. Sections from the center of the patch before treatment showed under the microscope a small-celled epithelioma. The edge of the patch presented, in places, proliferation of the basal layer of the epidermis with areas of hydropic and degenerated cells resembling, but not altogether identical, with those met with in Paget's disease of the nipple. The piece removed during treatment with the rays, showed a marked inflammation with many mononuclear and polynuclear leucocytes, some mast cells and plasma cells.

The connective tissue about the coil glands had undergone a mucoid degeneration. The epithelial cells of the coils also showed a degenerative change. After the inflammation resulting from the rays had disappeared no trace of abnormal epithelial growth remained. The original patch was covered with a thin layer of epidermis three or four cells in thickness.

Dr. JOHNSTON said that judging from portions of the patch shown in the microphotograph he would consider the case as a typical one of rodent ulcer. In regard to the degeneration of epithelium shown at the borders such changes were often seen in sections of soft moles. True, there were two diseases called by Paget's name, one of the breast and one of the bones, nevertheless, we knew quite well what was meant when Paget's disease of the nipple was mentioned; namely, a colliquative degeneration of the epithelium leading to an erosion of the surface with a subsequent or concomitant development of a duct carcinoma. The histological picture of rodent ulcer was also quite as typical whether ulcerated or not, so why attempt to change either name? One might as well object to the term lupus vulgaris which was not common, at least not in this country, and was a form of tuberculosis.

Dr. WHITEHOUSE thought the simple term cancer of the skin was sufficient.

Dr. LUSTGARTEN said the Society was deeply indebted to Dr. Fordyce for the painstaking manner in which the case had been investigated and presented. He specially wished to compliment the excellent photomicrographs. As to the diagnosis, he thought the line was not sharply drawn. In Paget's disease he had always found Wickham's bodies.

Dr. ALLEN objected to the term rodent ulcer. The term should be dropped as giving a false idea of security. It should be called rodent cancer. The result of treatment he considered excellent.

Dr. SHERWELL thought the term Paget's disease should be only applied to the breast, and there as Paget's disease of the nipple.

Dr. Winfield recalled, in this connection, a case he had seen three or more years ago, in which the disease began as an eczema of the lower lip, it first made its appearance in the center of the lip at the vermilion border, more and more of the skin and mucous membrane became involved, the center of the dermatitis became indurated, finally it began to resemble an ordinary epithelioma, it was removed, and microscopically it resembled that malignant neoplasm.

Dr. Piffard said that a number of years ago he had objected to the term Paget's disease of the nipple and had suggested "Mammalitis maligna."

Dr. Jackson considered the result to be excellent.

Dr. Fordyce, closing the discussion, said that as far as the clinical appearance went it was a typical picture of Paget's disease. The original patch was about two and a half inches in diameter, of a dark red or purplish color, with, in places, an eroded granular surface.

Had it been located about the nipple few would have hesitated to give it that name. Histologically certain points of difference were found in the appearance of the epithelial cells which will be brought out in a later communication. The infiltration of plasma and mast cells in the papillary region of the corium was identical in every way with that seen in Paget's disease of the nipple. At the margin of the diseased area the hydropic cells suggested those seen in Paget's disease of the nipple, but in the center of the patch the type of epithelial growth was that of a rodent ulcer.

A Case of Lupus Vulgaris of the Leg, Shoulder and Face. Presented by Dr. Fordyce.

The patient, a man about thirty-six years old, stated that the affection had begun more than twenty years before.

It had followed the amputation of a toe for some bone disease, presumably tubercular, and had slowly spread over the foot and leg. The area on the shoulder, about four inches in diameter, and the smaller one on the face had been present three or four years.

The chief interest in the case aside from the amount of skin involved was its possible origin from a tubercular focus in the bones of the amputated toe.

A Case of Lupus Verrucosus. Presented by Dr. Fox.

The patient was a woman presenting an eruption on the back of the left hand. The patch was about two or three inches in diameter and had elevated, papular, and in places warty-like margins. There was some scarring in the center.

Dr. Elliot called attention to the number and grouping of the tubercles in the scar tissue. He considered it a case of tuberculosis cutis—Lupus vulgaris serpiginosus.

Dr. Jackson offered blastomycotic dermatitis as a suggestion for further examination.

Dr. Klotz considered that it was neither characteristic of tuberculosis nor syphilis.

Dr. Lustgarten thought syphilis could be excluded. It was not a typical tuberculosis verrucosa cutis. Lupus or blastomycosis might be thought of.

Dr. Allen said lupus.

Dr. Dade agreed with the diagnosis of tuberculosis.

Dr. Fordyce considered it an atypical form of skin tuberculosis.

Dr. Johnston said that the specimen which had been submitted to him did not present the picture of tuberculosis verrucosa cutis, lupus or blastomycosis. There was a sheathing of round cells around the vessels and a proliferative endarteritis. The lesion was a granuloma, and taking the histological findings in conjunction with the clinical picture his diagnosis was syphilis.

Dr. Fox, closing the discussion, said his diagnosis was lupus verrucosus, for the lesions presented a clinical picture of this disease rather than of syphilis, but there had been some improvement under large doses of iodide of potash.

A Case for Diagnosis. Presented by Dr. Winfield.

The patient, H. M., native of Scotland, age 41 years, had always been well but never very rugged. No history of any constitutional disease (syphilis) obtainable. About one and one-half years ago he noticed a roughness of the skin over the base of the thumb, which he thinks followed a cut from his pocket-knife. This gradually extended until nearly the whole thumb was involved. At times there would develop a few superficially ulcerated patches over the diseased area. In the palm of the hand, slightly removed from the roughened skin, there are a number of wart-like excrescences arranged in a circle. Along the lymph vessels as far as the elbow there are innumerable, small, hard, shot-like nodules. The physician who had the patient in charge had made the diagnosis of lupus and had used the X-ray but without any great benefit, except to dry the ulcerated places. There had never been any pain in the diseased skin.

Dr. Lustgarten considered the case as a tertiary gummata cutanea more of the clavus syphiliticus type, complicated with œdema chronicum induratum. The miliary lymphangitis was highly unusual. He considers it a chain of bubonuli syphilitici tertiares.

Dr. Allen said that in conjunction with the scar in the neck he considered it a scrofulide. He did not think the X-ray indicated.

Dr. Sherwell did not consider it a syphilitic process and while he would hesitate as to the exact diagnosis he would suggest a probable tubercular condition, and possible osteo or other sarcoma.

Dr. Fordyce said the evidence was in favor of a tubercular process with secondary lymphatic involvement.

Dr. Klotz considered it an infectious inflammatory process combined with affection of the lymphatics similar to erysipeloid of Rosenthal.

Dr. Piffard said it was a tuberculide. The shot-like nodes in the lymphatics were purely accidental.

Dr. Dade considered it as tuberculous and similar, but less advanced, to the case of gummatous tuberculous lymphangitis of the arm of the Italian which he had shown before the society.

Dr. Winfield, closing the discussion, said that the improvement under X-ray was slight. The lymphatic enlargement had been present only about a month. Under manual examination the heads of the metacarpals and phalanges seemed enlarged, but a skiagraphic examination showed the bones to be of normal size, consequently he was inclined to consider this enlargement as periosteal. He said that when he first saw the case he thought it was not a good example of lupus and while in some respects it did resemble late syphilis, he hesitated to consider that to be the disease.

Dr. Piffard read "A Preliminary Note on the More Effective Utilization of the Spark-gap Radiations." (See Journal of Cutaneous Dis., 1904, p. 266.)

A. D. Mewborn,
Secretary.

NEW YORK DERMATOLOGICAL SOCIETY

225th Regular Meeting, May 24, 1904.

Dr. Charles T. Dade, President.

A Case of Duhring's Disease (?) or Neurotic Eczema (?) Presented by Dr. S. Sherwell.

The patient, K. T., aged eleven years, United States parentage, is of slender build. This peculiar and circumscribed eruption appeared on both nates about two years ago. At present the eruption is in the same location. The lesions consist of elevated papules and in places pustules and vesicles, almost bullous in character (dermatitis herpetiformis). The eruption improves from time to time, but relapses occur corresponding to the ordinary history of such cases. The case is shown on account of the extraordinary persistence in character and localization of the trouble. While it could be easily mistaken for a trouble of infectious character, the line of lesions being precisely like the edges of a "retirade" seat, my own opinion is that it is purely neurotic. The patient having shown for a year or two a tendency to slight scoliosis, his father placed him under the care of an osteopath and under the massage treatment some improve-

ment seemed to take place. The patient is of a highly neurotic temperament, as may be readily seen, and since he has been under my observation, May 10th, 1904, has received internally a tonic treatment of syrup of the iodide of iron and arsenic with locally a bichloride lotion. There has been a moderate improvement.

Dr. Jackson considered the case dermatitis herpetiformis. It was rather unusual for the eruption to localize itself so markedly.

Dr. Fordyce had seen a similar eruption in adults with deep urethral and prostatic trouble. He was inclined to view it as a dermatitis herpetiformis of neurotic origin.

Dr. Johnson recalled three similar cases seen in the past year. In one case, a young woman apparently sound and healthy, the eruption on the buttocks was of a similar saddle shape. There were also lesions on both arms below the elbows. This case had been treated by the hyperstatic current and all the lesions disappeared four days after the sparking. There were two points of interest in the cases to which he alluded, first that counter irritation over the spinal ganglia seemed to be of benefit, and secondly that in one case there was an alternation of pompholyx on one or both palms and soles.

Dr. Winfield thought it was a case of dermatitis herpetiformis.

Dr. Sherwell, closing discussion, said that it seemed to him quite evidently due to some form of spinal or peripheral irritation and that he had considered the advisability of using electricity to the lumbar ganglia in a mild moxa-like way or even the Paquelin cautery lightly brushed over the lower part of the spine.

A Case of Dermatitis Medicamentosa. Presented by Dr. Sherwell.

The patient was a stout, healthy-looking man of fifty-four years, a native of the United States whose occupation was that of engineer. His family history was good. Previous health excellent, habits temperate. About seven weeks ago on account of a general malaise he commenced taking "Kennedy's Medical Discovery," following this with "Swamp Root," two tablespoonfuls three times a day. The eruption made its appearance about a week after taking "Swamp Root." Eruption first appeared on lower leg, rapidly spreading until almost the entire body was involved except the face. At first the eruption was erythematous in character followed by an abundant scaly desquamation. This was the condition when first seen on May 12th. Is somewhat better since commencing treatment.

Dr. Lustgarten was inclined to regard the case as an atypical form of psoriasis, or at least as a psoriasiform condition.

Dr. Klotz considered it a dermatitis medicamentosa.

Dr. Allen said that he had seen many instances of eruption from taking the various patent preparations of sarsaparilla. That these eruptions were mostly due to iodide of potash there was no doubt. The case

under discussion, he regarded as a lichen planus which had been modified by the treatment. The history, duration, nocturnal itching, appearance of the lesions on the chest, and the brownish discoloration left by the patches he regarded as sustaining this opinion. In a case which he presented before the Society three months ago, after seven weeks' duration the pigmentation had been almost as great as that of Addison's disease.

Dr. Winfield thought it was a drug eruption. Two of the preparations were known to contain iodide of potash.

Dr. Johnson suggested the use of mercury internally. He had seen a lichen eruption disappear after ten days' treatment.

Dr. Jackson said that the case seemed to him to be an unusual form of lichen planus. The color was that which is characteristic of the lesions of that disease. On the scalp were some patches that resembled those of psoriasis and somewhat obscured the diagnosis.

Dr. Sherwell, closing discussion, said that the patient was perfectly well until seven weeks ago, when he began taking these patent medicines. That he had taken two bottles of Kennedy's Medical Discovery, one bottle of Hood's Sarsaparilla, and three bottles of Swamp Root.

Case for Diagnosis. Presented by Dr. George T. Jackson.

The patient was a boy twelve years old. His mother stated that he had always been "delicate" though she could not tell of any special illness he has had.

The eruption for which he came to the Vanderbilt Clinic began one week ago about the knees and on the next day all the lesions that are now present were out. Upon the right leg there are about twenty lesions; on the left leg ten lesions, and upon the right forearm two lesions. They are in the form of irregularly shaped macules, some round, some angular, some of no definite shape. They are of brownish color with a shade of red in the brown, and the color is not changed by pressure. These lesions are superficially scaly. They do not itch. There are no purpuric spots to be found, excepting some very minute red points that can be seen only with a lens, and are of doubtful character. The newest lesions are apparently those on the arm. The smaller of these is about the size of a marrow-fat pea, very faintly brown in color. The largest lesions have a long diameter of one inch. The lesions being unlike those of any dermatosis with which the presentor was familiar, and the occurrence of one lesion with a straight border at its lower edge, suggested the possibility of malingering as the explanation of the disease.

Dr. Fordyce thought the eruption belonged to the erythema group. There had been some hæmorrhage into the patches.

Dr. Dade considered the case one of purpura.

A Case of Epithelioma of the Lip. Presented by Dr. A. D. Mewborn.

The case is presented on account of a small, warty, flat lesion on the lower lip with a question as to the diagnosis.

The patient is a native American, aged fifty-two years, and an actor by profession. He denies alcoholic or venereal history, but smokes to excess, (pipe and cigar). He has suffered for ten years from attacks of seborrhœa of the scalp and chest. On the chest at the time of first examination the lesions were those of "flannel rash" or circinate pityriasis. On both legs are a number of warty oval patches which itch intensely at times, and are of the lichen planus verrucosus type. The lesion on the lip was first noticed about four years ago and the patient has no recollection of burns or other repeated traumatism to the part affected. The lesion is about two centimeters in diameter, having a rough, warty surface and an elevated shiny edge or border. The lesion seems very superficial, no underlying induration or glandular involvement.

Drs. Sherwell and Lustgarten considered the lip lesion an epithelioma.

Dr. Allen concurred in the diagnosis of epithelioma of the lip and advised curettage and cauterizing the base. The lesions on the leg he considered to be a peculiar form of horny dermatitis.

Dr. Dade considered the lip lesion a wart.

A. D. Mewborn, *Secretary.*

REVIEW
of
DERMATOLOGY AND SYPHILIS

Under the Charge of John T. Bowen, M.D.

DISEASES OF THE SEBACEOUS AND SWEAT GLANDS.

By H. G. Klotz, M.D., New York.

Tumors of the Sweat Glands. Oscar Klauber. *Beitr. z. klin. Chir.*, XLI., 311, Jan., 1904.)

Hypertrophy and Multiple Cystadenoma of the Sweat Glands. P. Thimm. (*Archiv. f. Derm. u. Syph.*, 69, 3, 1904.)

Klauber reviews the literature on tumors of the sweat glands with special reference to cases reported before, particularly by Verneuil, Beier, Thierfelder, Petersen and others. Anatomically, three types of tumor formation may be distinguished: hypertrophy and hyperplasia (adenoma), cystic degeneration and malignant degeneration (carcinoma), although the types are not always strongly defined. Hypertrophy may appear in the shape of small, wart-like protuberances. Klauber calls attention to the divergence of opinion in regard to the conception of adenoma, which

has been defined as a new formation of glandular elements, which imitates the type of the mother substance (Remak); later the condition has been added, that the continuity of the membrana propria must not be broken (Petersen). According to Unna, adenoma imitates the structure but exceeds the architecture of the normal gland. Thimm, who also touches upon this question, agrees with Petersen, that in adenoma we must insist, that the new growth reproduces in its main characteristics the type of the gland according to its location. In adenoma of the coil glands we must be able to recognize the arrangement and shape of the glandular cells as well as the lumen of the tubules, and the membrana propria must remain intact. Thimm also refers to the different interpretations of adenoma given by Ziegler in different editions of his hand-book of pathological anatomy.

From the review of the literature Klauber draws the following conclusions: Tumors of the sweat glands, congenital or acquired, may occur at any age with a predilection for the fifth and sixth decade. They are found wherever coil glands are normally present, without any predilection. They appear oftener as solitary tumors; if primarily multiple, they are usually benign and probably always congenital, acquired multiple tumors are usually malignant. They may vary in size from a pin's head to a child's head. The clinical picture may show great variety, they always start from beneath the skin and may throughout remain covered by healthy skin or may during their growth destroy it. They are rarely painful and grow in proportion to the growth of the body; originally they are mostly round and rather flat. The epidermis commonly does not show any change, but sometimes remarkable pigmentations have been observed; later on thinning, erosions, ulcers and destruction (from cauterization) may occur. Their consistence depends on the condition of the connective tissue of the skin and on the formation of cysts within the tumor itself. The diagnosis is hardly ever possible from the clinical picture alone on account of the polymorphism and the similarity to other tumors. Adenomata are usually benign, of slow growth and without metastases; carcinomata are not less malignant than those of other organs.

The new case reported by Klauber is that of a man thirty-six years of age, who had a tumor on the scalp as far back as he could remember. It grew slowly with advancing age; originally covered by healthy skin, after some years it broke through the skin and caused a very disagreeable secretion. It was treated at one time, when he was twelve years old; in 1884 he went into a hospital, where the tumor was diagnosed as lipoma and operation decided upon. But when some pus was discovered in the tissue only cauterizations with nitrate of silver were made and the patient left the hospital without any improvement. Since then no treatment had been applied; pain and hæmorrhages were entirely absent, the secretion being the only troublesome feature. On admission to the German surgical clinic in Prague the tumor measured 7.6 centimeters, rising

about 1.75 centimeters above the normal scalp, was movable and showed an irregular surface, partly papillary, several hairs being visible between the broken down tissue; no enlarged lymphatic glands. The tumor was excised, the wound partly closed by sutures, and partly allowed to heal by granulation. Microscopically two different strata could be distinguished: superficially a rather solid and papillary one, and a deeper one: softer, and showing numerous cysts. The microscopical examination showed adenoma of the sweat glands in which the glandular body as well as the excretory ducts took part; in the former the formation of cysts prevailed, while from the ducts originated the papillary formation. In the neighborhood of the cysts tortuous strands and tubules extending over some distance to some sweat gland were frequently observed. The occurrence of smaller cysts and more or less altered coil glands near the larger cysts suggest the formation of the latter by apposition in consequence of the gradual absorption of the interstitial tissues. The final diagnosis was that of *cystadenoma papilliferum of the sweat glands.* It was probably acquired, although some cause during the stage of embryonic development may have been responsible for its origin.

Thimm's case was that of a man thirty-five years of age. Numerous flat tumors, none much larger than a pea, more or less elevated, some of a grayish, transparent appearance, others of the natural color, others again distinctly yellow, were found principally in the sternal region (about 150), with others scattered over other regions (back and neck). Without any apparent cause and without causing any trouble they had developed between the seventeenth and twenty-fifth year. The gray, transparent nodules were the smallest, most deeply situated in the skin and hardly rising above its level; they felt hard to the touch, like embedded shot. The largest and most prominent tumors were covered by normal or slightly redder, sometimes considerably thinner skin, and some seemed to be lobulated and located at various depths in the skin. Numerous large comedones were found on and between the tumors. The yellow nodules were of medium size and less numerous, located directly under the skin and more firmly attached to it.

These tumors suggested cysts of some follicles. The microscopical examination of one of the tumors showed that it was located on the border between corium and subcutaneous tissue, and was formed by a cyst, the contents of which did not reveal anything. The wall of the cyst consisted of two layers or rings, one of connective tissue and one of epithelium. The latter showed unequal thickness; in the narrower portions the cell arrangement resembled that of the upper layer of the normal epidermis somewhat above the stratum spinosum; in the more irregularly protuberant portions the arrangement was that of the normal epidermis with the exception of the basal stratum which was formed by well defined, densely aggregated, rectangular, oblong or cubical epithelial cells. The staining quality and the distinction of the cell contours diminished toward the

center. In several places remnants of an elastic membrane could be seen between the two rings. Outside of the membrane, but in a way belonging to it, epithelial strands were observed partly solid, partly revealing an indistinct lumen, apparently compressed tubules of the sweat glands. In the majority of the specimens a large number of more or less hypertrophied coil glands were conspicuous. It was remarkable that excretory ducts of these glands could nowhere be seen.

So far the microscopical findings did not furnish the absolute proof of the origin from the sweat glands, but later in a portion of the specimen adjoining the large cyst, which, by a mere accident had been envolved by the incision, an oval, clearly defined glandular tumor was discovered, to which, from the nearest large aggregation of coil glands one or perhaps several tortuous hypertrophied sweat gland tubules extended, and which itself showed dilated tubules of different degrees. Thus Thimm could follow the development of normal sweat glands into hypertrophied ones, further on into conglomerates of glands with enlarged, partly hollow, partly solid, here and there budding tubules, later on into a multilocular cystadenoma and finally into one large, unilocular epithelial cyst.

Hypertrophic Acne of the Nose and Its Surgical Treatment. W. Dubreuilh. (*Ann. de Derm. et de Syph.*, 1903, IV., 785.)

The original treatment of hypertrophic acne until recently has not received much attention. After remarks on the etiology and pathology of the disease the different surgical methods are considered. Electrolysis may have some good effects in the early stages, when the hypertrophy is entirely restricted to the sebaceous glands, but when once a new formation of connective tissue has taken place, the success cannot be prominent or permanent. At first our general treatment consisted in the removal of pedunculated tumors only, but not much was gained thereby, because these separate tumors represent only a certain part of the hypertrophy. Other surgeons have tried to reduce the tumor by partial excision of slices and union by sutures of the remaining portions, but the latter usually continue to grow and produce more hypertrophic tissue.

Ollier has proposed, under the name of decortication, the thorough removal of the hypertrophic skin over the entire surface of the nose, so that out of the entire mass a nose of normal shape and size is carved. For this purpose the actual cautery has been employed, in other cases the bistoury with subsequent cauterization to stop hæmorrhage. Other surgeons have advised partial ablation, because the scar resulting from such an extensive burning would necessarily continue to contract and finally flatten the nose. With the knife the operation can be done more quickly, but on account of the profuse bleeding the operator is always cutting blindly; one advantage would be the possibility of immediate transplantations after Thiersch. These, however, D. does not consider necessary as a rule, because the hypertrophied sebaceous glands reach so deeply

through the new formed tissue, that their deepest parts are not removed and immediately furnish islands of epidermis from which new epidermis begins to spread very rapidly over the surrounding portions. These islands greatly facilitate the process of healing and are the cause that the newly formed skin hardly shows the character of a cicatrix and differs very little from normal skin.

Dubreuilh himself prefers the thermocautery, the heat of which does not penetrate so deeply as one would imagine in tissues so rich in blood vessels; the thickness of the scar would not exceed one millimeter. A minute description of the operative proceeding is given and its application demonstrated in six cases partly illustrated by photographs taken before and after the operation.

Tumors of the Sebaceous Glands. Richard Kothe. (*Archiv f. Derm.*, 1904, LXVIII., 33, 359.)

The case of Adenoma sebaceum reported by Kothe from the clinic in Munich was that of a healthy man, thirty-three years of age. The lesions had begun to develop about twenty-six years ago and showed the usual clinical character; they were distributed, as the illustrations show, quite profusely, more or less symmetrically over the face (cheeks, nose and chin), neck and inner aspect of both thighs, less numerously over the eyelids, back of ears, upper extremities and back; on the hands and feet (only around the nails). Upon the inner surface of the lower lip, extending to the mucous membrane of the cheeks, soft palate, uvula and the gums, isolated, poppyseed-sized nodules were found, like most of the lesions on the skin, with numerous telangiectases.

Histologically the nodules from the chin and neck showed about the usual picture of adenoma sebaceum, an increase of the sebaceous glands in number and size principally preserving the type of the normal gland with but slight abnormalities; besides hypertrophy of the connective tissue probably with colloid degeneration. The lesions on the eyelids and, in a more pronounced manner, those on the thighs presented normal conditions of the sebaceous glands and changes only in the connective and elastic tissues (fibroma with colloid degeneration); the tumors on the breast and back and those originating from the nail matrix were purely fibromatous.

The rest of the article is devoted to a critical review of the literature on the subject, in particular to a polemic against the opinion of some authors (Jadassohn) of the identity of the adenoma sebaceum with certain forms of nævi. As the divergence of the authors is largely due to the conception of the term "adenoma," Kothe advises to restrict that name to tumors consisting exclusively of glandular tissue of identical structure with the normal gland tissue, in which the essential feature is the tendency to increased growth, while the secretive action is diminished. Finally he reaches the following conclusions:

The multiple miliary symmetrical sebaceous tumors of the face (type

Pringle) must not be identified with the systematized sebaceous nævi (Jadassohn); probably even etiologically they do not belong to the nævus group, and have to be considered as real adenomata; the case reported belongs to that class (*Adenoma sebaceum disseminatum.*) Adenoma of the sebaceous glands occurs in another, clinically different, form as more voluminous, solitary, non-symmetrical tumors; while mostly found on the scalp and face, they are not restricted to these localities. (*Adenoma sebaceum circumscriptum.*)

Kothe's case proves that the disseminated form is not restricted to the face.

The microscopical picture is identical in both these types.

Besides the true adenomata in the same clinical forms there occur new growths, composed of epithelial masses which resemble sebaceous glands in their outward appearance, and probably are the result of the proliferation of the marginal epithelium of the acini (as well as of the epithelium of the sebaceous and hair follicles) upon the basis of an adenoma (epithelioma or adeno-epithelioma). Epithelial tumors, which clinically conform to the "Pringle" type commonly are designated as "Epithelioma sebaceum disseminatum," or as "Epithelioma adenoides cysticum," and the others as "Epithelioma sebaceum circumscriptum."

In both these forms of epithelioma a stage of transition from adenoma to adenocarcinoma is probably represented.

DISEASES OF THE HAIR AND NAILS.

By H. G. Anthony, M.D., Chicago.

The Growth of Hair in the Axilla and Congenital Defect of the Thoracic Muscles. Moritz Schein. (*Arch. f. Derm. u. Syph.*, Vol. 68, p. 323.)

The author enunciates as a general law the statement that the growth of hair is inversely proportional to the surface growth of the skin. Comprehension of this law makes it easy to understand the development of hair in the axillary space.

The muscles which bound the axilla develop at puberty, stretch the skin covering them and increase its surface growth, while the skin of the axilla itself having no muscle as a base is not subject to the same surface growth, hence more of its nutrition goes to nourish and to develop the lanugo hairs. This explains why the axillary hair grows earlier than the hairs of the extremities and why hair is present in the axilla in cases where it is not present on the extensor surfaces of the extremities. Axillary hair is not present in children because of a lack of muscular development and for the same reason is less marked in women than in men.

If it is true that the growth of hair in the axilla is dependent on muscular development at the time of puberty, then it necessarily follows that

where the pectoral muscles are congenitally absent there will be no hair growth and this was found to be correct in a case which he herewith reports, in a case reported by Lengsfelder and also in all of the one hundred cases of defect of the pectoral muscles which are now on record in which any mention is made of the hair growth.

The hairy growth of the breast is not subject to the same law as that of the axilla, usually muscular defect is accompanied by decrease in hair growth but not always. Where there is a congenital defect of the pectoral muscles there is usually an abnormal growth of hair over the inner side of the arm due to lack of muscular development.

Anomalies of the nervous system do not affect hair growth and animal experiments are cited to show that it is the nutrition of the skin and not nerve influence which causes hair growth.

In a case of congenital defect of the muscles of the calf of the leg there was a hypertrophy of hair over the affected muscles. Lack of muscular development is not the only cause of imperfect hair growth; in one case there was perfect muscular development and no axillary hair because of imperfect development of the entire lanugo hair system of the body which approached the female habitus.

Trichorrexis Nodosa. Sabouraud. (*Ann. de Derm. et Syph.*, 1903, p. 947.)

A few months ago (*Ann. de Derm. et Syph.*, 1902, p. 1139) the author reported a case in which a patient suffering from trichorrexis nodosa of the beard had contaminated three hair brushes in succession.

The badger hair of the brush showed the typical nodes and partial fractures of the disease. By ordinary methods of bacteriological examination no micro-organisms could be found in either the hairs of the beard or of the brush. He therefore concluded that there was sufficient clinical evidence to assume that the disease was due to a special unknown micro-organism which infects both live and dead hair.

He now submits the final report of his investigations of the case. There were three possible sources of contagion to be investigated, the beard of the patient, the brush, and the soap used in lathering the beard, He began with the soap. Assuring himself that his own beard was free from the disease, he lathered his beard twice daily for a considerable length of time, using the same make of soap as that which his patient had employed.

In four weeks the hair of his beard showed hundreds of typical nodes and fractures, and after two months the application of lather was discontinued and the beard cut a few times when it was found to have resumed its normal appearance. Studying the histories of his cases he became convinced that this method of production could be invoked to explain many but not all cases. He found that friction and the lather of any kind of soap would produce the condition in susceptible persons.

Brocq examined his beard and pronounced it normal; he then reproduced the condition in two weeks.

Koilonychia and Platyonychia. Ludwig Waelsch. (*Archiv. f. Derm. u. Syph.*, Vol. 67, p. 250.)

Koilonychia is a term employed by Heller to designate flat nails with central depressions which first became known as spoon-nails through an illustration in Crocker's atlas.

In addition to flatness and concave form, the nails are thin and more flexible than is normal, and the surface is not smooth but ridged. The free border tends to grow inward and splits easily into the quick, forming painful fissures. The color of the nail is whitish in the hollow and dirty gray on the borders from particles of dirt.

The cases heretofore observed have been of two kinds, those in which the bed of the nail was diseased and those in which it was not diseased, both forms occurring in those whose occupation requires them to have their hands constantly in water.

Up to this time it has been emphasized that heredity plays no part in the production of this pathological condition of the nails and the special importance of Waelsch's article is that he shows that this is not correct.

These are the first cases to be reported due to heredity. The series consists of six cases occurring in three succeeding generations of a family. All toenails and fingernails were affected in some but not in all cases. The patients found it necessary to keep the nails cut as short as possible to prevent tearing them.

Monilethrix. Hallopeau and Lebrel. (*Ann. de Derm. et Syph.*, 1903, p. 824.)

The authors observed the father and son of a family which has already been reported and they find that all hairs of the body are affected, lanugo as well as long and bristly hairs. The hairs of the head break off short; those which are least affected attain a length of from three to four centimeters and appear to be healthy, but on microscopical examination the moniliform arrangement is seen to be present. Both patients have keratosis pilaris, a condition which is often associated with monilethrix, as Brocq pointed out, but the authors do not believe that it is the ordinary keratosis pilaris, which is a form of ichthyosis, but a special variety. They state that a comparative microscopical study might decide this question, but fail to make it, and they base their opinion entirely on the clinical facts: that there is no keratosis to be seen about the hairs and that on picking out keratotic plugs, balls of hairs are sometimes found in them; in one ball seven hairs were found.

It is possible that the keratotic plugs are due to inflammatory changes resulting from the retention of hairs. In the common form of keratosis

pilaris retention of hairs in the hair follicles also occurs but the hair is not abnormally formed as in monilethrix. It has long been thought by some that each segment of affected hair was formed every twenty-four hours. The authors observed that the constriction formed during the day and the node at night. They also tried to determine whether the constriction was not an exaggeration of a normal phenomenon.

BOOK REVIEWS.

Cours de Dermatologie Exotique. E. Jeanselme. (Paris, 1904. *Masson et Cie.,* 120 Boulevard St. Germain.)

This volume consists of a series of twenty-two lectures delivered to the students of the Institute of Colonial Medicine in Paris. The author has not attempted to cover the entire field, quite properly. The volume opens with a long essay on lepra, occupying more space than is given to any other three subjects, but justified in view of its importance. While he is fully alive to the diagnostic importance of Hansen's bacilli in the nasal secretion, the author is far from accepting the theory that the nose is the organ by which the organisms gain entrance to the economy, even in a majority of cases. He thinks the genitalia and the skin offer as easy access. There is of course no difference between lepra and syphilis of the tropics and of our own clime, except that the latter is apt to become precocious and malignant, in the skin pustulo-ulcerative. In its treatment, for climatic reasons, mercury only should be administered hypodermatically in the form of soluble salts.

Yaws is next. It seems that the experiments of Paulet and Charlouis have demonstrated its auto- and hetero-inoculability and so conclusively prove its non-identity with syphilis. The fact that it is amenable to antiluetic treatment is not surprising. Many granulomas besides syphilis are.

The verruga of Peru is likewise a clinical entity with a definite, though variable course. It is neither a papilloma nor a granuloma; the lesion is composed of a spongy, areolar tissue traversed by innumerable blood vessels and lymphatics which gives it the appearance of a cavernous tumor. Although the author reviews the literature bearing on the point and has had an opportunity of examining the tissues from a case of Oriental boil, he makes no mention of any bodies resembling those found more recently by Wright, and classed by him among protozoa.

After phagedenic ulcer of warm countries, of which there are several varieties, one of them, ulcerating granuloma of the pudenda not being limited to the tropics, the author turns to the dermatomycoses. Besides those with which we are familiar and which take on exaggerated forms due to heat and moisture, he gives chapters to tokelau or tinea imbricata, caraté, and Madura foot. Crawcraw, filariasis, elephantiasis Arabum are the chief affections due to animal parasites considered. Particular attention is called to the varieties of filariasis and the great difficulty in discovering the nocturnal nematode in elephantiasis. Sunburn and miliaria, climatic diseases, are properly part of the treatise, but it is difficult to discover the reason for inclusion of albinism, cheloid, or even ainhum which we have rarely in natives of this country and which is like the Hebrew disease, a dystrophy following obliterating endarteritis. The last chapter gives careful directions for pursuing histo-bacteriological research on tropical diseases.

The treatise is elementary in a way but since it is a beginning, it is perhaps well that it should be so. It is well illustrated with photographs of both clinical and pathological conditions and maps which are necessary to a clear conception of the spread of the individual diseases. J. C. J.

THE JOURNAL OF
CUTANEOUS DISEASES
INCLUDING SYPHILIS

VOL. XXII. SEPTEMBER, 1904. No. 9.

AFFECTIONS OF THE MUCOUS MEMBRANES IN THEIR RELATION TO SKIN DISEASES.

By JOHN A. FORDYCE, M.D., New York City.

Professor of Dermatology and Syphilology in the University of Bellevue Hospital Medical College.

Read before the twenty-eighth annual meeting of the American Dermatological Association, Niagara Falls, June 2 and 3, 1904.

OUR knowledge of mucous membrane affections which are related to skin diseases, aside from certain observations on the mucous membrane of the urethra and vagina, has been chiefly obtained from a study of the lesions which are met with in the mouth, nose and upper air passages. Clinical observation confirmed by autopsies in certain cases has taught us that the mucous membrane of the gastro-intestinal canal as well as that of the deeper air passages may be implicated, at the same time, before, or after the cutaneous affection.

Because of their abundant vessel and nerve supply the mucous surfaces are prone to first reflect the action of the poison of the acute exanthemata or of other toxic agents in the general blood stream which act on the neuro-vascular apparatus or the vessels' walls. Furthermore, on account of anatomical and physiological differences the clinical course and symptomatology of mucous membrane affections may differ in a marked degree from similar skin eruptions. Organs may be disturbed which are closely related to the life of the individual; general toxæmia may result through absorption from infective foci or from broken down infiltrations. In short, it may be asserted that the succulence of mucous membranes, with their rich blood and lymph supply render them susceptible to a large number of infective agents, with greater liability to constitutional disturbance than when the skin

is in like manner the seat of the trouble. This is notably true of tuberculosis, which in its usual form on the skin seldom gives rise to a general infection, but is readily disseminated from mucous membrane or visceral foci.

As regards the diagnosis of mucous membrane lesions in general the usual rules which apply to purely cutaneous ones often fail us. There is less color contrast on account of the more translucent nature of the epidermic covering; vesicles, bullæ and pustules do not long exist as such; papular lesions are less sharply defined and more easily eroded; infiltrations readily ulcerate and become infected, and squamous types undergo modification by reason of the moisture of the epithelial cells.

The marked difference in the appearance of the various eruptions on the skin, which often enables us to make a diagnosis at a glance, are not so defined on mucous surfaces. We may have to confirm our belief in the existence of a certain disease of these structures by the coincidence of the skin eruption or by a process of exclusion. Few would care to diagnose lichen planus or lupus erythematosus of the mouth independent of the existence of the suspected disease on the skin. As we so often look to the lesions in the mouth to confirm our belief of the existence of syphilis, it is well to have in mind the possibilities in differential diagnosis. In the case of lichen planus, the skin, mouth and genital organs may be simultaneously involved and readily mislead even an observer of considerable experience.

Anatomy. A brief reference to the origin and structure of the mucous membranes with which we, as dermatologists, are more immediately concerned, may render somewhat clearer a proper comprehension of the diseases peculiar to such tissues.

The mucous lining of the oral and nasal cavities and the conjunctiva are developed from the ectoderm and are therefore not true mucous membranes, but resemble in structure the skin rather than the true mucosa of the deeper digestive tract which takes its origin from the entoderm.

The diseases of the oral and nasal cavities are, therefore, logically related to those of the skin, because of the common embryological origin of their respective tissues. The outer layer of the epidermic covering of the mouth, which consists of stratified squamous cells and is continuous with that of the skin and pharynx, is kept constantly moist by the mucous and salivary secretions. The cells, unlike the stratified horny layer of the skin exposed to the drying influence of the atmos-

phere, do not lose their nuclei as the surface is approached. On the lips where the skin passes into mucous membrane the epidermis becomes greatly thickened while the connective tissue grows thinner. The hair follicles disappear, but the sebaceous glands persist near the angle of the mouth and in the upper lip. They are also occasionally found in the oral cavity and now and then are so numerous over the lips as to constitute a positive deformity. Krakow (Die Talgdrüsen der Wangenschleimhaut; Inaug. Diss. Königsberg, 1901; *Arch. f. Derm. u. Syph.*, 1901, Bd. LXIX., p. 233), in two hundred autopsies performed on individuals from the ages of three to eighty-three years, found sebaceous glands in the mucous membrane of the cheek in thirty per cent. of the cases. Only about eight per cent. of children showed them. They developed in the majority of individuals about the age of puberty, and in this respect coincided with the development of the same glands in the lip. In structure they differed in no way from those in the skin.

The affection described by the writer in 1896 under the title of "A Peculiar Affection of the Mucous Membrane of the Lips and Oral Cavity," was at that time, erroneously believed to be due to a degenerative change in the epithelium of the affected part. D. W. Montgomery, and Hay, and others, have since clearly proved that the presence of sebaceous glands in these localities produces the clinical appearance described. Dr. J. M. H. Macleod (*The Brit. Jour. of Derm.*, 1904, Vol. XVI., p. 147) has recently described a similar case but has evidently overlooked the investigations connecting the clinical picture with the presence of sebaceous glands, as has also Crocker in the last edition of his work on Diseases of the Skin.

Sebaceous adenomata of the mouth, in connection with the affection on the face, have been described by Buschke (*Monatsh. f. prak. Derm.*, 1904, Bd. 38, p. 230) and others.

The mucous membrane over the cheeks adheres directly to the buccinator muscle and covers small papillæ. It is dense over the gums, with numerous papillæ and closely attached to the periosteum through the medium of the submucous tissue. The soft palate, uvula and fauces are covered by a loose structure containing numerous glands and much adenoid tissue. Mucous glands are also present through the mouth, but are rarely found on the gums or hard palate. The tongue is chiefly a muscular organ with the fibers arranged in vertical, horizontal and transverse planes divided in halves by a transverse fibrous septum. Over its sides and inferior surface the mucous membrane is thin, smooth, with small papillæ and mucous glands. The dorsum

has a more complicated structure with a thicker mucous membrane and numerous special papillæ and taste buds.

Syphilis, cancer, lichen planus, lupus erythematosus, and other affections are modified in their clinical features by the structural peculiarities of this organ. The root of the tongue is further complicated by the presence of taste buds, which may be compared with the tactile corpuscles of the skin and by a rich adenoid tissue through which absorption of infectious agents may readily take place.

The tonsils are covered on their oral surfaces by epithelium resting directly on adenoid tissue; the upper respiratory part of the pharynx by stratified ciliated epithelium; the part below the level of the soft palate by stratified squamous cells like those covering the oral cavity. The œsophagus has a like covering of stratified squamous cells, but when the stomach is reached the cells become columnar and the entire structure of the mucous membrane changes to meet the complicated functions of digestion and absorption.

The implication of the mucous membranes in the acute exanthemata is almost invariable, and the rash occurring here as it sometimes does in measles and scarlatina before it appears on the skin, may materially aid us in making an early diagnosis.

The significance of the primary macules on the buccal and labial mucous membrane has been prominently emphasized by Koplik and other writers.

The chronic infective granulomata are also, at some time in their course, found on the visible mucous membranes. There is a growing belief that the bacillus of lepra may find its first lodging place in the mucosa of the nasal passages on the upper respiratory tract. The characteristic microörganisms can usually be found in the nasal secretion of lepers, especially after the production of a coryza by the administration of iodide of potassium.

Syphilis, tuberculosis, glanders, actinomycosis and other members of this group of infections may involve the mucous membrane primarily, as a result of a general infection, or by direct extension from the skin lesions.

Certain general intoxications of the most diverse origin, comprising exudative erythema, urticaria, purpura and drug rashes may occasionally be seen in the mouth or give rise to gastro-intestinal or visceral complications of a serious nature.

The mucous membrane may accidentally be infected in the course of some of the pyogenetic affections by direct extension from the skin, through the medium of an infected finger, or in other ways.

It has been asserted that the skin and mucous membranes may be alternately invaded by catarrhal processes; that the rapid disappearance of an eczema has been followed by a bronchitis or asthma which in turn subsides and permits of a recrudescence of the eczema.

There are certain clinical grounds for the foregoing assumption in that the activity of a pathological process in one organ is often followed by a quiescent state of a similar process in another part of the body.

Lupus erythematosus. Until quite recently lupus erythematosus of the mucous membranes was thought to be one of the rarer manifestations of the affection aside from the direct involvement of the lips from the process on the face. On account of its freedom from subjective symptoms, the consequent ignorance of the patient of its presence, the fact that the physician, as a rule, does not look for it, tend to make its recognition difficult and to minimize the percentage of cases in which these structures are involved. Trautman (*Zur Differentialdiagnose von Dermatosen und Lues bei den Schleimhauterkrankungen der Mundhöhle und Oberen Luftwage*, 1903) has analyzed thirty cases collected from literature and found in them an involvement of the lips in forty-three per cent., the mucous membrane of the cheeks in forty per cent., the palate in thirty-three per cent., the tongue, tonsils, pharynx, gums, nasal, conjunctival and laryngeal mucous membrane in a much smaller percentage of the cases.

In seventeen out of the thirty cases the mucous membrane and cutaneous lesions coexisted while in only six did the changes in the mouth antedate those on the skin. Three instances were found of the disease on the mucous membrane without any cutaneous manifestation whatsoever. The clinical picture in the mouth is so varied that it is difficult to properly emphasize the salient features. The affected surface may be of a vivid red color, with slightly depressed center, and here and there pearly-gray spots showing beginning atrophy and change in the superficial epithelium. When the lips become involved by direct extension from the face they may first be swollen, purplish-red colored and eroded; later, dry, scaly, and finally showing an atrophic gray-white center surrounded by a hyperæmic zone much like the typical discord patches on the face.

Dubreuilh describes the early mouth lesions as somewhat infiltrated with rather indefinite outlines, slightly eroded surface, and of a blue-red color. The later appearance of gray or white lines throughout the patch marks the beginning of the characteristic atrophy. Eventually the red color of the affected area disappears and the infiltration

with its accompanying œdema is replaced by more or less scar or atrophic tissue which undergoes no further change.

Malcolm Morris (*British Journal of Dermatology*, 1903, Vol. XV., p. 410) exhibited before the Dermatological Society of London a patient with chronic relapsing lupus erythematosus. He had in addition to spots on his face, scalp and hands, a severe affection of the mouth and tongue. The tongue was of a vivid red color with a smooth and shining surface as if denuded of its outer coating of epithelium. It was only by associating the condition of the tongue with the spread of the eruption on other parts that a diagnosis was possible.

Without the confirmation of our diagnosis by the coexisting skin eruption lupus erythematosus of the mucous membranes could easily be mistaken for certain phases of leucokeratosis, the opalescent plaques or scars left by early specific lesions, late superficial infiltrations corresponding to papulo-squamous syphilides of the skin, lichen planus and other conditions. Smooth red spots on the tongue without infiltration or evident atrophy may present a striking resemblance to exfoliatio areata linguae. The form and situation of the latter condition, however, change so rapidly that a mistaken diagnosis should not occur. On the other hand a recognition of the prominent features of lupus erythematosus of the mucous membranes may help us at times in a diagnosis of an obscure skin eruption.

Within the past month a patient consulted the writer for a persistent symmetrical eruption on the face which was chiefly erythematous in character with outlying smooth papules somewhat resembling lichen planus, and a few pea-sized atrophic spots. She stated that one year before her hands and feet became swollen and red and that the skin exfoliated in large sheets. At the same time her hair fell out and she had fever and much constitutional disturbance. With the exception of the small atrophic spots there was nothing in the patchy redness to suggest lupus erythematosus. An inspection of the mouth showed on the inner side of the cheeks along the line of the closed teeth gray-white discoloration of the mucous membrane with here and there superficial erosions, and at the margin a deeper red zone due to dilated vessels and infiltration. The doubt which was at first felt regarding the nature of the eruption on the face was dispelled by the appearance of the oral cavity.

Wilfred B. Warde (*British Journal of Dermatology*, 1902, Vol. XIV., pp. 332 and 380) in investigating the lesions of mucous membranes met with in patients with lupus erythematosus found that ten out of fifteen cases had hypertrophic or atrophic rhinitis. As a re-

sult of the coincidence of the two conditions and from the similarity of the morbid processes he was led to draw certain inferences as to the nature of lupus erythematosus and the accompanying nasal condition. From these and other observations he believed that the affection was not so much a distinct pathological entity as an ordinary inflammation of the skin and mucous membranes dependent on vascular weakness, with resulting local œdema leading to atrophy.

In predisposed individuals exposure to a variety of physical or toxic agents either locally or in the general circulation might be sufficient to determine it.

Warde's theory as to the relationship of lupus erythematosus to hypertrophic and atrophic rhinitis is open to the serious criticism that the former is comparatively rare while the latter condition is frequently met with. Furthermore, the clinical pictures of the two conditions present more points of contrast than similarity.

The disseminated type of lupus erythematosus is sometimes the local manifestation of a general toxæmia attended with high fever, a parenchymatous nephritis and other visceral changes, while hypertrophic rhinitis is generally the result of a local overgrowth of adenoid tissue. The histological changes in lupus erythematosus are fairly characteristic, dependent on a local inflammation with œdema and terminating more or less rapidly in destruction of the collagenous and elastic tissues of the upper corium. In hypertrophic rhinitis the process is usually much slower in its development and it lacks the definite limitations of the former affection. A more accurate comparison of the pathological changes in the two conditions can only be made by further histological study which is rendered difficult by lack of suitable material. Erythema multiforme and the disseminated type of lupus erythematosus have certain symptoms in common in that they are both at times the expression of a serious toxæmia with visceral and mucous membrane lesions which may give rise to a fatal result. The relationship of the two affections has recently been emphasized by Galloway, Whitfield and others in a very instructive manner.

Erythema multiforme may occasionally terminate in atrophy which bears a close resemblance to that of lupus erythematosus, thus bearing out Galloway's opinion that the clinical expression of the affections is due rather to the quantity than the quality of the poison and the underlying state of the implicated tissues.

Lichen Planus. As stated by Hyde (Journal of Cutaneous Diseases, 1903, Vol. XXI., p. 105), our knowledge of the exact relation between lichen planus and leucokeratosis of mucous surfaces is

somewhat uncertain. The text books, monographs and reports of individual cases give a rather confused idea of the clinical manifestations of lichen planus in the mouth and on the genital organs. The lack of uniformity in the descriptions is probably due to the stage of development of the affection and to the diverse grouping of the individual elements making up the patch. The initial papule may appear as a white granule or dot the size of a pin's head or smaller, hemispherical, conical or flattened, hard to the touch and arising from the unaltered mucous surface. On the tongue the papules may occur singly or grouped, with most of the characteristics of those of the skin. The color of the tongue papule is usually described as dull white without the mother-of-pearl hue of leucokeratosis. Its most typical form is met with on the under surface of the organ.

Plaques of various sizes and outlines arise on the mucous surface of the mouth by the confluence of the individual papules. We may have oval, round or ring-shaped lesions with white depressions between the initial elements extending in parallel lines to the commissures of the mouth: or the white streaks may converge to a common center and produce stellate lesions.

The surface of the patch is usually rough and irregular to the touch, lacking the smooth impression conveyed by the normal membrane.

On the tongue the plaques affect by preference the free borders in a symmetrical manner. They have less of the mother-of-pearl hue than when the cheeks are implicated and convey a smooth impression to the finger.

Lichen planus of mucous surfaces is persistent, lasting at times for several years. It may disappear spontaneously and relapse. The relapses occur without the individual papules in the form of white lines arranged in a net-work-like manner.[1]

In addition to its situation in mouth and tongue, lichen planus has been observed in the larynx, the urethral and vaginal mucous membranes, and is rather frequently seen on the glans penis as a papular or circinate eruption. Lesions in the mouth and on the penis may antedate the outbreak of the skin eruption by several months, thus increasing the difficulties which are sometimes encountered in

[1] The writer acknowledges his indebtedness to Trautman's excellent work (*loc. cit.*) for the foregoing brief outline of the symptomatology of lichen of the oral cavity which was obtained from a critical analysis of the scattered cases occurring in literature.

differentiating the affection from syphilis. The grouping and distribution of lichen planus of the skin with its pigment changes may closely simulate a syphilide and if at the same time radiating, or parallel, gray or white streaks are seen inside the cheeks with palmar and plantar papules and swelling of the inguinal or cervical lymph nodes the diagnostic difficulties increase. The observer may be still further confused by the absence of itching in lichen planus and its favorable response to mercurial treatment. Consideration in the differential diagnosis of lichen planus and syphilis should be given to the several phases of mucous patches, scars or epithelial changes after the involution of specific lesions as well as to the specific and non-specific leucoplasias.

Leucokeratosis in individuals who are not smokers and from whom a syphilitic history cannot be elicited, should suggest the probability of lichen planus, and lead the observer to look for further evidence of that affection. In this connection it is well to have in mind the possibility of the occurrence on mucous surfaces of the affection described by Mibelli as Porokeratosis and by Ducrey and Respighi as *Hyperkératose figurée.*

Lesions having circinate and polycyclic outlines with elevated margins and opalescent centers have been met with on the arch of the palate, the lips and the under surface of the tongue, which had a strong resemblance to the annular type of lichen planus. The chief histological difference in the two affections is that in lichen planus the papule is caused by a subepithelial infiltration while in porokeratosis the epithelium is chiefly or alone involved.

Lichenization of the Skin of the Leg with Leucokeratosis of the mouth.—A patient presented himself during the past winter at the writer's clinic with a chronic pruritic affection of the lower third of the leg. The patch was half as large as the hand and made up of numerous closely aggregated papules of a dull red color, and deepening of the normal lines of the skin, with some resemblance to a lichen verrucosus. The outlying papules were dome-shaped and not typical of those seen in lichen planus. The condition had existed twenty years, had slowly spread, and was unattended with any other skin lesion excepting the outlying papules before mentioned.

On examination of the mouth for confirmatory evidence of lichen planus the mucous membrane of the cheek along the line of the teeth was found to be affected with broad bands of grayish-white alteration of the surface epithelium. It caused no symptoms and could not be

distinguished from an ordinary leucokeratosis of a mild grade as no individual papules or imbedded granules could be found. The patient was a lip-biter and showed numerous erosions and thickened epithelium in places but with no opaque patches on the irritated parts. A biopsy was made from both the leg and mouth lesions from which the photomicrographs (Plate 1, Figs. 1 and 2) were made. Both showed a pronounced hyperkeratosis with hypertrophy of all the epithelial layers. The leg lesion showed a chronic inflammatory process in the derma extending for some depth along the small vessels, the new cells having developed into young connective tissue similar to that met with in the chronic infective granulomata.

In the mouth the changes were chiefly in the epithelium, the prickle cell hypertrophy being more pronounced than in the leg. There was little or no evidence of inflammation in the subepithelial tissue but in other respects the two conditions presented a marked similarity.

The case is presented as a contribution which may throw some light on the obscure group of cases of leucokeratosis which cannot be explained by the effect of syphilis or tobacco and which differ in their manifestations from lichen planus.

The writer has also observed the occurrence of leucokeratosis of the tongue and other parts of the mouth with seborrhœic dermatitis of the scalp, arms and legs. In this case, however, the patient had had syphilis and was a smoker, so the relation between the conditions was by no means clear.

Morrow (*Med. News*, 1896, XLIX., p. 295) has reported the coincidence of leucokeratosis of the tongue with keratosis of the skin and seborrhœic dermatitis.

Colleville (*Gaz. Hedb. de Med.*, 1898, N. S., III., p. 277) has observed a similar connection between the two conditions.

Hutchinson (quoted by Butlin, *Diseases of the Tongue*) has described leucokeratoses of the tongue in connection with an exfoliative dermatitis of the skin.

Psoriasis of the Skin and Mucous Surfaces. The possibility of the occurrence of a true psoriasis on mucous surfaces is denied by the majority of modern dermatologists, although there are a number of instances on record in which white or gray patches in the mouth have occurred with a generalized psoriasis of the skin. The histological relationship of the affections has not been investigated with the exception of a case recently reported by Oppenheim (*Monatshcft. f. Prak.*

Derm., 1903, Bd. 37, p. 490). In this case several round or oval, sharply defined, blue-white elevated patches, were observed on the mucous surface of the cheek and the hard palate, which differed essentially in their appearance from a true leucokeratosis, together with a general surface psoriasis. The histological changes in a piece of excised tissue showed the same general features as in the skin affection, *i.e.*, a parakeratosis with epithelial hypertrophy and inflammatory reaction in the papillary body.

The author emphasized the absence of eleidin and keratohyaline granules, which were, he stated, constantly found in leucokeratosis, as an important feature in establishing his diagnosis of a true psoriasis.

No sclerotic change was found in the connective tissue or the vessels of the mucosa as had been described by Vidal, Schwimmer, Darier and others in leucokeratosis.

For the histological reasons given, as well as from the clinical appearance of the case, Oppenheim believed he had established the fact that a true psoriasis might exist on a mucous surface. Without denying the probability that in this case the skin and mouth conditions were due to the same affection, psoriasis, it would seem that the author is too dogmatic in stating that the absence of eleidin in the cells of the epidermis and the sclerotic change in the mucosa exclude positively a leucokeratosis.

In a number of cases of unmistakable leucokeratosis of the mouth which the writer had an opportunity to examine microscopically, neither the presence of eleidin droplets, the granular layer of cells nor sclerotic changes in the sub-epithelial mucosa were constant features.

In Plate 2, Fig. 3, made from a leucokeratosis of the tongue which had been followed by carcinoma of the organ, (Plate 2, Fig. 4,) we have a well marked parakeratosis with preservation of the cell nuclei to the surface, proliferation of the interpapillary processes, with a cell exudation in the papillary body and no sclerotic change in the connective tissue.

The histological features of the sections correspond closely with Oppenheim's description and invalidate, in the writer's opinion, his assertion that a diagnosis of psoriasis of the mucous membrane has been positively established in the case in question. The direct extension of psoriasis of the skin to the mucous surface of the lips and conjunctiva has been shown by the cases reported by Kuznitzky (*Arch. f. Dermat.*, 1897, Bd. 38, p. 405), Kreibich (*Wiener Dermat. Ges.*, 1900, 28, XI.), and Sack (*Internat. Atlas of Rare Skin Diseases*,

IX). These cases, with one of balano-posthitis psoriatica reported by Neilsen, establish the fact that psoriasis may directly invade the mucous membrane from the skin but do not throw any light on the occurrence of independent psoriatic plaques on these surfaces.

It can be stated with considerable assurance that psoriasis of mucous membranes, while possible, is met with as an extreme rarity considering the large number of cases of the affection which come under our observation.

Precancerous Keratoses of the Mucous Surfaces. Leucokeratosis of the mouth chiefly concerns us in its relation to cancer, aside from the interest which is attached to its differential diagnosis from lichen planus, lupus erythematosus and other conditions which bring about similar changes in the surface epithelium. Butlin (*Diseases of the Tongue*, 2d Edition, 1900) states that continued observation has led him to believe that its importance as a precancerous condition has been underestimated rather than exaggerated. It may exceptionally continue to slowly spread for forty or fifty years, however, before malignant change takes place.

It varies from a slight thickening and bluish-white opacity of the superficial layers of cells to circumscribed or diffuse hyperkeratoses which lead by pressure to atrophy of the papillary layer. Sooner or later warty outgrowths appear on the affected surface, which point with a fair degree of certainty to a beginning malignant growth. (Plate 3, Fig. 5).

Attacks of superadded inflammation may give rise to some pain or soreness of the tongue and to a great increase in the amount of infiltration beneath the epidermis. In some cases examined by the writer there was found little or no inflammatory reaction in the tissues beneath the epidermis, while in others a dense mass of lymphoid and plasma cells was observed. Sclerotic thickening of the connective tissue of the mucosa may be limited to the papillary body or extend to the muscular tissue of the tongue, giving rise to hypertrophy and fissuring of the organ. In addition to the irritation of tobacco smoke and syphilis as etiological factors, there is, in Butlin's opinion, some inherent vulnerability of the tissues or unknown cause which predisposes them to the change in question. In no other way can we explain the exceptional cases where neither syphilis nor tobacco can be invoked. The genito-urinary tract in the male and the vulva and vagina are at times affected in a similar manner and here the causes which are operative in the mouth are absent. The continuous irri-

tation of the mouth by tobacco smoke is probably the most constant and important factor in bringing on the condition. It is analogous to the hyperkeratosis of the skin caused by paraffin oil, or tar, and to the epithelial changes in the skin of the scrotum of chimney sweeps caused by soot. In all of these conditions combustion products are probably the active agents in stimulating the epithelium or in interfering with the normal and regular changes which take place in the cell nuclei.

On the lip a similar keratosis or hyaline degeneration of the surface epithelium, accompanied or followed by an acanthosis, precedes the development of cancer. These changes are shown in the photomicrograph (Plate 3, Fig 6).

While the superficial cells are undergoing degeneration the deeper cells of the spinous layer are actively growing. Cancer of the lip, tongue and interior of the mouth is almost without exception of the squamous celled type, producing the characteristic pearl bodies (Plate 2, Fig. 4) and invading the deep tissues. The formation of hyaline or completely keratinized pearl bodies may predominate in the histological picture or, on the other hand, the hypertrophic prickle cell layer may continue to proliferate as such with little tendency to form horny tissue. The metastases in the lymph nodes have the same general features as the original tumor.

The rodent ulcer type of epithelioma which predominates on the face and originates from the basal layer of the epidermis or outer root sheath of the hair, has never in the writer's experience been found on the mucous surfaces. Butlin states that the only form of carcinoma which has been found as a primary disease of the tongue is the squamous celled variety.

The mucous surface of the cheek and the floor of the mouth may also be the primary seat of a carcinoma.

The coincidence of epithelioma of the dorsal surface of the hand which developed from a seborrhœic wart in an old woman, and epithelioma of the mucous surface of the cheek, have been noted. In the photograph (Plate 4, Fig. 7) a primary carcinoma of the cavity of the mouth with ulceration and secondary infection of the lymph nodes, produced a condition suggesting an actinomycosis. Fistulous tracts subsequently formed, discharging curdy-looking pus which still further enhanced the resemblance of the two affections.

The diagnosis was made from tissue removed from the mouth ulcer.

Lupus. Lupus vulgaris of mucous surfaces manifests itself as a

distinct clinical form of tuberculosis and is readily distinguished from acute miliary tuberculosis or tubercular ulceration. It involves the nasal or oral cavity and even the larynx by direct extension from the skin; as independent foci with coincident involvement of the skin; or as a primary affection of these surfaces.

In the mouth the growth of the lupus nodule produces papillary excrescences which gives to the affected surface the peculiar mammelated appearance that is quite characteristic.

Leloir, under the name of semi-sclerotic lupus of the tongue (*International Atlas of Rare Skin Diseases, I.*) has described a unique involvement of the dorsal surface of the organ by numerous pea-sized nodules which recalled in a striking manner the interstitial glossitis of syphilis and leprosy.

In the photograph (not reproduced) an unusual type of tuberculosis of the muco-cutaneous surfaces in a child was portrayed. When the patient was first seen the upper lip, cheek and commissure of the mouth were the seat of a large granuloma without definite features. The administration of iodides was without result. During an attack of pneumonia in the Presbyterian Hospital some months later the lesion grew smaller under boric acid compresses. A year afterwards he was presented by Dr. Bulkley before the New York Dermatological Society with a typical lupus vulgaris of the lip and cheek. The enormous infiltration had disappeared, leaving behind a flat surface with imbedded lupus nodules. In this case the inflammatory reaction in the lip and contiguous surface of the cheek was so intense that the characteristic features of the infection were obscured.

Syphilis. Trautmann's recent book on the differential diagnosis of dermatoses and syphilis of the mucous membrane of the oral cavity and upper air passages contains many valuable references to literature and is extremely suggestive in recalling the numerous affections with which syphilis may be confused.

The papules and bullous lesions of the erythema group of skin disease when they appear on the mucous surface of the tongue or mouth, can readily be mistaken for the mucous patches of syphilis. Relapsing herpes of the mouth is not infrequently the occasion of much mental worry in individuals who have had syphilis. The eruption appears as gray spots with a red periphery and with the attached remnants of the epithelial covering at the margin. In syphilis neither the so-called epithelial *collarette* nor the polycyclic outline from the union of several vesicles are seen. The burning pain

PLATE XXXIII.—To Illustrate Dr. John A. Fordyce's Article.

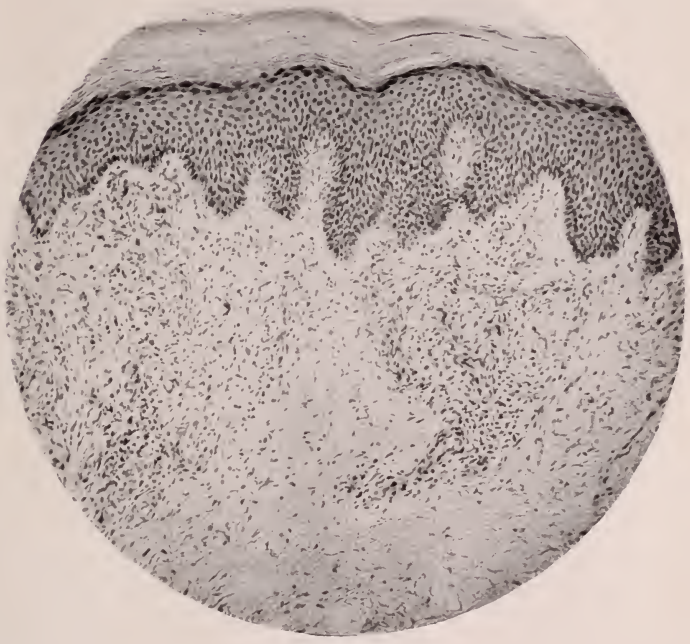

Fig. 1.

Fig. 2.

PLATE XXXIV.—To Illustrate Dr. John A. Fordyce's Article.

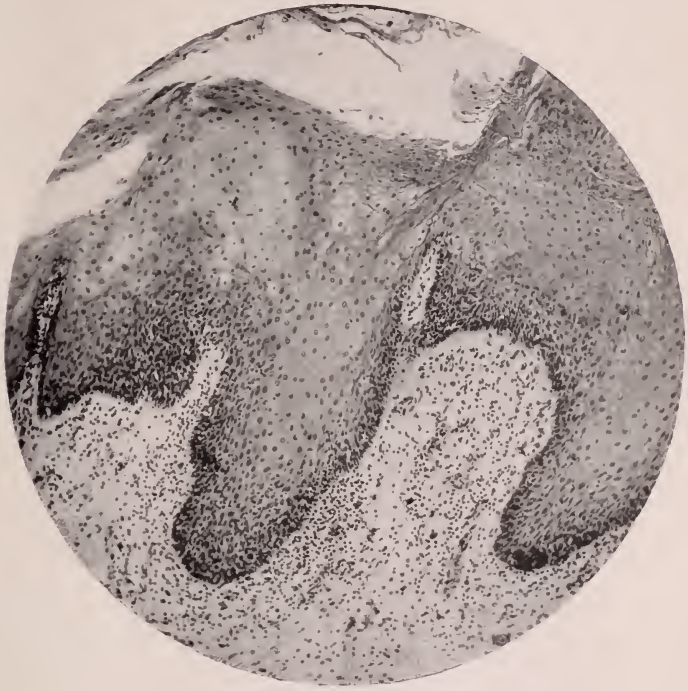

Fig. 3.

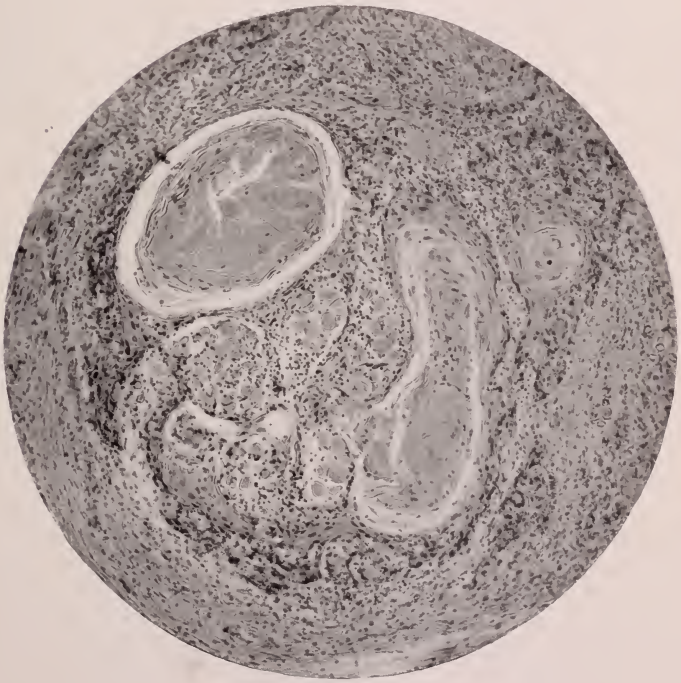

Fig. 4.

PLATE XXXV.—To Illustrate Dr. John A. Fordyce's Article.

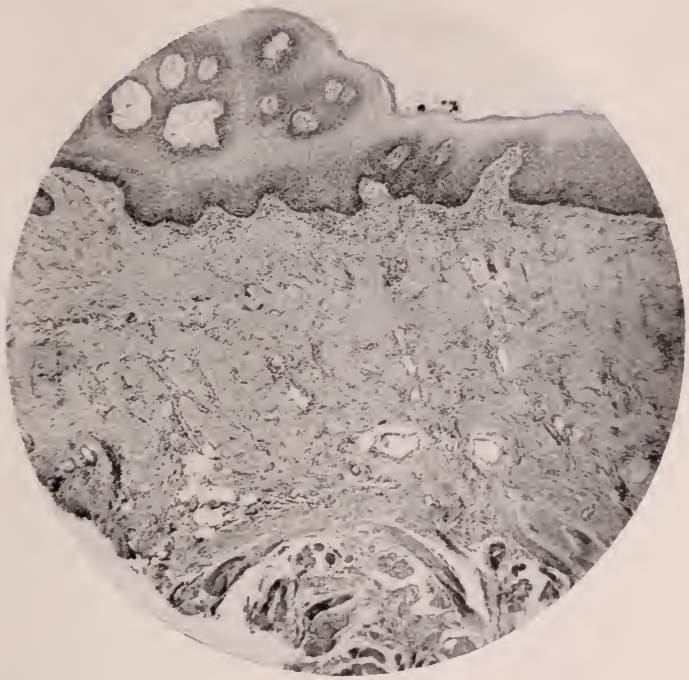

Fig. 5.

Fig. 6.

PLATE XXXVI.—To Illustrate Dr. John A. Fordyce's Article.



Fig. 7.

of the herpes with the peripheral hyperæmia and œdema, are absent in syphilis. Mercurial stomatitis may produce erosions which are with difficulty distinguished from the lesions the drug is intended to cure, and eventually can lead to such discoloration and thickening of the epithelium that the condition is easily mistaken for the scars of syphilis or leucokeratosis.

Antipyrine and other aniline derivatives have produced erosive lesions in the mouth which have been taken for specific ones. The growth of cancer from surface keratoses or from the deeper lesions resulting from syphilis may be so slow that it is not always possible to differentiate the two conditions. Numerous instances have been observed where improvement in tongue and mouth neoplasms has taken place up to a certain point, and the hope was expressed that the entire condition might be syphilitic. It was difficult to convince the patient and at times the physician that a cancer had developed from the tissue alterations caused by syphilis.

On the other hand it was not so unusual for syphilitic lesions to be mistaken for malignant growths. This was true not only of the late circumscribed gummata but also of the initial lesion in extra-genital and unusual locations.

A communication like this one which deals with so many pathological conditions must of necessity be very incomplete and fragmentary. It can at best only be suggestive and introductory to the discussion which is intended to follow it.

DESCRIPTION OF PLATES TO ILLUSTRATE DR. JOHN A. FORDYCE'S ARTICLE.

PLATE XXXIII.

Fig. 1. Lichenization of the skin of the leg in a patient with leucokeratosis of the mucous membrane of the cheek. Spencer, ½ inch. Zeiss, comp. ocular 4.

Fig. 2. Leucokeratosis of the mucous membrane of the cheek in a patient with lichenization of the leg. Spencer, ½ inch. Zeiss, comp. ocular 4.

PLATE XXXIV.

Fig. 3. Leucokeratosis of the tongue with deep carcinoma. Spencer, ½ inch. Zeiss, comp. ocular 4.

Fig. 4. Deep carcinoma of the tongue after leucokeratosis. Spencer, ½ inch. Zeiss, comp. ocular 4.

PLATE XXXV.

Fig. 5. Leucokeratosis of the tongue, with warty growth on the surface. Spencer, 1 inch. Zeiss, comp. ocular 4.

Fig. 6. Acanthosis of the lip adjacent to epithelioma of the lip. Spencer, 1 inch. Zeiss, comp. ocular 4.

PLATE XXXVI.

Fig. 7. Primary carcinoma of the mucous surface of the cheek simulating an actinomycosis.

AFFECTIONS OF THE MUCOUS MEMBRANES IN RELATION TO SKIN DISEASES.

By M. F. Engman, M.D., St. Louis.

Read before the twenty-eighth annual meeting of the American Dermatological Association, Niagara Falls, June 2 and 3, 1904.

I WILL endeavor to treat the portion of the subject allotted to me in as broad and practical a manner as possible. In discussing a subject about which so little absolute truth is known it is often difficult to refrain from speculative pathology, but in the following remarks I have been guided by the writings of others and my own clinical observations and studies.

For convenience of discussion I will divide the affections included in this paper into: (1) those diseases which affect both the mucous membrane and the skin by direct local auto-inoculation one from the other; (2) those diseases which affect both the skin and mucous membrane through general systemic involvement; by (a) the action upon the skin and mucous membranes of toxines metabolically produced in the system with or without the aid of micro-organisms or other known agents; (b) the formation of emboli of micro-organisms in the skin and mucous membranes. This division is one made purely for the convenience of the moment and is not brought forward as a classification. In the discussion of a number of diseases from any standpoint, the first unconscious effort is to arrange them into an etiological and pathological division, but as the present knowledge of the etiology of diseases of the skin is so meager, such a classification is impossible and worthless. Many of the diseases which affect both the mucous membrane and the skin shade so imperceptibly one into the other by their varieties of types and characteristics, it is ridiculous at the present time to make any dogmatic statements about their etiology or pathology. However, I believe a study of their general characters is of vast importance, and that it is through this study that a true knowledge of them will be gained.

I fully realize the vulnerability of my division of the subject and the remarks that follow, yet I place them before you as the result of some personal observations and study.

It is impossible to dwell in detail upon the various affections included in this paper or to describe the clinical appearances of but a few of them, as the time is too limited for such an attempt; therefore, much of value can only receive passing notice.

1. Diseases apparently due to micro-organisms which are con-

veyed from the mucous membranes to the skin and *vice versa*, by auto-infection.

A. Eczematoid dermatitis. The term eczematoid dermatitis is used here to avoid any discussion or misunderstanding of the disease or diseases called eczema. This affection occurs upon the skin especially upon the face, arms and scalp of children, and is the so-called impetigenous eczema, or, in some of its types, scrofulous eczema, dermatitis repens of Crocker, and certain forms of dermatitis exfoliativa. In 1902, I published some results of the study of this disease under the title of "An Infectious Form of an Eczematoid Dermatitis," and stated that I believed it a distinct entity and due to a variety of the staphylococcus. Since then my opinion has been strengthened by additional bacteriological examinations and inoculation experiments. The disease has been conveyed, experimentally, by inoculation and auto-inoculation and is always associated with a distinct history of infection, suppurative processes or catarrhal conditions of the mucous membrane of the nose, throat, ear or eye.

The initial lesion of this dermatitis is a vesicle or erythematous spot. It rapidly extends peripherally and forms variously sized eczematous plaques which by coalescing may involve a large area. In the initial vesicles and subsequently, staphylococci are found in pure culture, of a sero-tactic virulence, and it is not till later in the process that a strong leuco-tactic affinity is observed. Smears from the catarrhal mucous membranes, surprisingly, contain, in many instances, pure cultures of staphylococci, sometimes mixed with streptococci or a bacillus which is probably the pseudo-diphtheria bacillus.

Experimental inoculations of the discharge from catarrhal mucous membranes produces the eczematoid dermatitis, but inoculations from the artificial cultures of the staphylococcus are not entirely satisfactory. From long observation of this type of disease and the staphylococcus, I am led to believe that this coccus produces various types of dermatitis *according to the chemo-tactic quality of its toxines, and that in artificial media this quality is changed.*

When we have a pustular discharge from a mucous membrane the inoculated skin presents a more pustular dermatitis than that produced by a serous discharge. This can be verified by observation of the upper lip in rhinitis or about the ear in otorrhœa. In my experience it is a frequent occurrence to see an eczemaform eruption start from infection from a pustular conjunctivitis, rhinitis, otorrhœa, leucorrhœa, or various catarrhal conditions of the mucous membranes. About the lips and extending from them on to the cheeks and further

by auto-infection this condition is frequently seen after anginas, measles, scarlet fever, la grippe, and various other catarrhal conditions of the throat and pharynx. The initial infection is always upon the side upon which the individual sleeps and is produced by the infective saliva flowing over the skin of that side, or, by the habit of wetting the lips and skin with the tongue. In one of my cases, an infant, the disease began upon the cheek after a vigorous kiss by an individual infected with a severe catarrhal pharyngitis. I saw the initial spot of infection, prescribed, it was neglected and extended rapidly into a severe eczema of the cheek.

Often in these cases the buccal mucosa is reddened and the tongue coated, the patient complaining of heat and burning of the mouth. In institutions especially where children are congregated, this infection is a serious condition; it spreads rapidly from individual to individual, causing various types of catarrhs of the skin and mucous membranes of a serous and sero-purulent character. Isolation of every case, whether the skin or mucous membranes be involved, is the best procedure. The English speak of this type of disease as scrofulous eczema, and Unna calls the condition when the upper lip is œdematous from interference in the circulation in the nose, tuberculous eczema; yet, in institutions we see the healthiest children infected who subsequently present all the facies of the so-called scrofulous type—rhinitis, otorrhœa by extension from the nose, severe conjunctivitis and an eczemaform eruption upon the skin. Besnier describes an œdematous condition of the eyelids and lips from chronic eczema of the nares.

B. Bullous impetigo and, less frequently, other forms of impetigo, is often associated with mucous membrane catarrhs, and as Holt truly says, it is often difficult to make a differential diagnosis of syphilis when an infant has a rhinitis with pharyngeal involvement and bullæ upon the skin. It is far more difficult, however, when we have a dermatitis spreading beyond the diaper region with the mucous membrane complications named. Twice have I come near making this mistake, the eruption finally clearing under sulphur without internal treatment.

Luithlen calls attention to impetigo in children with septic mothers. Schamberg, in a study of skin diseases associated with summer diarhœas in children, noticed most frequently various forms of eczema and furunculosis. Many interesting types of disease occur about the nares associated with various forms of rhinitis. The most rebellious form of coccigenic sycosis is that of the upper lip associated with rhinitis.

C. In Kiesselbach's experience acute and chronic rhinitis is the most

frequent cause of eczema of the nares, and he observes that vesicles here are rare. Schmiegelow and also Moldenhauer refer to the infection of the hair follicles of the vibrissæ as a complication which is an exceedingly stubborn infection. In a chronic form of eczematoid dermatitis pustular follicular infection is the rule, due to change in chemotaxis of the coccic toxine. In such chronic cases mild attacks of erysipelas often occur, due most frequently to excoriation or fissuring and thereby secondary infection by streptococci, although the staphylococcus and pneumococcus can cause such conditions (Forssman). Vassant, in a bacteriological examination of one hundred cases of rhinitis, found streptococci fifty-eight times, and the diphtheria bacilli twenty-six times.

Boucheron affirms that there is a streptococcic rhinitis with subsequent accessory sinus involvement due to infection from an impetigo or erysipelas of the face.

Todd describes an external rhinitis in children after scarlatina associated with a dermatitis of the lips and pustules on the cheeks and fingers, in which he finds the diphtheria bacillus of weak virulence, pseudo-diptheria bacilli, and he suggests that this condition might explain the frequency of diphtheria after scarlatina.

Kanthack has also found the so-called pseudo-diphtheria bacillus in skin lesions, but adds that it can be brought to normal virulence. I have never seen the diphtheria bacillus in pure culture from the skin, but have found it in cases similar to those described by Todd, after the exanthemata, and on that account such lesions, together with the mucous membrane catarrh or otorrhœa, should be energetically treated and isolated for fear of the dissemination of the infection. One case of death from diphtheria in a child I believe to be due to such an infection.

Friederich, in his most excellent treatise upon "Rhinology, Laryngology and Otology in General Medicine," in speaking of diseases of the skin, says:

"There are certain diseases of the skin which lead to alterations of the mucous membranes of the upper air passages analogous to the general process although presenting certain differences in their appearances. There is a greater tendency to loss of epithelium and ulceration, due no doubt to the maceration which occurs in the mucous membranes as a result of the secretions, the moisture and the warmth of the air passages, so that, speaking generally, the mucous membrane shows defects and ulceration, whereas the diseased epidermis of the skin remains as a protective covering in the form of scales

and crusts. For this reason the mucous membrane will in a few hours undergo certain peculiar changes and lose the characteristic appearance of the same disease in the skin." Posner has demonstrated by pathological investigation that the mucous membranes are under certain circumstances inclined to horny-cell production and can take on an epidermic nature. These facts should be borne in mind in the study of diseases of the mouth and lips, especially.

There seems to be much confusion in the names, pathology and clinical symptoms of diseases of the tongue and mouth. Undoubtedly numerous diseases are crowded under the cover of the word leucoplakia and it in this way affords as great a convenience here as the word eczema in diseases of the skin. Localized infections of the mucous membranes similar to those upon the skin frequently occur and are more resistant to treatment on account of the location and the anatomical and physiological differences of the part. For instance, the clinical types which we call upon the skin, seborrhœic eczema or dermatitis, I am positive I have seen reproduced upon the mucous membranes of the eye, mouth, tongue, lips and introitus vaginæ. The association of marginal conjunctivitis and seborrhœa capitis and rosacea is familiar to all. I have seen acute exacerbations of seborrhœic dermatitis of the face in which the conjunctivæ were injected, granular, red and painful.

The staphylococcus enters into the clinical picture in the eye as it does upon the skin, as it is found in many inflammatory conditions there (Randolph).

Prof. v. Michel points out the frequency with which conjunctivitis phlyctenularis occurs with eczema of the face and body, and he believes there are sufficient pathological and clinical reasons to consider it a true eczema of the conjunctiva.

Veiel was one of the earliest writers to call attention to this association of eczema with chronic conjunctivitis. The mucous membrane of the nares (Freiderich) or vulva (Carriere) can also be secondarily infected by catarrhal processes from the skin.

Secondary infections of the buccal mucous membrane from the skin and the skin from the mouth conditions are of great practical importance and many of these auto-infections partake of the characteristics of seborrhœic dermatitis. A case in the Alms House in St. Louis first called my attention to this fact in 1900. There existed upon the face, scalp, eyelids and body of a girl typical seborrhœic dermatitis. On the buttocks were plaques of rupial crusts, having the character of Fox's rupial psoriasis, which was histologically con-

firmed. These plaques were produced, experimentally, under control experiment, by auto-inoculation. Upon the corners of the lips extending for some distance towards the center and on to the mucous membrane was a condition resembling that seen in congenital syphilis except that on the mucous membrane the outlines jutted down into the mouth more like an active parasitic growth. At that time seborrhœic dermatitis was almost in epidemic at this institution. The condition upon the patient's lips resembled the descriptions given of *La Perleche* by Lemaistre and others. The mouth of this patient was foul, sore and tender.

Uncleanly mouths, gingivitis and such conditions, are often the source of diseases of the lips and adjacent skin by auto-infection. Such cases as those described by G. H. Fox, Morris and by Galloway, where a crusted, pustulo-squamous or a mild serpiginous dermatitis occurs upon the lips and extends from there to the skin it is usually of buccal origin. In the disease, chelitis glandularis apostematosa (Volkmann), or chelitis exfoliativa (Crocker) there generally exists a catarrhal condition of the buccal mucous membrane. Galloway has reported an instance of an associate seborrhœa of the face and scalp. In the cases I have seen the mucous membrane of the mouth was inflamed and a mild gingivitis existed which preceded the lip condition. Crocker seems to include Stelwagon's cases of "Persistent Exfoliation of the Lips" in this class. Stelwagon's cases, of which I have probably seen two, seem to me to be of an entirely different character and due to the persistent habit of biting the lips, causing a chronic hyperkeratosis, as any constant irritation will produce upon the epidermis. My cases were neurotic girls in which the habit preceded the hyperkeratosis for years.

The ringed eruptions upon the mucous membrane of the penis, described by Morrow, Taylor and others as "seborrhœa of the glans penis," is usually associated with seborrhœa of the other regions. It is also probable that many of the types of circinate lesions of the tongue, glossite exfoliativa marginèe, geographic tongue, etc., described by Besnier, Kinnear, Kaposi, Hack, Lemonnier, Fournier and others, are probably of seborrhœic origin. Besnier also calls attention to this fact.

Petrini, at the Third International Congress of Derm. and Syph., reported two cases of what he called "Acne Rubra Seborrhœicum," in which the mucous membrane of the lower lip in one case was congested and covered with desquamation. Pringle calls this disease "A Rare Seborrhœide of the Face." At the last meeting of this Association I presented a photograph of this affection. I have seen these cases

for years and have called them seborrhœic acne in my notes. One case had a sodden, circular, plaque of a greyish white color upon the left side of the tongue near the tip which corresponded to a point usually touched by a seborrhœic lesion on the upper lip, which she was in the habit of moistening with her tongue.

D. Speaking of the simultaneous and alternating occurrences of eczema and catarrhs of the bronchial and bladder mucosa, Duhring says that "there are no convincing observations that the skin is affected in eczema as the mucous membrane is in bronchitis or that the two affections are due to the same cause." Friederich affirms that these conditions are not to be compared to eczema of the skin. Metastatic conditions in eczema as reported by Rayer, Dupeyrac, Brooke, Brocq, Gaucher, Borland and others, in which there is an infectious process, catarrhal or suppurative, induced in some other organ of the body, appeals to me as rational pathology. Dalmasco has proved, upon animals, that virulent micro-organisms can pass through the skin into the general system when the epidermis is broken. In intense general eczema or dermatitis, staphylococci may be forced into the general system by rubbing and the prevention of free drainage by pastes or applications containing powder. Such metastatic instances have been reported by Bernheim and by Borland, in infants. The late and fatal intestinal catarrh of Savill's Disease, epidemic eczema, and similar forms of dermatitis can no doubt be explained by metastatic processes or general systemic involvement by micro-organisms which have passed through the skin. However, I do not see how the cure or suppression of a dermatitis can produce metastatic involvement.

E. Condylomata, or Acanthomata, are frequently associated with seborrhœic dermatitis of the mucous membrane and elsewhere, though they are probably due to a special infection. Elliott calls attention to the frequency of papillomata about the anal regions on an eczema base, associated with fistulæ or hemorrhoids, and Rasch, Abraham, Lowenback, Heidingsfeld and Neumann to the occurrence of condylomata upon the mucous membrane of the mouth probably through auto-infection.

F. The bacillus coli communis, which is an inhabitant of the alimentary canal, according to Mantegazza can produce lesions on the skin by local auto-infection. He reports the cases of two infants with diarrhœa who had varicellaform lesions upon the perineum, genitals, and internal face of the thighs from which he grew pure cultures of virulent colon bacillus. He considers these two cases as analogous to those described as syphiloides, herpes phlyctenoides of the newborn

(Fournier), erythema papilleaux vacciniform infantile (Hallopeau). Cases of dermal infection by this bacillus have also been reported by Anthony and by Brunner.

G. Gonococcoderma. Paulsen asserts that local infection of the skin can occur in the newborn of gonorrhœal mothers.

Torilli reports a sero-purulent infection of the upper lip with crusting like eczema in which gonococci were found associated with a gonorrhœal infection of the urethra. Columbini also reports infection of the cheeks and gums in a similar case.

Baudouin and Gastou call attention to certain impetigenous and eczemaform eruptions of the pubes and genital region in which they find the same organisms as are found in the associate urethral or vaginal discharge—the pseudo-gonococcus, in most instances.

H. The fungi. In Kaposi's famous case of acute Favus infection, typical foci of the fungus were found in the œsophagus, stomach, and intestines. Mibelli and also Hallopeau report infection of the cilia and margins of the lids by the ringworm fungus. The latter writer calls attention to the immunity of the conjunctiva to the fungus.

Winfield's case of infection of the buccal mucosa by the aspergillus nigrescens, a fungus frequently associated with inflammations of the external auditory canal, is clinically interesting. Winternitz reports a case of inflammation of the lips and buccal mucous membrane by a peculiar fungus through auto-infection from the fingers and nails where the same condition existed.

I. Parasites. The dermodex folliculorum, a parasite essentially of the skin follicles, frequently causes marginal blepharitis with irritation of the marginal conjunctiva and great pruritus. Mulder and Hunsche report such cases, while De Amicis and Dubreuilh report disturbances upon the skin.

2. Diseases in which the disturbances in the skin and mucous membranes are symptoms of (a) a toxæmia, metabolically produced in the system with or without the aid of micro-organisms, or (b) the embolic formation of micro-organisms in the tissues.

Toxines, or micro-organisms, probably cause pathologic changes in the skin and mucous membranes through their effect upon the vascular or nervous systems, or by direct chemical irritation of the tissue cells of the part. However, it is impossible at the present state of our knowledge to positively assert what diseases are caused by metastatic foci of micro-organisms and what ones are produced by metabolic or microbolic toxines circulating in the blood and thereby affecting the vessels, nerves or the local tissues. The dermatoses spoken of as of

toxic or embolic origin form the largest group that attack both the mucous membranes and the skin and are of the greatest importance to general medicine on account of their frequent gravity and the fatal termination of many of them. The variability of the symptoms which some of them produce in the mucous membranes of the upper air track and in the alimentary canal, taxes the diagnostic acumen of the best observers. The interest of the relationship between the manifestations of these diseases upon the skin and mucous membranes, rests upon the pathology of the general process, as at no time in the course of apparently the simplest eruption can we be assured of the benignity of their causative factor. It may, however, be here remarked that mucous membrane manifestations, as a general rule, are an indication of a more serious systemic involvement than even severer lesions upon the skin. The splendid work of Osler, Galloway, Sequeira and Balean, MacLeod, Warde, and Waldo, is known to all of you. All of these writers except the first mentioned, Osler, have evidently been inspired by the revival of the study of lupus erythematosus in England.

Osler includes in his "Erythema Group," urticaria, angioneurotic œdema, erythema multiforme (its bullous types also) and various forms of purpura, and he has pointed out the fact that the general underlying pathological factor may find expression upon the mucous membranes and the skin in the form of one, several or all of the above named eruptions in the course of the process. The various polymorphic types of Duhring's dermatitis herpetiformis, form a connecting chain between the "Erythema Group" of Osler and pemphigus vulgaris, through herpes iris on one end and the more truly pemphigoid forms of dermatitis herpetiformis on the other.

When we consider the great polymorphicity of the drug rashes and that drugs can cause any of the initial types of lesions and produce them in such relationship to each other that almost any disease of the skin can be imitated, we must concede the great illustrative and comparative value of their study. The most instructive case in this respect that I have yet seen came under my care through the courtesy of Dr. Amyx, at the City Hospital, St. Louis. The patient, a man of thirty, had had dermatitis herpetiformis for several years of a papulo-erythematous and bullous type. The relapses were typical of the disease and could be reproduced at will by fifteen-grain doses of iodide of potash. Histologically and clinically the iodide eruption was indistinguishable from the normal course of the disease, except that there was a congestion of the conjunctiva and throat. In the

serum from the bullæ iodine could be demonstrated. The iodine rash was twice experimentally produced during his sojourn of one year in the hospital.

The toxic influences of drugs upon the system are difficult to differentiate from toxic and embolic effects of micro-organisms. Neumann's famous case of ulcers and gangrene of the mucous membrane of the stomach and skin from iodine is unique. Bouzetal reports ulcer of the cornea from iodide of potash; Schamberg, severe stomatitis and conjunctivitis; Blaything, gangrenous stomatitis with hemorrhagic eruptions on body and Milian, large ecchymosis on the vault of the palate without dermal manifestations, which is unusual. These mouth symptoms are somewhat analogous to those reported by Weber of sloughing of vulva and by Fayrer of sloughing of the tongue in purpura. These cases point to the similarity between these eruptions and the initial mucous membrane symptoms of grave infections.

Hallopeau and Hennocque report a case of hypertrophic lichen planus of the hands and feet with vegetations on the gums, frenum of the lips and yellow-white striæ on the mucous membrane of the cheeks, but as the patient had long taken arsenic, Besnier and Brocq thought it the cause of the eruption. This is a very instructive case in relation to the subject of this paper, when we consider the more circumscribed types of arsenical keratoses and those produced by unknown agents, keratosis nigricans, for instance, which affect the mucous membranes. It is interesting here also to note the cases of a peculiar keratosis of the knees, hands, and feet described by Buschke as a sequelæ of the effect of the gonorrhœal toxine upon the nervous system.

The urticaria, erythema, and pemphigus group must be closely allied in their pathology to the drug eruptions.

Urticaria. From the histologic study of drug eruptions, particularly of those produced by iodine, I believe that the drug in producing the eruption acts not by its influence upon the nerves, vessels, or glands, but by direct local action of the chemical upon the skin and mucous membranes, which coincides with the views of Philippson, Török, and Hari in relation to urticaria. In urticaria, probably, some slight local irritant oversets the poor equilibrium of the part. This seems to be an explanation of the mucous membrane dermographism reported by Spillman in which the least morsel of solid food would cause a bullous urticaria of the mouth and tongue. The food in this case caused the urticaria only by trauma. A similar condition, no doubt, exists in gastric crises of this group without dermal manifesta-

tions. Osler has lately called attention to the surgical aspects of these cases and urges a careful inquiry into the history of eruptions and arthritis in children in which there are symptoms of appendicitis, intussusception, or obstruction of the bowels before operation. Local disturbances of the mouth and alimentary canal associated with abdominal pain and sometimes hematemesis or bloody stools can occur without any dermal symptoms of urticaria or angio-neurotic œdema (Menx and Chittenden). Anuf, in his interesting report, goes so far as to say that enteritis membranacea is an expression of a similar disorder. Goodale and Hughes have noticed attacks of local œdema of the tongue associated with achlorhydria. The cases of Kahn are instructive. I have found in cases of gastric crises with urticaria upon a dermographic skin, that the bromides frequently prevent the abdominal pain and eruption by allaying the nervous irritability. In most of the intestinal disturbances of this type food acts not as a toxic irritant but as a mechanical one upon an irritable mucous membrane, as the fingers do upon a dermographic skin, whatever the underlying cause of the irritability may be. This is exemplified in Henoch's purpura and the various types of several metabolic disturbances described by Osler. Rapin and Romers divide urticaria of the upper air-passages into two forms: (1) When the wheals appear first on the skin, followed by those of the mucous membrane; (2) when the wheals appear first on the mucous membrane and then on the skin. In the latter form the disease simulates asthma or croup, being associated with dyspnœa and often hematemesis. Packard reports bronchial cough and urticaria alternating. Freudenthal calls attention to chronic laryngeal urticaria in recurring attacks—a very rare condition and was always due in his case to alcoholic and dietary indiscretions.

Erythema multiforme. In the light of recent literature the division as suggested by v. Düring appeals to me from the standpoint of their probable pathology. He gives three classes: (1) General infection with symptomatic outbreaks upon the skin and mucous membranes, (2) Angio-neurotic, under which he includes drug and toxic forms; (3) Embolic forms under which he includes the so-called "malignant polymorphic erythemata."

At the present time one must extend the erythema group to include urticaria, angio-neurotic œdema and certain forms of purpura, as it must be admitted that in the course of a certain pathological condition any or all of the forms of the above named symptoms may occur. The skin and mucous membranes of the mouth, nose, and alimentary canal may be attacked, either one preceding the other or co-

incidentally by any one of the types of eruption named, they each and all being dependent upon the general pathological condition.

It is through the mucous membranes, especially that of the mouth and upper air tract that infections gain entrance to the economy in many instances, as is evidenced by preliminary angina, pharyngitis, stomatitis, gingivitis and such conditions in many eruptive disorders. An illustrative case is that of Pagliano and Francois, in which a facial erysipelas extended to the mouth, followed by purpuric erythema, pneumonia and death.

It is exceedingly difficult to distinguish erythema multiforme of the mucous membranes without the skin manifestations of the disease, which often happens. Lukasiewicz depends in diagnosis upon their acuteness, superficial character, peripheral extension and early erosion of the erythematous elements. Schrötter says it is less painful than pemphigus yet it is practically impossible to distinguish the lesions of erythema iris, which frequently occur first on the mucous membranes of the mouth, from pemphigus vegetans or vulgaris in the early stages of the disease.

The bullous types of erythema multiforme attack the mucous membranes more frequently than the other forms, and when recurrent are usually suggestive of grave visceral disorders. Somewhat similar to the cases reported by G. H. Fox, Chambers and Turner, and C. Fox, are the ones reported by Hutchinson as "a form of chronic inflammation of the lips and mouth which sometime ends fatally and is usually attended by disease of the skin and nails." In this type the mucous membrane symptoms precede or quickly follow the skin manifestations in the form of bullæ which soon rupture. The whole process has a septic aspect and is no doubt closely allied to the type of bullous disease described by Howe as "Cases of Bullous Dermatitis Following Vaccination." Six out of ten of Howe's cases were fatal with marked involvement of the mucous membrane of the mouth and probably alimentary tract.

Pemphigus. It is exceedingly difficult to make any but a provisional line of division between the various forms of true pemphigus, dermatitis herpetiformis and the bullous disease above mentioned. Of course, there is a classical pemphigus vulgaris, pemphigus vegetans, dermatitis herpetiformis, herpes iris and bullous erythema, but there are so many deviations from the standard types, not only on the skin but in the tout ensemble of the mucous membrane symptoms, the apparent etiology and general clinical symptoms. Graham Chambers' cases, above cited, exhibited bullæ of the conjunctiva, although the

clinical symptoms of the relapsing bullous disease were those of an erythema bullosum or possibly more of a dermatitis herpetiformis. Lesions do occur upon the mucous membranes of the mouth in the latter disease, reported by Stelwagon, Morris, Whitfield, and Galloway, but I judge that such involvement is rather rare from my search of the literature. Again, many of the cases of pemphigus vulgaris have a distinctly septic aspect, especially so when there is marked mucous membrane involvement which is no doubt largely contributed to by secondary infection of those lesions. Pemphigus vegetans, according to Homburger and Rubil, usually begins in the throat and mouth; hoarseness was the earliest symptom in their patient. Those writers also point out that these early symptoms are to be differentiated from Hutchinson's disease above referred to, and foot and mouth disease.

Any form of pemphigus may involve the mucous membranes as a late or an early symptom of the process.

The conjunctiva is especially frequently primarily affected. Prof. v. Michel classifies the mucous membrane symptoms as follows: (1) Cases exclusively confined to the conjunctiva; (2) Cases in which the mucous membranes of the mouth, nose, pharynx and larynx and conjunctiva are all affected; (3) Universal cases.

This "essential shrinking of the conjunctiva" of v. Graefe, may occur without evident bullous formation. V. Michel asserts that sclerosis of the conjunctiva without evident cause is due to this process. Bellencontre reports a case where itching with pricking pains of the eye preceded any symptoms of pemphigus for nine months. Bullæ in the mouth and upon the skin finally appeared, but after the eye changes had become marked.

Bryan, Omerod, Pringle record cases of pemphigus vulgaris of the mouth, the former of the larynx, which preceded the skin eruptions. Numerous cases of this character have been reported. When the larynx is alone involved it simulates diphtheria on account of a membrane which quickly forms over the excoriation.

Impetigo herpetiformis is frequently preceded by like disturbances of the oral mucous membranes, thus suggesting a resemblance to pemphigus vegetans. Glaevecke has often seen it attack the mucous membrane of the alimentary canal.

Lupus erythematosus. To Galloway, Warde, Sequeira, and Balean lupus erythematosus signifies a symptom produced by various general processes and is closely allied to the erythema group and often indicative of visceral affections. Feeble circulation and persistent local paresis of the vessels from various causes is to them the principal

factor in the production of the disease. Sequeira and Balean think that the discoid form is not a tuberculous affection, but seventy per cent. of their cases of the disseminate form were associated with tuberculosis. Warde, in the study of the mucous membrane of the nose in fifteen cases of lupus erythematosus, found atrophic or hypertrophic rhinitis in seventy-five per cent. of them. "After all," he remarks, "there is nothing surprising in these two states, clinically they resemble each other in quite a remarkable fashion. There is the same chronic course, the same resistance to treatment and steady progression in the majority of cases, the same kind of atrophy of the glandular structures and cornification of the surface epithelium, the same vivid redness due to large vessels and subsequent white atrophy." In his subsequent papers he calls attention to certain changes found in the mucous membrane of the mouth; namely, atrophic patches, swelling of the whole mucous membrane and increase of stratified epithelium, smoothness of the tongue. Murray and also Stocker have noticed the relationship of certain diseases of the nares and skin of the face. Sticker, after the study of injected specimens, asserts that various intra-nasal conditions can be conveyed to the face through the lymph channel from the nares as they communicate between the two locations. Sticker, therefore, thinks that many infectious processes can be thus conveyed to the skin of the face including lupus erythematosus. It is interesting to note in connection with the tuberculosis theory of lupus erythematosus and the latter's frequent association with forms of rhinitis, that Goure, in the bacteriological examination of 201 cases of adenoids, closely allied to hypertrophic rhinitis, concluded that none of them were of tuberculous origin.

Numerous observers have described lupus erythematosus of the mucous membranes besides the writers named, particularly Dubreiulh, who gives a splendid clinical description of the condition. If the theory of Warde be true and atrophic rhinitis is the same process in the mucous membrane of the nares as lupus erythematosus, it is strange that the mucous membrane of the mouth, vagina and penis do not more frequently show evidences of the disease.

Herpes. Spitzer asserts from his anatomical investigations that the dividing line between facial and nasal herpes and genuine zoster is becoming fainter and fainter. Howard has demonstrated that herpes labialis and nasal herpes present changes in the Gasserian ganglion identical to those found by Head and Campbell in herpes ophthalmicus and of the trunk, only differing in severity. He also observes that acute coryza has some etiological connection with herpes

of the lips. Doplir's epidemic in a regimental mess, in which several cases of zoster of the inferior maxillary branch of the fifth nerve was preceded by sore throat, is interesting from an etiological standpoint. Doplir asserts that the ophthalmic branch of the fifth nerve is the most frequently affected. Bane calls attention to the frequency of the error of diagnosis herpes ophthalmicus as facial erysipelas on account of the shivering and redness of the skin in the early stage.

Herpes of the larynx is not infrequent. Secreton asserts that it may be single or may be accompanied by dermal lesions. The attack is accompanied by pain, shivering, hoarseness, dyspnœa and inflammation of the parts. A membrane soon forms over the lesions and might be mistaken for diphtheria.

Hugenschmidt reports two cases of zona of the mouth and gums, one of which preceded pneumonia and the other acute tuberculosis. Unna found in his researches among prostitutes that herpes progenitalis was frequent and that it was probably due to the recurrent local causes in such women. Local disturbance of the urethral mucous membrane can cause reflex zoster of the face, as in Sulzer's case. My first and only divulsion of a urethral stricture was followed in ten hours by a zoster of the face with temperature.

Lichen Planus. The lesions of lichen planus occur upon the mucous membranes of the cheeks, lips, tongue, penis, vulva and within the urethral canal. According to Thibierge it may invade the mucous membrane before, during or after the cutaneous eruption. Crocker asserts when upon the penis it may precede the skin eruption by some weeks or months. Upon the cheeks Thibierge describes the lesions as small, pointed, round or stellate pimples, white or shiny, solitary or forming patches. On the tongue the lesions appear as round or irregular white spots, solitary or united, not raised, and form parallel lines on each side of the raphe or at the edge of the organ. Opposite the teeth white branching streaks are frequently seen (Crocker). On the palate Crocker has seen the eruption in a mosaic with white outlines. Brocq has observed circinate lesions in the mouth. Balzer and Faure-Beaulieu reported before the French Society of Dermatology a case of pityriasis rubra pilaris in a neurotic woman with typical lesions, of lichen planus on the tongue. Fournier, in the discussion, remarked the difficulty of diagnosis between lichen planus of the mucous membranes and leucoplasia.

Darier speaks of three clinical types affecting the oral mucosa. Heuss has observed lichen planus of the urethra.

Thibierge believes that local irritation of the mucous membranes

favors the appearance of the patches there. In the study of the histopathology of lichen planus the picture conveyed to the writer is similar, in the arrangement of the cellular elements about the vessels and in the cutis, to syphilis without the typical plasma cells of the latter disease. The relationship between the location of syphilitic lesions and irritation is well known, and on account of some of the histologic similarities of the two diseases it seems to me that irritation has much to do with the location of the lesions in lichen planus.

Du Castel and Kalt have seen palpebral hyperkeratosis of the four lids with kerato-conjunctive herpetique associated with pityriasis rubra pilaris; Mohr has also observed ocular lesions in the same disease.

Xanthoma. The plaques of the various forms of xanthoma which occur upon the mucosa of the mouth, tongue, palate and œsophagus need no further mention. Kirk refers to a peculiar fissuring of the tongue associated with myxœdema.

That senile pruritis affects the mucous membranes is mentioned by E. Baumgarten as "Pruritis Senilis Linguae."

Pigmentary Diseases. In the presentation of a case by C. Fox of a peculiar pigmentation of the mouth of four years' standing in a man in perfect health, Stephen Mackenzie remarked that in such cases he generally suspected Addison's disease, as the primary pigmentation may exist in the mouth long before the other symptoms. Schultze reports melanoplaxia in the mouth associated with diseases of the liver. Audry and Enrique and Leroboullet report pigmentations similar to Addison's disease from prolonged administration of arsenic. In this connection it is well to notice the case of Chatin in melanodermia phthiriasique, or vagabond's disease, with typical pigmentation of the mucous membrane and the skin with prostration sufficient to form the picture of Addison's disease. These cases rapidly regained their strength under hospital care. Two such cases I have observed in the City Hospital, in both of which the diagnosis could only be confirmed by time. Both cases had pigmentation of the mucous membrane of the mouth and skin, with prostration. One recovered rapidly after the removal of a tape-worm, the other under the rest and food of the hospital.

Osler reports two cases of Ochronosis of Virchow with deep blue color of the sclerotics and skin of hands and portions of the face, occupying areas like lupus erythematosus, associated with alkaptonuria.

Embolic Eruptions of the Skin and Mucous Membranes. As bacteriological and histological technique becomes more proficient more

of the exanthematous rashes will probably be found to be of this nature. Meyer believes that the acute exanthematous eruptions are due to emboli of micro-organisms. Dehio believes the eruptions following acute anginas to be of this origin. It is also probably so of many of the eruptions of the erythema and pemphigus group. However, many of the eruptive disorders gain entrance to the system through the mucous membranes of the upper air passages, alimentary canal and urethra.

Brocq's scarlatiniform erythemata in the majority of cases is preceded by involvement of the throat; E. Finger classifies a number of septic-embolic exanthemata of the skin and mucous membranes; Musser, streptothrical infections of the skin, mucous membranes and lungs; Unna, a phlyctenulæ streptogenes causing a vesicular and purpuric eruption of mouth, conjunctiva and skin; R. Bernard and Jacob describe a disseminated gangrene of the skin associated with diphtheria due to Loeffler's bacillus aided by a polymicrobic symbiosis. This case is analogous to those reported by Stahl, Pratt and Abt of gangrene of the skin after typhoid.

The gonococcus may cause various erythematous, scarlatiniform, vesicular, papular or nodular eruptions through the influence of their toxics or by the formation of emboli as described by Buschke, Paulsen, Barbiani and others. Papular and vesicular eruptions of this origin most frequently occur in conjunction with gonorrhœal ophthalmia.*

REFERENCES.

Abraham: *Brit. Jour. of Derm.,* vol xii, p. 451.
Abt: *Jour. Amer. Med. Assn.,* Aug. 17th, 1901.
Allan-Wainfleet: *Brit. Med. Jour.,* Oct. 26th, 1901.
Allen: *Jour. Cut. and Ven. Dis.,* vol. iv., p. 167.
Audry: *Ann. de Derm. et de Syph.,* 1898, vol. vi.
Auspitz: Ziemssen's Handbook of Skin Diseases.
Balzer and Faure-Beaulieu: *Ann. de Derm. et de Syph.,* 1902, p. 1152.
Bane: *Jour. Amer. Med. Assn.,* Dec. 12, 1901.
Barbiani: *Giorn. Ital. della Mal. Ven. e della Pelle.,* 1902, Fasc. 1, p. 9.
Baumgarten, E.: *Munch. Med. Woch.,* No. 39, 1901.
Bènard: *La Pratique Derm.,* p. 969.
Bernard and Jacob: *Arch. de Med. Expèr.,* Sept., 1903.
Bellencontre: *Jour. des Mal. Cut. et de Syph.,* July, 1899.
Besnier: *Ann. de Derm. et de Syph.,* 1885, p. 321.
Besnier: *La Pratique Derm.,* p. 223.
Besnier: *Jour. Cut. and Ven. Dis.,* vol. iv, p. 244.
Blaything: *Med. Record,* June 17, 1893.

* On account of lack of time, all of Dr. Engman's paper was not read. This will explain some points in the criticism and discussion.—EDITOR.

Bodin: *La Pratique Derm.*, p. 564.
Borland: *Lancet,* Oct. 17th, 1903.
Boucheron: *Arch. Int. de Laryn., Otology, Rhin.,* T. ix, No. 6.
Boudouin and Gastou: *Ann. de Derm. et de Syph.,* 1901, p. 251.
Bouzetal: *Rec. d'Opthal.,* Oct., 1903.
Brocq: *Jour. Cut. and Ven. Dis.,* vol. iii, p. 232.
Brocq: *Rev. Gen. de Clin. et de Ther.,* April 3, 1897.
Bryan: *N. Y. Med. Jour.,* 1889, p. 775.
Buschke: *Arch. f. Derm. u. Syph.,* Bd. xlviii, No. 2.
Cala: *La Semaine Med.,* 1889, p. 346.
Carrière: *Bulletin Med.,* 1902, p. 1105.
Chambers: *Canadian Practitioner,* Oct., 1900.
Chatin: *Ann. de Derm. et de Syph.,* 1900, p. 1213.
Chittenden: *A. Jour. Med. Sciences,* Oct., 1898.
Columbini: *Riforma Medica,* 1900, Nos. 87, 88 and 89.
Corlett: A Treatise on the Acute Infectious Exanthemata.
Courtade: *Arch. Internat. de Laryn., Otol. and Rhin.,* Jan. and Feb., 1897.
Crocker: Diseases of the Skin.
Danlos: *Ann. de Derm. et de Syph.,* 1903, p. 486.
Darier: *Ann. de Derm. et de Syph.,* 1902, p. 1154.
De Amicis: *Giorn. Ital. delle Mal. Ven. e della Pelle,* 1898, Ht. 3.
Dehio: *St. Petersburg Med. Wochen.,* Mar. 17th, 1900.
Deshayes: *Union Medicale,* Aug. 28th, 1882.
Dopter: *Gazet. des Hosp.,* 1899, p. 1201.
Dubreuilh: *Ann. de Derm. et de Syph.,* 1901, p. 231.
Dubreuilh: *Monatsh. f. prakt. Derm.,* 1902, p. 209.
Du Castle: La Pratique Derm., p. 801.
Du Castel and Kalt: *Ann. de Derm. et de Syph.,* 1900, p. 1228.
Duhring: *Cutaneous Medicine, Part ii,* pp. 340 and 456.
Dupeyrac: *Gaz. des Hosp.,* Sept. 10th, 1903.
V. Düring: *Arch. f. Derm. u. Syph.,* Bd. 35, 1896.
Ebstein: *Wien. Klin. Wochen.,* 1896, No. 16.
Elliot, G. T.: *Jour. Cut. and G-U. Dis.,* vol. vi, p. 333.
Engman: *Amer. Med., Nov.* 15, 1902.
Engman: *Jour. Cut. and G-U. Dis.,* May, 1904.
Engman: *St. Louis Med. Rev.,* Nov. 10th, 1900.
Enriquez and Lereboullet: *Lancet,* Aug. 5, 1899.
Fayrer: *Brit. Jour. Derm.,* 1896, p. 73.
Finger: *Wien. Klin. Wochen,* 1896, No. 25.
Forssman: *Hygiea Medicinsk och Farmaceutisk Monadsokrift*, Stockholm, 1900.
Fox, C.: *Brit. Jour. Derm.,* 1899, p. 24.
Fox, C.: *Brit. Jour. Derm.,* 1899, p. 316.
Fox, C.: *Skin Diseases*, 1887, p. 260.
Fox, G. H.: *Jour. Cut. and G.-U. Dis.,* vol. v, p. 225.
Fox, G. H.: *Jour. Cut. and G.-U. Dis.,* vol, viii, p. 31.
Freudenthal: *N. Y. Med. Jour.,* Dec. 31, 1898.
Friederich: *Rhinology, Laryngology and Otology in Gen'l Med.,* p. 191.
Galloway: *Brit. Jour. Derm.,* vol. xiii, p. 7.
Galloway: *Brit. Jour. Derm.,* 1903, p. 235 .
Galloway: *Brit. Jour. Derm.,* 1903, July.
Galloway: *Brit. Jour. Derm.,* 1895, p. 113.
Galloway and Macleod: *Brit. Jour. Derm.,* 1903, p. 81.
Glaevecke: *Arch. f. Gyn.,* B. 211, Ht. i, p. 18.
Goodale and Hughes: *Amer. Jour. Med. Sc.,* April, 1899.

Goure: Thèse de Paris, 1897.
Hack: *Monatsh. f. prakt. Derm.,* April, 1882.
Hallopeau: *Ann. de Derm. et de Syph.,* 1902, p. 1138.
Hallopeau and Hennocque: *Ann. de Derm. et de Syph.,* 1900, p. 627.
Hamburger and Rubel: *Johns Hopkins Hosp. Bull.,* Mch. and Apr., 1903.
Heidingsfeld: *Jour. Cut. and G.-U. Dis.,* 1901, p. 226.
Heuss: *Monatsh. f. prakt. Derm.,* 1900, p. 470.
Holt: *Med Rec.,* Feb. 5, 1898.
Howard: *Amer. Jour. Med. Sc.,* 1900, vol. 125, No. 2.
Howe: Jour. Cut. Dis., 1903, p. 254.
Hugenschmidt: *Med. News,* June 21, 1890.
Hunsche: *Munch. Med. Wochen.,* 1900, No. 45.
Hutchinson, J.: *Royal Med. and Chir. Trans.,* 1887.
Hyde: Jour. Cut. Dis., 1903, p. 105.
Jamieson: *Brit. Jour. Derm.,* 1894, p. 297.
Kaposi: *Ann. de Derm. et de Syph.,* 1901, p. 86.
Kaposi: *Diseases of the Skin,* 1902. English Trans.
Kinnier: *Jour. Cut. G.-U. Dis,* vol. v, p. 56.
Kirk: *Brit. Med. Jour.,* May 20, 1899.
Kohn: *Amer. Med.,* Dec. 21, 1901.
Kurselback: *Monatsh. f. Ohren.,* 1885, No. 2.
Lemaistre: *Jour. Soc. de Med. et de Pharm. de la Haute-Vienne,* Limoges 1886, p. 55.
Lemonnier: Thèse de Paris, 1883.
Lewin: *Berlin Klin. Wochen,* 1876, No. 23.
Lowenbach: *Monatsh. f. Prakt. Derm.,* 1901, p. 85.
Luithlen: *Wien. Klin. Wochen,* Jan. 26, 1899.
Lukasiewicz: *Wien. Klin. Wochen,* 1896, p. 23.
Mantegazza: *Giornale Ital. delle Mal Ven. e della pelle,* 1900, p. 208.
Marfan and Hallé: *Rev. Mensuelle des Mal. de l'Enfance,* Jan., 1896.
Merx: *Munch. Med. Wochen,* 1899, p. 1174.
Meyer: *Arch. & Klin. Chir,* Bd. ii, Ht. 1, 1896.
Mibelli: *Monatsh. f. prakt. Derm.* Reprint.
v. Michel: *Derm. Zeitsch.,* 1900, p. 895.
Milian: *La Presse Med.,* Sept. 30, 1899.
Mohr: *Wien. Klin. Wochen.,* 1898, No. 35.
Morris: *Ann. de Derm. et de Syph.,* 1900, p. 188.
Morrow: Drug Eruptions.
Morrow: *Jour. Cut. and G.-U. Dis.,* vol viii, p. 140.
Muetze: *Arch. f. Angenheilk.* Reprint.
Mulder: *Nederlandsch Ty. dschrft. voor gennsskunde,* 1889, p. 803.
Murray: *Med. Rec.,* Mch. 25, 1899.
Musser: *Chicago Med. Recorder,* Aug., 1901.
Neumann: *Ann. de Derm. et de Syph.,* 1900, p. 1081.
Neumann: *Wien. Klin. Wochen.,* 1898, No. 8.
Newcomb: *Courier Med.* Jan., 1902.
Omerod: *Brit. Jour. Derm.,* 1903, p. 324.
Onuf: *Med. Rec.,* Aug. 5, 1899.
Osler: *Amer. Jour. Med. Sciences,* Jan, 1904.
Osler: *Brit. Jour. Derm.,* vol. xii.
Osler: *Lancet,* 1904, p. 10.
Osler: *Med. Rec.,* May 14, 1904, p. 791.
Packard: *Arch. of Pediatrics,* 1899, p. 729.
Pagliano and Francois: *La Presse Med.,* 1899, p. 196.

Paulsen: *Münch. Med. Wochen,* 1901, p. 1011.
Petrini: Third Internat. Congress of Derm.
Philippson: *Monatsh. f. prakt. Derm.,* 1900, p. 331.
Pollitzer: *N. Y. Med. Jour., July* 15, 1899.
Posner: *Arch. f. Path. Anat. u. Phys.,* vol. 118, No. 3.
Pratt: *Jour. of the Boston Society of Med. Sc.*
Pringle: *Brit. Jour. Derm.,* 1899, p. 323
Randolph: *Jour. Amer. Med. Assn.,* Oct. 3, 1903.
Rapin: *Rev. Med. de la Suisse Rom.* No. 12, 1886.
Rasch: *Derm. Centralb.* No. 6, 1900.
Rolleston: *Brit. Jour. Derm.,* 1902, p. 213.
Sarozin: These de Paris, July, 1883.
Savill: *Jour. Cut. and G.-U. Dis.,* 1894, p. 281.
Schamberg: *Med. and Surg. Reporter,* July 11, 1896.
Schamberg: *Internat. Med. Magazine,* 1900, No. 7.
Schein: *Ungar. Derm. u. urolog. Gesell. in Budapest.—Monatsh. f. prakt. Derm.,* 1899, p. 411.
Schmidt: *Krankh. der ob. Luftwege,* 2nd Ed. p. 531.
Schmiegelow: *Monatsh. f. Ohrenheilk., Abs. Jour. Cut. and G.-U. Dis.,* vol. iv, p. 213.
Schram: *Chicago Med. Rec.,* 1902.
Schrötters: *Monatsh. und Ohrenheil-Kunde,* Oct., 1898.
Schrötters: *Vorlesung. uber die krankh. des Kehlkopfes,* 1st Ed. p. 62.
Schultze: *Deutsch. Med. Wochen,* 1898, No. 46.
Secreton: *Ann. de l'Oreille,* etc., Aug., 1895.
Sequeira and Balean: *Brit. Jour. Derm.,* 1902., p. 367.
Somers: *Med. News,* Mch., 1902.
Spillman: *Ann. de Derm. et de Syph.,* 1902, p. 632.
Spitzer: *Centralb. f. d. Grenz. d. Med. u. Chir.* (Jena), July 10 and 17.
Stahl: *Amer. Jour. Med. Sc.,* 1900, No. 335.
Stelwagon: Diseases of the Skin.
Stelwagon: *Jour. Cut. and G.-U. Dis.,* vol. viii, p. 50.
Sticker: *Derm. Zeitsch. Dic.,* 1898.
Taylor, R. W.: *Jour. Cut. and Ven. Dis.,* vol. ii, p. 365.
Thibierge: *Ann. de Derm. et de Syph.,* 1886 (Abst. *Jour. Cut. and Genito-Urin. Dis.,* vol. iv, p. 51.)
Tilden: *Boston Med. and Surg. Jour.,* July 23, 1885.
Todd: *Lancet,* May 28, 1898.
Torelli: *Gl. Morgagni,* 1901, No. 8.
Török and Hari: *Arch. f. Derm. u. Syph.,* 1903, p. 21.
Turner: *Brit. Jour. Derm.,* Nov. 1898.
Unna: *Arbiet aus Dr. Unna's Klinik.,* 1895, p. 40.
Unna: Histopathology of the Skin. English Trans.
Unna: *Jour. Cut. and Ven. Dis.,* vol i, p. 321.
Vassant: *Jour. Amer. Med. Assn.,* Feb. 27, 1897.
Veiel: *Ziemassen's Handbook of Skin Diseases,* p. 171.
Volkmann: *Virchow's Arch,* 1870, p. 142.
Waldo: *Brit. Jour. Derm.,* vol. 13, p. 292.
Warde: *Brit. Jour. Derm.,* 1903, p. 161.
Warde: *Brit. Jour. Derm.,* Sept., 1902.
Warde: *Brit. Jour. Derm.,* Dec., 1902.
Weber: *Brit. Jour. Derm.,* vol. xii, p. 81.
Winfield: *Jour. Cut. and G.-U. Dis.,* 1897, p. 13.
Winternitz: *Ann. de Derm. et de Syph.,* 1902, p. 904.

DISCUSSION OF DRS. FORDYCE AND ENGMAN'S PAPERS.

Dr. James C. White said that although Drs. Fordyce and Engman had mentioned many dermatoses which were reflected either primarily or secondarily on the mucous membranes, it was strange that such conditions were not still more common. In certain cutaneous affections the skin was involved universally and to an intense degree, and yet the mucous membranes remained absolutely free from any sympathetic manifestations whatever. It seemed very difficult to explain why in these comparatively few instances the mucous membrane should have become affected.

One of the conditions which Dr. White said he did not hear the readers of the papers refer to was xanthoma, which occurred on the mucous membranes within the alimentary tract. It was questionable, the speaker said, how far to go in the terminology of certain changes which affected the cavity of the mouth and nose, and whether it was proper to call them by the names that were applied to similar forms of tissue changes as expressed on the cutaneous surface when they occurred on the mucous membrane alone. For example, writers spoke of pemphigus affecting the tongue only, meaning thereby a solitary bulla or a succession of bullæ on the tongue, and it was questionable whether these could be regarded as a herald of possible future and fatal disturbance or not. The speaker said he never felt justified in making the diagnosis of pemphigus in such a case unless it was supported by future events. Sometimes a single bulla on the tongue was the only one occurring in the patient's history. It was questionable whether we had any form of pemphigus expressing itself in this locality alone. It was also questionable whether eczema of the buccal cavity could exist alone as a solitary affection. The speaker referred to the frequency with which erysipelas had its origin in the nasal cavity, and was usually due to the habit of forcibly removing scales and crusts from the mucous membrane of the nose. He expressed the opinion that a large proportion of cases of erysipelas of the face were due to this habit, which affords the germs a ready means of entrance. He could recall perhaps twenty instances where persons who had long been subject to recurrent attacks of facial erysipelas were permanently relieved by having their attention called to this habit, and refraining from it in the future. There was another form of acute inflammation of the lower lip and extending a short distance into the cavity of the mouth which occurred in the late summer and autumn, and was the result of eating corn off the ear. The corn was first buttered and salted, and its contact with the lips and chin gave rise to this form of eczema. It could be recognized at a glance, and readily healed when the patients stopped eating corn off the cob. Another clinical form of eczema of the lip was due to fur-dye poisoning. Many women had the habit of covering the mouth with their fur boa in severely cold weather,

and this, in a certain number of persons with susceptible mucous membranes gave rise to this form of eczema.

Dr. Hyde said he had seen striking instances of leucokeratosis in the mouths of non-smokers. In one case, in which the lesions were typical and severe, the man had never put tobacco into his mouth. A few marked instances of porokeratosis of the mucous membranes of the glans penis had been seen by Dr. F. H. Montgomery and himself. A few years ago, most of the members would have smiled at a suggestion that psoriasis could affect the mucous membranes, but since then, the speaker said, he had modified his view of the subject, as he had seen psoriasis very definitely developed on the mucous membrane of the genital tract of both sexes.

Dr. Hyde said the etiological relationship between leucokeratosis and carcinoma, upon which the French writers had long laid much stress, was now generally recognized and admitted, especially in patients who used tobacco to excess. Leucokeratosis was probably much more common than was formerly believed, and frequently went unrecognized or was accidentally discovered. In cancer of the mouth and tonsil, it was not uncommon to find a coincident leucokeratosis, which probably existed long before the carcinomatous condition, and had been unrecognized.

Dr. Hyde said that during his last visit to Copenhagen, Dr. Finsen's assistant showed him a case of lupus vulgaris, with perforation of the septum, which was regarded there as a curiosity. The lupus nodules had perforated the septum. Subsequently, in visiting the Leper Asylum, the speaker called attention to the fact that in a large number of the cases of leprosy the eyes were affected, while in a relatively small number there was infection of the mouth and nose. This fact was of interest in view of the opinion held by some American writers that the source of infection in leprosy was through the nose or mouth. In Vienna, perforation of the septum due to lupus vulgaris was not uncommon.

Dr. Hyde said that the occurrence of an erysipelatoid (*not* erysipeloid) flush extending to the face as the result of picking the nose was quite common; but that it was identical with true erysipelas he strongly doubted. He had never seen true erysipelas result in these recurrent facial eruptions.

Dr. Douglass W. Montgomery, of San Francisco, said that Dr. Fordyce's description of epithelioma of the lower lip reminded him of a case he saw in Dr. Howard Morrow's practice just before he left home. It exactly simulated actinomycosis, and had the ugly look that one saw when the disease originated in the mouth.

Dr. Montgomery referred to an affection which was often associated with psoriasis. It consisted of irritable looking, red papillæ at the tip of the tongue, associated with coating of the tongue itself. The speaker said he had come to regard this as one of the symptoms of psoriasis. At its tip, the tongue almost resembled the so-called strawberry tongue.

Dr. Ravogli said there was no doubt that in the acute exanthemata the

diagnosis must, to a certain extent, rest upon the condition of the mucous membranes, which were more or less constantly involved. In smallpox, especially of a mild type, the mucous membrane of the palate, was sometimes involved, and this aided in the diagnosis; in other cases, however, even when the cutaneous eruption was well developed, he had not been able to find any red points or vesicles on the mucous membrane of the palate. In urticaria and erythema the geographic tongue was to be looked for. The speaker said he had seen several cases of lupus erythematosus where the lesions on the face were accompanied by an eruption on the palate, tongue and mucous membrane of the cheeks. In herpes labialis of the recurrent type he had seen the lesions spread to the tongue and mucous membrane of the cheeks. Quite often in syphilis he had seen superficial ulcerative lesions on the palate and pharynx, especially during the secondary stage of the disease. Erysipelatoid or erythematous conditions of the nose were sometimes accompanied by cracks or fissures of the nose, and so long as these remained unhealed the redness was apt to persist.

Dr. Whitehouse said that the lesions on the tongue mentioned by Dr. Engman as undoubtedly produced by auto-infection from contact with a patch of seborrhoic eczema of the lip, tended to throw some light, in his opinion, upon the nature of Dr. Stelwagon's cases of "A Peculiar Eczematoid Eruption of the Lip Region." It was the presence of these mucous membrane lesions alone in Dr. Stelwagon's cases that spoke against the diagnosis of seborrhoic eczema and he thought the observations of Dr. Engman would remove, in a large degree, that element of doubt.

Dr. Stelwagon said he did not think that the cases described in his paper belonged to the same class as those referred to by Dr. Engman. In his own cases, biting or wetting the lips was not a factor in the production of the eruption. There was frequent moistening of the lips, but this was more a consequence of the condition than a cause, and was probably induced by the unusual dryness of the parts.

Dr. Gilchrist said that an epithelioma not infrequently developed at the site of syphilitic plaques on the tongue, and surgeons were inclined to blame the dermatologist for not recognizing this condition earlier. The speaker recalled a case of syphilis in which there were a number of these hardened patches on the tongue, and one of them was apparently undergoing malignant changes. He excised it and found a condition similar to that indicated in one of the excellent micro-photographs shown by Dr. Fordyce. In connection with Dr. White's statement that picking the nose was a frequent cause of facial erysipelas, the speaker said that constant picking of the nose often induced a pyogenic folliculitis affecting the anterior portion of the nostril.

Dr. Henry G. Anthony said he recently saw in the practice of Dr. R. R. Campbell a case of leucoplakia of the mouth, in which

epithelioma developed rapidly in a wound made by a cutaneous punch for the purpose of obtaining tissue for microscopical examination. The wound never healed, within a few days an ulcer formed, extending rapidly, and within ten days it became necessary to do quite an extensive operation, removing a considerable section of tissue which proved to be an epithelioma.

Microscopically the tissue removed by the punch was warty-like in one part and epitheliomatous in another part. This case illustrated the fact that clinically it was sometimes difficult to determine when epitheliomatous changes had commenced in these plaques.

Dr. Frank H. Montgomery called attention to the statistics of Prof. Finsen, which showed that the mucous membranes were involved in seventy per cent. of all cases of lupus vulgaris treated in Copenhagen. This fact was so well known among the people of Denmark that persistent nasal catarrh always excited their suspicion, and brought them to the Lys institute for examination. In consequence it was not uncommon to find lupus of the nasal mucous membrane before lesions had appeared on the skin.

With reference to erysipelas and erysipelatoid conditions about the nose, a clinical distinction should be made since a patient who manifested at one time one type did not at another time show symptoms of the other type. The type remained permanent in the same individual. It was, however, more a matter of tissue resistance than of the organism involved. Erysipelas, commonly recognized, had been produced recently in animals by more than one form of organism, including the organisms found in the lesions of both erysipelas and erysipeloid.

Dr. Corlett said the usual involvement of the mucous membranes in the exanthemata had been described from time immemorial, and new phenomena in that connection had recently been brought to light. The speaker said he could corroborate the observation made by Dr. F. H. Montgomery regarding the frequency with which the mucous membrane of the nose was involved in cases of lupus vulgaris seen in Denmark. In perhaps one-third of the cases at Copenhagen, the mucous membranes were involved, and in quite a number of instances there were perforations of the septum. In a number of cases of eczema of the upper and lower lips the speaker said he attributed the eruption to the habit of sucking or moistening the lips. Impetigo of the mucous membranes had recently been investigated by Dr. Edward Cushing, of Cleveland, and the speaker said they were not able to find a single case of impetigo contagiosa in which the mucous membranes were implicated. It might possibly have occurred and been overlooked.

Dr. Shepherd said he had probably seen over a hundred cases of epithelioma of the tongue, but he had rarely seen it follow leukoplakia. The observations made by Dr. Fordyce in regard to the occurrence of deep-seated cancer cells in these cases were very interesting, and strength-

ened the belief that an epithelioma of the tongue should never be removed in a superficial manner. The disease demanded not only a free excision of the tongue itself, but also extirpation of the glands in the neck, and submaxillary region, which were almost invariably affected early.

Regarding erysipelas following nasal affections, Dr. Shepherd thought that many such eruptions were true erysipelas, and he could recall instances where they had resulted fatally. In connection with Dr. White's cases of eczema of the chin and lips following corn-eating, the speaker said he had seen a similar eruption produced by eating grapes.

Dr. Pusey said he had seen a great many cases of epithelioma of the mouth during the past two or three years, and while in many of these there was no history of a preceding leucoplakia, he was entirely in accord with what had been said regarding the dangerous character of these lesions. The number of epitheliomata that developed in them was large. The statement that when you got the horny overgrowth in these cases the epithelioma was already established was, in his opinion, doubtful; he could recall, for example, one recent case in which the overgrowth of horny epithelium was very extensive, but no carcinoma was present. This was a case where a carcinoma of one cheek had been removed, but the whole mouth—the gums, tongue, and mucous membrane—was involved in an extensive leucoplakia, with many hyperkeratotic masses. This patient had remained under observation for many years, and none of these masses have shown any signs of malignancy. A number of similar but not so extensive cases of the same history could be related.

Dr. Andrew P. Biddle said he recently saw a case in which there was persistent adhesiveness of the lips. The condition was an annoying one and had extended over a period of two years. No cause for it could be determined.

Dr. H. G. Klotz said he could confirm what Dr. Hyde said in regard to pseudo and true erysipelas. In early life, the speaker said, he was subject to recurrent attacks of an erysipelatoid eruption of the face, and more recently he had an attack of true erysipelas, so that he appreciated the difference between the two affections.

In regard to leucoplakia, Dr. Klotz thought it was more frequently observed in syphilitics than in non-syphilitics because the former class would more frequently go to the physician to be examined than the latter. The same was true in regard to herpes of the genital organs.

Dr. William F. Breakey recalled a case of lupus vulgaris with perforation of the nasal septum. In another case a carcinoma developed on a lupous soil. In another case of lupus developing in early life the man lost his ear and the tip of the nose, and the disease finally involved the inner side of the mouth.

Dr. Grover W. Wende said he wished to report a case that was unique in his experience. It was that of a woman forty-five years old, who, for seven or eight years, had had recurrent bullæ in the

mouth, leaving fungating papillary excrescences, which, in time, interfered with eating. This condition had gone on for a long time limited to the mouth. Of course, one would consider this a form of pemphigus, suggested by the formation of blebs. No doubt many bullous eruptions were classed as pemphigus which were probably something different.

Dr. HYDE said he did not wish to be understood that the case of lupus vulgaris, with perforation of the septum, was the only one that had been observed by Dr. Forcheimer, Dr. Finsen's assistant. It was the only case, however, in which it was certain that there was no element of syphilis.

Dr. FORDYCE, in closing, said that only the more important affections of the mucous membrane, in their relation to skin diseases, were considered in the two papers presented. Many of the rarer affections were not discussed. The speaker said he had seen relapsing bullous eruptions in the mouth extending over a period of years, with erythema of the skin of the herpes iris type.

Cases of infectious dermatitis to which Dr. Engman had referred were frequently seen. We might have an infectious dermatitis of the vulva and thighs from a gonorrhœal vaginitis. Erythematous and urticarial types of eruptions were not uncommon in gonorrhœa, and the speaker said he had seen the gonococci in a tenosynovitis, which developed twenty years after the gonorrhœal infection. In the pus of this inflammation the gonococci were demonstrated.

He had seen perhaps a dozen cases of epithelioma develop from leucokeratosis. Some of the patients had been referred to him from Hot Springs, Ark., where they had been treated for syphilis. The lesions improved up to a certain point, and then the improvement stopped, showing that the syphilitic element was cured by the mercury and potassium iodide, leaving the malignant element unaffected.

Dr. ENGMAN, in closing, said that many of the conditions referred to in the discussion were covered by that portion of his paper which he had not had the time to read. This included gonorrhœal eruptions, herpes, Addison's disease, etc.

So many distinct entities were included under the term lupus erythematosus, that it was difficult to say just what was lupus erythematosus. The same was true in regard to eczematous conditions of the mouth. Therefore, unless we adopted a definite standard it was difficult to tell what we had to deal with. Picking the nose, which was mentioned in the discussion as a contributing cause of erysipelas and eczema of the nares, was often due to obstruction in the nose. People who had adenoids or other obstructive lesions *unconsciously* picked the nose, thus favoring a lasting and unavoidable habit, which can only be eradicated by the removal of the cause. Adenoids, deviated septum, hypertrophied turbinates are, therefore, closely associated, etiologically, with various diseases about the nose and lips.

REVIEW
of
DERMATOLOGY AND SYPHILIS

Under the Charge of JOHN T. BOWEN, M.D.

RADIO-THERAPEUTICS AND PHOTO-THERAPEUTICS.

By W. A. PUSEY, M.D., Chicago.

Mycosis Fungoides and X-Rays.

During the last year the evidence of the beneficial influence of X-rays upon mysocis fungoides has rapidly accumulated. There is a gratifying unanimity in the reports upon this subject. They leave no room for doubt that we have at last found a method of treating these hitherto absolutely hopeless cases, that is of positive and great benefit. It may be interesting to collate briefly the reports which have appeared upon this subject since the first report by Schültz, in the *Arch. f. Derm. u. Syph.*, February, 1902, that in two cases of mycosis fungoides the premycotic areas and small tumors disappeared entirely under exposures sufficient to cause superficial necrosis.

In a paper read before the Edinburgh Medico-Chirurgical Society, in January, 1904, Jamieson stated that the case treated some eighteen months before (reported in *Brit. Jour. of Derm.*, 1903, xv, p. 1 and abstracted in the JOURNAL OF CUTANEOUS DISEASES, 1903) still remained well, there having been no return of the exposed nodules, though some nodules had developed on parts of the skin which had not been subjected ot X-rays.

Stainer (*British Journal of Dermatology*, 1903, pp. 137, 212) showed at a meeting of the British Society a case of mycosis fungoides, which had been completely cured by X-rays.

Riehl (*Fortschritte auf dem Gebiete der Röntgenstrahlen*, 1903, VIII., pp. 41, 157) presented to the Vienna Medical Society a case of mycosis fungoides which had received absolutely no benefit from the usual methods of treatment, and was finally subjected to the X-rays. The tumors were exposed separately, some once, some twice, the dose given being three to five units, according to Holzknecht's chromoradiometer. (This dosage is also given as 20 minutes at 20 centimeters, with a medium tube.) The effect was practically the same on all the tumors. On the second or third day there was marked lessening of the secretion, and on the seventh or eighth day pigmentation of the vicinity which increased to a dark brown. With this the consistency of the tumor became more dense, the nodule contracted, and became covered with horny scales. In two weeks the nodules were one-third of their original size, in three weeks

they were so small as hardly to project above the surface, and in five weeks were entirely gone, leaving a smooth area surrounded by brownish pigmentation. Premycotic annular areas of erythema and infiltration also disappeared under the exposures, leaving pigmented surfaces.

In November Riehl reported that, since the previous report, in May, there had twice been appearance of new nodules, which had disappeared under X-rays.

Marsh (*American Journal of Medical Sciences,* August, 1903) reported a case of mycosis fungoides in the early stage, in which there were three distinct tumors on the neck and face, which was symptomatically cured with X-rays in December, 1902. The disease had begun two years previously, with the appearance on the back of the patient's neck of a small red point, which gradually enlarged in all directions until it became a large red patch, about two inches in diameter. After four years of this preliminary dermatitis, raised hard lumps appeared on the margins. Three years later the same process appeared on the nose, and six months before it was seen by Marsh a lesion appeared on the upper lip, which assumed an ulcerative character almost from the start. X-ray treatments were begun on September 23, and on December 31 the areas were symptomatically well, all that could be seen being a slight hyperæmia of the skin.

Hyde, Montgomery and Ormsby (*Journal of the American Medical Association,* January 3, 1903) reported a case of mycosis fungoides, in which the patient's body was more than half covered with characteristic thickened and scaling areas, some of which were approaching the tumor stage. All lesions treated with X-rays disappeared entirely or faded decidedly, while those not so treated remained or increased in size.

Ormsby (*Medicine,* December, 1903) reporting on the case previously described by him in connection with Hyde and Montgomery, stated that after a year of further treatment only twelve lesions remained. Every lesion treated had disappeared, and no recurrence had taken place in the treated areas.

Carrier (Journal of Cutaneous Diseases, February, 1904) has reported an extensive case of mycosis fungoides, with many tumors over the body and with intolerable pruritus. The treatment was undertaken in August, 1903, for the relief of the pruritus. The case was put under X-ray exposures in August, 1903, and in November was symptomatically well. The effect on the pruritus was prompt, and from the first the tumors rapidly disappeared and no new ones developed.

Brocq, Bisserie and Belot (*Ann. de Derm. et de Syph.,* 1904, p. 140) reported the case of a woman who had been affected with mycosis fungoides for twelve years. Many of the macules had been removed by excision, and the authors, after unsuccessful treatment with sodium cacodylate and pyrogallic acid, decided to attempt treatment with X-rays. This was successful beyond any expectations. Improvement was quickly manifested, and in such a way as to leave no doubt that it was the direct

result of the X-ray treatments. The disease now can no longer be recognized.

Lustgarten (Journal of Cutaneous Diseases, April, 1904) presented before the New York Dermatological Society a case of mycosis fungoides in a Russian, forty-one years old, which had been cured by X-ray exposures. The patient had had about one hundred hypodermic injections of arsenic, with some subjective relief, especially from the intolerable itching, but with no objective improvement. When the X-ray treatment was begun the lesions were scattered over the entire body. He had in all thirty-two exposures, a total of over five hundred minutes, at five inches distance. Practically from the first exposure the itching ceased. Dermatitis of the first degree was produced almost all over the body, which disappeared within a week with shedding of the epidermis, leaving a perfectly healthy surface. There had been no recurrence in any area which was treated to the point of dermatitis.

Elliot (*Journal of Cutaneous Diseases,* April, 1904) commenting on Lustgarten's case, described a case of mycosis fungoides which he had seen in consultation, which was given X-ray exposures after two years' unsuccessful treatment by various methods. Seventy-two exposures were given, with the result that all the lesions completely disappeared. The intense itching very quickly disappeared. There had been no return in this case.

Effects of Radium Upon Carcinoma Experimentally Produced in Mice. Apolant (*Deutsch. Med. Wochensch.,* 1904, XXX., 454.)

Apolant gives a short communication on the results obtained in the section for cancer research of the Imperial Institute for Experimental Therapie from exposure of carcinomata in mice to radium.

The animals experimented on were from two series, one the seventh transmission by injection of a very malignant carcinoma, which had formed numerous pulmonary metastases, the other the eighth transmission of a carcinoma equally rapid in growth which had not, however, formed metastases. The transmissions by injection, carried out for some time past in the Institute with most successful results, were made in accordance with the method of Borrel and Jensen; the larger part of the injected emulsion of the tumor being deposited at some distance from the point of insertion of the needle. There was immediate development of a tumor in this location, followed quickly in the great majority of cases by another at the point of insertion or at some other point along the path of the needle.

Of 13 animals of the first series injected with positive result, 7 were exposed to the radium, and of 19 of the second series 8 were exposed; the others serving as controls. The exposures to radium were commenced twelve to fourteen days after injection, and the frequency and length of

the exposures varied in the individual cases. The mice were immobilized, and the capsule containing the radium placed just in contact with the skin without pressure over the site of the tumor. (The average amount of exposure given was nine exposures of ten minutes, each within sixteen days.)

Of the nineteen tumors, ranging in size from that of a pea to that of a plum which were thus exposed, eleven disappeared completely and eight were reduced in size to an insignificant fragment of their original bulk. The retrogression began in some instances as early as the fourth or fifth day, and in almost all before the development of alopecia in the overlying skin. In most cases there occurred, after the production of alopecia, a superficial inflammation of the skin, with formation of small erosions and crusts, which in a few instances went on to deeper ulceration.

In two of the cases, in which there was not complete disappearance of the tumors, the exposures were stopped after six days for the purpose of microscopical examination; and, in another, the exposures were not commenced until the growth had developed to an advanced stage, though even in this instance the tumor decreased three-fourths in size.

Of the controls, in the first series two remained stationary after a certain amount of growth, and in the second series two were spontaneously absorbed, one remained stationary, and one showed only slight growth; all the others developed enormously within a month.

The fact that in some cases the last remnants of the tumors were quite refractory to the exposures was very probably due to the formation of a thick connective tissue capsule. This process was histologically noticeable very early, and its clinical manifestations were apparent in the extreme hardness of the tumor remnants.

X-Rays in Favus and Tinea Tonsurans. Sabouraud. (*Revue Prat. des Mal. Cut. Syph., et Ven.*, 1904, p. 35.)

Sabouraud reports his experience in the treatment with X-rays of a hundred cases of tinea tonsurans and favus. On the whole, the results are, in his opinion, very satisfactory. His technique is carried out with Gallic exactness, all possible devices for definitely regulating the intensity of the exposure being used. He gives exposures of as near definite strength as possible, and carries them to the point of producing alopecia with an evanescent erythema. And in order to prevent reinfection while treatment is being carried out, a twenty per cent. solution of tincture of iodine in alcohol is applied to the diseased area throughout the whole treatment. In his opinion, the reasons for the poor results that have attended the treatment of these conditions are that the epilation has not been complete in all of the areas, or the unaffected spots have been overlooked or that the precautions to prevent reinfection during the course of the treatment have not been carried out with sufficient vigor and accuracy.

INFLAMMATIONS.

By F. S. Burns, M.D., Boston.

Tuberous Iodide Eruption of the Face. (*Sur un cas d'iodisme tubereux du visage.*) Hallopeau et Vielliard. (*Ann. de Derm. et Syph.*, May, 1904, p. 441.)

The subject of the eruption, a female, sixty-six years old, had taken potassium iodide for an intense cephalalgia, resulting in a few days in a bullous eruption of the eyelids. With return of the cephalalgia from time to time, and a fresh administration of potassium iodide, the eruption became augmented, spreading to the face.

Nine months after the first outbreak on the skin, the patient entered the St. Louis Hospital, where her cephalalgia was considered to be of syphilitic origin, and she was given inunction and six grains of potassium iodide per diem. Six weeks later, fresh lesions appeared on the face; the older ones also became aggravated. All parts of the face were invaded by discrete and confluent tubercles, some partly annular in contour, others in masses attaining the size of a cherry. The eyelids and ears were equally affected. The tubercles were vegetative and purulent, and covered with prominent crusts.

It was remarked that such tuberculous and vegetative eruptions are expected more often from bromine than iodine.

The exclusive distribution over the face, and tendency to partial annular configuration, was thought worthy of particular notice, the latter characteristic suggesting a syphilide.

Epidermolysis Bullosa. (*Epidermolyse bulleuse congenitale.*) Hallopeau et See. (*Ann. de Derm. et Syph.*, April, 1904, p. 342.)

An infant, three months old, with unimportant family history, developed an eruption during the first weeks of life, affecting particularly the hands and face. There were two varieties of lesions.

(1) Clear, circumscribed bullæ, moderately tense, somewhat larger than a bean. Occasionally there was a hæmorrhagic bulla.

(2) Numerous white, pin-head size, milium-like papules on the dorsal surfaces of the fingers and hands. The larger of these appeared polygonal and flattened, and in places showed a tendency to linear arrangement. The palms were exempt. Bullæ were present on the soles of the feet. On the trunk were very small firm papules. The face, particularly the cheeks and chin, presented small acuminate vesicles with a faint erythematous base.

The small milium-like lesions were thought to be epidermic cysts, although they did not agree exactly in descriptions with reported cases.

Occurrence of bullæ following traumatism was not established, yet the skin of the elbow when stretched showed separation and detachment

of the epidermis (sign of Nikolski) indicating a special fragility of the prickle cell layer. (Acantholysis of Auspitz.)

A Case of Impetigo Circinata with Bullous Lesions on the Hands and Feet, and Subsequent Infection of the Nail Matrices. Adamson. (*Brit. Jour. of Derm.*, Vol. 16, No. 5, p. 165.)

A boy, five years of age, during convalescence from measles and pneumonia, developed a purulent otitis media, and an eruption of small pustules on the legs. When first seen there were annular lesions one-half to two inches in diameter, moderately numerous over the back, abdomen and thighs; sparse on the arms and legs.

The rings consisted of a central portion, surrounded by a narrow band of crusting epidermis. Between the rings were small vesicles. The vesicles, drying in the center and advancing at their margins, represented an early stage of the larger annular lesions. The outbreak almost disappeared under white precipitate ointment, but in three weeks returned even more extensively, involving the cutaneous surface generally. The eruption again healed. A paronychia developed in the fingers of the left hand, affecting the nail matrices and resulting in detachment of the nails. The toes were similarly affected.

Bacteriological examination showed the presence of the staphylococcus aureus and streptococcus pyogenes.

The impetigo and nail lesions were evidently caused by the same infection.

Epidermolysis Bullosa Hereditaria. (*Ein Beitrag zur Lehre von der sogen annten Epidermolysis Bullosa Hereditaria. Die Regenerationsbedetung der Retentioncysten in den Schweissdrüsen Ausfuhrungsgängen.*) J. Bukovsky. (*Archiv. fur Derm. und Syph.*, December, 1903, p. 163.)

Bukovsky distinguishes two varieties of this affection: the simple form, and the form leading to atrophy and degeneration.

The writer reports the following case: A young man, well until three years ago, when the disease began characteristically. There was nothing of importance in the family history. When he was first observed he presented bullæ of various size and in varying stages of development, disseminated over the trunk and limbs. Besides, there were atrophic cicatrices, small milium-like lesions, pigmentations, and involvement of the nails. The bullæ developed between the papillæ and epidermis, resulting in a separation of the epidermis. All other lesions present were secondary. Chemical irritation, the electric current, and X-rays had no effect on the skin. The bullæ never developed spontaneously. They always followed a trauma.

The patient died at the hospital of phthisis, after nearly two years' sojourn. At the autopsy nothing was found in the internal organs that suggested epidermolysis.

Bukovsky believes the bullæ are produced by a physical defect in the skin, perhaps an irregularity of contraction.

Histologic examination showed the cysts to be situated in the excretory ducts of the sweat glands, at a point where the duct is obstructed by an epidermic lesion. As a result of accumulated secretion the ducts become dilated, and cysts form, over which degenerated epidermis persists. Finally, a process occurs that causes formation of a new excretory canal.

Tuberous Fungoid Iodide Eruption. (*Zur Kenntinss des Jododerma tuberosum fungoides.*) Albert Schutze. (*Archiv. fur Derm. und Syph.*, March, 1904, p. 65.)

A female patient, æt. fifty-three, directly after the crisis of a severe lobar pneumonia, developed a generalized papular syphilide. She was treated at once by inunction and internally with four grams pro diem of sodium iodide for eight days, then with 1.5 pro diem for two weeks, without untoward symptoms. Ten days later a few pin-head to pea-size purulent vesicles, with a red halo, appeared across the bridge and alæ of the nose, which bore some resemblance to acne. In a few days the pustules had increased in size, almost entirely covering the sides of the nose and becoming especially prominent under the right eye.

The nose and neighboring cheeks were finally converted into a large fungoid mass. Four weeks after the sodium iodide was omitted the eruption had entirely healed.

Bromism, Gangrenous Form of. (*Sur une forme gangreneuse de bromisme.*) Hallopeau et Vielliard. (*Ann. de Derm. et Syph.*, May, 1904, p. 442.)

The patient, a woman, sixty-one years old, noticed an eruption on her skin eight days after taking potassium bromide. An erythematous efflorescence appeared over the inner aspects of the thighs and legs; a bulla developed over the left knee. The back of the left hand was red and swollen, and violaceous papules covered with blackish crusts appeared on the inner and lower portions of both legs.

There was an ulceration on the left leg, six by ten centimeters in diameter, with slightly elevated and very irregular borders. A network or gangrenous bands occupied the center of the ulceration, their black color appearing prominent in contrast with the red base of the ulcer.

The polymorphic character of the eruption, and the network of gangrenous bands, gave a particular interest to the case.

Relapsing Phlyctenulæ and Dermatitis Herpetiformis. (*Phlyctenose recidivante et dermatite polymorphe douloureuse.*) Carle. (*Ann. de Derm. et Syph.*, April, 1904, p. 353.)

Woman, æt. thirty-four, lace worker; history unimportant. Affected first when twenty-three years old, during her first pregnancy, with a gen-

eralized eruption. The affection in the beginning was erythematous in disseminated plaques, and very painful. Over the involved surface considerable vesiculation rapidly appeared. The general condition of the patient was bad. At this period the disease was considered to be Duhring's dermatitis herpetiformis.

In three months the skin regained a normal state, but a relapse occurred in a short time, followed again by healing and another relapse.

From 1890-1896 the patient was in the hospital for five different attacks, from four to six months each time.

In 1896, during another pregnancy, a more severe attack than the preceding occurred, this time beginning to affect the borders of the fingers with vesiculation surrounded by a deep erythema. The nails became involved, and began gradually to exfoliate. From this time on, the attacks were always accompanied by involvement of the fingers, the digital lesions remaining persistently, and in a short time resulting in complete exfoliation of the nails. For the past five years the condition of the fingers has remained stationary.

The affection was in no way influenced by the treatment.

BOOK REVIEW.

Thérapeutique des Maladies de la Peau. By Doctor Leredde. (*Masson et Cie.*, Paris, 1904.)

In this book of over seven hundred pages, the author has covered the whole field of dermatological therapeutics, taking up, one after another, the different forms of cutaneous disease. The book is interesting to the reviewer as a pleasant change from the succession of text books that have followed closely on one another's heels during the last ten years. The solely therapeutical field has not been essayed before, so far as we know, with the exception of Leistikow's book, which treated the subject, however, in a very different manner.

In the preface, the author declares his intention of grouping the various procedures of dermatological therapeutics in the form of general methods, which are afterwards to be applied in each particular case. His aim, he asserts, is to cull the best from the various methods without adding to them; hence few new formulæ are to be found.

The book is divided into two parts: the first dealing with general therapeutics, and the second with special therapeutics.

Under general therapeutics, separate chapters are devoted to the methods classed as aseptic, antiseptic, antiphlogistic, keratolytic, reducing, exfoliating, caustic, and scleroginous. All of these methods are discussed at considerable length, and the various remedies used are enumerated. The writer's personal experience is freely referred to, and always lends an added interest. Many procedures common in the best dermatological centers do not receive approval in this work; for example, with regard to the removal of crusts, the author considers that by far the best results are obtained by means of spraying with sterilized water; and the common practice of using boracic acid in such conditions is condemned.

Under the scleroginous method is to be found an interesting discussion of radiotherapeutics and photo-therapeutics.

In the chapter on internal treatment, a refreshing conservatism is maintained, the author confining himself, as a rule, to the procedures and drugs that have shown themselves of real value. It is interesting to note in this chapter that the conception of "diathèses," so long held to by all the French school, is forced into the background. The writer confesses that the idea of "herpétisme" ought to disappear entirely.

The chapter on hydromineral medication will be found valuable as a reference, as the writer offers much valuable information about the various French springs and their indications.

The second part of the book is devoted, as has been said, to special therapeutics, and various skin diseases, even those of rarest occurrence, are discussed one after another. A considerable portion of this part of the book is taken up by a clinical description of the disease under discussion, which adds to the bulk of the book without, in our opinion, increasing its value. A few words, to make clear just what the affection under consideration is, would, in our opinion, have been sufficient. The writer has rigidly adhered to his determination to resist the temptation of full enumeration, selecting only those things which have proved of universal value or which appeal to him personally.

By no means the least interesting part of the book is its appendix by Pautrier on *Formulaire Thérapeutique.* An extremely interesting and valuable description of the various forms of pastes, powders, and ointments, etc., is given, with a number of formulæ illustrating their use.

On the whole, the book is to be recommended to the dermatologist, or practitioner with special interest in cutaneous medicine, not only for present reading but as a useful book of reference. It is refreshing to find the subject of therapeutics approached in a scientific manner, as is done in this book, where methods and their indications are accorded the most prominent place, and where we are not assailed with a long list of formulæ to be used haphazard. J. T. B.

ERRATUM.

Instead of "Toxicogenic" in the third line from the bottom of page 369, August issue, read "Tocogonic."

PLATE XXXVII.—To Illustrate Dr. Grover W. Wende's Article.

THE JOURNAL OF
CUTANEOUS DISEASES
INCLUDING SYPHILIS

VOL. XXII. OCTOBER, 1904. No. 10.

RHINOPHYMA—A PATHOLOGICAL ANALYSIS OF FIVE SEPARATE TUMORS OCCURRING IN THE SAME PATIENT.

GROVER W. WENDE, M.D., AND CHARLES A. BENTZ, M.D.

Read before the twenty-eighth annual meeting of the American Dermatological Association, Niagara Falls, June 2 and 3, 1904.

N. T., age sixty-nine; under observation since 1892; had lived in the United States for forty years.

Previous History. The patient was born in Germany, and, as his parents stated, "was hardly worth bringing up." When nearly twenty he began to drink hard cider. After this had been kept up for a time, he observed that the tip of his nose began to redden, which condition gradually increased and that the cheeks became unnaturally red after drinking. The congestion seemed to be influenced by changes of temperature, over-feeding, or the use of hot tea or coffee. The condition soon became permanent and was speedily followed by the appearance of pustules and papules, disseminated over the face. This state of things went on for many years. The patient soon noticed, for the first time, the peculiar bulbous enlargement which gradually progressed much to his satisfaction, as he was laboring under the delusion that, so long as this particular condition existed, he would be proof against other diseases. He always indulged in drink, beginning with cider, then dallying with beer and finally becoming a royal subject of King Alcohol. He was a well-known character of Buffalo for many years, during which time he was under professional observation. His case was finally reported in the *Buffalo Medical Journal* by Dr. Ernest Wende. When the tumor formation had reached its greatest size the measurements were as follows: largest diameter from base, four and

three-fourths inches; transversely, three and one-fourth inches; at right angles with the face, three inches—besides there were eight smaller tumors situated about the tip of the nose, the largest of which was nearly round and was one and one-half inches in diameter. The smaller ones were sessile, while the larger two had pedicles and would oscillate at every movement of the head.

The photograph represents the patient three years later, when he presented about the same appearance, except in the larger tumor, where there was atrophy of the epidermal layer of the skin, located in the front portion of the growth, together with the disappearance of the outer layer. The remaining surface of the large tumor continued to be characteristic of rhinophyma. There were large depressions corresponding to the dilated glandular orifices, some of which were obstructed by comedones. These openings varied in size from one-half to three mm. Upon pressure, there would sometimes appear a sebaceous plug, and, at other times, a seropurulent liquid. This was especially true of the large tumor, which would gradually refill and plentifully discharge. The color varied; at times the tumors whitened; at others, after spirits had been indulged in, they became red; the same hue was also imparted by cold. For a number of years there were no acne lesions; only a few dilated blood vessels could be discerned. The tumors were cold and felt greasy to the touch, and the overhanging mass interfered with both eating and drinking.

No definite course of treatment was ever followed out, on account of the stubborn caprices of the patient, so that the condition continued to develop almost without interference. After matters had progressed to a point where the patient was obliged to admit that his physical powers were failing, he manifested his characteristic independence by consulting first a witch and afterwards a clairvoyant. This was continued until he passed into a comatose condition, when Dr. Henry G. Bentz was called to his aid. His notes of the case follow: "Called to see patient March 1st, 1902; condition semi-comatose; an indurated mass between xyphoid cartilage and navel, possibly due to some irregularities of the liver, but probably cancerous; œdema of the legs; emesis; jaundice; slight pigmentation of the skin; mass painful to the touch; patient passed gravel stones about the size of a split pea, pains accompanying passage; case diagnosed as cirrhosis of the liver with possible cancer of the stomach." Patient died April 12, 1902. No autopsy permitted. Eight hours after death, five tumors were removed and subjected to various fixing agents.

Pathological Histology. Five different tumors were examined, in-

cluding the largest, the smallest and the most mature; the latter being about twenty-five years old and the newest about six months. By means of sections taken from these one could follow the process of formation and the subsequent changes.

An examination of the smallest tumor revealed numerous changes, the most striking of which was the enlargement of the sebaceous glands. This enlargement was cystic, due to hypertrophy and dilation of the excretory duct, probably caused by retained secretions, as well as the active hyperplasia of the glands. The lobules were very large, at times subdividing and surrounding the ducts. The sebaceous glands occupied the superficial portions of the skin, and its warty and irregular aspect was due in part to this fact. The sebaceous glands also occupied the deeper portions and showed marked hypertrophy and complexity; very few revealed connection with the hair follicles. The length and dilation of the execretory sebaceous duct were striking.

Another marked feature was the hypertrophy of the connective tissue. There was a decided change in the blood vessels, which were dilated and augmented. The walls were thickened, a fact due to hypertrophy. There was dilatation of the veins, which sometimes showed thin walls.

In the hypertrophic connective tissue was deposited a marked round-cell infiltration. This often extended from the epidermis to the subcutaneous tissue. There were also isolated areas apart from the glandular structure around blood vessels. The superficial layers of epithelium along the whole section were hypertrophied and, in places, showed a cellular infiltration. They were nowhere detached from the rete, which manifested no involutions and hardly a suggestion of papillation. The latter, however, played only a passive part in the process. The irregular aspect of the skin was due in part to the enormous increase in both the size and the complexity of the sebaceous glands. In the mass which made up the corium, there was a distinct round-cell infiltration around the blood vessels, sebaceous glands and the area of inflammation, which took the hæmatoxylin stain very deeply. In places where acute inflammatory reaction had occurred were found many plasma cells. These were located in the connective tissue, in close relation to the blood vessels. There was a marked disappearance of elastic tissue fibers. No mast cells were discernible. Stained by Gram, both micrococci and small bacilli were found, the latter agreeing in size and shape with the bacilli described by Gilchrist[1] in

[1]Gilchrist. "Etiology of Acne Vulgaris." Jour. Cutaneous Diseases, 1903, p. 107.

acne vulgaris. Many of the ducts were filled with circumscribed areas of bacteria. Surrounding these, a marked hyperkeratosis was noticed and there was some inflammatory reaction in connection with the keratinized layers.

A section from the second smallest tumor stained with osmic acid gave the following results: The epidermis had undergone passive changes, owing to the pathological process which had taken place in the sebaceous glands. This epidermal layer was about twice its normal thickness, due to an admixture of fat with the cells themselves. The epithelial border was compressed, much shortened or entirely obliterated. The stratum mucosum was somewhat thickened and some of the edges showed proliferation. In this layer there was also a deposit of fat, undoubtedly due to degeneration of the cells. This was found where the papillæ had disappeared. In certain areas there was an independent deposit of fat in the cells themselves. This condition would often affect all the layers. The outline of the cells was well preserved. There was an increase of pigment in the rete Malpighii cells of the lower layer. The horny layer was thickened, especially around the hair follicles and their orifices. This readily took on the osmic stain, showing that hypertrophy was not wholly due to the cells themselves, as their outline was fairly well unstained, but partly to a deposit of fat from the glandular structure.

A section from the third tumor presented features similar, with a few exceptions, to those described. The epidermis was thin; the basal cells of the rete revealed a dark pigment. In places, the epidermis contained collections of micrococci, which showed some relation to the mouths of the sebaceous glands. In most places the papillæ had entirely disappeared. Of the sebaceous glands, those located superficially were the only ones remaining. The lobules were very large and mostly filled with large polyhedral cells. There were a few deep sebaceous glands surrounded by a dense infiltration. Within the fat glands were found masses of bacteria surrounded by a marked hyperkeratosis. The corium was composed of dense fibrous tissue with diminished elastic tissue. In places there was a marked cellular proliferation about the glandular structure and the blood-vessels. The blood-vessels were increased and thickened in some places, and dilated in others, and were invariably surrounded by dense cellular proliferation. Besides leucocytes, an unusual number of plasma and mast cells were found, the former following the capillaries. In the entire tumor wherever there was newly-formed connective tissue, the columniæ adipose had been obliterated and was replaced by fibrous tissue. Micrococci were found in the glands and their ducts.

The fourth tumor, the second largest, measured about one and one-half inches in length and one inch in diameter. The section included the entire growth and underlying tissue. This also included a spot of surface gangrene. The corium was made up of dense connective tissue of the white fibrous variety, in connection with which many fibro-blasts were found. The tissue was well supplied with blood-vessels, increased in number, dilated, thickened and often filled. There was a collection of lymphocytes and plasma cells about the blood-vessels, most distinct in the papillary portion of the corium and in close relation to the gangrenous spot. The infiltration was, at times, seen in the vicinity of the sebaceous glands. At other times a dense fibrous tissue occupied the place. The sebaceous glands were about half the size of those previously found and were located beneath the epidermis, showing a remarkably large duct, cone-shaped and very short, the apex leading to the gland itself. The remaining glands were not connected with hair follicles. Evidence of their activity was not so marked as in other sections, known by the fact that there was not nearly as much sebum in the gland itself, neither was the gland epithelium so well formed. Situated deeply in the tumor was a large cyst filled with fatty material. The characteristic morphology of the sebaceous gland had disappeared with the obliteration of the duct. The pigment varied from light brown to black brown. It occurred in irregular-shaped cells in the form of fine or coarse granules, found throughout the tumor. In places, were large collections. Large irregular cells containing considerable brown pigment were found throughout the entire tumor, often seen just below the epidermis; also much pigment in the epidermis. Very few mast and plasma cells were discovered, and they showed no relation to the blood-vessels or the glandular structure.

In places, elastic tissue was found, especially in the deeper portions of the corium. In the papillary portion, as well as in that which was affected by acute infiltration, it was scarcely visible.

In the fifth tumor, the largest, a remarkable increase of fibrous tissue was noted, especially in connection with the blood-vessels and sebaceous glands. Undoubtedly it was this increase that obliterated the deep-seated glands. The fat layer was replaced by dense fibrous tissue. The changes in the epidermis were much more prominent than in the previous tumors. In portions, all the layers of the epidermis were absent, principally due to a superficial necrotic area, the débris of which consisted of bacteria, leucocytes and broken down epithelium, which took on the stain poorly. The bacteria and leucocytes promptly responded to the stain. At the places not affected by this condition,

the epithelium showed a tendency to thicken. The necrotic area seemed to have been located at the mouth of a sebaceous gland. In the rete Malpighii the cells of the deepest layer had undergone an unusually rapid multiplication; penetrating deeply into the underlying tissue; in fact, the basal membrane of the entire section had a suspicious look, resembling carcinoma, although the penetration of epithelium was much like the condition found in chronic inflammation with ulceration. The necrotic mass was found to be made up of micrococci and a few bacilli. The usual characteristic structures of the corium had disap-

Section through a portion of the circumference of the largest and oldest tumor, showing that it mostly consists of connective tissue with complete obliteration of the sebaceous glands. Hypertrophy of rete and partial disappearance of the epidermis.

peared, merging into a dense white fibrous tissue which extended downward, replacing the subcutaneous, cellular and adipose. The walls of the large blood-vessels showed a distinct hypertrophy. There was a marked round-cell infiltration following the course of the blood-vessels, although, at times, showing no relation to them. Portions of the tumor revealed a deposit of isolated fat cells, irregularly extending into the fibrous tissue. Surrounding this peculiar condition was a round cell infiltration. There was very little elastic tissue; in the localities occu-

pied by the cell infiltration it had wholly disappeared. The sudoriferous and sebaceous gands were reduced to a remnant. The lining membrane was more or less homogeneous and was enclosed in a dense fibrous envelope. The gradual formation of fibrous tissue had the effect partially to strangulate the gland. This condition was also surrounded by a round cell infiltration, and, in portions of the papillary layer where the sebaceous glands had disappeared there was such infiltration, many of the large blood-vessels being filled. Numerous irregular cells were found in the tissue, containing a brown pigment, corresponding to those found in the other tumors. The stratum corium was abnormal. The stratum mucosum was about normal, with the exception of a large increase of pigment, the papillæ having entirely disappeared. Examination of a section taken from another portion of the tumor showed that the corium consisted of a vascular fibrous tissue; in places the blood-vessels were surrounded by a dense round-cell infiltration, especially in the papillary layer. The arteries and veins showed a marked hypertrophy of the walls and, as usual, the blood vessels were filled. In the center of many of these circumscribed infiltrations the cells were so dense that they took on the stains poorly, strongly suggestive of abscess formation. A few of the sebaceous glands remained, but seemed to be preparing to disappear. These were surrounded by cell infiltration. In a section two inches long and one inch wide there were only three to be seen. There were also found many of the large irregular pigment cells. In portions of the section the epithelium was wanting, the vacancy being supplied by a necrotic mass. The débris was made up of serum, leucocytes, epidermal cells and bacteria, mostly consisting of micrococci. In portions, the epidermis penetrated deeply into the corium. In another part of the same section the papillæ had entirely disappeared; there was an increased amount of pigmentation in the lower cells. A few mast and plasma cells were found throughout the papillary portion of the corium, and more in the deeper portion; although a great many other cells of irregular size were found containing the black-brown pigment.

Before summarizing the histological changes found in the examination of these five tumors, it will be of interest briefly to review the more common opinions which have been given in relation to the histopathology and etiology of rhinophyma.

The first report on the microscopical examination was made by Simon,[2] who claimed that the growth was made up of connective tissue,

[2]Simon Gustav. Die Hautkrankheiten durch anatomische Untersuchungen erlaut, Berlin, 1851.

traversed by large blood-vessels and revealing sebaceous glands of considerable size, filled with hardened sebum.

The pathological process was investigated by Virchow,[3] who thinks that acne indurata may be identical with rhinophyma. He describes it as an advanced stage of acute rosacea. The skin surrounding the sebaceous glands was found to be thickened.

Hebra[4] is the one from whom the disease derives its special designation of rhinophyma, which he classifies with rosacea. His findings are a connective tissue, new growth; many dilated blood-vessels; the sebaceous glands numerous and enlarged. He considers the fibrous tissue as cutting off some of the acini from the rest of the gland. As the secretions continued the glands multiplied, while the retained sebum, by means of its irritation, created new growth.

Piffard[5] makes a histological report on a tumor weighing one ounce, which consisted of connective tissue, with thickening of the rete. The sebaceous glands had undergone degeneration where they were pressed by the fibrous tissue.

Biesiadecki[6] found alterations of the sebaceous glands, accompanied by hypertrophy, enlargement and the formation of new blood-vessels.

Lesser[7] declares that the chief anatomical changes of rhinophyma are the enlargement and cystic degeneration of the sebaceous gland, around which is established an inflammation following hypertrophy of the connective tissue. He considers this new growth as cystic adenoma-fibroma, generally due to external irritation affecting the sebaceous glands.

Unna[8] treats rhinophyma as a condition following so-called rosacea seborrhœica, classifying it with seborrhœic eczema, which may be considered as a seborrhœic catarrh, resulting, first, in fibromatous growth, and, second, in hypertrophy of the sebaceous glands.

Leloir and Vidal[9] have defined two variations of rhinophyma, in one

[3]Virchow, R. Die krankhaften Geschwulste, Berlin, 1864-67.

[4]Hebra Ferd. Atlas der Hautkrankheiten, Heft VIII, Taf. 6.

Hebra Ferd. Versuch einer auf pathologische Anatomie gegründeten Eintheilung der Hautkrankheiten. Zeitschrift der k. k. Gesellschaft der Aerzte Zu Wein. Zweiter Jahrg. Bd. I., 1845, pp. 148, 211.

[5]Piffard, Henry G. Archives of Clinical Surgery, 1876 and 1877, Vol. I., p. 21.

[6]Biesiadecki. Pathologie und Therapie der Hautkrankheiten, von M. Kaposi, Wein and Leipzig, 1883.

[7]Lesser. Lehrbuch der Hautkrankheiten, 1895.

[8]Unna, P. G. Histopathology of the Diseases of the Skin, 1894, p. 237.

[9]Leloir and Vidal. Recherches anatomiques sur l'acne. Société de Biologie, 1882.

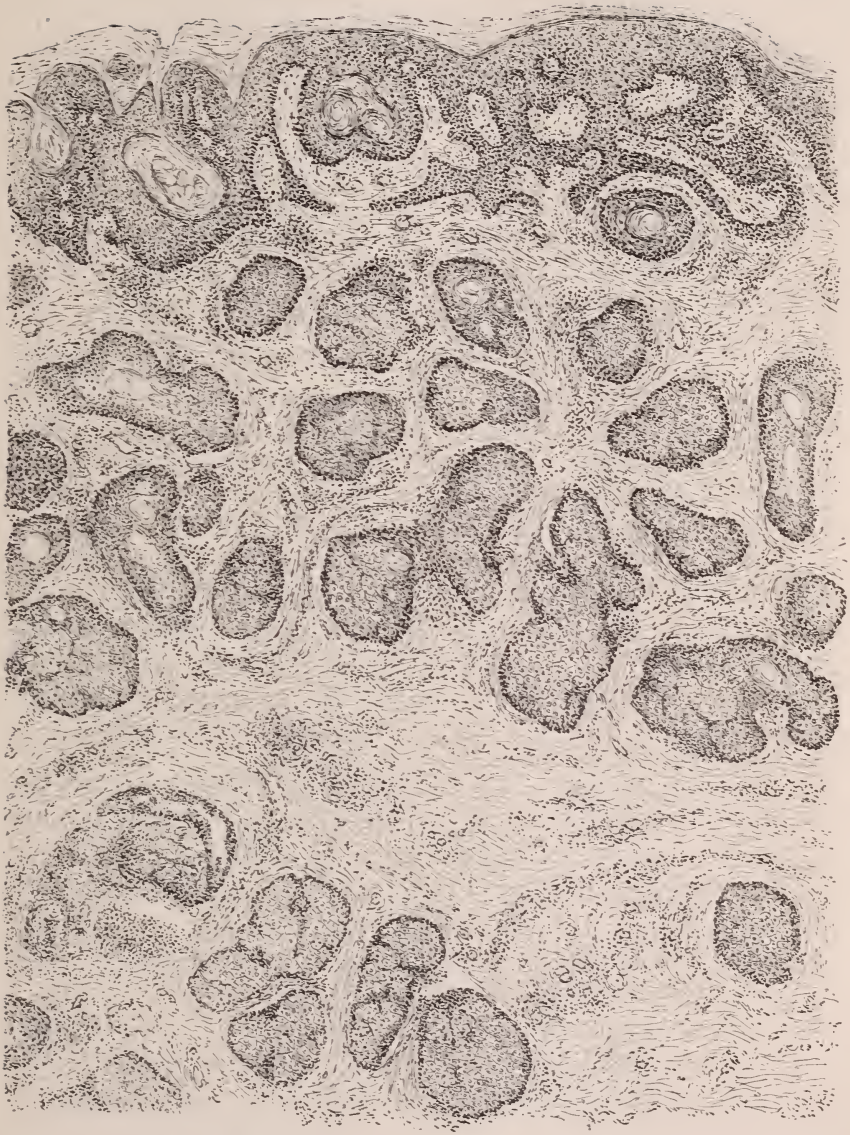

Section through the smallest and most recent growth, enlarged sebaceous glands normal in number, corium hypertrophied with many collapsed blood vessels, rete normal, epidermis hypertrophied.

of which the glands are very numerous and the connective tissue sclerosed and often slightly vascularized; the other they consider as belonging to the elephantiasic variety, in which the dermic sclerosis predominates, ordinarily accompanied by considerable vascular dilatation, and in which, exceptionally, the sebaceous glands may be lost entirely.

Dohi[10] considers the first change as vascular, due to an angioneurosis. He questions the formation of new blood-vessels and says that hypertrophy of the sebaceous glands is always present, although without increase. He considers the term adenoma wrongly applied. While portions show a fibromatous structure, round cells are constantly present, as well as an abundance of gelatinous substance which separates the connective tissue strands. He considers this separation typical of the lobulated growth, it being angioneurotic rather than the result of other changes. The changes in the glands, the dilatation of their ducts, and the keratinization of the secreting epithelium are to be considered as primarily vascular.

Solger's[11] findings are similar to many of the others. The principal feature of the pathological changes was a pronounced hyperplasia of the sebaceous glands. Around these glands the blood-vessels were dilated, and associated with them was a dense cell infiltration; many of the cells were plasma cells. He considers that the glandular hyperplasia is determined by alterations in the blood supply. He notes the common association of angiomatous changes and proliferation of the sebaceous glands, and though aware that angioma may occur without hyperplasia of the glands, he still thinks there is some relation between telangiectasis and increased vascularity, and that this may show some relation of the blood supply with the development of rhinophyma.

In Bulkley's[12] treatise on Acne he divides acne rosacea into stages—first, the stage of congestion, which probably causes the seborrhœa oleosa; second, an advanced condition with dilatation and varicosity of blood-vessels and the formation of new ones, together with round cell infiltration about the follicles and blood vessels; third, transition from congestion and inflammatory exudation to organization, exhibiting various degrees and conditions both in different cases and at different periods. In addition, he has suggested enormous hypertrophy of the

[10]Dohi, Ein Beitrag zur Kenntniss des Rhinophyma. *Archiv für Derm. und Syph.*, Bd. XXXVII., 1896, 3 Heft.

[11]Solger, Ueber Rhinophyma, *Archiv. für Derm. und Syph.*, 1901, Bd., LVII., 1901, 3 Heft.

[12]Bulkley. Text-book on Acne and its Etiology, Pathology and Treatment. New York, 1895.

skin of the nose, especially of the connective tissue, and the consequent formation of fleshy excrescence.

All observers of the affection agree that its anatomical structure consists of dilatation of the blood-vessels, leading to the new formation of connective tissue and hypertrophy of the sebaceous glands. We have thus been able to compare the histology of our case with the reports of others. The discrepancy in the microscopical findings may be due to the limited material one has for examination, as the showing stage of the disease presenting itself in this case necessarily varies according to the development.

The microscopical examination of the blood-vessels yielded results analogous to those obtained by Hebra and others. The blood-vessels showed dilatation, varicosities and thickening. The formation of new-blood vessels was noted. This last may not be easy to confirm, nevertheless endothelium cell-proliferation around the blood-vessels was demonstrated in many instances. The mast cells appearing near the location of the blood-vessels were greatly increased and indicative of marked proliferation. While former examinations led to the theory of new formation corresponding to the observations of Hebra, Biesiadecki, Bulkley and others, more recent investigators incline to the views of Dohi, who doubts the formation of new blood-vessels, but admits the dilatation and varicosity of the existing ones. The state of the blood-vessels is undoubtedly very important in connection with the pathological condition, as it governs the incipient stages. Whence the dilatation proceeds cannot be deduced from histological examinations; it may be referred back to an angioneurosis which produces a hypersecretion of the glands. Changes in nutrition must be expected in the locality where dilatation occurs. The greater cornification of the epidermis, which manifests itself clinically as scale formation, may be considered an anomaly of nourishment, and the finding of a bacillus may suggest a mechanical cause producing marked cornification of the epithelium. Whether the rete growths of the epithelium can only be traced to anomalies of nutrition, or whether the concomitant inflammation may not have an etiological significance, cannot be determined easily. The abundant proliferation of epithelium may argue its participation in the inflammatory phenomena. These rete growths would then stand in analogy with the epithelial growths observed in the examination of the chronic inflammatory process undergone by the large tumor. The changed sebaceous glands of the similar tumours are distinguished from the normal in nothing except dilated excretory passages and increased gland formation. There is no numerical increase, consequently the term adenoma is wrongly applied.

This point was confirmed by an examination of normal skin taken from the various regions of the nose, where, in the natural condition, more sebaceous glands exist, and those unusually large, having sometimes as many as twenty acini. There is no difference between the hypertrophy and the dilated duct. The question arises whether the increase in volume of the gland may not be due to a micro-organism which lodges in the acini, causing a hypertrophy. A typical connection exists between the increase of blood-vessels and the hypertrophy of the sebaceous glands.

The fibrous tissue existed throughout the tumor, and was equally distributed, but was more dense in certain areas, especially in the vicinity of the sebaceous glands. This varied in color from white to gray; in many places it was of a cicatricial consistency. Judging from the microscopical description, there was extreme hypertrophy of the connective tissue of the corium. The tissue element arises from the increased and dilated blood-vessels. The young tissue, however, appears to possess little tendency to change into fibrous. The young connective tissue may be discovered in the fibromatous new growth. With this the changes would be limited, which may be secondary to the changes in the blood-vessels, thus accounting for the progressive tissue formation.

There is no doubt that the hypertrophy of the duct of the sebaceous glands, together with the round cell infiltration, caused pressure which interfered with the elimination of the gland secretion. The stoppage in the excretory passage of the sebaceous gland occurred not only from stagnation in the secretion, but from a cell proliferation. The epithelium was stratified. In close relation to the cells of the connective tissue were found migratory cells of unusual size. These presented distinct types, undoubtedly leading to the development of granulation and young cicatricial tissue, which proliferates, ending as sclerosed connective tissue and scar tissue which increase and continue to change, and which may account for the large cysts by cutting off the duct.

The mast cells were increased in number but, considering the enormous proliferation of other connective tissue cells, seemed about normal. The plasma cells were of the large variety. No eosinophiles were discovered. Many irregular pigmented cells were found in the tissue, probably migratory.

The conclusions here arrived at comply with the latest interpretations of this disease; nevertheless there are many points unexplained; for instance, rosacea is comparatively a common disease, but extreme cases are rare, and the variations in the hypertrophies themselves continually vary, for the process may stop at any stage. Again, only the

skin of the nose may be involved in the process of rhinophyma, while rosacea attacks adjacent portions. One of the most striking features of the disease exists in the fact that while rosacea is more common in women than in men the hypertrophic stage hardly ever occurs in women. There is but one instance of the kind, which is reported by Crocker, that of a woman of fifty-one who had a tomato-sized tumor on the tip of the nose. Another etiological fact is connected with drinking, as has been proven in our case; nevertheless there are many who drink without inviting any reflex condition in the face, while in others it only amounts to a transient congestion. Again, in some cases the condition of telangiectasis ensues, in others, that of rosacea without hypertrophy.

It is hard to tell whether the infection has anything to do with the process, although some authors seem to find bacteria in the ducts of the tumors leading to rhinophyma. The same thing is true with the duct where there is no hypertrophy. If the bacillus may be considered as an etiological factor in the production of seborrhœa, comedones and the acne pustule, it also may be regarded as an influence in the alteration of the sebaceous glands in connection with the development of rhinophyma.

ETIOLOGY.

I. Angioneurosis:
- Telangiectasis (Period when nose and face flushed).
- Alcohol.
- Stimulants (Tea, Coffee, etc.).
- Indigestion (Chronic Catarrh).
- Auto-intoxication (Lowered resistance).
- Occupation.

A period intervened when there was no acne, only flushing of the skin, face and nose, becoming permanent.

PATHOLOGY.

II. Acne:
- Super-abundant nutrition } Increased secretion and
- Auto-intoxication } elimination.
- Infection (Probably due to acne bacillus (Gilchrist).
- Inflammation (Acute (glandular).
- Inflammation (Chronic (periglandular).

III. Tissue Production (periglandular).

Changes | deformity, cysts, etc., anæmia, necrosis, etc., vascular.

DISCUSSION.

Dr. Thomas C. Gilchrist said that he had rarely seen rhinophyma in Baltimore, so that he was not able to discuss Dr. Wende's paper. The bacillus of acne was apparently often present in the ducts of the sebaceous glands all over the face. In any section of the skin of the face, this bacillus could often be found in the mouth of the sebaceous glands.

Dr. Fordyce asked Dr. Wende if he looked for the demodex in the ducts of the sebaceous glands? Dr. Holder made some investigations along this line, and on three or four occasions found the ducts obstructed by the demodex, and the question arose whether they might not be a factor in preparing the soil for suppuration.

He recalled one case of extensive suppuration of the back, in which there were large papulo-pustules, like those met with in the suppurative type of rosacea, in which the demodex were present in large numbers. This might be a more important factor than is generally supposed.

Dr. James C. White would ask Dr. Fordyce if the demodex was not quite as common in the perfectly normal glands of the skin? If he scraped the face or forehead of the students in his class, would he not probably find the demodex in a large proportion of the number? He thought it would be a rather difficult matter to establish any connection between the demodex and acne rosacea.

Dr. Fordyce said that while the demodex was possibly present in a large number of apparently normal glands of the skin, as Dr. White suggested, still it might be an etiological factor in producing suppuration. It was a pathogenic organism in certain animals.

Dr. Gilchrist said that Dr. Hemmeter, of Baltimore, had made the suggestion that the demodex might represent minute flies in a larval stage. He had never made any investigations along this line, but the observation was certainly an interesting one.

Dr. Grover W. Wende, on closing the discussion, said that there was no special search made for the demodex folliculorum in the case under consideration. They were sought for a few years ago in connection with a case less pronounced. He agreed with Dr. Gilchrist that the finding of bacteria in the skin did not mean very much as a possible cause of this disease. But the finding the short, thick bacilli in large numbers in the ducts of the sebaceous glands, invariably surrounded by a marked hyperkeratosis, certainly had a local effect; but whether this fact had any pathological significance it was hard to say.

AN INQUIRY INTO THE ETIOLOGY AND NATURE OF THE TOXIC ERYTHEMATA.

Jay F. Schamberg, A.B., M.D.

Read before the twenty-eighth annual meeting of the American Dermatological Association, Niagara Falls, June 2 and 3, 1904.

THE cutaneous manifestations of the erythema group of skin diseases are so protean and varied that a satisfactory classification appears well nigh impossible in the present state of our knowledge.

The close relationship between urticaria, the various erythemata and purpura is recognized by most writers. It is known that these may occur as associated phenomena or at different times in the same individual as the result of the operation of the same cause. For purposes of classification and study it is still desirable to retain these different clinical types.

But if the cutaneous features of this group are varied, what must be said of the almost infinite variety of causes that give rise to them? A classification based upon etiological considerations would appear to be beset with even greater difficulties.

It would seem possible, however, to correlate certain facts in connection with the causation of these phenomena which might tend toward generalization and simplification rather than analysis and differentiation.

The variety of causal agents that produce the different expressions of the erythema group is almost legion. The commonly attributed etiological factors may be briefly set forth as follows:

Crocker includes among the causes of *urticaria* bites of insects and certain other local traumatisms, various food stuffs and medicines taken into the alimentary canal, worms, chronic intestinal catarrh, absorption of hydatic fluid, dyspepsia, the gouty diathesis, functional and organic disorders of the utero-ovarian organs, etc. Leeches to the os and the passing of a sound are given as examples of direct irritation to the uterus causing urticaria. Urticaria may be associated with asthma, gall stones, colic, diseases of the nervous system, albuminuria, jaundice, glycosuria, rheumatism, purpura and intermittent fever.

Other causes suggested by writers are surgical operations, particularly upon the abdominal cavity, dentition, the exanthematous fevers, etc.

Erythema multiforme. Crocker believes erythema multiforme to commonly result from chilling after being overheated, particularly among gouty and rheumatic subjects. Lewin and Kaposi state that it may occur as the result of urethral irritation from gonorrhœa or instrumental erosions. Hebra, Pick and others regard uterine disturbances as provocative in some cases.

Duhring believes that in many cases it is a disease of systemic origin and that it is favored by certain atmospheric conditions. In the other cases he states it may be due to irritating ingesta. Stelwagon regards the absorption of intestinal toxins as an all important factor.

Many writers look upon erythema multiforme, particularly the graver types, as a general infectious disease, and epidemics are cited to prove this view. Potassium iodide, copaiba, coal tar preparations and other drugs have produced attacks.

Scarlatiniform erythema is said to result from intestinal autoinfection, from the ingestion of such articles as shell fish and spoiled meats, from digestive derangements, after operations and injuries, in the course of malaria, rheumatism, smallpox, sewer gas poisoning, peritonitis, empyema, abscess, uremia; from the administration of mercury, copaiba, quinine, belladonna, salicylic acid, etc., etc.

Purpura may occur in the course of almost any of the infectious diseases. It is common in rheumatism, malaria, smallpox, typhus and measles. It may also result from profound anæmia, scurvy, hæmophilia, syphilis, influenza, nephritis, cirrhosis of the liver, etc. Osler observed purpuric outbreaks with particular frequency in patients suffering from kidney disease.

It would appear eminently desirable if possible to classify the kinds of poisons which give rise to the group of diseases under consideration. The following classification is tentatively suggested:

1. Bacterial and protozoal toxins.
2. Ptomains.
3. Leucomains and other metabolic poisons.
4. Drugs.

I. Bacterial and protozoal toxins. The presence of specific toxic substances in the blood in infectious diseases is well recognized. It would appear that at least some of the eruptions in the following diseases are due to bacterial and protozoal toxins. Scarlet fever, measles, rubella, smallpox, typhus, influenza, pneumonia, malaria, gonorrhœa, rheumatic fever, cholera, typhoid fever, etc.

Some of these eruptions are known to be eliminative and to contain the causative agent of the disease. There is conclusive evidence,

for instance, that the *causa causans* of smallpox is resident in the variolous pocks for the disease may be inoculated with fluid taken from them. But the prodromal morbilliform, scarlatiniform and purpuric rashes are probably produced by toxins.

The roseola variolosa has its analogue in the roseola vaccinosa which occasionally appears about the tenth day of the vaccine disease.

The rashes seen in vaccinia, variola and malaria may possibly be the result of the action of protozoal toxins. Neuhaus and Singer have found Eberth's bacillus in cultures from the blood of typhoid spots and this eruption would appear to be microbic in character, although some negative results have been recorded.

From the resemblance of the scarlet fever exanthem to certain drug and serum rashes it would seem probable that the eruption of scarlatina is produced by a toxin and not by a living organism. It might be here remarked that while scarlet fever scales are assumed to be infectious, we have no positive knowledge that they contain the contagium of the disease.

The same statements are true in reference to the eruption of measles. Morbilliform rashes have been noted in pneumonia by Rilliet, Barthez, Arnauld and others. The rashes observed in influenza are also usually rubeoloid in character.

Various rashes, particularly of the scarlatinoid variety, not infrequently accompany streptococcus infection. A definite streptotoxin has not been conclusively demonstrated, although some investigators claim to have found such a substance in filtered cultures of this organism. On the other hand, the staphylococcus pyogenes aureus is known to produce at least two toxins, leucocidin and lysin. The former has a destructive action upon the leucocytes and the latter upon the red blood cells.

Circumscribed pus collections have been observed to give rise to recurrent toxic eruptions. Schauta had under his care a woman who suffered from repeated outbreaks of urticaria until a purulent salpingitis was surgically removed, after which the attacks ceased.

The foregoing observations would seem to indicate that certain rashes occurring in specific infectious diseases may be the result of bacterial and protozoal toxins. As many of these rashes resemble and, indeed, may be included among the exudative erythemata, bacterial toxins might reasonably be invoked as a cause in some of the latter.

II. Ptomains. Ptomains or bacterial alkaloids are basic, organic compounds produced by the action of bacteria on nitrogenous matter.

This class of poisons plays an important rôle in the production of the different dermatoses of the erythema family. Under this heading are to be included the various food poisonings which not infrequently give rise to eruptions.

These may be classified, after Vaughan, as follows:

Food Poisoning. (*Bromatotoxismus*).

a. Mussel poisoning or mytilotoxismus.
b. Fish poisoning or ichthyotoxismus.
c. Meat poisoning or kreotoxismus.
d. Milk poisoning or galactotoxismus.
e. Cheese poisoning or tyrotoxismus.
f. Vegetable food poisoning or sitotoxismus.

Mussel poisoning commonly produces among other symptoms a more or less generalized urticarial rash, although less frequently a papular or vesicular eruption may appear. The eruption is accompanied by the most intense itching.

Brieger isolated from poisonous mussels a ptomain which he designated mytilotoxin. It is believed that this substance gives rise to the type of poisoning called mytilotoxismus paralyticus, while mytilotoxismus gastricus and exanthematicus are supposed to be due to putrefactive products. Mytilotoxin itself is not an ordinary putrefactive product, for Brieger failed to find it in mussels that had been allowed to undergo decomposition.

Fish poisoning. Ichthyotoxismus may result from ingestion of (1) certain species of fish which are always poisonous; (2) fish which are poisonous during the spawning season; (3) fish affected with epidemic bacterial diseases which render them toxic to man; and (4) fish which are poisonous by reason of having undergone putrefactive changes.

Vaughan (Vaughan and Novy: "Ptomains and Leucomains," 1896) has observed several instances of ichthyotoxismus exanthematicus. In one, a man thirty-four years of age, was seized twelve hours after eating canned salmon with nausea and vomiting and six hours later was covered with a scarlatinous rash from head to foot. A micrococcus was isolated from the salmon which produced a potent poison, ten drops of which sufficed to kill white rats.

Meat poisoning is usually due to the elaboration of certain poisons resulting from putrefactive changes. Sausage poisoning, known as botulismus, is of more particular interest to dermatologists as this article of food is known to give rise not infrequently to attacks of urticaria.

Milk and cheese poisoning. Highly poisonous ptomains have been found in milk, cheese and other products from these sources. The best known is tyrotoxicon, although others exist. A. W. Blyth claims to have isolated from milk two alkaloidal substances, galactin and lactochrome. Urticaria and exudative erythema occasionally occur from the ingestion of cheese and are doubtless due to the absorption of the contained ptomains.

Vegetable food poisoning. This is still a comparatively unexplored field.

Ergotism and pellagra are examples of diseases which are in all probability due to the presence of poisons in vegetable foods.

Ergotism results from eating grains infected with a parasitic fungus, the claviceps purpurea. It is believed that the principle in ergot which gives rise to areas of gangrene and to cachexia is sphacelinic acid. Grünfeld fed a number of animals with this substance and produced gangrene in each one. Even applied locally in concentrated form the skin undergoes sphacelation.

Mäidismus or pellagra is supposed to be due to the ingestion of diseased maize or Indian corn.

Poisons giving rise to various eruptions may be (1) introduced with foods or may (2) develop in the alimentary canal as the result of the action of intestinal bacteria upon the ingested material. Many eruptions of the erythema family have been attributed to what has been termed *intestinal auto-infection or auto-intoxication.*

III. Leucomains and other tissue poisons. A leucomain is a basic, organic compound resulting from metabolic changes in the animal economy. Leucomains are chemical substances, closely resembling the vegetable alkaloids.

The leucomains thus far discovered belong to two chief groups, the uric acid group, including adenin, guanin and the various xanthin products, and the kreatinin group. Some of these leucomains are extremely poisonous.

In addition to the substances which can be accurately designated as leucomains, there are certain other metabolic products which may act as poisons. During the process of normal digestion the albumoses and peptones formed do not enter the circulation. Under certain conditions, however, peptones may find their way into the blood and may be found in the urine. The depression and dullness in the head after meals in well fed, inactive men is attributed by Brunton to poisoning with peptones. Albumosuria has been found in a large number of conditions; among others, Senator observed it in dermatitis, and Loube noted it in urticaria.

In this group should also be included the large number of retention poisons about which little is known: in diseases of such eliminative organs as the kidneys, intestines and skin, certain products are retained which nature doubtless intended should be thrown off. Osler has called attention to the frequency of purpura in connection with diseases of the kidneys; it is also known to occur in cirrhosis of the liver.

IV. Drugs. That various drugs may act as poisons to certain individuals and evoke in them diverse eruptions belonging chiefly to the erythema group is a matter of every day experience. The same medicament may give rise to varied eruptions in different persons or even at different times in the same individual.

The effort has been made in this paper to demonstrate that all or nearly all of the diseases included in the erythema family are produced by the presence in the circulating fluids of the body of a chemical poison. While these poisons come from extremely diverse sources they would appear to be, in the last analysis, not so dissimilar. For instance, belladonna poisoning and intoxication from decomposing fish would seem *a priori* to be two forms of poisoning quite unrelated to each other: as a matter of fact the poisons are so similar as to have deceived medico-legal experts.

There is found in putrefying fish, game, beef and sausage a ptomain which has been designated ptomatropin, on account of its resemblance to atropin. Poisoning with this body produces dry throat, paralysis of the muscles of deglutition, arrest of perspiration and salivary secretion, mydriasis, and at times paralysis of accommodation.

The application of a solution of ptomatropin to the eyes of animals causes a dilatation of the pupil: it has already been stated that Vaughan observed a scarlatinoid rash in several cases of fish poisoning.

In addition, ptomains have been isolated which in their physiological effects and in their ordinary chemical reactions strongly resemble morphin, coniin, digitalin, colchicin, etc.

Crocker has observed sewer-gas poisoning to give rise to scarlatiniform erythema. According to studies made by Odling, sewer air has in it a ptomain which contains more carbon than methylamin and less than ethylamin.

The absorption of the fluid of hydatid cysts has on a number of occasions produced urticaria.

Langubuch and Brieger found in living hydatid cysts a poisonous ptomain. Debove injected hydatid fluid subcutaneously and produced an attack of urticaria.

It is quite probable that some leucomains and tissue poisons may give rise to erythematous dermatoses. The writer has had an opportunity of studying many rashes appearing after the administration of diphtheria antitoxin.

It has been quite definitely established by a number of investigators that these eruptions are not due to the presence of an antitoxin but to the introduction into the system of an alien or heterogeneous blood serum. The injection of plain horse serum into an individual likewise gives rise to these rashes. The exact constituents of the serum which produce the phenomena in question are not known, but they are doubtless albuminous substances which act as mild poisons. Mairet and Bosc have shown that the injection of serum of a different species may produce pronounced symptoms of intoxication.

The epiphenomena of serum injections are of considerable interest and appear to me to shed some light on the erythematous dermatoses in general. In a general way it may be said that serum rashes after the use of diphtheria antitoxin occur in from fifteen to thirty per cent. of those who receive this treatment.

The serum of certain horses is much more apt to produce rashes than that of others. The eruption may appear in from one to thirty days, but the vast majority develop from the seventh to the twelfth day.

The development of the serum phenomena is strikingly analogous with the sequence of events observed in the development of an exanthematous fever. Following the injection there is a period of latency more or less constant with the serum from the same animal, at the end of which time the symptoms make their appearance. There is elevation of temperature, often to 102° or 103° F., accompanied commonly by headache, muscular and joint pains and not infrequently by articular swelling. The eruption is most commonly urticarial or erythematous, but may be in rare cases, purpuric or vesiculo-bullous. The erythema may be scarlatiniform, morbilliform, or may consist, as it frequently does, of annular and figured patches. Mixed eruptions of urticaria and erythema are not uncommon. It is thus seen that practically all of the cutaneous expressions of the erythema group may be produced by serum injections.

The systemic symptoms are practically identical with those observed in well pronounced cases of erythema multiforme. This fact is of interest. There are some dermatologists who are inclined to regard erythema multiforme as a specific infectious disease and who point to the premonitory general symptoms as confirmatory evidence.

In serum eruptions the cause is manifestly a non-bacterial chemical substance formed within the animal body. The epidemics of this affection, noted by Rigler, Gaal, Herxheimer and Düring do not indubitably stamp it as an infectious disease. Epidemicity does not of necessity indicate infectivity. The memory of the recent extensive epidemic of arsenic poisoning in England due to contaminated beer, is fresh in our minds.

The muscular and joint symptoms due to serum injections are also of interest. There has been too much tendency in the past to look upon the joint pains and swellings associated with erythema multiforme, erythema nodosum and purpura as essentially rheumatic in nature; they are in all probability due to the action of various toxins and poisons which have a selective influence on these serous membranes.

Certain it is that in connection with the serum phenomena no thought of rheumatism can be entertained to account for the articular symptoms, and the strongest analogy exists between serum rashes and the erythematous diseases under consideration.

The period of latency before the appearance of antitoxin eruptions suggests in character the period of incubation of acute infectious diseases. As to the processes in each that take place from the moment of introduction of the poison into the system to the outbreak of symptoms, but little is known. It is quite possible that the blood serum when introduced does not contain the poison which produces the rashes but that these are developed in the system by action upon the body cells and fluids. This would account for the delay in the appearance of the eruption.

Courmont and Doyon (*Arch. de Physiol.*, 1895, page 252) have shown that certain toxins, such as diphtheria toxin, do not act directly on the nerve centers, but produce in the body certain poisons at the expense of some of the fluids or cells, which themselves act on nerve centers. Behrend thinks that such drugs as iodine and bromine produce toxins in the body.

Antitoxin eruptions not infrequently appear first in the neighborhood of the site of injection. I have frequently seen the lower part of the abdomen the seat of an urticarial eruption within twenty-four hours or earlier after the injection, whereas, the general outbreak did not occur until some days later. This observation would suggest that the eruption is due to the local effect of the poisons on the blood vessels rather than upon the vaso-motor centers.

From what has been said the conclusion is, I believe, justified that

PLATE XXXVIII.—To Illustrate Dr. Jay F. Schamberg's Article.

Rash appearing after the administration of Diphtheria antitoxin.

Fig. 2.

Fig. 1.

nearly all cases of scarlatinoid erythema, morbilliform erythema, erythema multiforme, erythema nodosum, urticaria and purpura are the result of the circulation in the blood of chemical poisons. These may be introduced from without by living organisms in food stuffs, or in drugs, or they may be produced within the body. At first sight, there would appear to be an exception to this generalization in the urticarias of nervous origin; but on closer scrutiny it seems quite possible that these may be due to metabolic poisons elaborated in the system as a result of faulty innervation. In the same manner various erythematous eruptions are doubtless due to metabolic poisons resulting from the disturbed function of some of the visceral organs. Osler has directed attention to this fact in several publications.

In his most recent contribution to the subject (Osler: "On the Visceral Manifestations of the Erythema Group of Skin Diseases"; *Amer. Jour. Med. Sci.*, Jan., 1904), he says: "Purpura of a severe type is very common in Bright's disease; urticaria and purpura in cirrhosis of the liver and cholelithiasis . . . and all forms of erythema with the chronic valvular lesions of the heart in children."

As our knowledge of autogenous poisons increases a much needed light will doubtless be thrown upon the nature of many cutaneous and other diseases which are now shrouded in mystery.

DISCUSSION.

Dr. James C. White asked Dr. Schamberg whether he could tell in what proportion of cases of so-called ptomain poisoning, cutaneous manifestations exhibited themselves. The speaker said he had in mind a rather extensive outbreak of ptomain poisoning, affecting some twenty odd persons, and in none of them was there any cutaneous manifestations.

Dr. Andrew P. Biddle referred to a case of diphtheria in an adult, in whom the injection of the diphtheric antitoxin was followed by a very severe eruption, with high fever and pain in the muscles and joints. This patient, who is connected with the laboratory of one of the large chemical manufacturing concerns of the country, said that every effort was being made to ascertain the cause of these eruptions, and of the joint and muscular pains, but thus far the investigators were entirely at sea in regard to the matter. In these cases the eruption usually appeared about the seventh day, unless it developed at the site of the injection; then it was more apt to appear about the second day.

Dr. Gilchrist said that in the description of the microscopical sections of urticarial hives which he gave some years ago he showed that the hive consisted of an acute inflammatory œdema, and in the sections taken from many cases he found large numbers of polynuclear leucocytes

and fragmentation of the nuclei. The idea he derived from his investigations was that there was a toxin circulating through the blood which produced this inflammation. Either a toxin or some deleterious substance.

Dr. Ravogli called attention to the importance of the vaso-motor nerves as a possible factor in the production of the toxic erythemata. He felt convinced that some of these eruptions were the result of the actions of the vaso-motor nerves under the influence of toxic elements.

With reference to the use of tuberculin, Dr. Ravogli said that the original preparation of Koch seldom gave rise to an erythema, but after injections of the "T-R" preparation, such eruptions were quite frequent, and he recalled one instance where it was followed by a very deep-seated erythema, with subsequent ulceration and lymphangitis.

In order to illustrate the fact that internal remedies were capable of producing an eruption, the speaker showed a photograph of a very extensive eruption following three doses of creosotol of ten drops each.

Dr. Schamberg, in closing the discussion, said that Dr. White's experience in connection with the comparative infrequency of eruptions associated with ptomain poisoning was in accord with the observations of most writers on the subject. It appeared that in cases of food poisoning in which profuse vomiting and purging occurred there was less danger to the life of the individual and possibly also less likelihood of an eruption.

XANTHOMA MULTIPLEX: HISTOLOGY OF THE PALMAR STRIÆ.

By Henry H. Whitehouse, M.D., New York.

Read before the twenty-eighth annual meeting of the American Dermatological Association, Niagara Falls, June 2 and 3, 1904.

THE subject of xanthoma is one of the most interesting in the entire field of dermatology. This is due, not alone to the fact that it is one of the rarer affections of the skin, but because its nature is so little understood. This seems the more remarkable when one realizes that since the first published accounts of the affection by Addison and Gull[1] in 1851, it has received the attention of some of the most able workers in this branch of medicine. Much has been done, to be sure, in the study of the various clinical types and manifestations, and the anatomical studies have elucidated some points respecting etiology, but after all, the past fifty odd years of most careful observation and research leaves the riddle to-day unsolved.

[1] *Addison and Gull*—"Guy's Hosp. Reports," 2nd series; Vol. VII, p. 268, London, 1851.

Bodin,[2] the latest writer on the subject this very year, says that "Xanthoma still remains a most mysterious and enigmatic disease."

It is with considerable trepidation, therefore, that I approach the subject to-day, even as relating only to one type of the disease, for in the limited time at my disposal, I can only touch upon a few special points. The histology of the palmar striæ, which, to my knowledge, has not been attempted before, and the results of treatment by the X-ray and high frequency current, are the only excuses I can offer for bringing before you the case which is the basis of this paper.

The patient, Mrs. Clara W., was born in England thirty-four years ago. She has been married fifteen years, and is rather stout, with fair skin and light hair. She is in apparent perfect general health, though she is easily fatigued, and is of a nervous temperament.

Family History. All the family have been in the liquor business and all are alcoholic, especially the father, who is said to have died of epilepsy at the age of forty-eight. The mother had ascites, and is said to have died of a tumor of the stomach. There is no history of mental disease or of tuberculosis in the family. The patient has four brothers and two sisters, none of whom has xanthoma.

Previous History. The patient has a moderate alcoholic habit. She denies syphilis. She has had articular rheumatism several times, the last in May, 1903, when the heart was said to have been affected. For four years she has felt less active than formerly, but has never had any severe illness. She has never suffered from jaundice. She has had two children and no miscarriages.

Present History. There are no pulmonary symptoms, save an occasional slight dry cough in the winter. Likewise, there are no cardiac or renal symptoms, except a slight dyspnœa on exertion for the last two or three years. The appetite is good, digestion apparently normal. Occasional nausea in the morning from loss of sleep or perhaps from too much beer. The bowels were formerly constipated, but have been regular for the past five or six years.

Physical Examination—Heart. The apex is in the fifth interspace, 3½ inches to the left of the median line. There is a soft-blowing systolic murmur in the third interspace, just to the left of the sternum. The heart action is irregular.

Liver. Dullness begins in the fourth space, flatness in the fifth space, and extends to the free border of the ribs. The edge is barely palpable.

Spleen. Not enlarged.

[2] *Bodin*—"La Pratique Dermatologique," Vol. 4, p. 862, Paris, 1904.

Urine. The patient passes water once at night, but has no great thirst. She passes eighty ounces in twenty-four hours, specific gravity 1010, reaction .2520 acid (Normal acidity .3730 oxalic acid equivalent in 100 c. c.). There was neither albumen nor sugar, and no indican—Urea .65 per cent.

Just over the manubrium sterni is a soft, apparently semi-solid mass, about 1½ inches in diameter, movable on the deeper parts, and situated subcutaneously. There are no inflammatory symptoms. It has every appearance of being a small lipoma.

The cutaneous affection began as yellow discolorations in the lines of the palms eight or nine years ago. These have never disappeared, but have, on the contrary, gradually increased, with periods of quiescence, spreading to the interdigital clefts, sides of the fingers, to the larger lines on the knuckles and the flexor surfaces of the wrists. The eruption appeared in the form of nodules on both elbows about two years ago, and these have steadily but slowly increased in size. The spots are not painful, neither do they itch, nor cause any inconvenience, except for their disfigurement. The tumors on the elbows are slightly more tender than the rest of the skin.

Recently two deep-seated nodules appeared, one on the outer surface of the left forearm, about three to four inches from the elbow the other, on the inner surface of the left thigh.

Yellow plaques are also present on the dorsal surfaces of the toes in the interdigital clefts and the flexor of the first joints of the second toe of each foot. It is uncertain when these developed, the patient being unaware of them, from their inaccessible location. It is quite probable, however, that they began at the same time as the discolorations on the hands, for they are lesions of precisely the same character.

The finger and toe-nails are free, and the eyelids are entirely free. The remainder of the cutaneous surface, other than the situations named, is free from the disease and normal in every respect.

The plane and striated lesions are all chamois-yellow in color. The discolorations along the larger lines of the palms, the knuckles and flexor joints of the fingers and wrists, stand out in bold relief from the surrounding healthy skin. The larger lines of the palms, extending at right angles to the axis of the hand, are particularly prominent, the deposit extending a distance of a sixteenth of an inch on either side, giving the appearance of narrow yellow ribbons.

The patches in the interdigital clefts of both hands and feet and on the sides of the fingers and dorsal and flexor surfaces of the toes are of the xanthoma planum type, irregular in shape; the largest,

about three-eighths of an inch by a quarter of an inch in diameter. These are not appreciable to the touch, and are similar in every respect to the lesions so commonly seen upon the eyelids.

The tubercular lesions on the elbows form irregularly shaped, sessile masses, resulting from the confluence of the component nodules, which have an uneven surface, raised one-fourth to three-eighths of an inch above the level of the skin, and about two and a half inches in diameter. Their color is a dull red, but upon stretching, the same yellow deposits are to be seen in places.

The nodules on the forearm and thigh are dull red in color, about the size of a hazel-nut, and are quite hard and deep-seated.

We have here, then, a case of xanthoma multiplex, occurring in a woman with good general health, with the exception of a rheumatic heart. There is no discoverable liver, kidney, or visceral disease, and no jaundice. The eruption is composed entirely of plane and nodular lesions, with no disseminated papules so often seen in this variety of the disease.

In regard to the symptom of jaundice—all authorities seem agreed that jaundice or a xanthomatous dyschromia is almost always present in xanthoma multiplex—Crocker[3] states that four-fifths of the cases are accompanied by this symptom. It is a strange fact that in the seven cases that I have observed personally, four males and three females, none had jaundice. They were all mild cases, however, and if the belief of some authors is correct, that the jaundice is secondary and due to obstructive xanthomatous growths in the bile ducts, a ready explanation of my observations is afforded.

In connection with the narration of this case, certain observations made by Leven[4] in a recent contribution upon xanthoma are of considerable interest.

In a collection of twenty-three cases from literature, including one of his own, he finds that sixteen, constituting seventy per cent. of the whole, fifteen of whom were males and only one female, were suffering from other diseases; twelve, or seventy-five per cent. of these had diabetes, two nephritis, one pentosuria and one hypertrophic interstitial hepatitis. Only seven of these twenty-three cases, comprising thirty per cent., four of whom were males, two females and one not stated, were free from other diseases.

In the sixteen cases associated with other diseases, seventy-five per cent. of whom were diabetic, the eyelids were unaffected, and the erup-

[3] *Crocker*—"Diseases of the Skin," 3rd edition; p. 743. Phila., 1903.
[4] *Leven*—"Archiv f. Derm. u. Syph.," Vol. LXVI., 1903, p. 61.

tion disappeared spontaneously, or as a result of treatment, in thirteen of them.

In the seven cases uncomplicated by visceral disease, five presented lesions on the eyelids, and no mention was made of any cures.

In regard to the type of the eruption, he found that eight were purely tuberose; seven of these suffered from other diseases, six of whom had diabetes and one nephritis. Four were of the mixed type (xanthoma planum and tuberosum), three of whom were free from disease and one had hypertrophic interstitial hepatitis. In eleven instances details of the type of eruption were not given.

These statistics of Leven only confirm the generally accepted opinion that a very large proportion of the cases of xanthoma associated with other diseases are diabetic, that they occur mostly in males and get well spontaneously or as the result of treatment. Also that in those cases uncomplicated by other diseases, males and females are affected in about equal proportion and they do not get well.

The histological examination of the palmar lesions in this case, together with that of very large tuberose lesions from another case were made by Dr. James C. Johnston, to whom I am indebted for the accompanying reports:

Histology of the Palmar Striæ.

So far as we have been able to discover, this point as to the nature of the process in tuberose xanthoma has not yet been investigated. It is reasonable to suppose that the growth would not differ, except in degree of development, from the lesions of the knees and elbows. The failure of development may be due, in part at least, to the restraining pressure of the thick horny layer.

There is not much to be added in the way of description to the appearances represented in the accompanying photograph. The process is evidently neoplastic, there is no inflammatory change of any sort, and it is limited to the superficial portion of the corium. The epidermis shows no alteration. The cells of the tumor are distributed more or less irregularly in foci along the line of the plexus of vessels dividing papillary body from reticular layer. They are evidently derived from the endothelium of the vascular channels and lymphatics, although it is impossible to determine their origin with certainty because growth has ceased probably long before the section was taken. The cells show gradation forms, here and there, remotely approximating proliferating endothelium, and are closely applied to the vessels, always following their distribution. The proliferation can be followed in the single branches supplied to the papillæ.

PLATE XXXIX.—To Illustrate Dr. H. H. Whitehouse's Article.

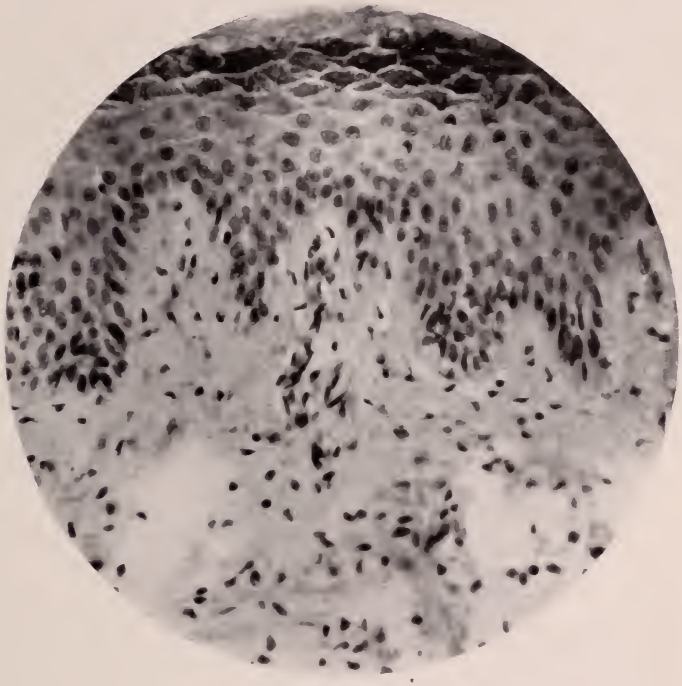

Fig. 1.

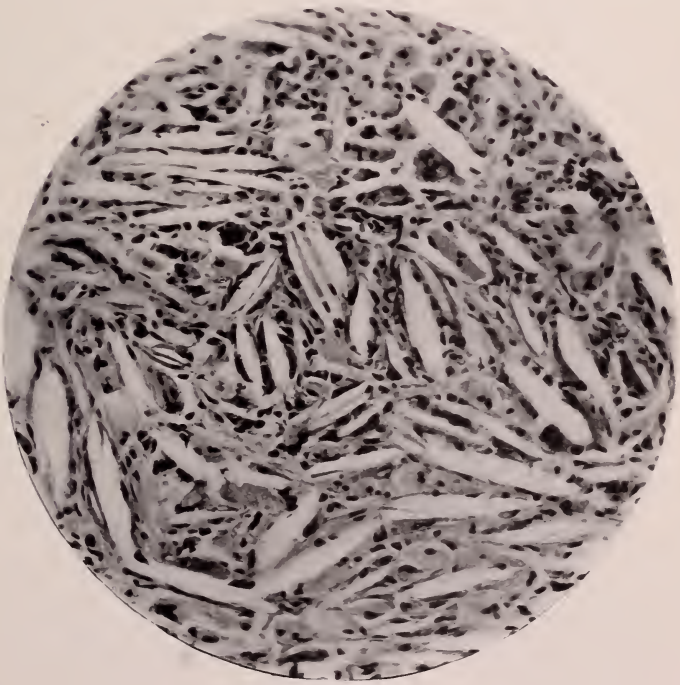

Fig. 2.

The cells are generally large, having a diameter of 15-20 microns with a membrane enclosing an almost homogeneous protoplasm, and an ovoid nucleus. The nuclei stain diffusely and show nodal points (false nucleoli), which are distinguished from the surrounding chromatin by their greater affinity for basic dyes. The homogeneous protoplasm apparently soon undergoes the fatty degeneration which is characteristic of all xanthomata. It becomes filled with small vacuoles which, before hardening in alcohol, were filled with fat and shows numbers of smaller, slightly acidophile granules which are of course part of the process. The cells do not break down sufficiently to permit the escape of the fat into the surrounding tissues. They increase in size perceptibly with the fatty changes, but occur always in small numbers in any focus. Occasionally they are disposed in strings of single cells. It is curious that so small a fat deposit should give so pronounced a yellow tinge to the striæ.

A Case Showing Enormous Development of Tuberose Lesions.

The history and material from this case were supplied by one of the recent graduates of Cornell University Medical College, Dr. Flynn. The patient was a man, laborer by occupation, aged about forty-five. He could give no family or personal history which bore upon his condition. His health had been and was good at the time of admittance to Seney Hospital. He had never been jaundiced; his desire in seeking relief was to be rid of the inconvenience his tumors caused him. The duration of the disease, he thought, was about ten years.

There were a dozen or more growths over the elbows and knees and on the backs and sides of the feet. They varied in size from a diameter of one centimeter to five, and the large ones which were taken from the elbows projected as much above the skin surface. They, like other skin tumors, were sessile in the early stage of development, as the elevation increased they showed a tendency to lateral growth, mushroom-like, over their attachment. The surface was smooth, unlobulated, eroded where the clothes rubbed it continually, but never ulcerated into the corium. The tumors were all of woody hardness of the familiar chamois-skin tint. The palms showed striæ, but no mention is made of the soles nor of the distribution of the neoplasms in their sites of predilection beyond that given.

On cut section, when fresh, the surface was of a diffuse deeper yellow than the skin, very slightly mottled with red at the periphery, the vessels being few and almost completely emptied of blood. Sections from a tumor two centimeters in diameter showed the entire

corium replaced by new growth which hardly infiltrated the subcutaneous fat at all and was, therefore, contained in the thickened skin. The epidermis was flattened and reduced by pressure to a thickness of five or six cell layers. The interpapillary projections and skin appendages had entirely disappeared.

The tumor proper presented a peculiar appearance, owing to the presence in it of angular spaces often large enough to be made out by the naked eye, well illustrated in the photograph, taken with a moderately high power, and showing only the half of the growth next the epidermis. The spaces contained, before hardening, cholesterin crystals which could be obtained by scraping a cut curface in the fresh state. Inside the condensation capsule formed by its development, the tumor grew diffusely, dissecting the collagen fibers (a), but collecting into nothing resembling alveoli. A few strands of cells could be seen passing down in the fibrous septa between the fat lobules below. In the peripheral, presumably younger portions, the cells were small polygonal, with granular protoplasm and the oval, diffusely staining nucleus described in the previous section. They formed columns without definite arrangement, and showed no intercellular substance. Further toward the center, they increased in size, and, undergoing granulo-fatty degeneration, resembled closely the cells found in the palmar striæ.

The xanthoma cells, so-called, giant-cells in reality, no different from any others occurring in tumors of endothelium, were numerous. They were large with numbers of small round nuclei grouped generally in a mass at the center from which ran threads of protoplasm to the periphery, the rest of the cell body having disappeared in the solution of its detritus. In places, degeneration was complete, denuded nuclei lying free in the spaces resulting. Other giant cells were found with the same nuclei whose protoplasm was granular, but showed no fat vacuoles. Mononucleated large cells almost always showed advanced degenerative change.

Cholesterin crystals were differentiated from the granulo-fatty detritus wherever it occurred and had remained long enough. It is apparent that in their formation the material from cytolysis was all used or that the granules were removed as the crystals took shape. The outlines of the cavities, in which they occurred, were always clear cut. While their position was naturally a matter of indifference, depending merely on that point where degeneration was advanced, they had a predilection for the neighborhood of small vessels, lying with their long axis parallel to that of the vessel.

There was no sign of inflammation present, and no evidence of the formation either of new vessels or connective tissue. In fact, the vascular supply was noticeably meager.

These pictures furnish one more convincing demonstration to our minds of the fact that there is no kinship between xanthoma vulgare and xanthoma diabeticorum, save only the presence of fat, due in both instances to a degenerative process. In the disease of diabetics it is inflammatory; in the neoplasm, it is at present inherent in certain types of endothelial new growth. Török[5] recognized this fact ten years ago and has had plenty of support. He claimed that xanthoma vulgare represented the development of fat in a heterotopic situation, and was, therefore, allied to lipoma. Of course, one man's experience in these rare conditions does not permit him to generalize dogmatically as to the nature of an entire group. Török's findings may justify him in his stand (the clinical picture would be the same), but if all xanthoma vulgare shows such histological pictures as these two cases, his interpretation is incorrect and the tumor is not a lipoma, but an endothelioma with a vessel derivation and inveterate tendency to granulo-fatty degeneration.

In concluding, I would add a few words in regard to the effects of treatment in this case by the use of the X-ray and of the high frequency coil. I have been able to find only one reference to treatment by either of these means, and that was in a case of xanthoma presented by Mr. Willmott Evans[6] to the Dermatological Society of London in November, 1902. The disease in his case was of seven years' duration, and affected both elbows. One elbow had been subjected to ten exposures of the X-ray, of about fifteen minutes' duration each, a fairly soft tube being used, with a result that, that elbow became practically clear of the disease.

Between February 10th and 19th each elbow, in my case, was exposed to the rays from a Queen tube, five times. The total time of exposure for each elbow was twenty-one minutes, and the anode was placed four inches from the skin. The right elbow was more sensitive than the left, and although both elbows became red, the right was slightly painful and tender. It then became soft and a thin slightly bloody discharge appeared. This soon ceased and by the middle of March, most of the reaction had disappeared. Both masses were then greatly diminished in size, the right especially.

[5] *Török*—"De la Nature des Xanthomes—Ann. de Derm. et de Syph.," Vol. IV., Nos. 11 and 12, 1893.

[6] *Evans*—"Brit. Jour. of Derm.," Vol. XIV., 1902, p. 465.

Both elbows were again exposed three times between April 5th and 12th, twelve minutes altogether for each elbow, with the same tube, the anode four and a half inches from the skin. The left elbow had extra exposures March 15th and April 15th, four minutes each.

The tube used in all cases was a Queen, medium size, with regulator set at three inches.

On April 22d both elbows were slightly red and tender, and the masses were gradually diminishing.

She was seen again about the middle of May, all irritation had ceased and the right elbow was nearly well; the tumor on the left elbow was about one-third its original size.

The palms were exposed five times between February 10th and 19th, twenty-two minutes altogether, the distance of the anode varying from five to seven inches. The hands became red, dry, slightly swollen and tender, and remained so about a week. They gradually returned to normal, and it was seen that the lines in the palms were entirely unaltered.

Treatment of some of the plaques along the sides of the fingers by hyperstatic electricity—Piffard's high frequency coil was begun April 8th. They became red, swollen and tender, one or two becoming blistered. The inflammatory action gradually subsided, and by the middle of May nearly all the redness had disappeared.

The lesions that had blistered had disappeared, but the others remained unchanged.

It would seem that in these agents, we have at last a convenient and effective method with which to treat these obstinate cases. I have reason to believe that the plane lesions would likewise disappear under the X-ray, if the reaction was sufficiently increased.

DISCUSSION.

Dr. Whitehouse, in reply to a question as to whether these tuberose forms of xanthoma were usually indurated and had a woody feel, as in the case he had reported, said that the lesions were usually soft; the indurated condition was exceptional, but not unusual.

PINTA: PAÑO BLANCO.

By Paul G. Woolley, M.D., Assistant Director Serum Laboratory, Manila, P. I.

(From the Government Serum Laboratory, Manila, P. I.)

UNDER the terms paño blanco, pinta, pinto, caraté, mal pintado, mal delos pintos, mal del pinto, peint, cute, cativi, quirica, pannus carateus, and the spotted disease of Central America, is included a group of dermatomycoses, characterized by peculiar pigmented patches on the skin, in the scales from which hyphæ, or spores, or both, of a mold-like fungus are found, which resemble in some cases penicillium, in others aspergillus, in still others monilia.

Heretofore this epiphytic disorder has been reported from Mexico, Central, and South America; and another disease resembling it in some respects has been observed by Legrain in North Africa, and by Sandwith in Egypt, but so far as I know no previous report has come from the Philippine Islands.

The case which I wish to record is not the only one that I have seen in Manila, but it is the only one from which I have been able to obtain specimens for examination. But all of the affected persons whom I have noticed have shown only the white variety, of which the following case is an example.

The history of the case is as follows: A Filipino of fifteen years, in good health, and a laundryman. There is no similar disease in any of his immediate family.

Upon inspection it is noticed that there are pinkish-white patches, irregular in size and shape, on ankles, dorsa of feet, shins, knees, elbows, hands, wrists, and one on the right shoulder. This last-mentioned lesion the boy says was the one he noticed first.

The largest lesions are over the external malleoli of the ankles. These, the boy says, appeared after the one on the shoulder. The patches on the knees and elbows appeared still later. None of these patches are of the same shape or size, nor are they distinctly and definitely defined, but shade from their clear white centers to the normal brown of the skin. Neither are the lines of extension regular, so that the outlines of the patches are irregular and crenated. About the larger areas are smaller ones, some barely visible and of a faint pinkish-white or very light-brown color.

On palpation one perceives that the skin over the larger patches is slightly rougher than the normal skin, and that it feels somewhat

thicker. The palpating finger can detect no abnormal variation in the covering of the smaller spots. There is but a minimum amount of scaling, and there is some itching.

The rate of extension has been extremely slow, for in three years the largest patch has a diameter of but 7 and 5 centimeters.

When asked regarding the cause, the boy said that the first spot came from carrying laundry baskets on his shoulder, and that the other spots followed traumata of one kind or another. There are no lesions on the palms of the hands or soles of the feet.

From one of the larger lesions on the ankle, scrapings were made and examined in a solution of caustic potash (25 per cent.). Among the epithelial cells, branching, segmented hyphæ were seen, forming a coarse meshwork. The mycelium was somewhat finer than that of the trichophyton. It was in general evenly refrangent, but in places beaded or granular. The spores were darker in color than the rest of the organism and less refractile. An occasional fructification was found in the smears, and in these the arrangement of the spores was like that of penicillium. When stained with dilute fuchsin the spores were stained a very deep red. The hyphæ showed an inner segmented arrangement with a continuous enclosing capsule.

There was nothing in any of the preparations to suggest the description of Gastambide. The mycelial filaments are usually long, branched, and terminated in a bunch of spores. The description given by Montoya y Flores seems to apply more accurately to the fungus of this case.

There can be no doubt of the nature of the disease. The clear white spots, with almost normal-looking skin, can be confused with no other skin affection that I am acquainted with. Diseases caused by trichophytons are extremely common in Manila, and are known generically as "dhobie itch," which is so common in the natives that in thirty cases of skin disease taken at random in Bilibid Prison twenty-four showed trichophyton filaments in caustic potash preparations.

It is possible that a brown pinta might be confused with pityriasis versicolor, should the small patches occur on the face, where it is said that the latter may occur. However, in the present case, the clear white color of the irregular patches, the presence of sensation, and of itching, together with the microscopic findings, are enough to assure a correct diagnosis.

REFERENCES.

[1] Manson. "Tropical Diseases," London, 1903.
[2] Scheube. "Krankheiten der Warmer Länder," Jena, 1900.



DESCRIPTION OF ILLUSTRATION TO DR. P. G. WOOLLEY'S ARTICLE.

The illustration represents different stages of the fungus of "paño blanco" in scrapings taken from the specific lesions. All were drawn from a preparation stained with carbol fuchsin diluted ten times with water. The two fructifications were drawn with the aid of a camera lucida using Zeiss ocular 4, and objective D.D.

The magnifications of the other sketches vary and no camera was used in making them.

REVIEW
of
DERMATOLOGY AND SYPHILIS

Under the Charge of JOHN T. BOWEN, M.D.

BACTERIOLOGY AND PARASITOLOGY.

By A. D. MEWBORN, M. D., New York.

Cutaneous Cocci.

Polymorphic Coccus of the Skin (*Recherches sur un coccus polymorphe, hôte habituel et parasite de la peau humaine*) AXEL CEDERCREUTZ (*Thése de Paris*, 1901).

Nothing was more natural than that dermatologists should have expected great results from a study of the bacteriology of cutaneous diseases and some, more enthusiastic than expert, have thought that each coccus isolated from the lesions of a disease had a specific value. The most discussed, on account of the eminence of the investigator, has been, quite naturally, the morococcus of Unna. And although at the Congress of Dermatology, in 1900, Kreibich, Morfan and Dockerell identified it with the staphylococcus, Scholz and Raab declared the arguments of Unna insufficient, Galloway identified it with the staphylococcus albus, Sabouraud described Unna's morococcus as a species distinct from the ordinary staphylococcus of suppuration, which he called *staphylococcus cutis communis, coccus butyricus,* Unna still maintained that the presence in sections of this coccus in the form of diplococci, the agglomerations in which the cocci were incompletely isolated and uncqual in size, as well as certain characteristics of culture differentiated it from the staphylococcus and identified it as the cause of eczema.

In order to elucidate the question, Cedercreutz, working in Sabouraud's laboratory, studied the variations in microbes with reference to cutaneous cocci, especially the relation of Unna's morococcus and Sabouraud's coccus butyricus with the staphylococcus and tetragenous group. He describes a polymorphic coccus, habitually present as parasite in the skin and which, to him, appears identical with the morococcus. He concludes that the flora constituted by the cocci of the human skin is much less complex than supposed by most dermatologists. That this error has been caused by the fact that there exists upon the human skin a coccus liable to great variations in the aspect and characteristics of cultures as well as in morphological appearances of individual cocci.

That the variations of which this coccus is capable may be effected by changing the media of culture; but hereditary conditions also play a certain rôle.

That this coccus developes well upon most media used in bacteriology;

but it prefers a medium lightly acid or neutral to an alkaline one. That this microbe, inoculated into the hair follicles of man, produces a folliculitis which heals rapidly; in the pus of lesions these cocci are usually enveloped by phagocytes, and then decolor more or less rapidly by a Gram.

That the question of the relation of this microbe to staphylococci cannot yet be definitely settled.

That many dermatologists have described with more or less detail cocci which were identical with this polymorphic coccus.

That the micrococcus tetragenous (Gaffky) is so nearly related to this coccus that Cedercreutz considers the two species identical. He recalls the fact that this coccus has been described by Class as the pathogenic agent of scarlatina.

Acne, Furunculosis and Sycosis (The Treatment of) by Therapeutic Inoculations of Staphylococcus Vaccine. A. E. Wright. (*Brit. Med. Jour.*, 1904, p. 1075.)

The author, while studying the changes produced in the blood after the inoculation of antityphoid vaccine, ascertained that the inoculation of a bacterial vaccine is followed by a negative phase of diminished bactericidal power, corresponding to the period of application of the vaccinal stimulus; secondly, by a positive phase of greatly increased bactericidal power, that is, a period of active response; and, lastly, after the remission of the stimulus, by a comparatively durable period of increased resistance. He further determined that the negative phase effect was directly dependent with respect to duration and intensity upon the dose of the vaccine; such negative phase being of only short duration when the dose of the vaccine inoculated is small and where the constitutional symptoms produced are slight.

About this time he was confronted with a case of chronic staphylococcic infection, of seven years' duration manifesting itself by recurrent attacks of furunculosis, sycosis, styes and eczema tarsi. The patient was a physician, whose trouble began with an infected finger, caused by cleaning a tracheotomy tube. The infection spread up to the axilla and was followed by high fever and septic peritonitis; since then the susceptibility to staphylococcic invasion became manifest. This case and a number of similar cases of staphylococcic infection were treated by inoculation of sterilized cultures of staphylococcus, with great benefit. These results were published in the *Lancet*, March 29, 1902. The author adds the reports of a number of other cases, twenty in all, which were inoculated with doses of vaccine varying from 500 millions to 5,000 millions of sterilized staphylococci. In all of these cases the phagocytic index was increased, in some cases from .54 to 2.1. In some obstinate cases it was found of advantage to make the vaccine from a culture of the staphylococcus found in the lesions treated. In conclusion, the author states that

his results bear out the broad principles of the therapeutic inoculations of bacterial vaccine and its wide sphere of application. In this method the chemical machinery of the patient is induced to elaborate by its own efforts the protective secretion which is required for the destruction of the invading bacteria. In appropriate doses, and at proper intervals, the vaccine introduced will call forth a production of the specific bacteriotropic substance required.

Dermatitis (Chronic Streptococcic) Assuming the Form of a Pemphigus. (*Sur une Dermatose streptococcique chronique affectant la forme d'un Pemphigus.*) F. Krzystalowicz. (*Monatsh. f. prkt. Derm.,* Feb. 15, 1903; also *Revue Prat. Mal. Cut., Syph. et Ven.,* 1904, p. 150.)

As the author states in his preliminary remarks, pemphigus does not constitute a clearly defined syndrome, in spite of the authoritative opinion of Kaposi. The appearance of bullæ, common to the different forms collected under this name, vary considerably in their aspect, as in their evolution. Only a systematic and careful histological and bacteriological examination in each case may be expected to throw light on the subject.

He poses, then, as a principle, that only those cases be qualified as pemphigus where the etiology of the bullous eruption is doubtful, or at least where bacteriology has furnished no positive proof, and those where we are obliged to admit, in order to explain the bullæ, the influence of the nervous system, circulatory, or intra-organic disturbances. Hence, would naturally be excluded vesicles following burns, impetigo contagiosa, herpes and other similar affections. Acute pemphigus of the newborn would also be excluded as the infectious nature of this affection (due to the streptococcus) is already recognized by the majority of authors. For the latter disease he favors the term bullous dermatitis of the newborn. He admits that at present it is impossible to decide whether Duhring's disease (*dermatite herpétiforme polymorphe douloureuse*) and the best known form of pemphigus (pemphigus vulgaris, p. foliaceous, p. vegetant) belong to one and the same group, or if they are distinct morbid entities, or if they encroach one on the other, or if they are only symptoms of different morbid processes. Rejecting the distinction of acute and chronic pemphigus, on account of the various factors modifying its course, such as insufficient or no treatment, concomitant disease, incident or antecedent, capable of prolonging or shortening the attacks, he adheres to the definition of Unna: a case of pemphigus is one in which clear, nonpurulent isolated bullæ develop in different parts of the body, upon a slightly reddened base, sometimes in periodic eruptions, never grouped or circinate, more or less symmetrical, without any subjective symptoms.

The case described by K. presents many interesting points in its evolution, histology and bacteriology. The patient was a young man of

eighteen years, who, eight months before presenting himself at the clinic, had suffered from an attack of scarlet fever, which in the second week developed an albuminuria and in the third week there appeared on different parts of his body and buccal mucous membrane numerous large vesicles. These vesicles would increase in dimensions, accompanied by fever, then subside, to be followed by similar attacks. On first examination the scalp was found covered with thick crusts, the face presented impetiginous crusts as well as large vesicles filled with clear fluid, and on the palms were large bullae.

The diagnosis at first was ecthyma vulgaris, which seemed than in accord with the history of extension progressively from one part of the body to another, but a diagnosis which was not in accord with subsequent evolution of the disease. After a careful cleaning up of the scalp, crops of new bullæ and vesicles appeared on the face and extremities. Some of the bullæ were the size of a silver dollar and were bordered by an erythematous zone. This recrudescence as a result of treatment was naturally imputable to a dissemination of the infection and to demonstrate this fact the author rubbed in some of the liquid from a bulla into the left arm of the patient and obtained, twenty hours later, two large flat bullæ filled with clear serum and surrounded by an erythematous margin. During the five months' observation at the clinic the attacks succeeded one another; the bullæ were at times with and without erythema. In considering the evolution of the disease subsequent to cleansing the scalp, the case is comparable to pemphigus, by the bullæ, and to bullous erythema by the erythematous patches. By its polymorphism: varying aspect of the erythema, and subjective symptoms (pain, burning and itching) one might think of Duhring's disease, but the oblong, flat vesicles with wrinkled surfaces were against this.

The histological examination of an excised bulla showed that, different from pemphigus, the entire epithelium was raised from the œdematous papillæ by the effused serum. The walls of the papillary vessels were dilated. There was only a small amount of fibrin in the serosity and a few lymphocytes. Sections stained by a modified Gram and Unna's polychrome-methylene-blue-glycerine-ether-mixture, showed masses of cocci in the bullæ, which, by the arrangement, rather suggested streptococci than staphylococci. Cultures made from the fluid in the bullæ by the pipette method of Sabouraud [This method consists in aspirating the serous contents of a bulla into an effilated glass tube, into which is then drawn up equal parts of sterile human serum and bouillon. The end of the tube is sealed in the flame and kept vertical at a temperature of 37 C. As the streptococcus is a facultative anaërobe, colonies of the streptococcus develop at the bottom of the tube where they can easily be separated from the staphylococcus near the surface. A. D. M.] give pure cultures of the streptococcus.

The erythema which complicated the symptoms was shown by the histological and bacteriological examination to have been due, not to an internal cause, but to the streptococcus. In conclusion it must be admitted that an erythema and pemphigus of the mucous membranes may be caused by a streptococcic infection, a consideration which must not be lost sight of in the study of each case of pemphigus.

Pemphigus Vulgaris (a Case of), with Some Observations on its Bacteriology. A. C. Eustis. (*American Med.*, 1904, p. 634.)

The patient was a San Domingo negro, aged fifty-five years, who had been in a camp of laborers engaged in work upon the sewerage system of New Orleans. He stated that the camp had been free of the disease until the advent of a German who developed the disease, and was quickly followed by an epidemic. Three deaths and one total loss of eyesight followed as a result of it. The first lesion developed in the patient as a small elevation at the root of the penis, which caused a burning sensation and in six hours developed into a "blister containing a clear fluid." On the following day vesicles appeared on the scrotum and inner side of the thighs. The eruption then spread to the axillæ, neck, and became generalized. The vesicles came out in crops, each crop being preceded by intense burning. At the time of admission to Charity Hospital the patient was almost entirely covered with bullæ, varying in size from a pea to a hen's egg. The scalp, beard and pubes were free of lesions. The lesions were tense bullæ, rising abruptly from sound skin and filled, for the most part, with clear serum. Except a reddened conjunctivæ, the mucous membranes were free of lesions and this despite the fact that the disease existed for two months. Two days after admission ulcerative lesions appeared in the pharynx and on the buccal mucous membrane. A purulent discharge from the nose also appeared and the temperature ranged from 100 F. to 102 F. No diarrhœa nor abnormalities in the urine were present.

The author isolated from the bullæ a diplococcus resembling the one described by Demme, Claessen, Wells, Hadley and Bullock, and Daehnhardt. A slow growing organism on the usual media, on solid media appearing at first white, developing in forty-eight hours a yellow pigment which in some cultures was so excessive as to appear orange in color.

No fermentation took place in lactose or glucose bouillon even after seven days' growth. In litmus milk it failed to develop fatty acids or to coagulate. In hanging drop cultures the coccus occurred in pairs or in chains of three to four, varying in size from .3 micron to 1.2 micron. The author remarks the general resemblance to the gonococcus. Stains with the usual stains and takes the Gram. In a number of animal experiments the author found that it caused death in a rabbit when introduced intravenously; that this diplococcus could be found in the organs of the dead rabbit and could be isolated in cultures from the rabbit; that the cul-

ture so obtained did not differ from that of the patient, and when this culture was inoculated into a pig (Sus scrofa) produced a pustular eruption in the latter animal, attended by mild constitutional disturbances. The author makes no special claim as to the specificity of his organism which, to the reviewer, bears many points of resemblance to the polymorphic coccus described by Cedercreutz.

INFECTIVE GRANULOMATA.

By H. G. Anthony, M.D., Chicago.

The Tuberculides, a Contribution to the Study of. Dr. Nicolau. (*Ann. de Derm. et Syph.* 1903, p. 713.)

Although it is now settled that lichen scrofulosorum, *erythéme induré* of Bazin, and the cases of Philippson and of Macleod and Ormsby are not caused by tubercular toxines derived from a distant tubercular focus, as was formerly believed, but are due to the presence of the bacillus tuberculosis in the affected tissues, doubt still exists regarding some of the remaining forms of the so-called tuberculides.

Imitating human pathology as closely as possible, the author endeavored to produce toxi-tubercular eruptions in guinea-pigs.

In one series of experiments he inoculated a pure culture of the bacillus tuberculosis, the bacilli of which had been killed by heat. Nodules formed at the point of inoculation which presented the microscopical findings which Darier describes as present in the tuberculides and in which he found dead granular bacilli. The nodules broke down and formed ulcers which finally healed.

In a second series of cases the bacilli of a pure culture in bouillon were removed by filtration and the bouillon inoculated, but no lesion whatsoever developed at the seat of inoculation and the animals did not react to tuberculin.

These experiments indicate that it is the presence of living or dead bacilli which produce the eruptions which are called tuberculides and not toxins derived from a distance. Where dead bacilli cause eruptions it is their toxins which produce the lesions, but these toxins act *in loco* and not at a distance. The article is accompanied by the report of a new case of acnitis.

Tuberculosis of the Skin, Experimental. Julius Meyer. (*Berlin. kln. Wochen.* 1903, p. 1038.)

In the discussion of bovine inoculation tuberculosis, Prof. Orth expressed the opinion that mixed infection favored the development of tuberculosis in the skin, while Prof. Schütz held that the contrary was true.

Meyer undertook to determine by experimentation which of these views is correct. Sputum mixed with streptococci, painted on the denuded skin of guinea-pigs, produced extensive deposits of tuberculosis in twenty days.

while pure tubercular material required a much longer time to produce less extensive tuberculous lesions. He therefore concluded that mixed infection favors the development of tuberculosis.

He showed one guinea-pig in which an inoculation of a pure culture of human tubercle bacilli had produced a peritoneal deposit of fourteen nodules of typical animal "pearl" tuberculosis, together with extensive ordinary tuberculosis of the thoracic and abdominal organs.

The presence of animal "pearl" tuberculosis in association with ordinary tuberculosis following an inoculation of a pure culture of human tuberculosis is a matter of great importance to general pathology. Most diseases which are pathologically a deep-seated phlebitis are symmetrical in their arrangement. The family tubercular history should be studied.

Lupus Nodularis of Hæmatogenetic Origin, A Case of. MAX WOLTERS. (*Arch. f. Derm. u. Syph.* v. 69, p. 83.)

The case, the study of which forms the basis of this article, was a man thirty-two years old, who had had plaques of lupus on the face for two years, the clinical history presenting no points of interest. The lupus nodules were excised and subjected to careful microscopical examination. They consisted of deposits which were of an oval form, and where several deposits united, of a cactus form, situated in the cutis and subcutaneous tissue.

These deposits followed the blood vessels and were both deep and superficial in their location. The cells of the deposits were chiefly epithelioid, with lymphoid cells on the periphery sending prolongations into the central mass. There were no typical plasma cells present; giant cells were present, but not numerous.

The microscopical appearance was in general that of an angiosarcoma, except for the presence of the bacillus tuberculosis. The capillary blood and lymph vessels were enlarged from obstruction of the deeper vessels. The chief pathological change was to be found in the veins of middle size, which presented nodules here and there projecting into their lumen, and producing partial or total obstruction. The nodules were composed of the same granulation tissue as that outside of the vessels. One would suppose that the granulation tissue contained in the veins was simply an extension of the tissue surrounding the veins and growing into them, as has been shown to occur in tuberculosis of the lungs, but such was not the case. Tracing the veins by serial sections and elastic fiber stains, the author found places where there were no cells surrounding the veins and where it could be seen that the disease began inside the vein and extended outward. The author believes that the lesions were produced by embolism from some distant hidden focus of tuberculosis.

Angiokeratoma and Family Tuberculides, the Tuberculous Nature of. L. PAUTRIER. (*Arch. f. Derm. u. Syph.*, vol. 69, p. 145.)

The author gives the theories which have been suggested as to the

etiology of angiokeratoma and the clinical and histological arguments favoring the view that it is a tuberculide.

Leredde was the first to suggest this possibility of diagnosis. The idea occurred to his mind because of the resemblance in the pathological findings in cases of lupus erythematosus and the tuberculides. In both conditions the disease begins as a phlebitis and endarteritis obliterans of the vessels situated deeply in the hypoderm.

Tuberculosis was present in three of the twenty-five cases of angiokeratoma reported up to 1893. Tuberculides occurring in families have only been studied during the past seven years, and the author reports the fourth recorded in literature up to the present time.

A young girl had lupus perneo, angiokeratoma and pulmonary tuberculosis, her father and uncle had lupus erythematosus and her mother's family had tuberculosis.

The same line of argument would make *acrodermatitis chronica atrophicans* a tuberculide. It is a deep-seated phlebitis and endarteritis obliterans. Clinically certain patches in the case of Fordyce could not be distinguished from lupus erythematosus. The *Pratique Dermatologique* recognizes the difficulty of differentiating these dermatoses.

Tuberculosis of the Skin Following Measles, A Case of Papular.

GAUCHER AND DRUELLE. (*Ann. de Derm. et Syph.* 1903, p. 947.)

The patient was a boy eight and a half years old, with no family history of tuberculosis. He was born in Syria and lived there until he was five years old, during which time he had repeated attacks of malaria, which have occurred during the past three years spent in France. He has had no enlargement of glands, and no joint or bone disease which could be attributed to tuberculosis. Two years ago he had varicella and one year ago diphtheria. Five weeks ago he was taken sick with measles, which lasted fifteen days and ran its usual course. Three weeks ago a non-pruritic eruption, accompanied with fever, appeared on various parts of the body. This eruption has steadily increased and none of the papules have disappeared except a few on the cheek.

On examination we find a monomorphous papular eruption, pea-sized and larger, rounded, of a dark red or bluish color, in the center of which there is a slightly depressed brownish crust, which was produced by the dessication of pustules. In some locations pustules are to be seen surmounting the papules. There is slight enlargement of the inguinal, axillary and submaxillary glands.

There are no lesions of the mouth or arms, and no rickets; there is a suspicion of tuberculosis of the apex of the left lung. The eruption is like that of acnitis. The patient died of tubercular meningitis a few weeks later.

Rhinoscleroma, the Treatment of, with Thiosinamin. Emil Glos. (*Wien. Klin. Wochensch.* 1903, No. 11.)

The author reports that good results have been observed in Chiari's clinic in reducing cicatricial stenosis in cases of rhinoscleroma by the use of thiosinamin.

Rhinoscleroma, Metastatic Disease of the Lymph Glands in. Alfred Kraus. (*Arch. fur Derm. u. Syph.*, vol. 68, p. 345.)

Formerly it was supposed that rhinoscleroma did not affect the lymph glands and the absence of enlarged glands was looked upon as an important symptom in diagnosis.

Róna published an article in 1900, in which he contended that this was incorrect and that a careful examination would show that the glands did become involved in this disease and that they contained the characteristic bacillus. This statement has met with considerable opposition.

Kraus reports two cases in which the lymphatic glands were examined. The first case was that of a woman sixty-nine years old, who had the disease twenty years, during which time it gradually extended from the alæ nasi to the mucous membrane of the nose until it produced total occlusion, which necessitated excision of the tumor mass.

The patient died of tubercular meningitis, and at the time of her death the naso-pharyngeal cavity and soft palate were affected. Huber has shown that the only way that the bacilli can be detected in gland tissue is to place small pieces of tissue on proper culture media in an incubator before fixation.

The gland tissue presents nothing characteristic in appearance. In the second case, which had existed three years, pure cultures of the bacillus were also obtained.

Rhinoscleroma, Cell Degeneration in. Mibelli. (*Monatsh. f. prkt. Derm.*, vol. 37, p. 378.)

The hydropic cells which are found in rhinoscleroma and which are ordinarily called Mikulicz cells are called "bubble cells" by Unna because they are spherical multilocular bodies like a soap or foam bubble. He believes that they are not characteristic of rhinoscleroma, but may be seen in granulation tissue, in malignant œdema and other œdematous inflammations of the skin.

Mibelli states that the bubble cells of rhinoscleroma differ from those seen in œdematous inflammations and he points out the following differences in the microscopical findings of the two conditions:

Mikulicz cells are more numerous than bubble cells; they vary in different sections of a given case; a tissue can only be identified as rhinoscleroma when Mikulicz cells are found; the rhinoscleroma bacillus is only found in degenerated areas which contain Mikulicz cells; in some sections nothing else can be seen in a given field; they are larger than bubble cells.

They contain cavities which are filled with bacilli; the cavities are larger than those of bubble cells; the light refraction and color reaction shows that the cavities contain bacilli which are embedded in a semi-solid homogeneous substance which is derived from cell protoplasm.

The bacilli cause culture media to liquefy, become sticky and cloudy and resemble the fluid which some observers report to have seen flow from the noses of patients affected with the disease.

The process is not an intercellular œdema. Unna's statement that many cells do not contain bacilli he found to be correct. The cell cavities are the result of physico-chemical changes produced by the bacilli.

The micro-organisms cause a cell infiltration and proliferation in the connective tissue of the skin, in consequence of which the bacilli form cavities in certain places; liquefaction results and nests of Mikulicz cells appear; sclerosis follows and the disease extends to new areas.

DISEASES OF THE SEBACEOUS AND SWEAT GLANDS.

By H. G. Klotz, M.D., New York.

Adenoma Folliculare Cutis Papilliferum, A Case of. Karl Kreibich. (*Arch. f. Derm. u. Syph.* 70, 3, May, 1904.)

A female, twenty-three years of age, had had since her birth a number of tumors on the neck and shoulder, which, beginning as small nodules, gradually grew to pea-size; then the skin would be detached from their surface and a wart-like growth would appear. These growths formed several groups situated on the center of the neck, extending to the right side, on the right ear, the right shoulder and the right side of the breast. They occupy mostly the region which Head has described as the fourth cervical or sterno-nuchal zone. The tumors therefore are characterized as a systemized nævus.

The histological examination showed that the principal portion of the tumor is formed by glandular tubules, which often are dilated into cysts or show papillary excrescences of their walls. All these tubules originate from the hair follicles or rather from the epithelial depression, from which normally are developed the hair and by lateral protrusion the sebaceous follicles. Upon the smallest lesions it can be distinctly recognized that the follicles which usually admit the hair papilla on the level of the outer propria, exhibit a lumen already on the level of the *pars papillaris*, that they assume the shape of a glandular tube, pass through the cutis propria in a more straight course and near its lower border form a convolute of tubular ducts communicating with similar convolutes, which, surrounded by a coat of connective tissue are situated between the septa of the subcutaneous fatty tissue. Sweat-gland ducts could nowhere be found in communication with the cysts, nor could real sebaceous gland tissue, as found in adenoma sebaceum, be anywhere discovered. Everywhere the

tubules showed a distinct lumen. The nævus is not a cellular one, nor does the new growth imitate any physiological tissue. Hence it seems justified to name the tumor from its anatomical changes. A certain similarity of the anatomical conditions to sweat glands suggest a critical review of cases heretofore published as adenoma of the sweat glands, particularly those of Brauns, Thierfelder, Petersen and others.

Naevi Syringoadenomatosi. M. Wolters. (*Arch. f. Derm. u. Syph.*, LXX., 375, June, 1904.)

The adenomata of the sweat glands, recently studied by Klauber and Thimm, form the subject of a paper by Walters, who has minutely described the histology of four small, wart-like, pedunculated tumors. Their clinical appearance did not allow of an exact diagnosis. Although solitary, they are classified among the nævi, because congenital. Histologically they are characterized by strands which extend from the epithelium into the deeper layers. Some of them persist as solid cords, cease growing after a short time and present button-shaped ends. Others form canalised ducts or tubules, which after a more prolonged course communicate with sweat glands, either normal or of approximately normal appearance, but not always normally located. A peculiar feature is the early transformation of the rete epithelium into high cylindrical epithelium; this rests upon a layer of cells, which W. is inclined to consider with Kölliker as a muscular layer. The tubules are all surrounded by a typical membrana propria. During the extension in the deeper portions, buds sprout in every direction, which again fork and branch, occasionally forming cysts, all showing the tendency to imitate the structure of the ducts by producing cylindrical epithelium muscularis and membrana propria. These shooting processes in some portions are responsible for the papillary appearance of the tumors.

After a review of the opinions of various authors, as Darier, Thierfelder, Török, Jadassohn, and others, and a critical consideration of the cases of Petersen, Bartel, Elliot, and Rolleston, W. would base the diagnosis of adenoma of the sweat glands on the following conditions:

1st. That the elements of the tumor represent as exactly as possible the type of the gland (epithelial layer, lumen and membrana propria).

2d. That it should be found in a region where normally glands are found.

3. That it should be due to a disturbance of development, etc., clinically congenital.

The Increased Occurrence of Sebaceous Glands on the Inner Surface of the Prepuce. Ernot Delbanco. (*Monatsh. f. Derm.*, 38, 536, 1904.)

On the inner surface of the prepuce in middle-aged men with abundant formation of smegma, numerous small yellow nuclei can be found. Micro-

scopically they are easily recognized as free sebaceous glands similar to those found in the mucous lining of the mouth. They usually surround the frenulum, being more numerous around the band. This corroborates the older observations of Kölliker, which had been contradicted by other authors.

BOOK REVIEWS.

Studien ueber die hereditaere Syphilis. Zweiter Theil: Knochenerkrankungen und Bewegungsstoerungen bei der angebornen Fruhsyphilis. CARL HOCHSINGER. (Leipzig u. Wien. Franz Deuticke, 1904. 567 S. 9 colored plates and 69 illustrations in the text).

Five years after the appearance of the first part of his "Studies of Hereditary Syphilis," Hochsinger has published Part II., which treats of the affections of the bones and motory disturbances as observed in the early stages of hereditary syphilis. The late appearance of the book, at least in part, is due to the author's desire to make available the results of radioscopy, which within the last few years has assumed such importance. The advantages of the numerous Roentgen-ray pictures seem to amply repay for the delay. The book, in addition to a complete survey of the literature of the subject, brings the results of the vast experience and the laborious and elaborate studies and researches of the author, which present many new and interesting facts and opinions. No doubt it will be fundamental for future studies of the subject and for the present affords the principal source of information of the bone lesions of early hereditary syphilis. The excellence of the colored plates and the numerous illustrations, principally the skiagraphs, largely contribute to the value of the book.

In the first part we find a brief delineation of the physiological formation of bone in the fœtus and a careful, more or less critical, review of the literature. The second part (pp. 85 to 194) treats of the pathological anatomy and histology of the affections of the osseous system. The following pathological conditions of the skeleton may be produced by syphilis: disturbance of growth and inflammatory processes of the epiphyseal cartilage, hyperplastic inflammatory processes of the periosteum, periosteal and endosteal processes of rarefication, abnormal formation of marrow spaces within the cartilaginous and osseous structures, excess of calcification of cartilage upon the epiphyseal lines, diffuse inflammatory cell proliferation starting from the endosteal marrow spaces, retrogressive changes of the diffusely affected marrow of the cartilage and of the bone, and peculiar processes of necrosis within the zone of proliferation and calcification of the hyaline cartilage and the zone of primary formation of marrow spaces. But the characteristic feature is always a diffuse inflammatory affection of the growing tissues originating from the blood vessels. Hence it becomes evident, why in the earliest stages it is rather difficult to distinguish between rachitic and hereditary syphilitic affections of the epiphyses. The most important changes occur in the long, hollow bones of the extremities, then follow the ribs, the short hollow bones, and finally the flat bones, which form the covering of the cranial cavity. In the different chapters are considered: the affections of the cartilages; changes in the zone of subchondral formation of marrow spaces; changes of the spongiose marrow in the ends of the diaphyses; disturbances of periosteal bone formation. The last chapter, entitled, anatomical considerations, describes the changes occurring in the flat bones, the ribs, the short, hollow bones, particularly the histology of phalangitis.

The largest part of the book (pp. 199 to 426) is devoted to the results of

clinical and radioscopic observations of the bone lesions and motor disturbances. In the first chapter it is shown, that affections of the ribs cannot be clinically recognized, principally because they usually do not cause any pain. Phalangitis, (dactylitis, osteitis of the short, hollow bones) is described as a distinct type of syphilitic disease occurring during the early period of extrauterine life, coincident with early skin eruptions, with no tendency to affect any of the soft parts or the skin or the joints, nor inclined to suppuration. Numerous radiographic pictures amply demonstrate the importance of the Roentgen-rays for the diagnosis, as it allows of the demonstration during life of pathological conditions which cannot be discovered or even guessed by any other means. This is also shown to be the case in regard to the long hollow bones in the next chapter, illustrated by radiographic illustrations and by reports of cases from the author's own observation. The affections of the long bones become clinically manifest by the intumescence of the epiphyseal ends of the bones and by disturbances of the motility of the affected member. Anatomically, there are cases with evident changes of the bones or of the muscles or without any palpable changes. The functional disturbances may be paralytic or spastic and may cause irregularities of motion or of the posture of the extremities. Many cases described as pseudo-paralysis are really what the author has previously named, "myotony of hereditary syphilitic infants," a general continuous spasm of the muscles, which, independent of bone lesions, may be due to some affection of the nerve centers or possibly to the influence of some toxins on the muscles themselves. The pseudo-paralysis of Parrot with its peculiarities, mostly restricted to the upper extremities, is the subject of the next chapter, then follow painfulness and anatomical changes in the muscles, which heretofore have hardly been mentioned or described. They are caused by the spreading of the inflammatory process from the periosteum to the insertion of the muscles. Of great interest is the next chapter, which contains a report of the author's own experience, founded on tables of 98 cases, with quite a number of histories of cases of pseudo-paralysis. The differential diagnosis of pseudo-paralysis is next considered (paralysis due to injuries during birth, tuberculous and simple inflammatory affections). The last chapter is devoted to affections of the joints; they are of rather rare occurrence in the early stages of hereditary syphilis in comparison with later periods.

The fourth part of the book treats of the relations between syphilis and rachitis; the author's own researches and observations being added to a careful scrutiny of the literature. Other chapters take up the affections of the bones forming the skull, syphilitic hydrocephalus and its diagnosis and the effects of syphilis on the nose, concomitant changes of its shape and destructive processes. The large experience of the author and his careful investigations are everywhere in evidence in the description of these important affections as throughout the book.

H. G. K.

THE JOURNAL OF
CUTANEOUS DISEASES
INCLUDING SYPHILIS

VOL. XXII. NOVEMBER, 1904. No. 11.

NOTES ON CERTAIN POST-VACCINAL ERUPTIONS.

By WILLIAM THOMAS CORLETT, M.D., of Cleveland.

Read before the twenty-eighth annual meeting of the American Dermatological Association, Niagara Falls, June 2 and 3, 1904.

THERE has been in the city of Cleveland during the past five years unusual opportunities of observing various complications and sequelæ associated with vaccination. It is not the intention, however, to take up the general subject of disturbances associated with vaccination, but rather to report a series of cases which have come under the writer's observation.

In making this report I shall begin with the cases in which the disturbance began in the vaccinal lesion, and appeared soon after vaccination, and then proceed to those in which the vaccinal lesion was less closely associated, and conclude with the cases in which vaccination, although the alleged cause, apparently had little or nothing to do with the subsequent eruption.

Case 1. J. R., female, aged twenty-five, unmarried, was seen March 30th, 1899. The family history was negative so far as anything bearing on the present condition was concerned. She said she was vaccinated for the first time by the family physician March 4th, 1899, somewhat more than three weeks before the case was seen by the present writer. Three inoculations were made on the upper third of the right arm. Two of the lesions promptly healed without producing characteristic vaccinal lesions. The third matured, and she said was considered by the medical attendant to be a normal vaccination pustule. As the lesion dessicated there appeared at the periphery an undermining of the epidermic layer with a transparent serous fluid. The process extended, and in some places measured about one centimeter beyond the original margin. With mild antiseptic treatment, consisting of an application of boric acid in the form of an ointment, the process

subsided and resolution took place with the formation of a reddish cicatrix apparently involving the superficial surface of the derma. (Pl. XLI., Fig. 4.)

Case 2. M. H., male, aged twenty-two years, antecedents said to be good, was vaccinated by his family physician, June 8th, 1900. Three punctures were made extending in a circular direction around the upper third of the right arm. Patient had never been previously vaccinated. Two of the inoculations ran a very mild course and disappeared without producing characteristic lesions. The third or center inoculation became painful and red in appearance. The case was presented to me July 4th, 1900, on account of certain peculiarities observed in the lesion now remaining. Upon examination I found in one of the original sites of vaccination quite a deep-seated destruction of the derma in which resolution was taking place. With the subsiding of what was considered a normal though severe vaccination, there appeared at the periphery and extending more especially in the long axis of the arm, the formation of a serous exudate under the epidermis which resembled what one often meets with in impetigo bullosa. The epidermis was easily ruptured, exposing a reddish surface glazed with a serous exudate. The eruption healed in about six weeks with a one to two thousand bichloride dressing, followed with zinc ointment.

These cases would scarcely be considered worth noting were it not for the fact that they form a connecting link with the vaccinal lesion, and that they first appeared after the active inflammatory action of the vaccination had disappeared. They probably correspond to the case reported by Norman Walker (*Brit. Med. Jour.*, 1901, p. 1201), in which, after the crusts had fallen off fresh activity took place in the vaccination area with the formation of vesicles.

Case 3. L. S., female, aged sixteen, consulted me on account of deep ulcerations which had followed vaccination. The family history was good. The patient was large for her age, of good color and had never had any serious illness. The case was first seen September 29th, 1902. She had been vaccinated about five weeks previously. According to the patient's statement about five days after being vaccinated the lesion began to swell and gave rise to considerable pain. The case went through the early stages of what was considered a severe vaccination until two deep ulcers formed, when the case came under observation. Upon examination I found two ulcers about three centimeters in diameter on the anterior surface of the upper third of the right leg, just below the head of the fibula. The case presented in a severe form what the writer has not infrequently seen in women after

vaccination on the leg. In this region the vaccinal lesions are commonly termed "severe" and usually leave deep cicatrices. This is probably caused by the entrance into the wound of pathogenic substances which are stirred up from the street. The reverse of this necrotic action is met with a granuloma or strawberry excrescence at the site of vaccination, a few instances of which have come under the writer's observation. Gardua (*Brit. Med. Jour.*, 1897, Vol. 1, p. 134) reports an interesting case of this kind.

The case herein reported especially brings to mind the one observed by Graham Little (*Brit. Jour. of Derm.*, 1900, p. 60), in which a child was vaccinated in four places; two of the scabs fell off in a short time, but the remaining two never healed perfectly, and six weeks after vaccination *pimples* developed in the site of the vaccination, which passed into *large sores*. Finally they became dry and assumed the character of lupus vulgaris. The surface of the patches, however, was fissured and *unusually scaly*. No signs of tuberculosis elsewhere, and no family history of tuberculosis.

Case 4. Male, aged sixteen, father died young, cause unknown, mother still living and apparently in good health. The patient has brothers and sisters who are also reported to be well. Aside from measles, scarlet fever and chickenpox, never had any illness. He was vaccinated for the first time in May, 1898, and nothing unusual was noted until three weeks after the crusts had fallen off. According to the mother's statement blisters appeared at this time, first on the trunk, later on the extremities, which increased in size, ruptured easily and discharged a clear fluid. The eruption extended to different regions of the body, as shown in the plate. (Pl. XLI., Fig. 5.) The patient entered Lakeside Hospital November 16, 1898, where he remained three months. There was some constitutional disturbance although the temperature never registered higher than 101 degrees. He was not entirely free from the eruption when he left the hospital. In about two months, April 3d, 1899, he returned for treatment and at this time many new blisters had formed. The case was finally discharged, June 4th, 1899, although the skin had not wholly resumed its normal condition. He has not since been heard of. This case seems to belong to the Clinical variety previously reported to this Association by Dr. Bowen (1900) and possibly those of Dr. Howe (1902).*

*Pardee (L. C.) reported two cases of herpes iris or erythema exudativum bullosum (Johns Hopkins Hosp. Reports, 1898, Vol. 9, p. 165), one case appearing soon after vaccination. In both the clinical picture and pathological findings were the same.

Galloway (*Brit. Jour. of Derm.*, 1902, p. 176) has likewise observed a case of bullous dermatitis following vaccination in a healthy young man in whom the vaccination was uneventful, and not especially severe. About one week after the vaccinia had run its course, there appeared vesicles on the right cheek, thence spreading to other parts of the body. The clustering of the lesions suggested to this observer dermatitis herpetiformis, a feature reported in some of Dr. Bowen's cases and likewise observed in Dr. Pusey's case (*Jour. of Cut. and G.-U. Dis.*, 1897, p. 158). On the whole, however, the case herein reported conforms more closely to that reported by Sequeira (*Brit. Jour. of Derm.*, 1902, p. 174), of a man suffering from pemphigus following vaccination. The vaccination lesions healed in fourteen days. Three weeks later bullæ appeared on the forearms, varying in size from a split pea to the half of a walnut. In that case the bullæ appeared to arise from the normal skin without any surrounding dermatitis.

Case 5. R. F., female, aged eleven, applied for treatment at Lakeside Hospital Dispensary, June 5th, 1901. The mother stated that the child had been vaccinated about three weeks previously by one of the public vaccinators. Concerning the family history nothing could be elicited bearing on the case. The people were uncleanly, living in one of the thickly settled parts of the city. On examination the arm was found wrapped in a pus-saturated-roller bandage which the mother said had been applied at the time of vaccination and had not been disturbed. On cutting away the bandage, a pus-covered area about five centimeters in diameter was exposed. The lesion was situated above the middle of the arm and consisted of a central area denuded of epidermis with a margin of from one to two centimeters broad of loosely adherent epidermis, such as one sees in pemphigus foliaceous. Underneath was found quite a copious sero-purulent exudate. The line of demarkation between the normal integument was less abrupt than in the cases previously reported, although as shown in the half-tone (Pl. XL., Fig. 2) it was fairly well defined. With cleanliness and the application of zinc ointment the eruption disappeared in about three weeks, leaving, however, a bluish-red scar. This case serves to explain the cause of many of the complications and sequelæ of vaccination.

Case 6. R. H., male, aged twelve years, seen at Lakeside Hospital Dispensary, October 2nd, 1902. Nothing could be ascertained as to his family history and previous condition. He seemed to be in normal health and stated that he had been vaccinated about three weeks previously by one of the public vaccinators. He had a very sore arm, which was slow in healing. Finally an eruption appeared on the arm,

for which he sought relief. Upon examination the former vaccinal scar was plainly visible, which indicated that much suppuration had taken place leaving a distinct scar without the characteristic pits of a successful vaccinal lesion. Over the lower half of the deltoid muscle were three scaly patches about a half-dollar in size, and irregularly roundish in outline. There was a tendency in one of the lesions to heal in the center while the margin was more prominent. In most of the lesions the line of demarkation at the periphery was not especially pronounced, less than is usually observed in psoriasis although slightly more so than one expects to find in eczema. The lesions were thinly covered with rather small scales which were adherent and of a yellowish or light-fawn color. On the lower part of the arm and forearm were a number of less prominent lesions of a furfuraceous character, while others still less pronounced appeared on the trunk and face. These looked like patches of seborrhoic eczema, while the large ones first described resembled more closely the lesions of psoriasis. There was but little itching complained of. The case returned for treatment three times at intervals varying from ten days to two weeks. He was gradually improving and the lesions had well nigh subsided when last seen.

Case 7. Mrs. L. H., aged twenty-seven, was referred to me May 7th, 1902, for a peculiar eruption which she said had followed vaccination. The family history was given as follows. Father still living, aged forty-eight, mother died in child-birth at the age of forty-two. Patient has six brothers who are all in good health. Grandparents died of old age. Patient is a blonde, has always had fairly good health; has two children, aged four and six respectively, who are reported to be healthy. Physical examination revealed no evidences of tuberculosis in the internal viscera, nor could any history of syphilis be obtained. She says she was vaccinated for the first time in December, 1900. Ten days later she "came down with smallpox." The eruption which followed was not plentiful, but she felt very ill. Upon further questioning she said that the smallpox made its onset just as the vaccination was beginning "to work." The vaccinal lesions never fully healed, although they gradually became smaller. She further stated that in September, 1901, the sites of the former vaccination began to give some annoyance, and new spots appeared. These gradually became more numerous, and at the time of the first examination (May 7, 1902,) were well marked over the back, chest, face and arms, although other parts were not wholly exempt. (Pl. XLII., Fig 6.)

The lesions apparently belonged to two types of eruption, one deep-seated with loss of structure while the other was superficial, pink-

ish in color and covered with branny or furfuraceous scales. The former condition resembled scrofuloderma, while the latter corresponded to what is known as eczema seborrhoicum. The lesions in the former were dark-red in color, covered in some places with a thick crust with a deep-seated destructive process underneath. No enlargement of the lymphatic glands could be detected. Resolution was slowly taking place when first seen, leaving deep scars. The eruption gave rise to little inconvenience aside from the disfigurement.

Upon reviewing the early history, the patient stated that the vaccinal lymph was carried in a tube, that it did not produce any ill effect in others vaccinated at the same time, although it failed to produce a successful inoculation in her two children and the patient's mother. It may be further stated that none of the latter had variola at the time, although occupying the same house, nor were the children, at least, immuned by vaccination. In my opinion some uncertainty may reasonably be entertained as to the diagnosis of variola in this case, although one must admit such a possibility, especially under strict quarantine measures. Had the vaccination been successful one might attribute the subsequent generalized eruption to vaccinia, of which numerous examples are reported. Abraham (*Brit. Jour. of Derm.*, 1896, p. 332) reports the case of generalized vaccinia in an infant who developed pustules which appeared on the thorax and face thence spreading more or less over the whole body and which went through an evolution apparently similar to that of the original vaccinal lesions. This might be mistaken during an epidemic for variola. In Graham Little's case, previously cited, there appeared large sores which formed slowly as in this instance. P. Lacour (*Lyon Méd.*, 1889, lxi., 537) also reports generalized vaccinia in a patient suffering from eczema which terminated fatally.

The case herein reported was under observation for about ten months and made a gradual improvement. Finally the scaly patches disappeared, and the ulcerating lesions healed.

Case 8. J. S., aged fourteen, female, applied to the Lakeside Hospital Dispensary with the following history: She was vaccinated by a public vaccinator in January, 1904. The lesion was slow in healing, and in disappearing left a large cicatrix. Patient's father stated that about one month after vaccination the present eruption appeared. Several other children in the family were vaccinated at the same time, without ill effects. On examination, the vaccinated area was indicated by a quarter-dollar-sized, dark-red cicatrix, which indicated that a severe inflammatory action had taken place. The scar was glazed and

without puncta. On the forearms, and to a less extent on the legs, were found about a half-dozen, half-dollar-sized lesions of a roundish or oval outline, pinkish in color, and covered with a thin layer of branny scales. Upon removing the scales, a serous exudate was observed. The eruption was most marked on the extensor surfaces, and itching was moderate. The eruption was neither typical of eczema nor psoriasis. The case is still under treatment and is very intractable. (Pl. XL., Fig. 1.)

Case 9. A. N., male, aged thirteen, applied at the Lakeside Hospital Dispensary November 1st, 1902, when the following notes were taken: Patient has three cousins on the paternal side afflicted with psoriasis. Nothing further of importance in the family history could be elicited. In July, 1901, the patient said he was vaccinated although it did not "take," the "spots," however, never fully healed. According to the patient's account it remained red until the following January (1902), when the present eruption appeared. He further stated that the present eruption "broke out" on various parts of the body, and the vaccinated area became scaly. The spots increased in number and extended somewhat in area, although for the most part he said no especial change had occurred in the character of the eruption. When examined the lesions presented a branny desquamation rather copious, and the scales were whitish and adherent. The tips of the elbows and the anterior aspect of the knees were free. The case was seen from time to time, and the eruption was gradually disappearing. After about eight months, the patient failed to report. A diagnosis of psoriasis was made. (Pl. XLI., Fig. 3.)

In this case it is difficult to attribute more than a casual relation between the vaccination and the subsequent eruption. One not infrequently sees psoriasis appearing in areas subjected to local irritation, as from the rubbing of suspenders in men and underskirt-bands in women, yet it would be irrational to attribute psoriasis to this cause. So in this case, there doubtless existed a strong predisposition which any local irritation might have brought into activity. In this connection, Rohé has reported two cases of acute psoriasis following vaccination (*Jour. of Cut. and G. U. Dis.*, 1882-3, Vol. 1, pp. 11-14). Weinstein (Abstract from *Brit. Med. Jour.*, May 31st, 1902), reports the case of a soldier aged twenty-two vaccinated with calf lymph in two places on left arm, in October, 1900. The vaccine pustules were succeeded by *red scars*. Early in February they were covered with white scales, which became more marked until they presented all the characters of psoriasis. For a month the scars were the only parts affected, but the disease then spread to left elbow and thence to other

parts of the body. Weinstein has collected twenty-four cases in which psoriasis appeared at varying intervals after vaccination. In most of these the patients were healthy and there was no history of previous psoriasis.*

Case 10. E. W., female, aged twenty-one, consulted me May 21st, 1904, for a scaly eruption which she said was due to vaccination. The following history was obtained from both the patient and her father who accompanied her. The family history was exceptionally good so far as longevity was concerned, and no history of any cutaneous disease could be brought out. The patient was the only child, and enjoyed normal health, was vaccinated at the age of six years in two places without any eventful circumstance occurring at the time. Some time during the first year thereafter, the exact date could not be ascertained, the present eruption began, first appearing on the side of the chest, thence appearing on various parts of the body as seen at present. The patient stated that the eruption had always been dry and scaly. When seen the lesions consisted of roundish or oval plaques covered with furfuraceous scales, scattered discretely over the body. The forearms, notably about the vaccinal scars, face and scalp were most freely studded, while the lower extremities were to a less extent involved. The patient stated that the eruption is very much better in the summer months, and on one or two occasions had almost wholly disappeared, and that it is always aggravated during the cold weather. The vaccination scars consisted of one dime-sized and one pea-sized lesion. The patient has never been vaccinated since. In this case, no conclusive evidence could be brought out, connecting the eruption with the previous vaccination, which disappeared without attracting especial attention. The appearance of an eruption which is fairly common in all classes of people would not be worthy of consideration were it not for the fact that the disease was attributed to vaccination.

Case 11. Mrs. H. L. B., aged thirty-nine, sought relief on May 15th, 1904, for a disfiguring eruption on the face, which, she said, had appeared soon after vaccination in November, 1902. The previous history of the case as given by the patient is as follows: Nothing could be elicited from the family history especially bearing on the present condition, excepting that the mother is said to have had eczema after the menopause. The patient was first married when young, and has two boys, aged fourteen and sixteen, living and well. No history of miscarriages. Her second marriage was contracted about two years

*Rioblanc (G.) has published one case of what he terms "Psoriasis Vaccinal," (*Ann. de Derm. et Syph.*, 1895, p. 880.)

ago. A child was born about a year ago, which was never well. The mother stated that when born, "it was as white as snow" and was found dead on her arm one morning when she awoke, seven weeks later. "The doctor said it died of heart trouble." The patient said she was vaccinated at the age of nine years, and again two years ago, it being necessary to vaccinate her three times before it "took," as she expressed it. She then had a very sore arm, and for a time said her life was despaired of. She was obliged to take morphine to quiet the pain, and the arm remained sore for several months and the vaccinal area discharged for about a year. Being questioned as to whether the patient had ever previously taken morphine, she admitted she had. In November, 1903, or nine months ago there appeared just anterior to the left ear a reddish area somewhat kidney shaped, about a quarter-dollar in size, and covered with a few adherent scales. Some smaller spots appeared near the angles of the mouth which increased in size until they were as large as a twenty-five-cent piece. At first the lesions were on a level with the skin. Soon after this, what was considered to be a boil appeared on the left thigh, just above the knee. This the patient stated was very painful, and necessitated her remaining in bed for several weeks, and when she moved about she was obliged to use a crutch. During the six months preceding the time the case came under observation, she had been treated with the Roentgen rays.

Examination as to her present condition revealed a dark-red eruption sparely covered with adherent scales on the face, involving the cheeks just anterior to the ears, forehead, scalp and upper lip, angles of the mouth and to a less extent over the nose, passing down in the form of broad bands under the malar bones. A cluster of smaller, irregular outlined, pea to dime-sized lesions were found on the outer aspect of the right arm, surrounding a dark blue vaccinal scar. On the right thigh, above the knee a pigmented dark patch about the size of a quarter-of-a-dollar was also found. The mucous membrane of the mouth was likewise, although to a less extent, involved.

The eruption on the face was fairly symmetrical, and appeared to be elevated above the normal skin, although in most of the lesions the margin was not especially prominent. The line of demarkation, however, was distinct. It was thought that the appearance of the eruption might have been modified by treatment to which she had been subjected. A positive diagnosis was not made, although a strong suspicion of syphilis was entertained. The eruption on the face for the most part resembled that of lupus erythematosus although no sebaceous plugs could be found, and a ring-shaped lesion on the forehead at the margin

of the scalp was suggestive of a luetic origin. The patient was given potassium iodide. She remained in the hospital for one week, and when she left the eruption seemed slightly less prominent. On May 28th, the patient wrote that she was much better. In this case vaccination had probably nothing to do with the eruption. On the other hand, vaccination in a syphilitic subject, and the eruption which appeared later modified by repeated exposure to the X-rays, would, in the writer's opinion, account for the phenomena herein presented.

In conclusion it may be said in reviewing the histories of the foregoing cases that there are undoubtedly instances of post-vaccinal eruptions, although in many of the affections attributed to vaccination no connection can be established between the vaccination process and the subsequent disease. Naturally, vaccination being so universally performed in all civilized countries any disease might be called a post-vaccinal affection occurring in one previously vaccinated. At the same time, while there seems to be no uniform cutaneous manifestation such as is very generally observed after the use of diphtheritic antitoxin, there are affections which are indubitably associated with vaccination, and may be properly called post-vaccinal eruptions. That these eruptions are peculiar to vaccination, some difference of opinion exists; the writer believes such a claim has not thus far been fully established, because similar conditions are met with in the unvaccinated. (Pardee.)

The following résumé, however, seems warranted at this time: Post-vaccinal eruptions may be provisionally divided into four classes: The first class contains those which are associated with or soon follow the subsidence of the vaccinal lesion. They may be divided into, (a) deep-seated ulcerations at the site of inoculation, (b) moist undermining of the epidermis at the periphery of the dessicating vaccinal lesion and (c) granuloma or strawberry excrescence.

The second class contains the bullous eruptions which have no especial distinguishing features. The third class comprise scaly eruptions which usually occur several weeks after vaccination and may or may not develop near the site of inoculation. A fourth class may possibly be added including scrofuloderma and lupus.

The etiology of these post-vaccinal eruptions is doubtful, but the writer believes that they probably depend upon (a) impure vaccinal virus, (b) uncleanliness at the time of vaccination, or before complete resolution has taken place, allowing the inoculation of various pathogenic organisms; and (c) possibly the local disturbance caused by the vaccinal process in a subject of low resisting power, or one having a strong predisposition to some cutaneous disease.

PLATE XI.—To Illustrate Dr. W. T. Corlett's Article.

Fig 1.

Fig 2.

PLATE XLI.—To Illustrate Dr. W. T. Corlett's Article.

Fig 3.

Fig 4.

Fig 5.

PLATE XLII.—To Illustrate Dr. W. T. Corlett's Article.

Fig 6.

DISCUSSION.

Dr. Jay F. Schamberg expressed his pleasure in having listened to the interesting and instructive paper of Dr. Corlett. The responsibility of determining whether a causal relationship existed between vaccination and various cutaneous diseases naturally fell on the dermatologist. He should be extremely guarded in expressing an affirmative opinion under such circumstances unless fully warranted by the facts.

A small body of antivaccinationists was waiting for any information which could be used to discredit vaccination. The medical profession was ever ready to admit and proclaim the truth, but where facts and figures were going to be wilfully exaggerated and distorted, and where such action was apt to redound to the injury of the human race, evidence must be thoroughly sifted and resifted before definite conclusions adverse to vaccination were to be formulated.

It appeared to be a judicial weakness of the lay mind to confound sequence and consequence. Vaccination was the most universally performed of all operations. The vast majority of people of the civilized world subject themselves one or more times to it during their lives. In the city of Philadelphia during the past few years over 500,000 people, or about one-third of the population, availed themselves of the protective influence of vaccination.

No one had ever claimed that vaccination conferred immunity against subsequent skin diseases. If it did not, it must occasionally happen that a cutaneous disease would make its appearance within a short period after vaccination. There were doubtless many eruptions which bore no relationship to vaccination, save a chronological one. The eruptive disorders that seemed to be caused, at times, by vaccination might be due to one of two conditions: (1) wound infection, and (2) constitutional commotion. Considering the frequent maltreatment of vaccination sites by children, it was surprising that complications from wound infection did not more frequently develop.

The cause of the bullous eruptions which had been recorded by a number of observers as following vaccination was undetermined. Whether the affection was due to an impurity of the virus, or foreign infection of the vaccine site at the time of or subsequent to vaccination, time and future research must determine.

The occurrence of these bullous eruptions in those who have not been vaccinated should cause physicians to reflect and consider whether vaccination was really a factor in their production.

Vaccinia was an acute infectious disease and might, doubtless, like scarlet fever, measles, and allied affections, occasionally excite the appearance of an eczema or a psoriasis in persons predisposed to these disorders. It must be remembered that vaccination had also occasionally determined the disappearance of eczema and psoriasis. These changes were doubtless

brought about by what the older writers called a "constitutional commotion."

Dr. Douglass W. Montgomery said that he had always looked upon these bullous pustular lesions following vaccination as pyogenic affections. He recalled particularly the case of a young baby, one of those light-haired, fine-skinned children that were apparently prone to any kind of infection. She had had a number of attacks of grippe, was a capricious eater, and had always been delicate. This child was vaccinated when very young, and shortly after the appearance of the vaccination sore, a roseola, resembling a syphilitic roseola, appeared. At the same time she developed a high temperature and was somnolent, and, in fact, was very ill; he was positive it was not syphilis, and had always attributed it to the vaccination.

Dr. John T. Bowen said that with regard to the bullous type of lesions following vaccination, he thought there were two distinct varieties. Case No. 4 of Dr. Corlett's series corresponded with the cases that he had described and published in his paper on bullous eruptions following vaccination in children. Of this type he had seen ten or twelve cases—three or four since his paper was published. He had also seen several of the same type which had not followed vaccination. These were exactly of the same type as those following vaccination in children, which, to his mind, corresponded closely to dermatitis herpetiformis, although it was a very pure bullous type. Then there was another class of cases which Dr. Corlett had—wrongly, he thought—put with the cases he described. These were the cases described by Dr. Howe, of Boston, in which there was an acute infection, with high temperature, and most of them ended fatally. They were like acute pemphigus, occurring particularly in butchers. In a recent issue of the Journal of Cutaneous Diseases he described such a case occurring in a butcher, and discussed the possibility of its association with foot and mouth disease.

Dr. Gilchrist said the bullous type of eruption which had been described had been seen in Baltimore, and it always followed vaccination. One of the cases was worked up very thoroughly by Dr. Pardee, of Chicago, who found that it was not a pyogenic infection. He demonstrated that the vesicles were sterile, there being no organisms in the bullous lesions. The formation of the vesicles was similar to those of dermatitis herpetiformis, but the subsequent picture was not the same.

ERYSIPELOID, WITH A RECORD OF 329 CASES, OF WHICH 323 WERE CAUSED BY CRAB BITES, OR LESIONS PRODUCED BY CRABS.

By T. Caspar Gilchrist, of Baltimore.

Clinical Professor of Dermatology, Johns Hopkins University.

Read before the twenty-eighth annual meeting of the American Dermatological Association, Niagara Falls, June 2 and 3, 1904.

IN May, 1896, I read a paper before the section of Dermatology of the American Medical Association, entitled, "A Special Form of Dermatitis, due to Bites or Lesions Produced by Crabs," based upon 156 cases which had been seen chiefly at the Johns Hopkins Dispensary.

A summary of the paper was published in the *New York Medical Record*, of 1896, Vol. 49, p. 783. The paper was not published in full because the writer was dissatisfied with not having obtained any positive results while seeking for the cause of the disease. The subject has been taken up a number of times since 1896, and discontinued because the results were always negative. Many cultures have been taken, inoculation experiments have been made and the crab juice has been experimented with, but all to no purpose. I am at present still trying to find the cause of this disease, and although the work is not finished, yet I thought it might interest you to know at this stage some of the details of the work which has been done, as well as give a clinical description of the disease.

It is very singular that no published reference whatever, except my own, has been made to this special form of dermatitis, which is fairly common in Baltimore in the summer months when crabs are in season, whereas the variety of erysipeloid which is due to inoculation of dead animal matter or fish is rarely seen. It seems to me that many cases must have been seen in other cities where crabs are prevalent and eaten as a food.

Similar eruptions of the skin have been recorded by European observers under different titles, e. g., erythema serpens, erythema migrans, erysipelas chronicum, etc., but none of them has been due to lesions produced by crabs. All these varieties were grouped under one title of erysipeloid by Rosenbach in 1887.

In 1870 Tilbury Fox referred briefly to two cases of erythema of the hands, which he thought was produced by dyes. The hands be-

came red and swollen in different places, although the lesions began at one spot. In the first case the eruption was produced by the dye on cheap kid boots, and in the second case the patient was an inspector of clothing.

In 1873, Morrant Baker described a disease of the skin, occurring in London, under the title of "Erythema Serpens," which he thought was due to the handling of spoiled meats or fish. He refers to sixteen cases which he has recorded, but he notes that he had seen as many more, especially among butchers. The disease is a mild, inflammatory, pinkish erythema, which is distributed in blotches or patches, due to the breaking up of the spreading edge, and distributed chiefly about the finger joints or knuckles and with but little swelling. The pain is considerable, yet the lymphatics are never affected. There is always a history of a slight injury a few days before, but on examination only a perceptible scar can be found. If seen early, the scar forms the center of the erythematous patch or patches. As the disease spreads peripherally in a blotchy manner, the central portion apparently gets better. The author describes the progress of the disease as being rather "freakish," i. e., the margin of the lesion becomes broken up, leaving pink and tender erythematous spots distributed here and there. (A colored plate, accompanying the article, shows the arrangement.) The prognosis is always favorable; there was never any tendency to suppuration, or to affect deeper parts. The average duration of the disease was about three weeks. (Two to six weeks.)

In 1884, and later in 1887, when the disease was described in greater detail, Rosenbach gave the apt title of *Erysipeloid* to this disease. It was produced, the author said, by inoculation into the skin of the finger or hand of dead or decomposing animal matter or fish, or even foul cheese.

It is most frequently met with in cooks, kitchen workers, butchers, and those who handle game, fish, and in shopkeepers who handle cheese or herrings.

The eruption consisted of a slowly progressing, slightly elevated, well defined, rather violaceous—almost livid—red zone, which develops around the seat of inoculation. The lesion spreads peripherally, and the central portion fades away without desquamation. There is usually burning, pricking or itching.

No constitutional symptoms are ever present, nor are there any signs of lymphangitis or glandular enlargement. The disease usually disappears spontaneously in one, two or three weeks.

With reference to the etiology, Rosenbach obtained a pure culture

on gelatine, which he found was the best media, from a case of erysipeloid acquired from foul cheese. The culture at first appeared to consist of cocci-like bodies, but later a mould-like growth appeared, which assumed a grayish-brown in color as it grew older. The author inoculated his own arm in three places with the pure culture. A reddish spot appeared forty-eight hours afterward, and three days later a well-defined, raised erysipelatous-like patch had formed, which spread peripherally with an apparent clearing up in the center. The disease then appeared to have died out, but, four days after, a wider ring of redness reappeared, and it reached the size of 24 x 18 cm., then gradually disappeared.

Inoculation experiments with the pure culture into four rabbits yielded negative results. The author also tried to inoculate the disease on a case of lupus, but failed to get any results. Rosenbach likened his organism to one discovered a short time previous by Cohn, who called his organism Cladothrix Dichotomie.

In 1886, G. T. Elliot recorded a case of erysipeloid in a woman, who had four attacks of the disease. The first attack appeared on both palms, three years previously, and it lasted four weeks. The second attack was limited to the left palm, one year later. The lesion seen by the author commenced as a small red spot on the left palm, and it involuted as it spread over the palm, so that later it formed a narrow zone of violaceous redness. The disease also appeared on the feet. Only erythematous redness was noticed, and itching and burning was present. Ichthyol ointment was used with success. One month later a relapse occurred on the left palm, as two incomplete circles on the toes of the right foot. The author does not refer to any cause for these attacks.

In 1894, S. Filsenthal reported four cases of (zoonotic) erysipeloid; on three occasions he cultivated Rosenbach's micro-organism.

In 1893, at the New York Dermatological Society, Fordyce showed one case of a colored boy, who had redness and swelling of fingers on both hands, and later it extended to palms. It was diagnosed as erysipeloid.

In 1899, W. Anderson exhibited a case before the London Dermatological Society, and referred to the fact that erysipeloid had long been familiar at St. Thomas' Hospital, among those engaged in the provision trade.

At the same meeting, Colcott Fox remarked that the disease was not common in the skin departments of the London Hospitals. He had only seen one case, and that recently.

In 1898, E. Delbanco says that out of 1,100 patients in Unna's Polyclinic, in 1897, only four cases of erysipeloid were seen. In a case of this disease in a woman, who got the eruption from a scratch with a fish bone, Delbanco failed to find any micro-organism in sections or by cultures. Pathologically, the disease consisted of an inflammatory œdema and numerous mastcells.

As I have mentioned in the title, I have a record of 323 cases of erysipeloid due to crab bites or lesions produced by crabs, and six cases due to inoculation with other agents, viz., four from fish bones, one from meat and one from pigs' feet. I am indebted to Dr. Halsted and Dr. Finney for allowing me to refer to the cases which have occurred in earlier years in the surgical department of the Johns Hopkins Hospital.

The disease usually makes its appearance about June and disappears about the end of August or early in September, i. e., when hard crabs are in season as an edible dish. We are so accustomed now in the Johns Hopkins Dispensary to seeing the disease that it is usually recognized at a glance as the patient enters the room for diagnosis. Dr. Finney, in 1892, exhibited some cases before the Johns Hopkins Medical Society of what was then designated as "Crab Cellulitis." He, together with Dr. Wright, now of Harvard, made a number of cultures and coverslip preparations from the cases, but failed to obtain any positive results. Later, Dr. Abbott and Dr. Livingood made a number of examinations, but with negative results. None of these investigations have been published.

The observations which have been made on our cases are as follows:

1. *The Incubation Period.* This was, in the majority of cases, about two days after the inoculation; in a few instances it was as short as twelve hours and in one case three hours, and in rare cases as long as a week elapsed before the eruption appeared.

2. The duration of the disease, when the patient applied for treatment, was about a week. In many cases it was only three or four days, and in many others it extended from ten days to two weeks.

3. *The Distribution.* In practically all the cases the disease occurred on the fingers or hands, there being only two cases where the lesions appeared on the soles of the feet. With the exception of the little finger, the thumb, fingers and hand were all about equally liable to be the seat of the primary lesion. The right and left hands were also about equally affected. In very many cases, only one thumb or one finger would be attacked when the patient applied for treatment.

4. *The Character of the Disease.* The history is practically always

that of a bite or injury from a crab. There is usually a small abrasion of the skin, which, as a rule, is so slight as to attract very little notice, and which can rarely be found when the case comes under observation. Within a few days, in most cases two days, however, there appears around this lesion a painful, red swelling of the skin. The description of a selected case will illustrate the usual course of the disease. The index finger was bitten near the tip, and the resulting lesion, which was slight, could not be found when the case came for treatment; in the meantime, two days after the injury, the end of the finger became red, swollen, painful, hot, and accompanied by a throbbing sensation. The lower border of the eruption presented a distinct line of demarcation, and was slightly raised. The disease then extended slowly down the finger to the base, after which it began to climb the adjoining finger on the proximal side, until it reached the tip, when it descended the opposite side until the whole finger became gradually affected in the same manner as the index finger. The eruption, in this way, if left alone might attack all the fingers, and encroach on the back or palm or both sides of the hand. The characteristic slightly raised margin retains its definite bright red outline wherever it advances, but usually presents a rather more acute inflammatory aspect than the enclosed area. The lesion may first occur on the palm of the hand, rarely on the dorsum, and begins to extend peripherally with the same characteristic border. In many cases only one thumb or finger is affected, and then the whole member, as before described, becomes swollen, hot, reddish, slightly shiny, painful, with a distinct, slightly red, raised margin encircling the base. On grasping the affected finger firmly in one's hand, it is felt to be much warmer than normal, and firm pressure often eases the pain. The intensity of the disease varied but slightly in all our cases. A particularly characteristic feature of this dermatitis is that suppuration never ensues, neither do any papules, vesicles or pustules form on the surface, unless, as very rarely happens, pus organisms infect the primary lesion. Desquamation does not follow, but the surface remains smooth.

In some few cases the disease had advanced very slightly up the forearm, but this was a rare occurrence. This form of erysipeloid is practically never accompanied by any constitutional symptoms. The temperature remains normal, the bowels regular, and the tongue clean. In a number of cases the patients have complained of pain extending up the arm, but it has not been severe.

In only five cases has there been glandular enlargement, the epitrochlear alone being enlarged or the axillary as well, and in three

other cases lymphangitis has been present. (In case No. 6 is described the condition in one patient.)

In one case, where the erysipeloid was due to inoculation while cleaning pigs' feet, the disease was typical, and it began three days after the finger was cut during the process of cleaning.

In another case, a meat cutter injured his left thumb, and an erysipeloid-like eruption appeared.

In one of the four cases where the inoculated material came from fish bones, and an erysipeloid rash appeared, the epitrochlear gland was enlarged.

The diseases in all these cases always presented a typical clinical picture.

5. *Pathology.* From two well marked cases I excised a portion of the growing margin on the fingers (palmar surface), and also included the normal skin. The sections showed the presence of an acute inflammation (see drawing) of the whole corium, and slightly of the subcutaneous tissue. The sweat ducts appeared to be particularly surrounded by inflammatory material. The epidermis was thickened, but this was probably due to the epithelial cells being larger in size (œdematous) and the intervening spaces being wider. It was also invaded by numerous polynuclear leucocytes. It could not be said that one portion of the corium was more affected than the other, with the exception of the area around the sweat ducts, as was mentioned before. Besides the presence of the numerous polynuclear leucocytes throughout the corium, there was also a much larger number of small lymphoid cells, which were particularly massed around the blood vessels. In all the sections one could observe the gradual change from the normal at one end of the specimen to the most pronounced inflammatory region at the other, but no distinct line of demarcation could be recognized as was done clinically.

No micro-organisms could be found in any of the sections.

6. *Cultural and Inoculation Experiments.* Many cultures were taken on various media, from twenty cases. The advancing edge of the lesion, and especially where it appeared to be most active, was washed with soap and water, then, in some cases, it was swabbed with bichloride of mercury solution and then alcohol, after which an oblique superficial incision was made, so that a platinum loop could be inserted beneath the epidermis. Cultures were then taken from the blood and serum which oozed out of the incision. Many smears were also examined, after being stained according to different methods. In the very large majority of cases the cultures were always sterile, and, where

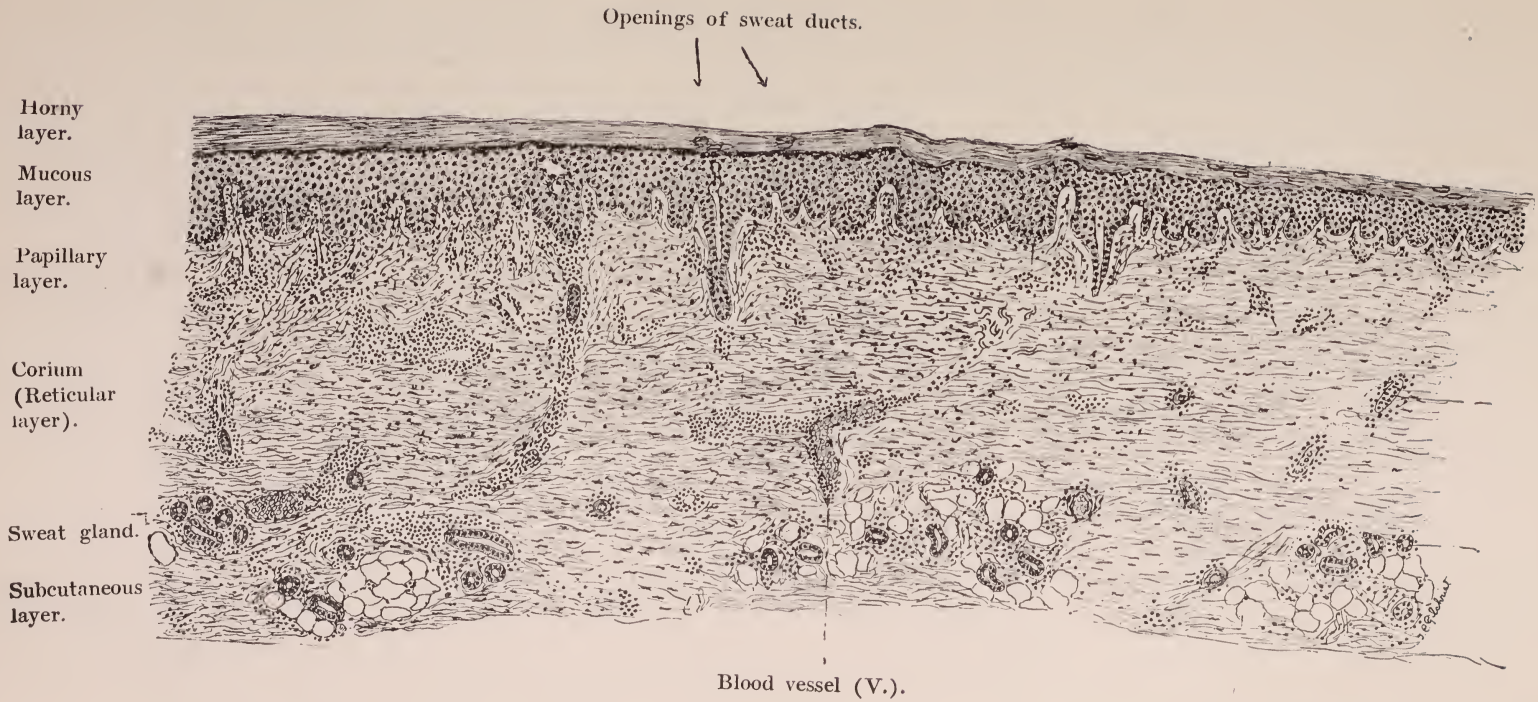

Section from advancing margin, case of crab cellulitis. (Side of finger.)

growths did occur, they appeared as one or two colonies of the staphylococcus epidermidis albus. None of the stained smears revealed the presence of any micro-organisms.

In order to ascertain the contagiousness of the disease, a number of experiments were carried out.

One man, who very willingly offered himself for experiment, was tested a number of times. He had never had erysipeloid. The skin of his second finger of the left hand was incised with a small knife, the hand being first washed, and was then inoculated with the blood and serum which exuded from an incised, actively-growing edge of an erysipeloid patch of a patient. This experiment was carried out on three separate occasions on this man, from different patients suffering with erysipeloid.

The inoculated lesions were allowed to dry, after the inoculated substance was rubbed in. Nothing ever resulted from any of the inoculations, although the lesion was noted daily for a month. It is possible that this man may not have been susceptible to this disease.

A patient who had erysipeloid on the right hand allowed me to inoculate a finger on the left hand, after the plan which I have just described, and since he was susceptible to the disease it occurred to me that the disease could be successfully inoculated in his left hand, but here again the results were negative. The artificial lesion healed up rapidly, with a superficial scab. Four other cases were tried in a similar manner, the inoculated material being inserted deep into the corium and then rubbed in, the only antiseptic precautions being a thorough washing with soap and water.

It was then thought possible that one could produce the disease by inoculating the skin of the hand with the juice of crabs. Three fresh crabs were taken and thoroughly crushed and pounded, the juice was pressed through a Paquelin filter, so as to exclude all the micro-organisms present in crabs.

A small quantity of this juice was inoculated by rubbing it into a small incision on the finger of the man mentioned above, but no results followed. One susceptible patient was also inoculated the same way, but again the results were also negative.

7. *Etiology.* The disease occurs at all ages, and in our cases ranged between seventeen months and seventy years of age. As one would naturally expect, it occurred most commonly in those who dealt in crabs or were engaged in cleaning them. As far as sex was concerned, the distribution was also equal. The condition of the general health did not appear to be a factor in the etiology, but, as in poison

oak or ivy, idiosyncrasy apparently played an important rôle. In comparatively few cases was there no history of a lesion produced by crabs. Of the 329 cases which we record, more than half were bitten by crabs, many others received scratches from the shells, and many gave a history of handling crabs, whereas the remaining cases do not record how the primary lesion was produced, other than that it was due to crabs, which were alive or had just been killed.

The special appearance and character of this affection are such as to render the diagnosis certain at the first glance.

Since no micro-organisms were found in the tissues of the cases which were examined, and since all culture and inoculation experiments yielded negative results, it seemed feasible to suppose that the cause of the disease might be a special ferment, which is inoculated into the skin by the crabs. The presence of the ferment would set up an acute inflammatory reaction, and, since the movement of lymph in the hands is extremely sluggish, it would be brought into contact with fresh tissue as it was carried along the superficial lymphatics and not affect the deeper parts, and the central portion of the eruption would attempt to return to its normal condition.

The disease naturally tends to spontaneous recovery, and this could be explained by the ferment being finally carried away and dissolved in the lymph stream.

On rare occasions the pain, which is usually localized, is felt extending up the arm even to the axilla, but the lymphatic glands are only very rarely enlarged. The pain may be due to the ferment extending up the lymphatics.

8. *Diagnosis.* This disease is to be diagnosed from eczema erythematosum and erysipelas.

Erythematous eczema is characterized by a diffuse and infiltrated patch, and, although there is at first no scaling, yet on account of the intense itching the surface becomes scratched, and then weeping will follow.

When eczema attacks the hands it often selects the interdigital spaces, and when the dorsum and particularly the palms are involved the character of the lesion is perfectly distinct from that of erysipeloid, the former consisting of patches which are scaly, indurated and often fissured. In eczema, the acute inflammatory, fairly rapidly-advancing margin is especially absent.

In eczema also there is intense itching, whereas erysipeloid is accompanied by pain, which is relieved by firm pressure.

Erysipelas is unusual on the hands alone or on the fingers, and it

is accompanied by constitutional disturbances, viz., fever, headache, coated tongue, vomiting, etc. Locally, erysipelas and erysipeloid from crab bites are very much alike, but since no micro-organisms were found either in the tissues or by cultures, erysipeloid is quite a distinct affection from erysipelas.

9. *Treatment.* In the surgical department under Dr. Finney, the cases were treated at first as follows: the finger or hand was soaked in bichloride solution, then a carbolic acid solution varying in strength from 1-20 to 1-30 was injected hypodermically at the growing margin of the disease, and finally the affected portion was dressed with ung. iodoformis. Later, this method of treatment was slightly curtailed in that the soaking in bichloride was done away with, so that only the injection with carbolic-acid solution was done and the iodoform ointment afterward applied.

In the dermatological clinic, I applied varying strength of Unna's salicylic acid plaster. At first fifty per cent. was applied in strips to the diseased portion, and also well beyond the growing edge of the patch. Ordinary adhesive plaster was applied over this. In many cases one application was sufficient to cure the affection.

When 38 per cent. and 25 per cent. plasters were applied, the same good results ensued, except that in two or three cases a second application was necessary, which was probably due to the fact that the plaster did not extend sufficient beyond the margin.

Out of 182 cases, 22 were treated by soaking in bichloride solution, injection of acid carbolic solution and iodoform ointment.

In 49 cases the acid carbolic injection and the ung. iodoformis were used. Salicylic acid plaster was used in 40 cases. It was thought, especially by my colleague, Dr. Lord, that the good results from the plaster might be partly due to the pressure produced mechanically by this application, so numerous cases were treated with plain adhesive plaster alone. The plaster was applied in strips, and well beyond the affected margin. The general results were good. In four cases only one application was necessary, but in nine cases the plaster was used twice, and three applications were necessary in three cases. In the history of the remaining cases the treatment was not mentioned. As the results of these various methods of treatment, it has been shown that the salicylic acid plaster of the strength of 25 per cent. is perhaps the best remedy, although plain adhesive plaster is frequently efficacious. After removal of the salicylic plaster, at the end of three days, the skin is found whitish and sodden, and a simple ointment is ordered. The disease is often cured in one application.

On comparing the variety of erysipeloid due to crab bites, etc., to that described by Morrant, Baker and Rosenbach, there are found some differences clinically. In Rosenbach's cases a livid zone advanced slowly on the finger or hands and the central area faded considerably, while in Baker's cases, as the area spread, its advancing margin broke up into discrete, irregular blotches, the central portion recovering its normal appearance. In my cases, the whole retained its redness slightly, but the margin was usually continuous and formed a bright-red zone.

Again, Rosenbach obtained one pure culture of a mould-like fungus, which he called a cladothrix, from an erysipeloid produced by foul cheese, and reproduced a somewhat similar eruption on his arm by inoculating this culture. He did not obtain again a culture from this lesion. Filsenthal says he obtained similar cultures from three cases. On the contrary, Delbanca and myself never obtained any positive cultures, nor did Wright or Livingood, at the Johns Hopkins Hospital, get any results. No organism could be found in smears, sections or cultures.

It is apparent, however, that all these cases belong to one typical clinical type, and they all practically present the same features.

The histories of a few cases, chosen at random, are related here in detail:

Case No 1. Girl, fourteen years old; was scratched by a live crab at tip of middle finger of left hand; two days later an inflammatory redness appeared around the abrasion, which had rapidly healed up. The redness gradually extended up the middle finger and then down the index finger to the distal phalanges; it also spread to the ring finger, and after extending down this finger a little distance it started on the little finger. The disease did not extend as far as the distal extremities of the ring and little fingers. The redness now gradually spread over the palmar surface, and now, two weeks after it commenced, involves the whole palm up to the wrist. The dorsum of the hand is free.

The Character of the Lesion. The whole patch is continuous, with a well-defined margin, slightly swollen, of a bright red color. The lesions itch at times, but there is not much pain. The lymphatic glands are unaffected, and there are no constitutional symptoms.

Case No 2. Woman, aged thirty-one years; was scratched in two places on thumb and index finger of left hand, while cleaning fresh crabs. The incubation period was twenty-four hours before the redness appeared. The patient was seen two days after the abrasions

were produced, and there were, on index finger and thumb, red, acutely inflamed, distinctly swollen, well-defined patches, which measured 2 x 2 cm. in size. No other symptoms were present.

She gave a history of having had a similar lesion the previous year, and produced by a similar cause.

Case No. 3. Girl, aged fourteen years; was scratched five days previously on the right thumb, while handling crabs. The whole right thumb down to the second phalanx was hot, swollen, pulsating, bright red, with well-defined marginal redness. The patient complained of aching during the day time. On pressure, the pain was relieved.

Case No. 4. A man was bitten by a crab eleven days ago on the index finger of the left hand, and two days after the dermatitis commenced. The lesions spread over the index finger, with a well-defined margin and the finger became swollen, hot, inflamed and painful. It was painted by the patient, two days after it appeared, with tincture of iodine, which treatment relieved the disease very much, but a week later it relapsed. It was then seen for the first time by the writer. The index finger was fairly hot, swollen and red, but was not very painful, and the skin lesion presented a rather acutely inflamed, reddish, well-defined margin.

Case No. 5. Boy, aged four years; was bitten by a crab two weeks ago. The dermatitis commenced about two days after the bite, and it extended over the whole back of the hand and along the backs of the fingers (Fig. 2). The second and third finger were swollen and painful. The lesion presented a well-defined, reddish margin, but the central portion was pale although still slightly swollen and tender. An application of 40 per cent. German acid salicylic plaster cured it.

Case No. 6. Man, thirty-four years old; while cleaning crabs, four days previous, pricked his left thumb a number of times with the juice of crab shells. The following day the skin around the points of injury became red and swollen, and next day the swelling was quite marked. When first seen by the writer the thumb was hard, swollen, quite red and hot, with a well-defined margin of redness.

From the metacarpal extremity of the thumb was a thin line of lymphangitis, which extended up the forearm almost up to the axilla. The epitrochlear and axillary glands were enlarged. No constitutional symptoms were present. The lesions were painted with tr. iodine, and next day the lymphangitis had disappeared. Two days later there was still some considerable redness about the metacarpephalangeal joint. It was painted with iodine tincture, and adhesive plaster was applied. Six days later the lesion was still spreading, but another application similar to the last one cured the disease.

Case No. 7. Man, aged seventeen years; was bitten by a crab on the proximal end of ring finger of right hand; the incubation was only three hours, and he applied for treatment thirty-six hours after injury.

No definite lesion can be found, but proximal ends of right ring and middle finger, and extending for one inch down palmar and dorsal surfaces, are reddened areas, which have well-defined edges and are swollen and painful. No glandular enlargement. No constitutional symptoms. Adhesive plaster was applied. Patient returned six days later, with area of lesions increased; disease had extended up fingers to back of hand and on to little finger. Tr. iodine was painted on, then adhesive plaster was applied. Three days later a small area was found on middle portion of the back of the hand, just above the plaster. The rest of the lesion has disappeared. Same treatment was applied.

REFERENCES.

1. Fox, Tilbury: Erythema of Hands. *Brit. Med. Jour.,* 1870; vol. II., p. 132.
2. Baker, Morrant: Erythema serpens. *St. Bartholomew's Hospital Report;* vol, IX., 1873, p. 198.
3. Rosenbach: (1) Text book, 1884; (2) *Verhandl. der Deutsch. Gesell. fur Chir.;* vol. XVI., 1887, p. 75.
4. Elliot, G. T.: *Jour. Cut. and Genito-Urin. Dis.,* 1888, p. 12.
5. Felsenthal, S.: *Arch. f. Kinderhlkde,* Bd. XVI. Abstract *Monatshft f. prakt. Derm.,* Bd. XIX., 1894.
6. Fordyce, J. A.: *Jour. of Cut. and Genito-Urin. Dis.;* vol. XIV., 1896, p. 28.
7. Gilchrist, T. C.: Special Dermatitis due to Crab Bites. *New York Medical Record,* vol. 49, 1896, p. 783.
8. Delbanco, Ernest: *Dtsch. Medizinalztg.,* 1898, Sept. 29th. Abstract *Monatshft. f. prakt. Derm.,* Bd. 28, 1899, p. 652.
9. Anderson, W.: *Brit. Jour. of Derm.;* vol. II., 1899, p. 121.
10. Lenhartz, von Herman: Erysipelas and Erysipeloid, Wien, 1899.

DISCUSSION.

Dr. Bowen said these cases were occasionally met with in Boston, usually in persons who handled fish. Some years ago, the speaker said, he excised sections of the lesions in two cases and the histological findings were exactly the same as those reported by Dr. Gilchrist. No micro-organisms were found. No attempt was made to obtain cultures.

Dr. Martin F. Engman referred to Musser's cases of streptothrical infection of the skin, lungs and liver in which it was very difficult to find the organism. Hundreds of sections were made without finding it. Dr. Engman said that in taking cultures from certain lesions of the skin, it was often difficult to get a viable culture. In order to get a successful culture of typhoid fever bacilli from the rose spots, for instance, the method had been followed of first driving the blood out of the spots by freezing, as the blood drawn in pricking or cutting the lesion acts as a local antiseptic and thus the inoculated tubes are sterile. This

might be the case in the negative results of Dr. Gilchrist. The blood should be eliminated in making cultures and many sections should be examined, according to Musser, in the search for the streptothrix.

Dr. Shepherd said he had seen several cases of this affection among medical students as the result of scratches received at post-mortems or in the dissecting room. He had also seen it in butchers who had wounded their fingers with the rough edge of bone. The application of tincture of iodine was usually very efficacious.

Dr. Zeisler said he did not see the necessity of calling this affection erysipeloid, as it fitted entirely into the group of eruptions known as toxic erythemata. A great many similar eruptions were known to occur after infection with various animal poisons.

Dr. Klotz said he had seen several cases of this affection in which the infection was undoubtedly traced to preparing poultry, particularly removing the entrails. The eruption was sometimes very painful, preventing sleep. Usually, the local application of a 1-1,000 bichloride solution was efficient, but in one instance, where the infection was particularly severe, Dr. Klotz said he was obliged to resort to the intracutaneous injection of the bichloride solution.

Dr. Gilchrist, in closing, said the name erysipeloid was first used to describe the condition by Dr. Rosenbach, because the eruption looked like erysipelas. Previous to that time it had been known under various names. It was doubtful whether it should be classed under the term toxic erythema, because it had not been proven that it was due to any micro-organism, although the value of bichloride applications in the treatment of the affection might possibly lead one to suppose that the disease was microbic in origin.

GRANULOMA PYOGENICUM (BOTRYOMYCOSIS OF FRENCH AUTHORS).

By M. B. Hartzell, M.D.

Associate in Dermatology, University of Pennsylvania; Dermatologist to the Philadelphia Hospital.

Read before the twenty-eighth annual meeting of the American Dermatological Association, Niagara Falls, June 2 and 3, 1904.

In 1897, in a communication made to the French Congress of Surgery, Poncet and Dor reported four cases of a new growth which they believed represented a form of neoplasm not previously described as occurring in man. In two of these cases there was a small tumor upon the fingers, in the third the growth was situated upon the thenar eminence, and in the fourth upon the shoulder. These tumors

were pea to nut-sized, fungoid masses attached to the underlying parts by a slender pedicle, and, upon sections, were found to be composed of inflammatory tissue having a very vascular fibrous stroma throughout which were scattered yellowish, granular masses. Microscopic and bacteriological examination also revealed the presence of a micro-organism which, when cultivated and inoculated into the ass, produced a growth similar to that from which it had originally been obtained. The authors concluded from their researches that this organism was identical with one found by Bollinger, in 1870, in certain inflammatory tumors occurring upon the scrotum and spermatic cord of the horse, the so-called fungus of castration (*champignon de castration*), and to which he had given the name botryomyces because of the mulberry-like masses produced by it in the tissues. They accordingly regarded these tumors as human botryomycosis, similar in all essential features to the equine disease. In addition to the four cases which formed the subject of the communication to the Surgical Congress, Poncet, in conjunction with Bernard, has recorded three others under his observation more recently. Cases have also been reported by Chambon, Sabrazés and Laubie, Reverdin and Julliard, Brault, Carriere and Potel, and Bodin in France, and by Faber and Siethoff in Holland. All these observers agree as to the clinical, and most of them as to the histological, features of the neoplasm, but they are by no means of one mind as to its etiology and pathology. Bollinger, Nocard and Leclainche, and until very recently Poncet and Dor regarded it as a malady due to a specific organism, the botryomyces. Nocard and Leclainche who, shortly after its discovery by Bollinger, made a study of this organism, found that, in cultures, it was practically indistinguishable from the staphylococcus, but in the tissues it occurred as yellowish grains, forming mulberry-like masses. I am not aware, however, that these findings have been confirmed by subsequent investigations. Bodin, in the two cases reported by him, failed to discover the mulberry-like masses of cocci described by Poncet and Dor and some others, but found only cocci in the peripheral parts of the tumor having the morphology and staining characteristics of the staphylococcus; and the features presented by the micro-organism in cultures convinced this author of its identity with the yellow staphylococcus of suppuration. Carriere and Potel, who also reported two cases, both of which occurred upon the fingers, found that the neoplasm was a fibrous tissue made up of connective-tissue cells having a quasilamellar arrangement. In the midst of this tissue were numerous cavities, some of which were empty, others filled with a slightly granular substance. At the level

The fourth and last case occurred in the person of a married woman, thirty-five years old; the lesion being situated upon the tip of the little finger of the right hand and presenting features precisely like those described above. The growth, which had lasted four months, was extremely sensitive, and occasioned the patient much annoyance. It had been removed repeatedly by the family physician only to return; and the proposal to excise it together with a considerable portion of the sound tissue drove the patient to seek advice elsewhere. In this case, as in the previous one, the curette was used, after spraying with ethyl chloride, and a forty per cent. pyrogallol plaster applied. The tumor was extremely vascular, the little wound made in its removal bleeding very freely for a half hour or more, ceasing only after firm constriction of the end of the finger for some time. There was no further attempt at reproduction after this treatment.

Sections made of this tumor showed that it was made up of collections of cells chiefly of the connective-tissue type, and numerous blood-vessels contained in an abundant fibrous stroma. A portion of its surface was covered by a thin layer of polygonal epithelium in which the usual basal layer of cylindrical cells was, for the most past, absent, but the greater part was without epithelial covering, and was here and there slightly necrotic. Besides connective-tissue cells there were small collections of lymphocytes about some of the vessels, a very few "mast-zellen," and a moderate number of polynuclear leucocytes in the periphery of the tumor. One of the most marked features was the great number of blood-vessels, most of which were filled with blood, in the central parts of the sections; these were so numerous and large as to present somewhat the appearance of an angioma. No trace of either sweat or sebaceous glands was observed in any of the many sections examined. Sections stained with Gram-Weigert and other stains showed a moderate number of staphylococci in the superficial parts of the growth, but none of the yellow, granular masses described by Poncet and Dor, the so-called botryomycetes.

In conclusion, we regard the non-specific character of this growth as fairly well established. It is a granulation-tissue tumor, and the micro-organisms found in it are nothing more than the yellow staphylococci of suppuration. The conclusion of Carriere and Potel that it is a fibroadenoma of sweat-gland origin finds no support from my study, nor from the observations of other authors.

DISCUSSION.

Dr. Gilchrist said that he now recalled two cases which probably belonged to this group, but which at the time he did not know where to place them. Some years ago a young man applied to him for treatment. He had a growth on the lower lip, which he at first thought was a commencing carcinoma. It was very soft and vascular, and as large as a good-sized pea. There was no glandular enlargement. He excised it pretty thoroughly, and under the microscope it presented the features of granulation tissue, very full of blood vessels, polynuclear leucocytes and lymphoid cells. It appeared to be a typical example of excessive granulation tissue. The result of the excision was excellent and there was no recurrence.

In the second case, the lesion was at the base of the little finger and it presented the same clinical features which Dr. Hartzell had just described. It was a mulberry-like growth, resembling granulation tissue, and this was verified by the microscopic findings. There was a possibility of its being malignant, but a recurrence did not take place.

Dr. Henry W. Stelwagon would like to ask Dr. Hartzell if the lesions bore any resemblance to the raspberry-like growths sometimes developing on the site of vaccination?

Dr. Augustus Ravogli said that he had occasion to see one of the granulation tumors just underneath the finger-nail of the right thumb. The finger had been bruised in lowering a window of a railroad car. Suppuration had set in and continued for a long time in the form of paronychia. Upon examination it was found that there was an exuberant amount of spongy tissue just under the nail. This formed a round, flat, tumor, and upon removing it with the forceps the wound healed without further delay. Under the microscope, this tumor showed the same characteristics as those described by Dr. Hartzell. Eruptions of granulation tissue were not uncommon in cases of long-continued suppuration, especially in the Negro race and among people who were negligent and lacking in cleanliness. He had attributed them to constant irritation, and to the presence of staphylococci in the normal skin, which produced these peculiar vegetative processes. In the treatment of these cases, he usually employed the sharp curette, followed by an application of resorcin, or better still, a preparation known under the name of formo-resorcin, which had given him excellent results.

The President, Dr. Zeisler, asked Dr. Hartzell whether from his study of the subject the location behind the nails was particularly favorable for the development of these granulomata? He recalled two cases behind the nail in which the lesions were not unlike panaris.

Dr. Hartzell, in closing the discussion, said in reply to Dr. Stelwagon that he believed that the so-called raspberry-like growths sometimes seen after vaccination belonged to this class of tumors. He had

not noticed that the region behind the nail was a particularly favorable location for their development.

He did not report these cases because he considered them at all rare. On the contrary, they were comparatively common, but nobody had paid any particular attention to them. Each and every one of us had doubtless seen a number of such cases, and had simply dismissed them by calling them masses of granulation tissue. It was certainly curious that it occurs as it does. In not a single one of his cases was there a history of previous injury. Careful inquiry was made on that point. He was still convinced, however, that there must have been a slight traumatism. The subject interested him particularly because the French regarded it as analogous to botryomycosis, which occurred after castration in the horse. It was no doubt due to a proliferation of granulation tissue, resulting from pus organisms. Still, it occurred very infrequently as compared with the number of wounds of the skin. While we had not succeeded in demonstrating any special micro-organism in this type of granuloma, there might be some particular cause for it.

EDITORIAL.

THE FIFTH AND SIXTH CONGRESSES OF DERMATOLOGY

THE Fifth International Dermatological Congress, which concluded its sessions in the city of Berlin on the 17th of September last, accomplished a large success. It is early to estimate with approximate exactness the value of its scientific work, but enough has been spread before the profession at large to justify the statement that the labor represented in its contributions to science was well expended and the fruits of its research of permanent value. As usual, on account of the pressure for lack of time, many of the papers were either unread or read merely by title. Yet others were presented in very brief abstract. Of those read or already published in part (chiefly the contributions made by special reporters to the Congress), many were examples of a sterling common sense illuminating the labors of the laboratory expert and the clinician.

The exhibits of photographs, models of diseases of the skin, and microscopical specimens were numerous; many of them of really remarkable value. The photographs and casts illustrating cutaneous lesions artificially produced in the lower animals (apes, swine, etc.,) were both instructive and novel. The exhibition of clinical patients affected with the rarer and interesting types of common disease was on a large scale. With every meeting of the Congress, the exchange of views of individual members in the presence of patients displaying variations of type in diseases of the skin gains in importance.

The entertainment of members by their colleagues in Germany was exceedingly generous, and gave convincing proof of the most charming hospitality. The dermatologists of Berlin vied with each other in the sumptuousness and elegance of their reunions and banquets; and not the least interesting of the receptions was that given on the closing day of the Congress by the authorities of the city of Berlin. In all arrangements for the comfort of the gentlemen in attendance the love of the German nation for system and detail bore evident fruit.

It would certainly prove an invidious task to attempt to contrast this with any one of the Congresses preceding. Each has been characterized by some special features of value. The great courtesy and kindness exhibited by President Lesser in all his relations with individual members, and the indefatigable efforts of Sanitätsrat Rosenthal, went far to insure the final result.

Not the least interesting and important act of the Congress, one which very nearly concerns the readers of this journal, was the vote taken on September 18th, naming the city of New York as the place of meeting of the Sixth International Congress of Dermatology under the presidency of Professor James C. White, of Boston, on the invitation of the American Dermatological Association. It is gratifying to note that the vote was taken without nomination of another man or place, and without dissent. The result was greeted with applause. Dr. White is admirably qualified by long experience and gathered honors to preside over the Congress which in the year 1907 will unite students in this department of science from all parts of the world. It is to be remembered that while the American Dermatological Association has taken the initiative in this matter, the invitation to America was extended by other bodies as well, including the Dermatological Section of the American Medical Association. It is assured that the *personnel* of the forthcoming Congress in America will not be limited to the members of any group or society of medical men. Every reputable physician devoting time and attention to dermatological study will have the privilege of becoming a member of the Congress on payment merely of the annual dues. The organization of the new Congress will assuredly be effected on the broadest and most liberal lines and with a view to the largest success of the meeting.

The two meetings held in Paris were designated each as "Le Congrès International de Dermatologie et de Syphiligraphie"; that in London was entitled simply "The International Congress of Dermatology." The fifth was styled "Internationalen Dermatologen-Congress." It will be well if our American colleagues shall designate the sixth as "The International Congress of Dermatology," opening its

doors, as in London and Berlin, to the presentation of all papers which may be offered on the subject of either cutaneous or syphilitic diseases.

Meantime, there is need of much unselfish labor, great harmony among those co-operating with a view to the largest success of the scheme, a deal of self-sacrifice, and the most generous spirit. The task before American dermatologists is sufficiently serious in its demands and well-nigh unmeasured needs. A grave responsibility rests upon all those who have conceived and must carry to completion the scheme of the enterprise. Nor let any dismiss the matter as one not requiring immediate attention. The three intervening years will slip rapidly away. Already there are those on the other side of the Atlantic who are inquiring what shall be the themes for general discussion in 1907 in New York, as it is purposed to devote the intermediate time to a study of such subjects. In order to make the next International Dermatological Congress a success, it will be necessary to conform to one of the precepts of Emerson and "toil terribly."

J. N. H.

"FEUILLETON."

Glimpses of the Fifth International Congress of Dermatology

DURING one of those delightful evening chats, which at great medical gatherings have always seemed to me a most attractive relief after the strenuous work of the day, a noted Italian colleague said to me, "There are two things that I am looking for at these congresses, clinical cases and friends." How natural! As we get older and more skeptical about the real value of listening to the reading of papers we learn to appreciate more and more the unofficial features.

But not only in this respect, in every other way was the Berlin Congress a complete success. In attendance, scientific character, general arrangements, clinical material, the exhibits, the sumptuousness and variety of entertainments, it easily equalled if it did not surpass its predecessors at Paris, Vienna and London. It was truly international in its makeup, albeit the German representatives, as a matter of course, formed an overwhelming majority. This is easily understood when we learn that Berlin alone has almost 150 men devoted to skin and venereal diseases; besides, all the German universities and the larger cities of the empire had sent their best men. To enumerate all of them would mean to reproduce the registration

list. From France we had the pleasure of meeting Darier, Jacquet, Gaucher, Barthélemy, Brocq, Hallopeau, Leredde, Dubreuilh, and the head of the Pasteur Institute, Metchnikoff. England was sparsely represented. We saw Crocker, Malcolm Morris, Brooke, Eddowes and Pernet. From Italy we met Pellizzari, Campana, Truffi. From Russia, Petersen, Pawloff and Alapin. Austria was well represented by Neumann, Finger, Riehl, Ehrmann, Spiegler, Kreibich, Ullman, Schiff, Pick, Janovsky, Freund, Lukasiewicz, Glück. Hungary sent Róna, Havás, Marschalko. We also saw Petrini de Galatz from Roumania; Duhot, Dubois-Havenith from Belgium; Ehlers and Forchhammer from Denmark, and Asahi from Japan. From America had come Allen, Bulkley, Fordyce, Stelwagon, Schamberg, Heidingsfeld, Wende, Gilchrist, Hyde and Zeisler. It is said that in numbers the Congress outdid all previous ones, the registration being about 500.

With the exception of the first meeting, which was held in the Langenbeck Home, in the presence of numerous dignitaries from the German empire, the Pathological Institute of the Charity opened its doors to us, offering its amphitheatre for the general meetings, while adjoining halls contained collections of photographs, *moulages* and microscopical specimens. Here, also, from 11 to 12 every morning men could be seen crowding around long tables laden with delicacies of all sorts to be washed down by streams of Gambrinus' choicest brown fluid.

It was clear from the beginning that the programme, which contained the announcement of 147 papers and other communications, could not possibly be carried out, although the sessions were considerably extended; and probably less than one-third were actually presented. Nobody regretted this, for it cannot be denied that the international makeup of an audience makes it often difficult for many to follow a speaker in a foreign language. One may have a fair reading ability in more tongues than his own, but it is quite different when it is necessary to strain one's ears to unfamiliar sounds.

The subjects for the general discussions had been selected with rare tact and gave opportunity to men outside of our own specialty to assist in our deliberations. This was true of the Reports on Leprosy, most of which were ready in a bound volume; of the discussion on Skin Diseases in Their Relation to Faulty Metabolism, when von Noorden gave a most comprehensive résumé of this vast subject. Jadassohn (Bern), Bulkley, Crocker, Hyde, Eddowes and Brocq also participated. But were we to draw the sum total of all that was said we must confess that little new was offered and the evidence was

rather of a negative character. The main contributors to the next theme, Syphilitic Affections of the Circulatory Apparatus, were again from outside our guild, von Hansemann and Renvers, both of Berlin.

The discussion on Epithelioma and Its Treatment was the occasion for the presentation by His Excellency von Bergmann, of about thirty patients whom he had operated upon for cancers of the lip or adjoining parts, and who had remained free from relapses for periods of from five to ten years. This was supposed to offer a strong argument against modern radiotherapeutic measures, which were declared as unsafe. These, however, found strong advocates among the dermatologists present whose testimony as to the value of the method in superficial epithelioma of the skin was quite pronounced.

The announcement of Neisser, in the first meeting, of his successful inoculations of syphilis upon chimpanzees, and his warm tribute to Metchnikoff, who had first succeeded in these experiments, was the occasion of quite an ovation to the noted Parisian biologist, who himself gave very valuable data concerning the susceptibility of that species of monkeys. Lassar also showed some interesting *moulages* of monkeys inoculated by him.

Modern phototherapeutic measures came in, as a matter of course, for a good share of general interest. Forchhammer, of the Finsen Institute, had brought a series of about thirty lupus patients, several of whom had been previously shown at the Paris Congress, and were the strongest possible argument as to the superiority of Finsen's method over all others, at least in lupus. Outside of that, however, it was clearly shown that the X-rays, in the opinion of the majority, have a much wider range of usefulness.

Our American colleagues made a very creditable showing with their lantern slide exhibits. Schamberg illustrated a paper on Variola by excellent pictures, and Fordyce exhibited his, to us well known, splendid photomicrographs of the Histological Features of Epithelioma. Unfortunately the projection apparatus was so close to the screen that the demonstrations did not do the subject full justice.

The clinical demonstrations took place every morning from 8:30 to 9:30 and were naturally, as at previous congresses, the chief attraction. It seemed to me as if there was less variety than in London, but there was no lack of interesting material. Many Berlin cases were exhibited to show the effect of the Finsen light, the X-rays and radium, but they could not stand comparison with the Copenhagen display. Holländer of Berlin, who is known by his "Hot Air Treatment of Lupus," presented some interesting cases of lupus erythematosus where the iodine-quinine treatment had proved very successful.

Unusual instances of all forms of nævus, atrophy of the skin, rare forms of the lichen group, angiokeratoma, Raynaud's disease, cystadenoma, unusual forms of ulerythema, and many other interesting dermatoses were seen in large numbers. It is much to be regretted that such valuable material should not have been exploited more fully. It would seem that much profit could be derived by selecting each day a few of the more interesting cases, particularly those which give rise to differences of opinion, and make them the subject of more general and orderly discussion. No cases of blastomycosis were shown.

The social features of the Congress will long remain a pleasant recollection. We had thought that London had marked the climax in that respect, but Berlin made an almost Byzantine display. Sunday, the 11th of September, in the evening there was an informal gathering at the Kaiserhof, with ladies. Monday evening the President, Prof. Lesser, had invited about 150 to a gorgeous dinner at the same famous hostelry. The Genial Secretary General, Rosenthal, had arranged two large dinner affairs at his home, one on Sunday afternoon, the other on Tuesday evening. Wednesday evening was the general banquet, again at the Kaiserhof, and the representatives of almost all nationalities had occasion to make themselves heard. On Thursday evening Prof. Lassar gave a soirée at his home, at which almost 300 members were present. A children's chorus and the American prima donna, Edith Walker, were heard, and an exquisite supper was served. Friday evening the Congress was entertained by the City of Berlin in its famous Rathaus, and all the aldermen in their official costumes, representative of the government, among them Minister of Finance, Baron von Rheinbaben, had come to do honor to the occasion. Unlike receptions occurring in this country, we were all seated around long tables and a complete supper with a variety of wines was served; there was music and speeches were delivered in all languages. Saturday afternoon many of the members and their ladies made a delightful excursion by steamer on the Spree, which gave us a chance to observe a good deal of the industrial activity in the outskirts of the capital, and in the evening we were given an informal supper in the so-called Abtei, where the President, in a cordial address, bid adieu to all of us, to which Zeisler, Stelwagon, Allen and others responded.

It would be ungrateful to forget the many delightful luncheons, several of which had been arranged on each day, at some of which we had occasion to inspect the private clinics in Berlin.

It is a matter of no small pride to us Americans that we succeeded in securing the next International Congress for our country, to be

held under the presidency of our honored Nestor, J. C. White of Boston, in New York in September, 1907. Dr. Hyde of Chicago presented the invitation in the name of the American Dermatological Association and was followed by Fordyce in the name of New York City, and Stelwagon for the American Medical Association. After this Zeisler of Chicago addressed the Congress in German and dissipated in an impassioned speech the fears and objections which had been heard as to the possible success of a meeting in the United States. Our invitation was accepted amidst tumultuous applause. Judging from the expressions which I could hear upon all sides I have no doubt that a large number of foreigners will come to our shores three years hence. We have a great task on our hands if we are to come up to the precedents established; we can succeed only if we work in harmony. Let everybody who is interested in American Dermatology stand shoulder to shoulder and work united for a glorious Sixth International Congress. J. Z.

OBITUARY.

NIELS RYBERG FINSEN.

In the death of Prof. Niels Ryberg Finsen, September 24th, in the forty-fourth year of his age, the world has lost an earnest, diligent investigator possessed of unusual inventive genius, and an honest, modest man, who was genuinely and unselfishly interested in the welfare of his fellowmen.

The history of his work is a familiar story, so often has it been told in professional and in popular writings. The very nature of the light treatment made it inevitable that the public as well as the medical profession should become interested in it at once. He consequently received earlier than do many worthy investigators the reward of a great reputation and the homage of scientists, of royalty, and of the people. But the prompt recognition of his genius has been too frequently marred by the extravagant claims of his overzealous and less scientific followers; while the name of Finsen and the echo of his discoveries have furnished many a charlatan with the ready means of preying upon an over-credulous public, and incidentally of bringing the method into disrepute. The great value of phototherapy in the treatment of cutaneous tuberculosis, and of a few other diseases of the skin, is established beyond question and assures for its originator a permanent place in the history of medicine. It is impossible at this time to foretell the future developments of phototherapy or to estimate fully the value of Finsen's labors, since he,

more than any other one man, instigated the present active researches in this field of therapeutics. It is a pleasure to note that no exaggerated claim for the light treatment ever emanated from Finsen or from his associates in the Lysinstitut, notwithstanding the fact that his enthusiasm in his work seemed to be contagious, as it was shared apparently by every assistant and nurse in the institution and almost invariably by the patients and visitors.

Those of us who were so fortunate as to know Finsen at work in his laboratory remember him as an able, honest, enthusiastic but always modest investigator, who cared more for truth and for helping his fellowmen than for material wealth or, indeed, for a great reputation. Though seriously ill during a large portion of his professional career and knowing that he had but few years to live, his courage never failed and he devoted all the energy he could command to the pursuit of his chosen work. He was

"One who never turned his back but marched breast
forward,
Never doubted clouds would break,
Never dreamed though right were worsted, wrong
would triumph,
Held we fall to rise, are baffled to fight better,
Sleep to wake." F. H. M.

DR. FRANCIS B. GREENOUGH.

Dr. Greenough of Boston died October 16th. He graduated from Harvard College in 1859, and from the medical department in 1866. After study in European schools he returned to practice in diseases of the skin and genito-urinary surgery. He was appointed lecturer on Venereal Diseases in Harvard University in 1871, and from 1875 to 1895 was clinical instructor in the same. At the latter date he retired from practice and teaching on account of failure in health. He became a member of the American Dermatological Association in 1878, and was its president in 1890-91. He was also a member of the American Association of Gen.-Urin. Surgeons and of the Boston Dermatological Club. He filled all these positions well.

Dr. Greenough's contributions to dermatological literature were few, but these articles and the opinions he expressed in discussions before societies were characterized by sound judgment and independent observation. Every word that he spoke or wrote was reliable and straightforward, and he was blessed with an exceptional degree of common sense. We have lost a most lovable, genial and honorable colleague.

REVIEW
of
DERMATOLOGY AND SYPHILIS

Under the Charge of JOHN T. BOWEN, M.D.

MALIGNANT NEW GROWTHS.

By E. C. JAGLE, M.D., New York.

Acanthosis Nigricans, Two New Cases of. Dr. OTTO HESS (*Münch. Med. Wochensch.* Bd. 50, H. 38).

The three chief symptoms are typical localization, hypertrophy of cutaneous papillæ and increase of pigment. It appears symmetrically on neck, breast, navel, lumbar region, anus, genito-crural fold, axillæ, elbows, hand and foot, as a dark pigmentation and distinct furrowing so that the skin appears folded. In a few cases there is hyperidrosis. At these sites develop simple and branched, isolated, and grouped papillomata, which become brown to black, while the furrows remain light. Mucous membranes are covered with soft, thickly grouped, pale or red, often painful papillary growths. Course is progressive, death being due to severe lesions of viscera, often through malignant neoplasms. A satisfactory explanation has not yet been offered between this disease and malignant new growths.

Of the two cases reported by Dr. Hess, the first was a male, sixty years of age, presenting a typical picture of acanthosis nigricans, without mucous membrane involvement. Nine months previously, the disease began with gastro-intestinal symptoms which grew progressively worse, patient becoming icteric and very cachetic until at the end of a year a tumor in epigastrium became palpable and lymph nodes in left supraclavicular fossa were the size of cherries. Death took place a month after.

The second case, a male of forty-one years, was typical clinically and interesting on account of the combination with elephantiasis, which began first on the left side and then involved whole body. Œdema and weakness increased and patient died six months after initial symptoms.

Cancer of Basal Cells. Dr. E. KROMPECHER (*Der Basalzellenkrebs*).

Seventy-five cases are described and the author distinguishes clinically and histologically the benign from the malignant basal cell growths as follows:

The benign baso-cellular epithelioma occurring:

(a) On the skin, usually in young individuals; grows slowly, is encapsulated and forms numerous small, scarcely elevated nodules on the face and trunk, or, single pea to nut-sized nodes on face near orifices. They do not metastasize. With these he considers soft nævi; aggregations of nævus cells having become displaced in the cutis.

(b) On pavement epithelium of mucous membranes, including papilloma of bladder, ureter and pelvis of kidneys.

(c) In glands which open on the surface of pavement epithelium, for example, prostate.

The malignant occur:

(a) On the skin, as single or multiple, often fungiform, prominent tumors, sometimes encapsulated; mostly in older individuals. They seldom metastasize, but when they do, it is by way of the blood stream, and often recur. To these belong ulcus rodens and epithelioma adenoides cysticum.

(b) On mucous membranes lined with pavement epithelium, as mouth, throat, œsophagus, nose larynx, vagina, *portio uteri.*

(c) In glands excreting on surface of pavement epithelium, viz., sebaceous, sweat, meibomian, salivary, mucous glands and probably those of the gums, the mammary gland, prostate and testicle.

Basal cell cancers do not occur in mucous membranes lined with cylindrical epithelium or glands connected therewith, but it is noteworthy that tumors corresponding to them are found in the ovary and they probably take their origin from the germinal epithelium.

The neuro-epithelioma of Wintersteiner resembles the adenoid type of basal cell cancers. The mixed tumors which have been designated as plexiform sarcoma, adeno-sarcoma, cylindroma, adeno-chondroma of the skin and salivary glands, and the endotheliomata of those organs in which basal cell tumors occur, as well as angio-sarcoma, perithelioma, melano-sarcoma, etc., have proved to be basal cell tumors.

Histologically, the cells are characterized by the retention of their embryonal characters. Their size and shape as well as the amount of chromatin, vary; so that diagnosis must be based on type and nature of growth.

The various types are solid, glandular, cystic tubular, reticular, parakeratotic, hyalin and myxomatous, either pure or in combination. The growth may be initiated by a marked œdema of the young connective tissue and hydropic degeneration of the lower epidermic layers. The snaring off of the epithelium as described by Ribbert, the writer thinks, is due to a preceding inflammation, which in a mechanical way leads to their isolation.

In the prickle, cylindrical and gland cell tumors the differentiation of the cells goes on as under normal conditions, only the manner of differentiation undergoes a change, in that the cells become anaplastic and cancer cells are formed. In the basal cell tumors, however, this differentiation does not take place; the cells retain their embryonal character and become simply anaplastic, which anaplasia is recognizable in the polymorphism and mitotic changes of the cells. The transitional forms, Dr. Krompecher has named carcinoma cubo-cellulare.

The connective tissue of these tumors may show the same degenerations as their growths.

The Etiology of Carcinoma. Researches on the Morphology of an Organism Associated with Carcinoma Mammæ and on the Etiological Significance of This Association. By R. N. Monsarrat. (*Report LXXIX., Scientific Grants Committee, B.M.A.*).

Monsarrat reports that he has isolated an organism from seven out of twelve specimens of non-ulcerated carcinoma of the breast. Of the remaining number, one was contaminated with staphylococcus epidermidis albus, the other four yielded no cultures. Positive results were obtained with the ordinary nutrient broth, in one case with glucose broth (4 per cent.) and with glucose agar (1 per cent.) in the other six. The organism was cultivated by immersing small pieces of the tissue in the fluid media, or rubbing them over, or leaving them on the surface of the solid media, under aërobic conditions and incubated at 37° C.

He gives a summary of his researches as follows:

1. From a considerable proportion (58.3 per cent.) of specimens of carcinoma mammæ an organism presenting characteristic features was isolated.

2. The organism presents a life history in which two cycles were traced—the one a vegetative budding cycle, the other a sporulating cycle.

3. The organism when injected into animals is capable of infecting and inhabiting endothelial and epithelial cells.

4. The organism initiates in endothelium and epithelium a process of proliferation, as a result of which masses of new formed tissue are built up, which consist of a parenchyma and a stroma and grow and extend actively from their centers of origin.

5. This new cell mass formation may be associated with growth of a similar character, in neighboring glands, and some evidence was also presented that visceral metastasis occurs.

6. Intracellular bodies are demonstrable in carcinomata mammæ which present the same features as the intracellular parasites of the experimentally produced nodules.

7. The evidence derived from these researches points to the conclusion that the organism described is an etiological factor in the morbid process known as carcinoma mammæ.

Cancer, Note upon the Causation of. H. J. Campbell, M.D., F. R. C. P. (*Brit. Med. Jour.*, April 30, 1904.)

Dr. Campbell's view is that cancerous growth is caused by the degenerative reversion of epithelial cells to a germinal type, in association with a local irritant and in the presence of an abundant blood supply. Multiplication having once commenced, the local conditions serve to continue and fix the type, the growth becoming practically a colony of unicellular parasites. In cells, with regard to specialization, evolution may be downward as well as upward, and, to a certain extent, the individual

cell in its decay tends to approximate to an earlier type similar to that from which it has been evolved. However, the more specialized the cell, the greater will be the difficulty in its reverting to an ancestral type.

The epithelial cells may be looked upon as those which have been left over after the more specialized ones have been budded off, and it is these which will most nearly resemble the ancestral cells. As to the objection that the reversion ought to be to an embryonic type, in the higher animals at least, the power of so complete a reversion has been lost.

As to time that the disease appears, the decadent period of life should have set in. A tendency to precocious degeneration of the epithelium may be a parental legacy, like atheroma, gray hair, etc. With reference to site the favorite ones are the breast and cervix uteri, where degenerative processes appear most early. Further, with the increased rapidity of living under modern conditions, all the degenerative diseases are tending to increase in frequency and to appear at earlier ages.

With regard to corner houses, streets and villages, the writer is of the opinion that any external conditions which favor the early onset of degenerative changes in epithelial structures will favor the development of cancer.

Essential Similarity of Innocent and Malignant Tumors. Delivered before the Royal College of Surgeons of Edinburgh on March 4th and 11th, 1904. Charles W. Cathcart, F. R. C. S., Eng. and Edin. (*Brit. Med. Jour.*, June 4, 1904.)

Evidence from many different and independent observers was brought forward and it was therefore considered right to conclude:

1. That innocent and malignant tumors are essentially similar to one another.

2. That both forms of tumor might equally be considered as due to growth broken free from normal restraint.

A plea was made for accepting these conclusions without fear of the deductions which naturally followed from them, some of which are:

(1) That every type of tumor has associations with malignancy, no class being exempt. The general principle, however, might be stated that the more highly organized and formed the tissue of a tumor, the more it belonged to the simple class, and vice versa. All forms of connective tissue tumors seemed to converge to the round-celled sarcoma type, and all forms of epithelial tumors to converge to the encephaloid cancer type, there being, however, many tumors which were quite characteristically malignant although considerably removed from the extreme malignant structure.

(2) Attention was drawn to the difference that exists between the behavior of the developing cells of a tumor and that of an embryo, although under the microscope their appearance might be indistinguishable.

The caution was therefore thrown out that mere structure did not necessarily indicate clinical behavior.

(3) With regard to the etiology of tumors, the general principle was enforced that no theory of tumor growth could be considered satisfactory which would not apply equally to innocent and malignant tumors. The bearing of this on the parasitic and other theories was shown.

(4) With regard to treatment, it was pointed out how the view as to the similarity of all forms of tumor would put the surgeon always on his guard, while the view of those pathologists who held that certain kinds of tumors were invariably innocent would have an opposite effect. Further, with regard to the search for a cure for cancer, it was shown how the view of abnormal growth was consistent with many apparently inexplicable statements as to the behavior of malignant growths. Thus it made it more easy to understand that the life of the tumor cells might be more precarious in some ways than those of the normal tissues, and thus that spontaneous subsidences might occur, or, again, that the cells of tumors might be injured by toxins, X-rays, or even by mental influences. The lecturer thought that mental influence might explain the effect of many vaunted cancer cures, all probably useless in themselves except so far as they might affect the mind of the sufferer.

(5) With regard to the influence of this view on classification of tumors, the opinion was expressed that it was undoubtedly best to divide them primarily according to the type of tissue or organ from which they arose, and in each class to arrange the individuals according to the degree of malignancy which they manifested.

Idiopathic Multiple Cutaneous Sarcoma.

D. Franz v. Krzysztalowicz. (*Monatsh. f. prakt. Derm.*, No. 5, March 1, 1904.)

The case cited differs clinically and anatomically from the Kaposi type and the author has placed it with those sarcomata which, in dermatology, have as yet no distinct classification.

The patient was a male, fifty-two years old. Shortly after a traumatism in the region of the right shoulder a nodule appeared which bled easily and was soon followed by new ones, all varying considerably in size. Subjectively, there were pain, tension and burning. He was given injections of natr. arsenic 0.01-0.03 pro die for six days and then Asiatic pills for several weeks. Under this treatment the number of nodules increased, so that portion of the skin was excised, wound healing readily. Two months later fresh nodules appeared in the region of scar. He was treated energetically with arsenic pills and dismissed in six weeks improved. After six months he returned again with numerous nodules and enlarged axillary nodes. Arsenic five times daily and morphine were administered internally and an anodyne lotion applied externally. The nodules became flatter and some disappeared leaving only pigmented spots; but new ones

continued to appear, pain increased, general condition of sufferer grew worse, and three years from beginning of disease he died.

Autopsy revealed, in addition to skin lesions, similar growths in left pleura, both lungs, left side of heart and liver.

The tumors were situated deep in the skin, lobulated, but not encapsulated. Microscopically, cells varied in size and form and as to number of nuclei, there being as many as ten. Their arrangement was more apt to be polar than central and in cells containing many, they had an irregular distribution.

Pigment was present only in retrogressive nodules and the author considered it the remains of neoplasmatic tissue. Blood vessels were numerous but small, and in later stages their walls were thickened and lumina narrowed.

The nodes in the viscera were microscopically identical with those in the skin.

The writer also describes two cases of sarcoma of the Kaposi type by way of comparison, and concludes that the latter might be called fusocellular and the above described globocellular. In the Kaposi type giant cells are absent, while in the other case they were so numerous that the tumor might be classed with the giant cell sarcomata.

They are probably large connective tissue cells whose nuclei divided while the cytoplasm underwent a degeneration. One might take it that they are the "end-form" in the development of the sarcoma cell, after which they can be absorbed, so that finally the entire nodule disappears as seen clinically.

The infiltration in the initial stage is the same in both; but in the Kaposi type the connective tissue organizes and forms a sharply circumscribed node, while in the other type the collagenous bundles are separated by the increasing cells and from these strings of cells a nodule is formed. In the disappearing nodules there is a growth of connective tissue cells in place of the newly formed ones—the whole being replaced by scar tissue.

INFLAMMATIONS.

By H. P. Towle, M.D., Boston.

Erythema Group of Skin Diseases, On the Visceral Manifestations of the. Wm. Osler. (*Am. Jour. Med. Sci.*, Jan., 1904.)

This is the third of a series of papers by Dr. Osler upon this subject. The first appeared in the *American Journal of Medical Sciences* for December, 1895, under the title "On the Visceral Manifestations of Erythema Exudativum Multiforme," in which he reported eleven cases. In the *Jacobi Festschrift*, May, 1900, he published seven new cases under the title of "The Visceral Lesions of the Erythema Group." In the present paper he has reported eleven additional cases and, further, has

analyzed the whole series of twenty-nine. The chief significance of these papers lies in the author's statement that the same poison which causes the skin manifestations may also cause the visceral lesions. He also asserts that cases occur in which the skin manifestations are, at times, suppressed and in which the visceral lesions alone appear, although, at other times, in these same patients, the skin and the visceral lesions appear together. Because of this latter fact such visceral cases are included in these papers. Although the skin manifestations vary greatly the fact that visceral lesions occur at the time binds these cases into one group. In answer to the charge that he has jumbled together a motley group of skin diseases Dr. Osler replies that "he did so purposely for he was seeking similarities and not diversities, often not knowing what to call a case." In another place he explains that "he classes his cases under the exudative erythema because, while some of his cases would be described as separate diseases, they all belong to the same family. Further, they are characterized by the similarity of the conditions under which they occur, the frequency with which the lesions are substituted the one for the other in the same case, the tendency to recurrence and, finally, the identity of the visceral manifestations."

In short, his aim has been less to report a series of cases with an accurate diagnosis of the skin eruption than to call attention to the association of the skin and visceral lesions. In his first paper he also denies that there is anything new in this idea and quotes a number of authors who have reported similar cases. It has been stated already that he found a multiplicity of skin lesions which occurred either alone or in combination in the same case. In analyzing the twenty-nine cases it was found that "in five cases purpura was the only lesion. In four cases there was arthritis. Four had fever. In seven cases there was the common combination of purpura with raised wheals—purpura urticans. In five there was angio-neurotic œdema, sometimes occurring alone, more frequently with erythematous lesions or alternating with them. Erythematous lesions occurred in fourteen cases, in only two alone, with swelling in the form of erythematous blotches, usually with purpura or urticaria, once only with vesiculation of extensive character."

In his second paper Dr. Osler explains this multiplicity of skin lesions by saying, "that while similarity of lesions may result from a variety of causes, *e. g.*, the purpuric rash of iodism and scurvy are identical, on the other hand, unity of cause may result in a variety of lesions. In one and the same person within a few months, presumably under the same etiological conditions, there may be a multiplicity of skin lesions." Recurrence is another striking feature, sometimes extending over a number of years. Thus, Case xiv. had a history of repeated attacks of urticaria for thirty-seven years, while Case vii. had a history which extended over seven years.

In twenty-five of the twenty-nine cases there were recurring attacks of

colic, sometimes with vomiting, sometimes with diarrhœa, occasionally with the passage of blood. The colic varied from mild to severe and lasted from some minutes to several hours. In some cases there were attacks of colic at various times without skin manifestations. At other times in these same cases the colic and the skin eruption occurred together. In regard to these cases of colic without skin manifestations Dr. Osler says that he considers the association of colic with certain cases of angio-neurotic œdema and the relationship of these conditions to those obscure cases of recurring colic and gastro-intestinal crises in children to be very interesting. In fourteen cases there was acute nephritis. Five of these died of uræmia. He says that "the importance of the poisons causing the skin lesions of the erythema group is not sufficiently recognized as a cause of acute nephritis." He also states that the nephritis, as a rule, comes on at the height of the skin lesion, or it may follow it in a week or ten days, or even, as in case xxvi., a couple of months after the subsidence of the skin lesions. With reference to the skin lesions which occurred in these renal cases he reports that in four purpura alone was present; in three purpura and urticaria; in two purpura, urticaria and erythema; in one purpura, erythema and œdema; in one, at various times, purpura, simple erythema, urticaria and localized œdema; in one œdema and erythema, and in two purpura and erythema.

In addition to the visceral complications already mentioned seventeen cases had arthritis or arthritic pains, usually mild. Seven cases had hæmorrhages from the mucous membranes and two cases had cerebral symptoms. There were also cases in which there was swelling of the fauces and larynx, while in three cases there was pneumonia. In two of the latter Dr. Osler states that it was impossible to determine whether there was any connection between the pneumonia and the skin and visceral lesions. In one case, however, a protracted pneumonia followed directly upon a severe outbreak of exudative erythema. Acute endocarditis he considered rare, as only three cases had even murmurs. In the entire series there were eleven females and eighteen males. While the extremes of age were three and fifty-seven the majority of the cases occurred in patients under twenty.

Erythema Induratum Combined with Lichen Scrofulosorum. Söllner. (*Monatsh. f. prakt. Derm.*, Dec. 15, '03, p. 545.)

The writer reports a case with the following history: Cook, twenty-one, nightsweats in childhood, menses at fourteen, regular. For four years menses have been more scanty. With each menstruation bunches, which desquamate, have appeared on the lower extremities. Two years ago, for the first time, a bunch ulcerated and did not heal for a year and a half. After this one several ulcerated. Has two at present on right lower leg, which have been there for two months. The nodes were painful if broken or in consequence of walking or standing. Feet swollen.

The nodes were at first red, but soon became bluish. If the lesion did not go on to ulceration the color faded gradually. There was no glandular swelling. Family history negative except that her mother died of lung disease. Upon examination signs were found at the apex of the right lung. There were the remains of two nodes, middle left lower leg over the tibia. Near these was the scar of the old ulceration mentioned above. Near the left external malleolus was an almost circular, diffuse red spot whose center was covered with hemp seed sized papules, sometimes confluent, which was about 7 cm. in diameter and was quite sharply defined. On the inside of the left knee was a group of old lesions, of a violet color, with darker centers, color disappearing on pressure. Patches on both thighs, chiefly on the outer surface, of a pale violet, scarcely different from the surrounding skin in touch, elevated in the center to about the size of an urticaria wheal. No evidences of deep degeneration. This is the efflorescence of erythema induratum. Scars of lichen scrofulosorum were present on left leg. On right cheek was an area of deep resistance from an old node. Similar nodes were found about the right malleolus. The skin of the right leg was red everywhere and covered with violet colored spots.

There was a three months' old eruption on the backs of both feet made up of numerous pin-head papules, occasionally elevated, but usually not. Similar papules occurred on both feet between the tendo-achilles and the external malleoli. Here and there was fine scaling between the papules with depressed atrophic scars. There were typical papules of lichen scrofulosorum on the inner side of the right knee, grouped, brownish, size of lentil, scaling, and also on the back and thighs.

Histologically, he found the epidermis normal; the cutis but little changed except for perivascular cells; at the lower border, pressing down toward the fat, an infiltration which he considered to be tubercular. The individual groups of this infiltrate are so large that they often occupy the whole field and are visible macroscopically. Microscopically they consist of a peripheral wall of epithelioid and round cells and a large central necrotic area. The neighboring fat tissue is infiltrated with round cells and has small areas with a central necrosis everywhere. Giant cells were found, often in small groups. No tubercle bacilli were found in ten sections.

In conclusion Söllner remarks that from these observations one can say, with the greatest probability, that erythema induratum is either a tuberculosis itself or else stands in the same relation to tuberculosis as lichen scrofulosorum, which in this case was present with the erythema induratum.

Eruptions Intermediate between Pityriasis Rosea of Gibert and Seborrhœa Psoriasiformis. Brocq. (*Presse Medicale,* July 11, 1903, p. 501.)

The article begins with a report of the following case: A "plaque

eruptive" had appeared fifteen days before in a child of twelve. When first seen the plaque had attained the size of a two-franc piece and had a red border and pale center. Then suddenly another eruption of multiple elements broke out on the shoulders, neck and face, and spread steadily. There was no trace of scratching. The plaque was now the size of a five-franc piece and resembled a plaque primitive of pityriasis rosea of Gibert, which had become eczematous. The secondary eruption was composed of numerous small elements, nearly all of which were isolated from one another, from twenty to fifty centimes in size, irregularly round or oval, with fairly sharp borders, of a pale red or biscuit color, which disappeared completely on pressure, uniform and without tendency to circination, covered with fairly adherent, grayish scales which could be detached by scratching, thus exposing a red and excoriated skin which took a purpuric aspect, not, as in psoriasis, a skin red, glistening and strewn with hæmorrhagic points. These elements existed in great numbers everywhere on the body, but were especially abundant on the sides of the thorax, in the axillæ and in the groins. They were less numerous over the neck, ears, cheeks, forehead and upper and lower extremities. There were also patches of seborrhœa psoriasiform in the scalp.

Brocq then goes on to say that while this case recalls pityriasis rosea of Gibert in its mode of appearance by a single plaque primitive with a subsequent secondary eruption, the character of this secondary eruption suggests rather one of those generalized eruptions which occur in patients previously subject to a seborrhœa psoriasiform, whose evolution is abrupt, which spread over the whole body and which have nearly the same sites of election as pityriasis rosea of Gibert save that they affect the face more often. They may also disappear spontaneously, like pityriasis rosea, in from six weeks to three months. He, therefore, decides that the case is neither one nor the other, but intermediate between the two. Then using this case as an illustration he proceeds to discuss at length the existence of such an intermediate group. He begins by dividing the group into two classes. The first class is very close to the macular form of pityriasis rosea of Gibert, and is characterized by a début with a plaque primitive absolutely analogous to that of pityriasis rosea.

After several days a secondary eruption occurs with the same localization as pityriasis rosea but with more tendency to invade the face and scalp, with elements quite uniform in size and in appearance analogous to a superficial seborrhœa psoriasiform, round or oval, five to fifteen millimeters in diameter, nearly always discrete, but at certain points confluent and in severe cases having a tendency toward eczematisation, but evoluting to a spontaneous cure like pityriasis rosea. The second class is nearer seborrhœa psoriasiform than the first. Its characteristics are that it often affects patients long subject to a torpid seborrhœa psoriasiform at any one point whatsoever of the body, its début is more rarely abrupt than in the first class. It also differs from the first class in that it does

not present a "plaque primitive" analogous to that in pityriasis rosea, but the disseminated generalized eruption has the same objective and evolutive characters as that of the first group.

From this Brocq goes on to say that in all dermatoses there are intermediate cases which establish a relationship with various other diseases. Each group, he says, should be considered as having ill defined boundaries which shade off gradually into the surrounding group rather than as having sharp, well defined limits. He then discusses the existence of intermediate groups in general and one between pityriasis rosea Gibert and seborrhœa psoriasiform in particular very exhaustively, and illustrates his remarks by a very ingenious diagram.

BOOK REVIEW.

Studies on the Pathology and on the Etiology of Variola and of Vaccinia, by William Thomas Councilman, A.M., M.D., Shattuck Professor of Pathological Anatomy, Harvard University, Visiting Pathologist to the Boston City Hospital; George Burgess Magrath, A.M., M.D., Assistant in Pathology, Harvard University, Pathologist to the Long Island and to the Carney Hospitals; Walter Remsen Brinckerhoff, S.B., M.D., Assistant in Pathology, Harvard University, formerly First Assistant in Pathology to the Boston City Hospital; Howard Ernest Tyzzer, A.M., M.D., Assistant in Pathology, Harvard University, Research Scholar of the Rockefeller Institute of Medical Research; Elmer Ernest Southard, A.M., M.D., Instructor in Neuro-Pathology, Harvard University, First Assistant in Pathology to the Boston City Hospital; Ralph Leroy Thompson, A.M., M.D., Second Assistant in Pathology to the Boston City Hospital; Irving Reed Bancroft, A.B., M.D., formerly Resident Physician to the Boston Detention Hospital, and Gary Nathan Calkins, Ph.D., Adjunct Professor of Biology, Columbia University, Consulting Biologist, State Pathological Laboratory, University of Buffalo. From the *Sears Pathological Laboratory, The Harvard Medical School, Publication Office of the Journal of Medical Research,* Boston, Mass., 1904.

The volume containing the series of papers by the authors enumerated above is a reprint of Vol. XI., No. 1 of the *Journal of Medical Research.* The studies embodied therein were based on material collected during the epidemic of variola in Boston, 1901-1903. Of the various subjects dealt with in the twelve articles of the volume the most important are the Pathological Anatomy and Histology of Variola and the Life History of *Cytoryctes Variolæ, Guarnieri,* and we shall direct our attention chiefly to a consideration of the latter.

It is well known that Professor Councilman and his associates, supported further by the biological authority of Professor Calkins, have described a series of cell inclusions in the lesions of variola which they regard as stages in the development of a protozoan parasite, the causative agent of smallpox. The bodies in question are found only in the specific lesions of the skin and of the mucous membranes up to the sixth day of the disease, counting from the first appearance of the eruption. Occasionally they are found as late as the eighth or ninth day; but after this period, when the healing process has set in, the organism has not been seen.

The organism on which our interest centers is described as occurring in two series of forms; in its younger or cytoplasmic form it is present in the cytoplasm of the epithelial cells of the rete mucosum of early lesions and of such of the

older lesions as are extending; in its intranuclear form it is for the most part in lesions more advanced. The name *cytoryctes variolæ* was given by Guarnieri in 1892 to an organism which he described as the parasite of variola and vaccinia and which he showed experimentally to be a living organism; but his account of its various stages of development is less convincing and far less complete than that presented in the volume before us.

Briefly summarised the first or cytoplasmic stage of the parasite begins with the presence of small structureless bodies, 1 to 4 microns in diameter, lying in vacuoles within the bodies of the cells of the lower layers of the rete. These bodies increase in size, develop a reticulated structure containing granules, and undergo segmentation resulting in the formation of small round bodies about 1 micron in diameter. This completes the first or cytoplasmic or "vaccine" cycle of development. A similar cycle is shown by Tyzzer to occur in vaccinia. But the difference between vaccinia and variola is found to depend on the fact that in vaccinia the cycle is single, whereas, in variola a second cycle of entirely different forms follows the completion of the first cycle. In the second cycle the entire process runs its course *within the nucleus* of an epithelial cell. It begins with the invasion of the nuclei by small round ring-like bodies "at the period of segmentation when most of the cytoplasmic bodies have disappeared." These ring-like bodies "increase in size and acquire a definite structure consisting of a series of vacuoles around a large central vacuole. The rim of the central vacuole stains more distinctly than do the other parts of the body. The body becomes larger, the nuclear ring grows less distinct, finally disappears, and the body lies in a completely degenerated cell, or this breaks down, setting free the body. Finally a structure is formed which contains numerous fine vacuoles. At this time small circular bodies begin to appear in it and groups of these are surrounded by a faint ring. The circular ring-like bodies have a central dot, they are one, to one and a half microns in diameter and are seen with great difficulty." The authors regard the bodies of this second cycle derived by segmentation of the cytoplasmic organism as the true infecting material of variola. This brief account is condensed from the detailed description of their work presented by Councilman in May, 1903, before the American Association of Pathologists and Bacteriologists. We produce it here for the better understanding of the subject, though in the work under review this simple description is replaced by an elaborate article by Professor Calkins, in which he gives an exhaustive description of the organism with an interpretation of its highly complicated life-cycle. For the details of Calkins' interpretations we must refer to the original paper; we can give here only the briefest sketch. *a* His account of the early cytoplasmic stage agrees on the whole with that given by Councilman, Magrath, and Brinckerhoff, but is more detailed. With the escape of the spore-like bodies or "gemmules" the first cycle is completed. These gemmules may develop into new cytoplasmic organisms by invasion of new epithelial cells (auto-infection), or *b*, they may become germ cells within the nucleus and there develop into structures regarded as gametocytes, the products of which probably conjugate. The resulting zygote is an amœboid pansporoblast mother-organism. *c* The zygote appears as an intranuclear (sometimes also cytoplasmic) amœboid body with a deeply staining central mass, which resembles the fertilized gametocyte of Coccidium. This body becomes the pansporoblast, the mother-cell of the primary sporoblasts. *d* In the intranuclear zygote-like body the central mass undergoes fragmentation and is distributed throughout the substance of the organism which may attain the diameter of 10 to 12 microns. In this pansporoblast eight to twenty primary sporoblasts may develop, leaving unchanged a large part of the organism which persists as a "rest body." The young sporoblasts are solid and homogeneous at first, but later become hollow and appear as thickened rings. When they have attained a diameter of 1 to 2 microns the thickened ring becomes vacuolated.

Two types of primary sporoblasts are described: in one the spores develop in peripheral vesicles, in the other throughout the substance of the sporoblast. The spores may invade fresh nuclei, giving rise to *e*, the secondary intranuclear phase. This consists of a vesicle thickened at first at one side, the thickened portion extending all around the vesicle as the latter grows. Minute vacuoles develop throughout the periphery; secondary vacuoles then appear and the entire body (secondary sporoblast) is made up of vesicles containing spores, which, escaping, leave behind a sporoblast residuum.

"It will be seen from the foregoing that the cytoplasmic and the intranuclear stages of Councilman, Magrath, and Brinckerhoff correspond to the cytoplasmic and secondary nuclear stage of Calkins, and that Calkins' work has added materially to the complexity of the life cycle of the parasite. He adds an intranuclear stage due to the invasion of nuclei by gemmules, leading to the formation of bodies which he regards as male gametocytes, infers a conjugation between male and female gametocytes, describes a zygote form which forms an intranuclear pansporoblast, in which two forms of sporoblast develop, each producing spores which may invade fresh nuclei, there giving rise to secondary sporoblasts in which spores develop." (Howard and Perkins, *Jrl. Med. Res.*, Oct., 1904.)

On considering this presentation as a whole the reviewer can not escape the feeling that plausible as it is it proves too much. When important deductions are based on details of structure in a body 1 to 2 microns in diameter, there is obviously large room for the play of imagination. It may be admitted that the cell-inclusions described by the authors represent, with considerable degree of probability, a parasitic protozoan organism, but it must not be forgotten that the extremely complicated series of cycles of development are solely a matter of interpretation, not of observation, and that many of the forms described may be closely approximated or even duplicated among the cells of a rapidly growing and degenerating epithelial structure like carcinoma. Whoever has worked by modern methods on cell inclusions in cancer will realize the enormous difficulties of interpretation presented, even when the perfectly fresh material is fixed under the most favorable circumstances. In these variola studies all the material was obtained post-mortem and in most of the autopsy protocols given we read "rigor mortis present." It is but fair to state that Calkins admits these difficulties, but adds that in distinguishing between artefacts and minute phases he has been guided in his interpretation of the life cycle less by the morphology and staining reaction than by the fact that the growth stages are always present in a sequence which follows the development of the skin lesion. But this looks very much like arguing in a circle.

A feature which must occur to every reader of the book is the absence of any serious attempt to bring the parasites into relation to the disease as a whole as distinguish from its cutaneous manifestations, though smallpox is certainly not a skin disease! What is going on in the body of the patient during the fortnight that elapses between the time of his exposure to the disease and the appearance of the eruption? Where are the organisms developed whose myriads of spores or gemmules suddenly overwhelm the cutaneous system on a given day? By what process do the organisms escape from the blood current into the epidermic cells? These questions, among others, must be answered before the pathology of smallpox can be regarded as established.

On the whole, we cannot refrain from intimating that there is still room for some doubt as to the correctness of the interpretations placed by the authors on the cell-inclusions they have described, and we deplore especially the confusion between demonstrated truth and bald hypothesis that pervades Professor Calkins' paper.

Of the other articles in the book those on the occurrence of cytoryctes and

on experimental variola in the monkey, and on the etiology and pathology of vaccinia are of greatest interest and we regret that we can not here discuss them.

The chapter on the pathological anatomy and histology of variola gives a most admirable presentation of the subject, contains much that is new, and may be characterized as one of the best and most complete descriptions of the lesions of smallpox up to the present time.

In conclusion we may well say that these studies of Councilman and his fellow-workers constitute the most important contribution to our knowledge of variola made in recent times, and whether or not all the details of their work are confirmed by future workers in this field the authors are to be congratulated upon their notable achievements in this difficult subject. S. P.

MISCELLANY.

A New Medical Journal, "The American Journal of Urology."

The Journal of Cutaneous Diseases takes more than a casual interest in the fine appearance of the first number of *The American Journal of Urology;* in fact, our interest is somewhat akin to that of Radica in her sister Dodica after the successful termination of the operation which ended their existence as twins. And, although the operation which severed us was performed in January, 1903, the complete rehabilitation of our severed companion, Genito-Urinary Diseases, has just taken place with the October, 1904, issue of this official organ of the American Urological Association.

The editor, Dr. Henry G. Spooner, has an able staff of directors consisting of Drs. Arthur Bevan, Follen Cabot, A. E. Gallant, Orville Horwitz, Howard A. Kelly, Gustav Kolisher, Robert T. Morris, William H. Porter, Robert B. Preble, and Hugh H. Young. The first number has an interesting table of contents, a glance at which will show ample justification of our inability to confine such a vigorous department of surgery to the pages of an organ devoted to an equally vigorous specialty of medicine, Dermatology.

We wish *The American Journal of Urology* the greatest success and a long life.

THE JOURNAL OF
CUTANEOUS DISEASES
INCLUDING SYPHILIS

VOL. XXII. DECEMBER, 1904. No. 12.

ON THE RELATION OF CERTAIN DERMATOSES TO EACH OTHER AND TO CHANGES IN VASCULAR EQUILIBRIUM.

By JAMES NEVINS HYDE, A.M., M.D., Professor of Dermatology, Rush Medical College, Chicago.

and

ERNEST L. MCEWEN, M.S., M.D., Associate Instructor in Dermatology, Rush Medical College, Chicago.

Read before the twenty-eighth annual meeting of the American Dermatological Association, Niagara Falls, June 2 and 3, 1904.

THE tendency in dermatology has been toward elaborate clinical subdivision, with multiplicity of titles and refinement in nomenclature; yet the classification of cutaneous diseases is extremely unsatisfactory. It is inevitable that in the development of a special branch of medicine particular attention should be paid to objective manifestations, to the neglect, partial at least, of underlying factors not obviously manifest. The amassing of clinical facts, however, must necessarily precede their correlation; and it may be expected that the future will bring a clearer recognition of fundamental relationships. In the following pages an attempt is made to study certain dermatoses of the hands and feet in their relation to each other and to a uniformly associated condition—that of vascular instability.

The cutaneous phenomena displayed in the hands and feet which are here regarded as linked in a pathological chain, and which are in part or wholly the result of unstable vascular equilibrium, may be enumerated as follows:

Hyperidrosis localis, Dysidrosis, Hydroa, Pompholyx, Cheiropompholyx, Keratodermia erythematosa symmetrica (Besnier), Kera-

todermia palmaris et plantaris, Keratosis palmaris et plantaris, Erythema keratodes, Symmetrical tylosis of the palms and soles, Hyperkeratosis subungualis, Subungual keratoma, Onychauxis, Onychogryphosis, "Chronic inflammatory diseases of many finger-nails," and Dystrophia unguium.

In the citation of cases which follows, the order of sequence of these phenomena from the simpler to the serious types is observed. Every considerable clinical experience must include scores of illustrations of each element in the closely linked chain of morbid conditions. It is the recognition of the links of this chain which is of paramount importance. Omitting a large number of data which are fully set forth in the literature which has accumulated on the subject, a single clinical illustration of each phase of the morbid process is given. The valuable contributions to the subject made by pathologists have heretofore been concerned rather with tissue changes demonstrable in sections of the skin microscopically studied than with the relations of these changes to the essential disturbances of the general economy which are responsible for the results.

1. The earliest and simplest objective symptom of retardation of the circulation in the hands and feet is the familiar persistence of abnormal coldness of the organs, perceptible alike to the subject and to the touch of another. That which is abnormal in these instances is the persistence of the condition, seeing that the hands and feet of sound individuals for brief periods of time may be even colder than those of the victims of the disorder. The affected parts may be cold and white, or cold and pink, the difference being explicable by varying conditions in the capillary channels. The hands and feet may be dry and cold and not moistened with sweat. Instances of this impaired circulation are sufficiently common among the cachectic, the tuberculous, and the asthenic.

2. With more or less persistence of the coldness of the hands and feet, there is often a coincident hyperidrosis, and this in either pink- or pallid-hued organs. The degree of wetness, it is well known, varies in different individuals and in the subjects of the disorder at different periods and under diverse conditions of the environment and nervous state. That the wetness is due to excessive effusion of sweat is demonstrable both by the chemical constitution of the exuded fluid, the evaporation of which is in part only responsible for the condition, and by microscopical examination of sections of the

sweat-pores from which the fluid proceeds. That the involved organs are relatively cool irrespective of the evaporation of the effused sweat, is demonstrable after careful drying and examination of the skin. In the milder cases, the hands and feet are habitually more moist than in a condition of health. In exaggerated cases, the organs are as wet as when immersed in water. The persistence of this condition throughout long periods of time is illustrated in the following case:

(*Case I.*) H. B., a single woman, fifty years of age, well nourished but pallid, weighing 140 pounds, without history of drug-usage or serious ailment, had led the life usual in the leisure classes of society. A grandfather died of cardiac disorder; a maternal uncle had frequently fainted when his hands were chilled.

She complained of persistent wetness of both hands and feet, habitually carrying a handkerchief to save her clothing from contact with the moisture. The condition has existed since early childhood. The hands are distinctly cold to the touch, and when held at a distance from the person the sweat visibly drips from the fingers to the floor. She is the subject of a well-marked bradycardia, the pulse-rate varying in the erect posture from 50 to 55 to the minute, with occasional intermittance.

3. The type of disorder in which, with hyperidrosis, smaller and larger blebs form in the integument of the hands and feet, is that to which Tilbury Fox and his English colleagues have in effect limited the title Dysidrosis (or Pompholyx), while Thibierge and other French writers regard the condition as a third or exaggerated stage of what they term "Dysidrose," a term made by them to include two or more of the conditions described above, resulting from impairment of equilibrium in the circulation. The diagnosis of "Dysidrose" in France is made with a frequency only equalled by the rarity with which the English accept a given condition as illustrative of what they designate as Dysidrosis.

In this morbid state there are multiple and often exceedingly numerous rounded, oval, or very irregularly shaped sub-epidermic vesicles, which enlarge to pea- to bean-sized and blebs even of greater size, which develop over the skin of the hands and feet, more often, however, upon the hands. The elements of the eruption are usually symmetrically, occasionally asymmetrically disposed; spring from a tumid, often sensitive and tender integument; and are filled with a freely as to drip from purposely ruptured lesions. As a consequence yellowish, alkaline serum, which in exaggerated cases is furnished so

of coalescence, blebs even of the size of large nuts may form, enclosing septa representing the walls of the fused eruptive elements. The eruptive symptoms, among the working classes, often undergo a secondary infection with pus cocci. In most cases, collapse of the bleb occurs either from evaporation or rupture, a sodden floor for a brief time remaining until crusting occurs, the extent of which is related to the severity of the process. The organs involved are invariably the seat of hyperidrosis. There is very rarely obvious hyperæmia or an appearance of redness. The subjective sensations are those of tenderness, burning, and pain, rather than of pruritus. As to the regions of chief attack, the palmar faces of the hands, including those of the fingers, are most frequently invaded, though in extreme cases the backs of the hands and feet and the entire organs are extensively involved.

Crocker, who saw several of Fox's patients, states that the disease is one occurring chiefly in the summer season; but in our experience it is a complication of hyperidrosis, liable to occur at any season of the year when the sweat function is abnormally active, either by reason of a heated atmosphere or as a result of systemic infection. We have observed the disease most often in the asthenic and the cachectic.

The following is an illustrative case:

(*Case II.*) W. C., aged 45, married, and the father of three children, weighing 160 pounds, applied in the autumn of the year for relief of a dermatosis affecting the hands chiefly. He was a building contractor, who, a few months before the attack, had sustained grave business reverses. He had used tobacco for years in large excess. The patient was anæmic, complained of insomnia, suffered from cardiac failure, and exhibited a coated tongue and other evidences of gastro-intestinal disturbance. The pulse was rapid and corded, at times intermittent. His hands and feet were bedewed with sweat. Both hands were swollen and uniformly covered with pea-sized bullæ, containing a turbid serum of grayish-yellow tint. A few lesions had coalesced to form marble-sized blebs. Interspersed among these were subepidermic vesicles, which suggested the "boiled sago-grain appearance" of English writers. Where rupture had occurred, in consequence of dressings previously applied, the integument was sodden and in places covered with light crusts. The right hand was somewhat more extensively affected than its fellow.

4. The vulnerability of the moist hand and foot to the accidents

of pressure and friction is responsible for a series of dermatoses, which have been amply described in the literature of cutaneous medicine. The results are betrayed in three fairly well defined grades of hyperæmia, inflammation, and ulceration. These may be briefly outlined as follows:

In the first grade, the palms and soles, softened and in varying degrees macerated, resent the impacts and contacts of the hours of the day expended in active exertion. The reaction occurs in these regions rather than over the dorsa of the organs, chiefly because the former are submitted necessarily to more frequent pressure and attrition; though in many cases the backs of the hands and feet are similarly involved, the morbid process extending from the palm or sole upward. The regions most often affected beyond the limits of the palms and soles, are the wrists, the interdigital spaces, the soft tissue of the instep as high as the ankle, and the sulcus on either side of the tendo Achillis.

The first reactionary effects are declared in a hyperæmia, active or passive, evidenced by a reddened or pinkish-red blush extending uniformly over the parts invaded, or limited largely to regions of special pressure, such as the heel, the skin covering the cushion over the first and fifth tarso-metatarsal articulations, and surfaces adjacent nearest the axis of the sole. In the hand, the hypothenar eminences and those over the proximal articulations of the metacarpal bones of the thumb and little finger, may exhibit circumscribed areas of redness. The color disappears on pressure and returns more or less speedily according to the condition of the circulation. The subjective sensations are mild pruritus of the hands and an annoying burning and itching of the feet.

When carefully examined, the affected surface is found to be smooth, non-infiltrated, reddened, and invariably moist. Here and there, pin-head-sized whitish scales are visible, rarely numerous, their edges often slightly tilted above the general level. Each of these represents the site of a pre-existing lesion, where a droplet of sweat was imprisoned and afterward escaped, either by evaporation or rupture, from its chamber in the corneous layer of the epidermis. The following case is in illustration:

(*Case III.*) K. W., a florid-faced Irish working maid, aged sixteen, weighing 120 pounds and presenting the general symptoms of unusually sound health, complained of excessive burning and soreness of the feet at the close of the day. She had been eating without restraint large quantities of beef, sugar, and hot breads. (No cardiac disease was recognized.)

When examined, the hands were found to be pink, warm, and constantly moistened with sweat. The feet were pink-tinted, wet, and the soles were the seat of a uniformly displayed hyperæmia. The smooth, reddish-tinted surface of each was dotted here and there with superficial, papery, thin, and silvery scales, the edges of which were slightly lifted from the general level. She was relieved, after strict limitation in diet, with application of stimulating lotions followed by a dusting powder.

The second grade of this morbid process, due immediately to the vulnerability of the moist hand and foot, includes the classical phenomena of inflammation. Under the titles "Eczema palmare," "Sweat Eczema," and others, many cases have been described. In these instances there is invariably undue moisture of the hands and feet. The epidermis, weakened by constant maceration, is unfitted to withstand the accidents of daily toil with the hands and of friction and pressure through the medium of shoe, boot, sock, or stocking. The result is first declared commonly in the hyperæmic state described above, which is readily pushed to the point of awakening an inflammation of the parts involved, varying greatly in intensity and severity. The subjective features are those in general of a subacute dermatitis, including sensations of itching and burning. The objective symptoms, complicated by the results of scratching, are those described by most authors under the title of eczema. The skin, at first reddened, later becomes infiltrated, and finally exudes serum as well as sweat. The inflammation may be limited to the palm or sole, but frequently extends beyond the limits of these regions, as described above, to the wrist, the instep, and the ankle. The areas of involvement are, as a rule, poorly defined. Oozing of serum, pustulation, and crusting alternate in a persistent and distressing series of accidents, often unrelieved, save for brief periods of time, by local treatment. The following is an illustrative case:

(*Case IV.*) W. B., forty-eight years of age, weighing 240 pounds, a physician in active practice, complained of an inflammatory affection of the feet, from which he had suffered for four years. He had applied to Professor Kaposi, of Vienna, who treated him for an "eczema" of the feet with the Wilkinson salve, securing thus an appreciable but transitory benefit. The patient habitually used tobacco and alcohol in excess.

When examined, the hands and feet were found constantly moistened with sweat. The soles of the feet and the insteps and interdigital spaces were the seat of poorly-defined patches, in which the integument was reddened, infiltrated, here and there crusted, and in places

oozing. The itching was intense, with nocturnal aggravation. The patient was the victim of arterio-sclerosis and an enlarged liver.

The third grade of this morbid condition results in ulceration, an unquestioned sequence of the conditions described above occurring in asthenic subjects specially predisposed to degenerative changes. The following is in illustration:

(*Case V.*) Mrs. R. F., aged twenty-six, married four years and mother of two children, weighing 135 pounds, applied for advice August 3, 1902. She had suffered for nine years with excessively cold and wet hands and feet, accompanied by severe itching and pain, producing constant distress. She was in a state of typical neurasthenia.

When examined, the hands and feet were excessively cold to the touch and drenched with moisture. Over the right ankle, near the outer malleolus, was an irregularly ovoid patch, produced by confluence of the smaller areas, made up of verrucoid elevations springing from a partly ulcerated and partly cicatrized floor. Dark-colored crusts were interspersed among the warty growths. In the parts most stretched when walking, there were painful and excoriated fissures. Thin, horny plates began to form over each heel and at the outer border of the sole. The heart's action was weak; the urine normal.

5. As a consequence of interference with vascular equilibrium, the hands and feet, constantly cold and macerated with excessive sweat, at first exhibit the symptoms already described. Becoming, however, more and more vulnerable in direct consequence of the persistence of the morbid condition represented in the type cases briefly outlined above, at last the integument inevitably attains the keratoma stage. At times early in the history of the hyperidrosis or so-called dysidrosis, careful observation reveals the fact that, as in the case last cited, more conspicuously in the soles of the feet, callous thickenings begin to develop. This results in part from defective keratinization of the corneous layer of the epidermis, and in part, it seems probable, as a consequence of what may be recognized as compensation for the diminished powers of resistance of the sensitive integument. The issue is a retrogression to the type of the foot of the aquatic animals. In the fins of fishes, in the feet of waders, and in the pedal extremities of the hippopotamus a similar cornification is provided with the view of prevention of maceration. In the keratomatous stage of lost vascular equilibrium, two fairly distinct grades may be determined, as illustrated in the following cases:

(*Case VI.*) F. O., a physician, forty-seven years old, weighing 210 pounds, married, and father of two healthy children, had suffered for twenty-five years from what was termed by the physicians who treated him in vain "eczema of the feet." Two years prior to its occurrence, he had begun the study of medicine in a school in one of the Southern States of this country, and had then been advised by his teacher in anatomy to chew tobacco in order to aid in overcoming the repugnance common in the first year of medical study to the environments of the dissecting-room. Since that date he had regularly smoked between eight and ten cigars daily and had been chewing tobacco for a great part of his hours of professional work when not engaged in smoking. His urine was normal; his heart-beat registered at 72; the sounds were negative; there was no unusual degree of arterio-sclerosis.

He had wet and pink hands; the redness diminishing under pressure with the diascope and slowly returning when the pressure was removed. His feet were cold and wet; the soles reddened, scarcely infiltrated, with here and there minute, silvery-white scales visible at points where the sweat had accumulated in minute pockets and subsequently disappeared after rupture of the chamber in consequence of pressure. The feet were the seat of burning and itching sensations. The early keratoma stage in this case was conspicuous but not yet complete. A callous formation was developing in the usual sites, as follows: A firm, horny ring surrounded the flattened palmar face of the big toe; another, less distinct, encircled the corresponding part of the little toe. Fainter signs of the same process could be recognized at the free plantar edge of the second, third, and fourth toes, their lateral faces being compressed by contact with their immediate neighbors. A horseshoe-shaped flattened ring, its concavity forward, its thicker dimensions on the outer edge, encircled the point of each heel. A faint halo fringed the outer border. The nails also were beginning to exhibit changes. The free border of each was thickened and very slightly raised above its normal position. The nails of the hand were as yet spared.

The second, advanced grade of this condition (described by authors as Keratodermia palmaris et plantaris, Keratosis palmaris et plantaris, Keratoma of the hands and feet, etc.) has been amply delineated, both by description and in striking portraits of the well-recognized deformity. The following is an illustration:

(*Case VII.*) R. M., aged twenty-six, unmarried, weighing 140 pounds, a student of law, gives a good family history and has suf-

fered from no diseases save those of childhood, including scarlatina. For the preceding ten years, he has been engaged in study, though spending his vacations in farm work. His habits are excellent. There is a moderate bradycardia, but no cardiac lesion, the pulse registering 64 to the minute.

The hands and feet are constantly cold and wet. There are a few patches of callous skin on the palmar face of the thumbs. The soles of the feet display circumscribed, dense, leathery, whitish-yellow callosities in a wide, horseshoe-shaped ring about the point of the heel, encroaching slightly upon the sides of the feet, with similar circumscribed callosities over the palmar faces of all the toes, save the fourth of each foot and the second of the left foot, parts relatively protected from pressure and friction. At the distal extremity of both first and fifth metatarsal bones are circular discs exhibiting the same features. The nails are onychogryphotic; the free border of each tilted vertically from the nail-bed; the subungual spaces filled with horny masses of epidermis; the nails themselves discolored, rugous, and exhibiting a marked tendency to lateral curvation.

6. The changes in the nail directly related to defective keratinization have been described by authors chiefly under the titles onychogryphosis and onychauxis. Neither term in any adequate sense describes the character of the disorder or its frequent association with other symptoms of unstable vascular equilibrium. Few authors have suggested any such connection in their description of lesions of the nails to which these clumsy titles have been given. And yet those lesions are more constant of occurrence in connection with keratoma of the palms and soles than in any group of disorders affecting the hands and feet.

Two grades of well-defined change in the nail associated with sweating and circulatory disturbance may be recognized. The distinction between the two is established: first, by the grade of development of the disorder; second, by the character of the nail-changes.

In the first class, there is no subungual keratosis, the nails, none the less, being characteristically tilted away from the bed. Instead of assuming a dirty-yellowish tinge in these mild cases, the upturned nail has often a peculiar, dull, milky-whitish hue.

(*Case VIII.*) The condition is illustrated in the following record: Miss S. P., aged twenty, working in a telephone station, weight 120 pounds, is constipated, and has had poor health since early childhood.

The patient has always suffered from wet hands and feet. When

examined, these organs are found to be warm and wet with perspiration. The nails of the hands are slightly diverted upward from the normal line, some more than others, especially those of the little fingers, which are very markedly tilted away from the beds. The nails are not in any sense thickened, but thin, and some have a characteristic milky-white hue, the up-tilted nails being more conspicuously whitened than those reclining on their beds. All the nails of the fingers present a distinct exaggeration of the transverse convexity, with unusual down-turn of the edges of the nail. The appearance of the nail-plates thus deformed suggests that they have been contracted by a transverse narrowing of the nail-bed. Those most characteristically altered in transverse diameter are the thinnest and most milky-white.

The nails of the feet are characteristically altered. The patient states that she has been obliged to trim them in order to save her stockings from perforation by the upward thrust of the nail-growth. The nail-plates are all transversely curved and narrowed and are distinguishable as thinned curved blades, with edges scarcely projected above the level of the skin of the dorsum of the toes. Each semilunar-shaped plate is directed vertically, sustaining little further relation to the nail-bed proper. The exposed and unprotected dorsal surfaces of the last phalanges of the toes are macerated and somewhat suggest the appearance of chamois-skin immersed in water.

The second and advanced grade of this condition is accompanied by the usual wetness and clamminess of the hands and feet. The nails, as in the case just cited, are tilted upward and away from the long axis of the digit; they are thickened, discolored, and often the seat of unusual transverse curving, with the result of producing the effect of a nail that is smaller than the needs of the terminal phalanx; and, well-nigh invariably, the subungual space is more or less choked with imperfectly formed corneous material, slightly resembling the similar condition in psoriasis of the nails. Every nail of both the hands and feet, or selected nails only, may exhibit this peculiarity. The condition is said to be more common in the nail of the great toe than elsewhere, but this statement is based upon an imperfect study of symptoms, as in most well-marked cases, even though the change is most obvious in the big toe, it can be recognized in less pronounced features in the nails of the other digits. The following case, originally reported by one of us in a communication made to this body in 1887, illustrates the characteristic features to which attention is here directed:

(*Case IX.*) N. B., an unmarried woman, aged twenty-four years, lymphatic temperament, a servant by occupation, was first brought to the clinic from the County Hospital, where she had been a patient for several weeks in the spring of 1884. She stated that her parents, two sisters, and one brother, living in Scotland, were healthy and free from symptoms of her disease. She had been admitted to the hospital for relief of a symmetrical recurrent tylosis of the feet, and failing to secure relief there applied elsewhere. Some months later, she was admitted to the Presbyterian Hospital, and was under our observation in that institution until the spring of 1887. During all this time her physical symptoms were practically repeated in a recurring cycle of changes. About one year previous to her original admission to hospital, she first began to suffer from her disorder, though insignificant symptoms of it had been noticed some time before the date referred to above.

When examined, her condition was as follows: Her intelligence was above the standard to be expected in one of her position. Her nutrition was fair, menstruation and functions of the alimentary canal properly performed. In the sitting posture, the cardiac pulsations averaged between fifty and sixty per minute, and were often counted at fifty. No organic disease of the heart could be recognized. The hands were constantly cold and bathed in a profuse sweat. This perspiration was effused to such excess as to be a constant source of annoyance to her. All the nails of the hands were slightly discolored, somewhat rugous, their free borders slightly separated from that part of the nail-bed adjoining the tip of the finger. In the angle thus formed was a grayish, irregular mass of tissue, proliferated from the bed of the nail. This condition was very much less marked than the similar onychauxis to be noticed in the toes. There was no tylosis of the palms or symptoms of anæsthesia in those organs; the skin of the hands were soft and supple, though clammy and macerated with sweat.

The soles of the feet, including the plantar faces of the distal phalanges of the first and fifth toes, were symmetrically involved and displayed a uniform, grayish-yellow, thick, firm, and closely adherent callosity, whose surface was exceedingly rough and irregular. It was absent over but a small area of the sole, next the instep and plantar faces of the second, third, and fourth toes. On account of the habitual shedding and recurrence of this plantar shell, the feet had been at times exceedingly tender, and the inability of the patient to pursue her usual vocation on foot, resulting from this cause, had first in-

duced her to seek hospital relief. When the callous masses were removed, either spontaneously or as a result of the soapings and scrapings practiced by the patient herself, a sound tissue was never recognized beneath, but always an irregularly roughened, yellowish-gray and softish, macerated, horny layer of the epidermis. As a result, whether the cast were forming, formed, or recently shed, the soles of the feet were tender and locomotion correspondingly impeded. The feet were habitually cold and wet, and there was some anæsthesia as far as the ankle. Two pea-sized callosities on the dorsal surfaces of the fourth and fifth toes of one foot participated in all these changes.

The nail of each toe was so deformed as to make the wearing of the usual coverings of the feet painful. Each nail was enlarged, unusually friable, deprived of its polish, and tilted up, often at an angle of thirty degrees from its bed. In the groove thus formed had accumulated an irregular mass of tissue, which resembled to a certain extent the uneven surface of the sole of the foot when the callous plate which covered it had been partially scraped off. The dorsum of the foot, though cold and macerated with constantly effused sweat, was apparently otherwise unaltered. Throughout the time during which this patient was under observation, no tendency whatever to ulceration beneath the plantar encrustation could be recognized.

A second variant from the normal standard of nutrition of the nail is displayed in connection with embarrassment of the circulation when the hands and feet are the seat of a well-marked hyperidrosis and the nail-substance exhibits no perceptible increase in its dimensions.

(*Case X.*) A male subject, pauper, fifty-five years old, was presented at the authors' clinic. He had been for years using alcohol to excess. The hands and feet were bathed in sweat; the lower limbs œdematous; the abdomen tumid. There were granular casts and a large amount of albumin in the urine. The heart was feeble and intermittent.

The nails of both hands and feet were conspicuously altered in appearance, several of the nails of the toes having the consistency and feeling of the carapace of a soft-shell crab. Several of the nails, in consequence of this softness and of the ease with which they had yielded to the pressure of the coarse boots worn by the patient, exhibited an odd-looking folding of the nail-tissue upon itself, one nail being the seat of a distinct fluting.

The third variation recognized by us is that peculiar to the condition described by authors as "clubbed fingers," and in our ex-

perience is relatively rare. It seems to be related to the vaguely defined group of symptoms confused under the misleading title of "Raynaud's disease." The nails in this anomaly have an eburnated appearance; they may be discolored; are dense, shining, often presenting an unusual polish of the outer face of the plate. They are neither tilted upward nor involuted, but tend to assume a distinctly recognizable curve in the line of axis of the phalanx. The digits on which they rest have without question a "clubbed" appearance and remotely resemble the condition found in acromegaly. The hands and feet, as in all the cases here tabulated, are cold and bedewed with sweat.

There are two fairly distinct grades of the special change produced in the nail where there is no accumulation of ill-formed corneous substance in the subungual space, and where there is antero-posterior curvature toward the point of the digit. There is coincident alteration in various degrees of the nail-plate. This first grade is illustrated in the following:

(*Case XI.*) F. W., a commercial traveler, aged thirty-two, weighing 175 pounds, presented himself with recently acquired syphilis in 1902. He had previously suffered from three blennorrhagic attacks, one of which had resulted in producing a nodule in the globus minor of the left epididymis. When contracting these disorders he had lived a dissolute life, smoking ten cigars daily and drinking heavily. During these periods, he had frequently suffered from attacks of angina pectoris, with fluttering of the heart and intermittent pulse. He had been leading an absolutely correct life for two years. He was examined May 24, 1904, when he presented no signs of syphilitic infection. He had, however, suffered from coldness and wetness of both extremities for years before infection of any kind.

The hands and feet were bathed in sweat and cool (not *cold*) to the touch. The soles of the feet were pink-tinted on the border above the limit of the plantar contacts with the surface of the ground. A faintly-defined keratomatous thickening had begun over the heel and the outer limit of each sole.

The nails of both feet and hands were characteristically altered. A few of the nail-plates, not all, were transversely, others longitudinally, striated. All were noticeably curved forward toward the tip of the digit. Each presented a peculiar, purplish-red tint and an exterior polish, this smoothness being perceptible even in the corrugated nails. This condition in general had somewhat improved since the patient had lived correctly.

The more advanced grade of this anomaly is illustrated as follows:

(*Case XII.*) A married man, aged thirty-two, clerk, weighing 160 pounds, well developed and regularly attending to his duties, complains of pain in the hands and feet. He is the subject of poor digestion and is often troubled with malaise.

The hands and feet are unusually cold to the touch. When handled, they produce to the touch an icy suggestion. They are dripping with sweat on every occasion when examined.

All the nails of both hands and feet are dense, polished, curved forward over the point of the digit, and have a faintly empurpled hue. The distal phalanges are all evenly and uniformly "clubbed." The embarrassment in the circulation is made conspicuous by contrast when elevating one hand while the other rests at the side in the standing posture. In this way, the passive congestion of the organ which is below the plane of the heart is visibly increased. His habits are generally good.

Circulatory disturbances in these and other cases of similar type seen by us are practically constant and justify careful investigation of the possibilities of vascular instability as an etiological agent in the production of the essential pathological processes. For the purposes of this paper, two conditions may be chiefly considered: first, hyperidrosis, and, second, parakeratosis, manifested in both skin and nails.

Vascular equilibrium is established in that condition of the circulatory system in which is maintained the proportionate distribution of arterial, capillary, and venous pressure which is essential to the proper performance of the functions of the various organs of the body.

The subject of blood-pressure and its relation to disease is an extremely complicated one, owing to the multiplicity of factors concerned in the maintenance of the normal, and to the diversity of influences acting upon these which may disturb a physiological equilibrium. Omitting from consideration the local variations which are dependent upon changing functional requirements, the general blood pressure curve may be described as follows: Starting at its *niveau* in the left ventricle, it gently descends as the terminal arterial twigs are approached, where, in the arterioles, an abrupt fall occurs. In the capillaries a slight decline appears, which is continued in the veins, the pressure in the latter becoming negative before the right auricle is reached.

By far the most important factor influencing blood pressure (which in itself is the resultant of the action of the heart pumping a fluid against the resistance of elastic vessels) is the nervous system acting upon the heart and blood-vessels through the agency of special nerves. While it is true that general pressure is increased in plethora and diminished in anæmia, the greatest variations are dependent upon changes in the circulatory mechanism rather than in the circulating medium. With respect to the heart, simple increase in the rate and power of the beat increases the arterial, and decreases the venous, pressure, while the capillary pressure remains the same or is raised. Contraction of the arterioles increases arterial pressure; dilatation of them reduces the arterial, and increases the capillary, pressure. The latter effect also follows when the venous channels are narrowed or where from any cause venous pressure is raised. It is evident, therefore, that cardiac force and rate and vessel calibration are very important elements in blood-pressure phenomena. These are under nervous control, the mechanism of which may be described briefly as follows:

For the heart, inhibition is accomplished through the vagus. This rises in the floor of the fourth ventricle, leaves the cranium by the jugular foramen, receives fibers from the glosso-pharyngeal and spinal accessory nerves, and descends to its distribution to the larynx, pharynx, œsophagus, lungs, stomach, and heart. Stimulation of the cardiac branches produces slowing of the heart rate. Acceleration of the heart-beat is the function of the cardiac sympathetic; its fibers leave the cord with the third spinal nerve-root, pass, by way of the upper cervical sympathetic ganglia, to join the vagus trunk near the jugular foreamen, from which point it descends, with the vagus, to its distribution in the heart muscle.

For the blood-vessels, calibration is regulated by the vaso-motor nerves. The complex system is made up of (a) vaso-motor centers in the medulla, with subsidiary centers in the spinal cord; (b) vaso-motor nerves of two kinds, constrictors and dilators. The vaso-motor center has been accurately located in the floor of the fourth ventricle by methods of section. When communication between it and the cord below is interrupted, a marked fall in blood-pressure occurs. After a time, a rise follows, explicable by the fact that the function of maintaining vascular tone is taken up by subsidiary centers resident in the cord. The exact location of these subsidiary centers, however, is not known. The vaso-constrictor nerves (accelerators) leave the cord by the anterior roots from the second dorsal

to the second lumbar, inclusive. They pass by way of the white *rami communicantes* to the lateral sympathetic ganglia. In these are located cell-stations, from which new axis cylinders pass as gray fibers to their destination upon the vessel walls. The vaso-dilators (inhibitory) are not limited in their outward passage from the cord, as are the constrictors; their cell stations are not found in the lateral ganglia, but in the great prevertebral plexuses or in the terminal ganglia upon the vessels themselves. Experimentation has demonstrated the presence of cell-stations for the cardiac accelerators and for the sweat-glands in the prevertebral ganglia.

It is obviously necessary that in order to produce constriction or dilatation by nerve impulse, contractile cells must be present upon the vessel walls; hence, it is readily seen how the calibration of the arteries and veins may be changed as these are supplied with muscular coats. Until recently, the capillaries have been supposed to be beyond the influence of vaso-motor nerves, since they are made up of endothelia disposed in a single layer. Steinach and Kahn* have demonstrated, however, that contractile cells are present upon capillaries, and that these cells are capable of stimulation directly or through the nervous system; their contraction narrows or completely obliterates the capillary lumen. The important bearing of this discovery upon capillary blood pressure is apparent; it can explain an enormous local rise through direct action of irritants within the capillaries.

What relation has blood-pressure to lymph production? There has been much discussion concerning the true source of lymph. Both the mechanical theory of filtration and the vital theory of endothelial secretion are considered insufficient to account for all experimental findings. Authorities seem agreed, however, that the lymph flow is increased with augmentation of the intracapillary pressure, irrespective of whether the process be one of filtration, osmosis, or cell secretion. Unquestionably, certain lymphagogic substances act by increasing osmotic interchange through the capillary walls; others increase the flow of lymph by rendering the capillary walls more permeable, through toxic action.

What relation do the facts detailed above bear to the subject in hand? Respecting, first, hyperidrosis: If by constriction of capillaries, or of venules, either by direct action of circulating irritants, or by impulses from vaso-motor centers, intra-capillary pressure be raised and the lymph flow thereby increased, would not the following result: fulness of tissue from increase in amount of lymph and

* *Arch. f. d. ges. Physiol.*, Bonn, XCVII., 105-133.

hyperidrosis from increased lymph pressure in and about the sweat glands? Further, the constant association of rapid heart action and wet hands in those who use tobacco to excess suggests that the factor which is stimulating the cardiac accelerators is acting also upon the nerves regulating the sweat glands. We have therefore at least two bonds of relationship between circulatory disturbances and hyperidrosis: one through abnormal conditions of intracapillary pressure; the other through associated action of nerve stimuli upon vaso-motor and viscero-motor centers.

As regards parakeratosis: Unna has shown the effect of cell-œdema upon the process of keratinization. Cell-œdema implies excess of tissue lymph. We have therefore a direct connection between hyperidrosis and parakeratosis, since an antecedent condition, dependent upon circulatory instability, is common to both.

With respect to the great preponderance in man, of hand and foot dermatoses traceable to disturbed circulation, it is interesting to note that the symptoms of instability of vascular equilibrium are rarely if ever displayed in the extremities of quadrupeds among the lower animals, for the reason in part that in them, whether for the moment they assume the erect posture or are engaged in locomotion, the long axis of the trunk is commonly maintained at right angles to the supporting limbs. In the human family, on the contrary, the phenomena of impaired vascular equilibrium are conspicuously exhibited in the hands and feet; first, because of the fact that in the erect posture the currents within the vascular walls correspond more or less closely with the axis of the trunk; and, second, because of the distance of the hands and feet from the centers of circulation. A striking illustration of the fact first cited is furnished by the existence of valves in the veins of the trunk in man which are wanting in the quadrupeds. In the case of children not engaged in toil, the consequences of perturbation of vascular equilibrium are rarely perceptible before the twelfth year of life. With respect to the organs chiefly suffering from such changes, it is to be noted that they are, as a rule, symmetrically affected, either the two hands, or both feet, or both hands and feet.

Reviewing the objective symptoms of obstructed circulation, there is ground for the belief that many of them have been included by investigators in their description of the disorders the titles of which have been cited above. It would be an error to conclude that each of the morbid conditions represented in the list is solely due to vascular changes of the types here considered. Without question, hand and foot dermatoses may occur where vaso-motor influences are not the

chief etiological factors. The same may be said of certain dystrophies of the nail, such as those occurring in lepra, of certain keratoses of the palms and soles developing under the influence of arsenic administered internally, and of erythematous lesions of hands and feet occurring in subjects of toxæmia. Due allowance, however, being made for these exceptional cases, the fact remains that under each of the titles enumerated above a large number of cases has been included which properly should be classed as sequences of impaired vascular equilibrium, and not as special dermatoses.

The condition described in some of the treatises on general medicine as hypertrophic pulmonary osteo-arthropathy has been illustrated by too few cases to serve as a basis for definite conclusions. None the less, the symptoms described under the title given, in several points strikingly suggest the cutaneous symptoms of embarrassment of the circulation and their remote results. In the so-called hypertrophic pulmonary arthropathy, the terminal phalanges are said to be "spread with both transverse and longitudinal curves"; the nails are large and obviously curved over the extremities of the phalanges. In some instances, the fingers themselves are reported as elongated. Investigators are still undecided as to whether the disease be of tuberculous origin, or due to a toxine derived from the morbid pulmonary tissue. It remains to be determined whether the morbid condition be not a pathological sequence of unstable vascular equilibrium, whatever the primary factors, with hand and foot manifestations due largely to the influence of thoracic troubles upon the circulation.

DISCUSSION.

Dr. Gilchrist said that Dr. Hyde's paper was a very broad one, and embraced a large group of cases, some of which he had examined histologically. In a case of bromidrosis of the feet, sections taken from the reddish margin showed dilatation of the epidermal portion of the sweat ducts and only lymphocytes present. Dr. Hyde's remarks brought to mind a curious feature in connection with different skin diseases showing that there must be some special selective power in certain skin diseases, in attracting only certain cells of the blood. In urticaria there was apparently only polynuclear leucocytes present, in hyperidrosis only lymphoid cells. In urticaria pigmentosa only mast cells were present. It was not often that you would find all the various blood cells in the same type of lesion.

The sympathetic system, he believed, also played an important rôle in producing hyperidrosis. The fact that toxic substances in the system

were attempting to make their exit through the sweat apparatus might set up an acute or chronic irritation, and the protection was afforded by the hyperidrosis. The lymph stream of the hands and feet was extremely sluggish. The circulation was often very poor in the hands in these cases, and the irritating substances that were passing through staid there much longer. This possibly also might give rise to irritation of the skin. Of course, the vulnerability of the individual must be taken into account, together with the very sluggish lymphatic stream.

Dr. RAVOGLI said that he was entirely in accord with the statement made regarding the rôle played by the vaso-motor nerves in the production of these affections, and also in the chronic course of the process. He had at present under his observation a man who had suffered with polyneuritis, which had induced a marked alteration in the shape of the toes and feet. In addition to this, he had two superficial ulcers, which had proved to be extremely difficult to cure. There was no doubt that they were the result of vaso-motor disturbance, interfering with the proper nutrition of the skin. This patient had a syphilitic history.

In reference to the vaso-motor disturbances of the skin he had observed an interesting case of chromidrosis of the feet. The patient was an Italian, whose feet took on a bluish tint, and in warm weather, when he perspired freely, his white socks were stained blue from the perspiration. This man also had syphilis, with some nervous complications.

Dr. HARTZELL said that, some years ago, Erasmus Wilson called attention to the fact that hyperkeratosis of the hands and feet was preceded by marked hyperidrosis. It was a question whether they were both due to a common cause, or whether one was the sequel of the other.

Dr. HYDE, in closing the discussion, said that he would like to call Dr. Pusey's attention to the fact that this was only a preliminary paper, referring solely to dermatoses of the hands and feet.

With respect to the remarks made by Dr. Gilchrist, it was to be noted that the relatively slow current of the lymph in the hands and feet, observed in conditions of health, was greatly modified when an undue pressure was exerted upon the circulation of both blood and lymph in conditions of disease.

PARASITIC SYCOSIS COMMUNICATED FROM CATTLE

By Wm. F. Breakey, M.D., Ann Arbor, Michigan.

Read before the twenty-eighth annual meeting of the American Dermatological Association, Niagara Falls, June 2 and 3, 1904.

ABOUT eight weeks ago a young farmer twenty years of age came with his physician to consult me about a severe inflammatory condition of neck and face, chiefly on one side, involving bearded portion particularly, patches of beard already gone, with crusted nodular masses, furuncular abscesses, burrowing sinuses and a brawny swelling reaching up to the ears and down on the neck.

The mycelia and spores of the tinea tricophyton (barbæ) were readily demonstrated in roots and shafts of hair and beard and in crusts and scrapings of cuticle.

A solution of hyposulphite of soda had been used, and continuing the alkaline wash in the form of soap tincture and an oleate of mercury ointment, the further spread of the parasite and superficial dermatitis was soon arrested. The deeper lesions cleared up more slowly.

The young man had the care of cattle, milking cows and handling them, the whole herd being affected with a disease of the skin and hairs. One animal bought from a drover infected the others.

The patient subsequently appeared at my clinic two or three times at intervals of several days and when last seen was practically well. Unfortunately the patient was not photographed nor the slides at my office saved.

The following letters from his father in reply to my inquiries form an interesting part of the history. May 2nd, '04. "My son is getting along nicely and no others of my family have been affected. Two members of the neighbor's family in whose herd of cattle the disease prevailed, were infected with the disease, but succeded in killing it before the disease spread much. In both of these cases the sores were on the neck below the beard line. In addition one had a sore on the wrist."

"During the winter this disease is a common one through this section among the cattle, lasting from one to two months, then disappearing when not treated. Under treatment it is easily killed with turpentine, tincture of iodine, or sulphur and lard. It appears on cattle mostly on the head and the neck, but sometimes is found on other parts of the body.

"I think I am safe in saying that it can be found among fully one-half of the herds during the winter.

"Regarding animals other than cattle; during the past winter a horse that ran with cattle having the disease became infected on the nose. It was easily cured however. This is the only case of which I know."

Under date of May 23rd he writes: "Replying to your recent favor, I beg to advise that I have tried to find a case of the skin disease among the cattle in this vicinity but have been unsuccessful, as it has entirely disappeared with the coming of warm weather. Nor have I been able to find a human patient. So all I am able to send is some of the skin from my son's face, which I fear may not be useful to you, as the sore is nearly healed. I doubt not that in the fall the disease will again appear among the cattle, and if at that time samples of the skin and the hair will be useful to you, I shall be pleased to be called upon to furnish them."

Since the foregoing was written, Mar. 24th, '04, I received from Mr. H. scales from the face of the patient which were macerated and examined. The first specimen after prolonged teasing showed small bunches of mycelia—very adherent, branching dichotomously. Very few round spores were seen. No distinct jointed structure. Specimen also contained one small animal parasite (?) size of pin point, red, almost round, shaped like pediculus, showing beak and four legs on each side. Slide was destroyed accidentally.

Second specimen showed smaller number of mycelia. No other parasites found.

A few days following the advent of the first patient a second one came to the hospital from an adjoining county with almost identical appearance and history of infection from cattle.

The following is taken from entry in the hospital record and additional data furnished by him concerning his family: "M., age 37, married, admitted March 18th, 1904, farmer. Present trouble with face and neck began about the middle of January. Thinks this came from ringworm on cattle. Began with scaly patch on left cheek size of a nickel. Did not spread until after application of a green salve, and an attack of influenza. It went down on neck and spread over face on both sides. Lesions on neck disappeared and then a patch appeared on the collar bone; this disappeared. Lesions started in separated patches from one side to the other; did not spread by continuity."

"Treatment before coming to the hospital, bichloride of mercury wash for ringworm; then a green salve; then soda hyposulphite wash;

then green salve again. Since March 12th has used gunpowder and vinegar."

"At present, March 18th, around base of neck are papules and indurations. On the under surface of the chin and around the angles of the jaws on both sides are crusted patches, greenish yellow crusts, size of pinhead to size of a cent. Some crusts on chin and lower lip, and isolated crusts on both cheeks above."

Additional history: "In August, 1903, a neighbor bought a young bull from a drover. This animal had patches over the head and anterior part of the body from which the hair had disappeared. The cattle from the two farms broke into fields and ran together and soon began to lose hair in patches. There are probably only three herds infected, but seven or eight men. State Veterinarian saw the cattle and pronounced the condition 'mange and ringworm.'"

"Wife had spots size of half dollar on one leg; well now. One child aged two years, has it in eyebrows and left eyelashes, also left ear. Child aged four years has lesion under left ear, between eyes and on buttocks. Oldest aged seven years had spot on the right side of neck—disappeared now. All children are boys and all have had treatment with soda hyposulphite. Farm hand has spot on left cheek; disappearing. Children acquired disease from the father. Wife from husband or from the children. Farm hand probably from cattle. Neighbor acquired the disease on the left forearm from cattle. Hired boy had it on left cheek. Killed it with gunpowder."

"Steer bought from neighbor spread the disease to another herd."

The photograph of the cow shown is not from either of the herds from which my patients were infected. Nor do I know that anybody was infected from her. I saw her being led by my office window and thinking that providential chance had sent me what I had been trying to secure, as her appearance indicated some local disease of the skin and hair and neck, I got some hairs from the margin of the partially bald neck.

She was ungroomed and ill kept. Her owner stated that she had been lousy, and she was as thin as Pharaoh's "lean kine." She had no "crumpled horn," though she doubtless is a lineal descendant of the "cow that tossed the dog, that worried the cat, that killed the rat," etc., as this is said by veterinarians to be the usual way in which the lower animals infect each other. There was not time for cultures. Slides were not stained as it was not expected they would be photographed. The roots of these hairs even before maceration showed a peculiar shape, somewhat like the head of an asparagus stalk.

The hairs procured failed to show the tricophyton—whether be-

cause there had been none, and the loss of hair had been due to the pediculi, or the ringworm parasite had disappeared as a result of treatment, or spontaneously under improved sanitary conditions of outdoor life, and contact with dry earth, and the normal shedding of hair. Possibly also further effort might have found evidence of the tinea.

The secretary of the Michigan State Veterinary Examining Board writing from Arizona, where he was engaged in dipping sheep for "sheep scab," says: "There is an alarming amount of this trichophyton tonsurans in cattle of the west, and the Bureau of Animal Industry is beginning of late to take action regarding its extermination. In some parts of the West this disease is called 'ringworm,' 'barber's itch,' 'scab,' 'Texas itch,' etc.

"I have seen many cases of the disease in cattle in Michigan in former times, but not to the extent as in the warmer, dryer parts of the West."

A medical student in my class reported that ringworm was found on cattle in Prebble Co., in Ohio, and was communicated to men herding them.

We know that cats and dogs have, and convey, diphtheria. Rats carry the plague. Flies carry the germs of typhoid. Mosquitoes serve as the intermediary hosts of malaria, etc. But it seems that the dangers of disease communicated from the lower animals is not wholly as to systemic conditions, but that parasitic diseases of the skin are also communicated probably much more frequently than has heretofore been thought, and quite often enough to furnish grounds for the growing belief that most, if not all the parasitic diseases of the skin have had their origin in the lower animals.

The so-called "Texas itch" is frequently heard of in various parts of the country. It is not improbable that the eczematous dermatitis going by this name is one of the forms of infection from cattle or other domestic animals.

The micro-photographs of the long jointed mycelium beside a hair shaft is the only micro-organism found in the hair and scales from this cow and is shown as a mould fungus, a saprophyte grown in the dirt and dead matter of the animal's skin, and is instructive only in a negative way.

The photograph of the boy "B" is of an out patient at the hospital three years ago with a sycosis of neck, communicated from a calf which he had the care of and which had disease of the skin and hair.

The following is taken from a hospital record:

History of present attack of five to six weeks' standing—"Noticed first a slight chafing, presumably from a sweater. Lesions are found on neck, especially on left side, and abdomen. Lesions greenish yellow, cupshaped with thickened connective tissue growth on left side." "Diagnosis—Tinea favosa." There was a lumpy folliculitis, and perifolliculitus, followed by suppuration and two small abscesses. He made a slow but good recovery.

The fact that the boy had the care of a calf with disease of the skin was not ascertained on his first appearance and no significance had been attached to that by the family.

The photograph of patient "M" was not taken till he had been in the hospital some time and was much better. After entering the hospital he was sent to the surgical ward, on account of a suspected appendicitis. He was successfully operated upon for appendicitis a short time after (in the interval) and made a good recovery.

The micro-photographs numbers 1, 2, 3, 4, are from hairs from the beard and the scrapings of the face of the same patient which were not procured until the face had greatly improved.

The reports of the Government Bureau of Animal Industry give much valuable information concerning diseases of all kinds (particularly communicable) of cattle, but have almost no information concerning those communicated from domestic animals to man.

And the medical literature is rather meager, more so in this country than in Europe.

The facts learned in an incidental and hurried effort covering different regions indicate a rather widespread territory in which cattle and other domestic animals are affected by various forms of skin parasites and that probably some of them have at the same time both vegetable and animal parasites—tinea and sarcoptes as well as pediculi.

Yesterday a member of my class showed a marginated patch on chin, the hairs and cuticle showed tinea barbæ. He had been dressing the face of the patient whose photograph is shown.

I regret that I have been so occupied with the work of our own State Medical Society that I have not had time to make better preparation of the material here presented. But at the time that I yielded to the persuasive powers of your efficient Secretary after declining to your President, I supposed that I could secure some hairs from the cattle from which my patients were infected, in time to demonstrate the parasite on the animals, but was disappointed. This I expect to do and to procure further evidence of the missing link of demonstration in these cases, as I have through medical friends and cor-

respondence run on to a considerable number and variety of cases of diseases of the skin of domestic animals, that I think may prove worthy of further study.

If, therefore, the Association will accept this as a preliminary report, I will endeavor to complete it or extend it when I can add to the collection and more thoroughly analyze and digest the material, trusting that the discussion which this may receive will assist me in both efforts.

DISCUSSION.

Dr. Grover W. Wende said that it might not be unusual to find ringworm communicated to man from cattle. He thought Dr. Breakey would be interested in the report of a number of such cases, which had occurred in Olean, N. Y., in a person having charge of cattle, who stated that the entire herd was often affected. The clinical picture of the patient represented the kerion form, affecting the beard, and was marked by extensiveness. Subcutaneous abscesses were in evidence. Microscopical examination showed that it was due to the megalosporon endothrix. Dr. Breakey referred to ringworm among sheep; this seldom occurred. The disease referred to was probably that of scabies. Among veterinarians the term mange was rather loosely applied.

Dr. Gilchrist said that it was interesting to note, in connection with these parasitic sycoses, that the fungi were often pus-forming organisms. In one instance, some years ago, he injected a pure culture of one of these parasites into the arm of a man who offered himself for the experiment, and produced pustular lesions, from which he again obtained pure cultures of the organism. He again inoculated the man from this second culture, and again produced pustular lesions. This experiment showed that the pus was formed by the organism, and was not due to secondary infection.

In connection with this subject he would like to refer to a number of cases seen at the Johns Hopkins Dispensary. The cases were usually seen in children, and the lesions were diagnosticated as impetigo contagiosa of the scalp and consisted of scattered, pustular lesions, covered with a superficial, yellowish scab. He made some cultures from these lesions, expecting to obtain the streptococcus or the staphylococcus albus or aureus, but was surprised to get a pure culture of large-spored trichophyton. This occurred in probably twelve or fifteen cases. Another phase of the tricophytic disease was seen often as scattered, dandruff-like lesions in children, and he taught his students to regard all cases of what appears to be dandruff on a child's head as being suspicious of ringworm. One will usually find scattered, broken hairs if one looked diligently for them.

Dr. Frank H. Montgomery would like to ask Dr. Breakey if he found the trichophyton in the lesions on the face, as well as in those on the scalp. In the cases he had seen, he investigated a large number of the superficial lesions on the face; in a few he found the trichophyton, and in a large number staphylococci. Some of the lesions were pustular, and all of them were very superficial. They were not of a scaly type.

Dr. Charles J. White said that the observations reported by Dr. Gilchrist were new to him, and very unusual. In his experience, the lesions caused by the megalosporon ectothrix were usually very deep, and always follicular. It was well recognized that the ectothrix was pyogenic in itself, without the addition of any other organism.

It was surprising how easily the cattle described by Dr. Breakey got rid of their ringworm.

Dr. Francis J. Shepherd had seen quite a number of cases of this affection occurring in grooms who were infected by horses. He had not found it common in cattle. There was at present an epidemic of ringworm of the scalp in Montreal, and in these cases he found the disseminated dandruff, with an occasional broken hair, but no bald patches.

Dr. Ravogli said that in Professor Hebra's clinic many cases of scabies had been reported, where the patients had been infected by attending the camels in the menagerie in Schönbrun. Some years ago, in Cincinnati, he had reported a case of scabies crustosa, where was found an acarus, which proved to be different from the ordinary sarcoptes hominis; it was smaller and somewhat longer, and appeared to belong to one of the animal varieties. The patient was on a farm, where he took care of the sheep. He had also seen cases of itching sensation in individuals who had to do with dogs and other domestic animals, where the affection was not clearly scabies, and yet they got rid of the itching and of the eruption after rubbing an ointment contra scabicem.

Dr. Gilchrist said that there were some rabbits in the John Hopkins pathological laboratory which became affected with some disease about the nose. Dr. Welch asked him to investigate it, and he found evidences of undoubted scabies, but of a type which differed from the variety attacking man. There was present considerable scabbing about the nose and ears, and, upon removing the crusts and examining some of the pus, he found these parasites to be quite numerous. One peculiarity about them was that they were all arranged in pairs.

Dr. Hartzell said that some years ago, at the dispensary of the University Hospital, he saw a farmer from New Jersey who had a large patch of inflamed follicles on the forearm, which he said he had contracted from a calf. When he had made this statement he threw upon the table the ear of the calf, which he had brought with him. It was almost devoid of hair, and covered with numerous scaly patches. He found an abundance of trichophyton in the follicles of the ear. This man told him that the disease was comparatively common in his neighborhood.

Dr. Breakey said, in closing the discussion, that Dr. Wende had misunderstood him. He did not wish to be understood as having confused the acarus found in sheep with the trichophyton. He had quoted from a letter from a man who wrote of "sheep scab," as well as ringworm. In some of these cattle affected with ringworm he was advised that the recovery was spontaneous and prompt, particularly when they were freed from the confinement of the stables and danger of repeated infection, and got out of doors. The opportunity to roll in the dry earth might have had something to do with the recovery without other treatment.

LICHEN PLANUS VERRUCOSUS.

By A. Ravogli, M.D., Cincinnati, O.

Read before the twenty-eighth annual meeting of the American Dermatological Association, Niagara Falls, June 2 and 3, 1904.

LICHEN PLANUS VERRUCOSUS must be considered not as a variety of the disease of Wilson, but only as an anomaly of the lesions of lichen. The papules of lichen, on account of peculiar circumstances, in some regions of the body, attain so great a development and so uneven an appearance as to deserve the name of lichen verrucosus. The same affection has been called by Fordyce[1] lichen hypertrophicus, and on account of the hard, scaly and rough appearance of the epidermis covering the lesions, Vidal and Leloir have called it *lichen ruber corné*.[2]

In a short time a series of four cases of this affection have come under my observation, and I find it of some interest to refer to them for a clinical and pathological study.

This affection occurred in three men and one woman, all at the age of between forty and sixty years. Every one had suffered attacks of lichen planus for years. The lichen had come and disappeared and had left the skin of the legs hard, thick, pigmented and uncomfortably itchy.

On the legs they had noticed papules somewhat larger than in other parts of the body, of the size of the head of a nail. They had often scratched the top of the papules, which had bled, and the blood had formed dark brown crusts. These lesions have gradually shown

[1] Fordyce, J. A. Hypertrophic Lichen Planus. *Journal of Cut. and G. U. Dis., Feb.*, 1897.

[2] Quoted by L. Brocq. *La Pratique Dermatologique*. T. III. Les Lichens, p. 176.

a growth, and have become thickened and have extended, several have coalesced and have formed characteristic hard patches of lichen planus verrucosus.

In the woman the lesions were most developed on the right leg, although a few were on the left; large patches, thick and hard, elevated above the normal skin, somewhat œdematous, covered the external malleolar region.

In one of our male patients the lesions were distributed in the form of a long stripe in the peroneal region of both legs. In another patient the eruption of large lichen papules was limited to the middle and to the lower third of the left leg, while in the other they occupied the internal surface of the whole leg.

According to Schutz,[3] the anterior surface of the leg is the preferred place for this affection, and it is found in individuals with a tendency to varicosities of the lower limbs. This is not the only place where the lesions of lichen planus verrucosus have been observed, but also on the thighs, sacrum and on the forearms. In a case referred to by Fordyce,[4] the lesions affected not only the anterior surface and the popliteal region of the leg, but entirely surrounded the penis and the pubis in the form of large, hard, warty papules. Gebert[5] referred to a case of lichen ruber verrucosus, circumscribed to the scrotum, in which the lesions, excoriated by the action of scratching, looked a great deal like moist papules. Brocq[6] in one case found the same lesions extended to the thighs, shoulders and thorax.

In one of my cases, of which I exhibit the photograph, the internal surface of the left leg shows most of the lesions in the form of large flat papules, which coalescing form a large stripe, beginning underneath the knee joint and extending to the internal malleolar region. The right leg has only a few large papules on the anterior surface, while it is covered with small characteristic papules of lichen planus. The patch of lichen verrucosus consists of seven large warty elevations hard and firm to the touch; some are round and others are oblong in shape, resting on a base of a dark brown color. They are raised up for several millimeters above the normal skin, their edges are irregularly outlined and are covered with rough thickened epidermic masses, which are imbedded deeply in the affected surface. They are

[3] Schutz, J. Ein Beitrag zur Therapie und Aetiologie des Lichen chronicus circumscriptus hypertrophicus. *Archiv. f. Derm. und Syph.*, 1900.

[4] Fordyce, J. A. *Loc. cit.*

[5] Gebert. *Berlin Derm. Gesellsch.*, 3d Dec., 1901. Ref. *Derm. Zeitschr.* Bd. IX., p. 225.

[6] Brocq, L. Les Lichens. *La Pratique Dermatologique.* T. III., p. 209.

rough and appear studded with small holes, which are the opening of the follicles and of the sweat glands. In many instances they are plugged up with epidermic accumulations. The patches so covered with thick, strongly adherent epidermis have a grayish color, which is characteristic of the old lichen lesions. Spots of brown yellowish pigment are seen around the lesions, showing the places where other papules had undergone involution.

The inguinal glands were somewhat enlarged, hard, but not tender. None of the four patients affected with lichen had ever had syphilis. All were of a good physique, had always enjoyed good health and had never had any disease of any consequence. Of two we can say that they had been rather high livers, had enjoyed the moderate use of liquors, and had suffered with attacks of gout.

In all our patients the mucous membrane of the mouth showed alterations as whitish linear patches of cornified epithelium, in the form of stripes on the mucous membrane of the cheeks, and in one in the form of round whitish nodules on the right edge of the tongue.

In the disposition of the lesions in all our cases we find a kind of linear arrangement, which shows a certain law or tendency to group themselves in stripes or bands. Kaposi[7] had already made a variety of lichen which he called moniliformis from the linear arrangement of its lesions. This peculiar disposition was, after a while, confirmed by the observations of Hallopeau and Gardner, Hallopeau and Constensoux, Hallopeau and Villaret,[8] Danlos,[9] Hugo Meyer,[10] Balzer and Mercier,[11] Brocq[12] and D. E. Vollmer.[13]

In all our cases we have remarked that the lichen lesions follow somewhat the disposition of the underlying nerves, and in nearly all cases the lesions have maintained, as a rule, the internal side of the internal line of Voigt. According to Fischel and Pinkus,[14] all lichenoid affections, and especially lichen planus, have been seen to occupy

---

[7] Kaposi, M. Lichen ruber moniliformis. *Viertelj. f. Derm. und Syph.*, 1886, p. 571.

[8] Lichen de Wilson en bandes. *Soc. franc. de Dermat.*, 1898, 1899, 1901.

[9] Danlos. Lichen plan sur une bande nerveuse. *Soc. franc de Derm.*, 1898.

[10] Hugo Meyer. Cas de lichen ruber sur la ligna interne de Voigt du membre inferieur. *Archiv. f. Derm. und Syph.* 1898. B. XLII., p. 59.

[11] Balzer et R. Mercier. Trophoneurose lichenoide en bande lineaire sur le petit sciatique. *Soc. Franc. de Derm.*, 10 Mars, 1898.

[12] Brocq, L. *Ann. de Derm. et Syph.*, 1898, p. 261.

[13] Vollmer, D. E. Ein fall von Lichen ruber planus mit linearer Hautatrophie. *Derm. Zeitsch.* Bd. V., p. 29.

[14] Fischel und Pinkus. Strichförmige Hautauschäge am Bein. *Derm. Zeitschr.* Bd. IX., 1902, p. 1214.

by preference this region of the body. This peculiar disposition of the eruptions is not alone true of this form of lichen, but a linear arrangement of the lesions has been observed and described by Heller[15] in exudative forms, in affections accompanied with hyperkeratosis and in others with exaggerated pigmentation.

Pathological anatomy. One of the lichen patches was removed, hardened in 2 per cent. formalin solution, and then in alcohol. The small pieces were embedded in celloidin and cut in sections for microscopical study.

The epidermis showed a great increase in its layers. The stratum corneum was thickened and showed its lamellar structure not well maintained. Nuclei of the cells were not stained. The stratum lucidum contained abundant granules of dark pigment, and the stratum granulosum and spinosum were greatly developed. Thick epidermic masses surrounded the hair follicles. This epidermic hypertrophy was limited only to the lesions, and the horny masses followed the furrows of the epidermis. In some places the thickening of these layers was greatly increased and the hypertrophic papillæ appeared as round bodies in the middle of the epidermic masses.

In the old lesions the epidermic cells had scarcely perceptible nuclei, which were very feebly stained. All the layers of the epidermis were greatly increased, in the form of interpapillary elongations of epidermic masses making their way down to the deep layers of the derma, separating the enlarged and elongated papillæ. Masses of epidermic cells were found to fill up the ducts of the sebaceous glands, and of the follicles of the hair.

In the deep layers of the epidermis were abundant granules of yellow brown pigment. In the specimens stained with Weigert's fibrin stain the Herxheimer's epithelial fibers are also perceptible, as Juliusberg[16] had already found. Fibrin and leucocytes between the epidermis and the corium were found abundantly. This alteration had been already noted by Caspary,[17] and some time afterward by Max Joseph.[18]

Unna[19] refers to the production of the epidermic masses as the

[15] Heller. Ueber strichförmige Haut erkrankungen. *Int. Atlas Lehr. Hautkrankheiten.*

[16] Juliusberg, F. Eigenthümliche Lichen ruber ähnliche Hautveränderungen des Unterschenkels bei Prurigo Hebrae mit vergleichenden Bemerkungen über Lichen ruber verrucosus. *Festschrifft,* M. Kaposi, 1900.

[17] Caspary. Ueber Lichen ruber. *Viertelj. f. Derm. und Syph.,* 1888, p. 159.

[18] Joseph. Beiträge zür Anatomie des Lichen ruber. *Archiv. f. Derm. und. Syph.,* 1897, Bd. XXXVIII., p. 3.

[19] Unna. *Die Histopathologie der Hautkrankheiten.* Berlin, 1894, p. 317.

cause of a papule of lichen planus becoming one of lichen corné. The stratum spinosum above the swollen papillæ takes so great a development as to form a thick layer, on which the stratum granulosum and corneum lies horizontally, forming hard desquamating epidermic masses which cover the hypertrophied lichen papules.

The alterations of the corium were exceedingly interesting in all its anatomohistological elements. In all our specimens the papillæ were enlarged, elongated, and in some places multiplied, distorted and deformed. They were infiltrated with a large quantity of small cells, and the connective tissues were greatly thickened with infiltration. The tissues forming the derma must have undergone some biochemical changes, which cause them to react rather tardily to the different stains.

With a stronger objective specimens have shown the connective tissue masses in the places free from infiltration to form a strong net of fibers, disposed somewhat irregularly, crossing each other in different directions. The nuclei of the connective tissue corpuscles were not easily seen, and the fibers looked hardened and thickened.

The greatest alterations we have found were on account of the hyperkeratosis in the follicles and in the sebaceous glands. In one of our cases they had been changed into small cystic tumors, surrounded by a thick infiltration and enlarged epithelial layers.

The follicles of the hair in the same way were much enlarged and filled with abundant epidermic cells.

In the corium in the places where the infiltration was not so abundant, the connective tissue fibers could be seen well maintained and the elastic fibers were very perceptible. The corium showed with the Unna-Tanzer Polychrome-blue stain many plasma cells and only scanty mast cells.

The blood vessels were enlarged, and showed a perivascular infiltration. Max Joseph[20] maintained that lichen ruber planus is a disease of the blood vessels. In one of our specimens the alterations of the blood vessels were clearly shown. A blood vessel appeared thrombosed, its walls were surrounded by a large quantity of blood corpuscles effused and scattered in the tissues. This condition of the blood vessels supports the opinion of Schütz, that the varicose veins are the principal cause of lichen planus verrucosus.

In consequence of the vascular alterations an exudation takes place in the corium, which causes an abnormal nutrition of the rete.

---

[20] Joseph, M. *Loc. cit.*

The increased pigmentation which is so conspicuous in lichen lesions is due to the effused coloring matter of the blood, which passes through the blood vessels, or to small interstitial hæmorrhages. The infiltration of the corium is the cause of the increased hyperkeratinisation, which differs from that of the ordinary warts only on account of being much thicker. The thick diffused infiltration of the corium has the same end as other infiltration; it is reabsorbed, leaving the connective tissues in hard, atrophic and cicatricial condition.

It is true that microscopically there exists great similarity in the lesions of lichen planus and pityriasis rubra pilaris; so much so that Kaposi admitted that both are identical affections. This identity, however, was denied by Neumann, Unna, Neisser and others, claiming both to be different diseases. Rosenthal[21] also claimed a close relation between lichen ruber acuminatus and pityriasis rubra pilaris. We believe with Joseph, that in lichen planus the inflammation of the corium with the resulting infiltration of the superficial layers of the corium is the primary cause, the hypertrophy and the hyperkeratinisation of the epidermis is the consequence.

Etiology. Our subject is lichen planus verrucosus, and it would be out of our field to enter the discussion of the causation of lichen planus. We will only point out that out of four cases, three were in men and one in a woman, maintaining the well-known fact that lichen planus verrucosus is more frequent in men than in women.

In a general way we favor the idea of an autotoxic condition as a factor in the production of lichen planus. Violent emotions, prolonged pathemata; in a word, any cause affecting the nervous system is able to induce changes in the general nutrition resulting in the production of toxic elements.

In the same way we are in favor of the opinion of Jacquet,[22] that lichen planus is a morbid expression of the gouty diathesis affecting the nervous system. The same opinion has been maintained by Colcott Fox, Koebner and Lindetrem.[23] For these authors lichen planus would be but a variety of a neurodermatitis.

From our own experience we cannot admit that the papules of lichen planus are the result of the injuries produced by the scratching. They are too well defined and too characteristic of the disease to be

[21] Rosenthal, O. *Berlin Derm. Gesellsch.*, Nov. 1, 1898. *Sitz. Berich. Derm. Zeitschr.* Bd. V., p. 804.

[22] Jacquet, L. Nature et traitement du lichen de Wilson. *Semaine Medicale*, 8 Decembre, 1897.

[23] Lindetrem, A. Contribution a l'etude de l'etiologie du lichen ruber. *Nouvelle Iconographie de la Salpetriere.* Mars, 1898.

attributed to local irritation and excoriations. In nearly all our cases of lichen planus we have found a marked gouty condition. Lichen planus is often accompanied with purpuric spots, which tends to support the opinion of Joseph that the papules of lichen planus are the result of a vascular and perivascular affection. The affection of the capillaries is often the result of the uric acid diathesis.

In reference to lichen planus verrucosus, we believe that the stasis caused by the varicose veins, or by any other cause, is the principal factor of the hypertrophy and of the hyperkeratosis, which produces the enormous development of the lesions.

Treatment. In the treatment of lichen planus verrucosus we have continued the general treatment of lichen planus. Subcutaneous injections with 10 per cent. solution of cacodylic acid repeated three times a week have been beneficial to the general condition of the patient. The lesions, however, must be treated locally. We think that any remedy which acts upon the epidermis, producing superficial necrosis, and at the same time capable of reducing the hypertrophy of the connective tissues, is a remedy adapted to the case. In one case we obtained a good result from a 10 per cent. solution of chrysarobin in traumaticin. In two cases we obtained the complete disappearance of the lesions by touching them with formalin in full strength. In the last cases the exposure to the X-rays caused the disappearance of the hypertrophied papules.

We do not agree with the idea of Joseph[24] of the excision of the papules of lichen verrucosus, for the reason that when we have excised a papule for the purpose of biopsy, a papule has returned in the same place where we performed the excision.

The remedies named have given in our hands satisfactory results, and their action has been helped by local application of 5 per cent. ichthyol salve. We had occasion to see one of our patients only a few days ago, and in the places where the lesions had been there remained only superficial scars, with a somewhat rough epidermis.

---

[24] Joseph, M. Ueber Lichen ruber verrucosus. *Berlin Derm. Gesellsch.* July 4, 1899. Ref. *Derm. Zeitschr.* Bd. V., p. 685.

DISCUSSION.

Dr. Gilchrist said that he had seen a few cases like those reported by Dr. Ravogli. The trouble was purely local and there were no lesions elsewhere. The speaker said he had taken sections of lichen planus in the early stage, and it was very interesting to note the early condition of the lichen planus papule. The process apparently commenced about the sweat-ducts, and there was sinking in of the epidermis. The hypertrophic forms of the disease on the legs were also very interesting. Treatment by curetting and the X-ray was usually beneficial.

Dr. Zeisler said he had practically given up the use of arsenic in the treatment of lichen planus, and had come to look upon this old-time remedy as very unreliable in this affection. It even at times caused an aggravation of the symptoms. He had found the protoiodide of mercury more satisfactory. The local treatment of the hypertrophic forms of the disease had to be energetic. Curettage and applications of chrysarobin frequently failed and led to recurrences. In at least half a dozen cases, the X-rays had given him a perfect result in a marvelously short time, and he had come to regard it by far the best method of treating these cases of the hypertrophic type. In his experience, this form of the disease was comparatively common, at least one-quarter of the cases he saw being of that type.

Dr. Hyde said he agreed with Dr. Zeisler that in the routine treatment of lichen planus the internal use of mercury was preferable to arsenic, and it should be combined with the local use of the X-rays. In the ethiology of the disease, the influence of the nervous system should not be lost sight of. As an illustration of this he cited a case of typical generalized lichen planus in a slender, delicate woman, the eruption appearing after a severe mental shock produced by the loss of one of her family in the recent theatre fire in Chicago.

Dr. Engman thought that the hypertrophic form of lichen planus was not rare, particularly in women with poor circulation. Histologically, all types of the disease were vascular in character, the early changes beginning about the superficial vessels. For that reason, the picture of the vascular changes was similar to that observed in early syphilis, and any contributing factor, such as irritation or poor circulation, would naturally tend toward producing the hypertrophic form. As regards treatment, Dr. Engman said he favored the internal use of mercury, and in order to avoid local irritation, which he thought was often responsible for the spreading of the disease, he laid especial stress upon the use of an antipruritic salve, preferably a menthol ointment or Unna's ointment.

Dr. Stelwagon said he could not entirely agree with Dr. Zeisler. He still employed arsenic with much confidence in the treatment of lichen planus, and placed more value upon it than upon the external treatment.

In many cases of the chronic form of the disease, it was markedly improved and its extension limited by heroic doses of arsenic.

In reply to a question by Dr. Zeisler as to whether he had ever seen the lesions of hypertrophic lichen planus disappear under the use of arsenic, Dr. Stelwagon said that his remarks did not bear particularly upon the hypertrophic form of the disease.

Dr. Gilchrist said he had found arsenic a failure in the treatment of lichen planus, except in the more chronic cases, to which Dr. Stelwagon had probably had reference. The drug usually aggravated the acute cases. The speaker said he had found dilute nitro-muriatic acid of value in the acute type of the disease.

Dr. Zeisler said that while he realized that arsenic would cure almost every case of lichen planus, its use entailed a great deal of risk, produced a great deal of pigmentation, and was accompanied by much loss of sleep on account of the severe pruritus. All these disadvantages could be avoided by the use of the protoiodide of mercury.

Dr. Ravogli, in closing the discussion, said that arsenic had little or no effect upon the hypertrophic lesions of lichen planus. In order to effect a cure in those cases, the infiltrations must be destroyed. In the acute miliary type of the disease, the speaker said he had seen good results follow injections of cacodylic acid. In order to relieve the itching and render the patient more comfortable, he favored the use of salol, in combination with antipyrin.

REPORT OF A CASE OF BLASTOMYCOSIS

By Dr. Henry H. Koehler,

Professor of Skin and Genito-Urinary Diseases, Kentucky University, Louisville, Kentucky.

AND

Dr. Gaylord C. Hall,

Assistant to Chair of Skin and Genito-Urinary Diseases, Kentucky University.

ALTHOUGH cases of blastomycosis are increasing in number, this affection still ranks as one of the rare skin diseases, and the report of every well-authenticated case becomes of interest, as at present, the exact clinical picture of the disease entity as a whole has not been perfectly established.

Blastomycosis seems to start as a cutaneous infection, the lesions appearing at the point of inoculation. A subsequent systemic infection is a possibility and has occurred in several cases.

The immediate effect of the entry of the blastomycetic fungus into the skin is the production of miliary abscesses followed by an ulcerative condition, resulting further in papillomatous outgrowths. The discharge from the lesions is a thin, purulent material in which the fungus is readily demonstrable, and from which cultures can be obtained for the verification of the diagnosis.

A condition most likely to be confused with blastomycosis is lupus verrucosus and, in consideration of the limited number of cases observed, the microscope is needed for the establishment of a positive diagnosis. The histological picture is easily recognized.

Our case was referred to us by Dr. O. M. Kelsey, Elkhorn, Kentucky, and the facts are briefly as follows:

Clinical history: Tom White, colored, aged thirty-nine years, married, occupation farm and section-hand on railroad, entered clinic, Kentucky University, March 28, 1904.

Family history: Father died at sixty, cause unknown. Mother living, aged about sixty-five years, healthy except for rheumatism. The patient is the second child in a family of five; the oldest brother died of typhoid in 1880; the others are all healthy. The patient married in 1895. His wife and three children are in good health, the oldest child being five years old. Wife has had no miscarriages. Patient is a well-built, well-nourished, well-muscled negro, five feet eight inches in height, weighing 148 pounds and somewhat above the ordinary intelligence of his race. He had no knowledge of any diseases in childhood, claiming always to have been in excellent health, excepting typhoid fever seventeen years ago. He denies all venereal diseases and presents no evidence of any.

His present trouble started two years ago as a boil at the angle of jaw, which was opened and the contents expressed. Shortly afterwards he noticed a similar condition on upper inner surface of right leg, which was treated as above, with the additional use of some ointment. Temporary improvement followed, then the condition grew rapidly worse, abscesses appearing, followed by warty excrescences of rapid growth.

An examination made on the morning of entrance showed a large, sharply defined, warty growth, elevated about one and one-half inches above the surrounding skin and extending from under left ear on the neck to the median line. It had a peculiar gray and red mottled appearance and was moist. Pus could be easily expressed from the growth. (Fig. 1.)

The postauricular and a few supraclavicular glands were enlarged

and hard. No distinct odor was noticeable. A similar patch existed on upper inner surface of right leg near the perineum, about six inches long, elevation one inch, sharply defined, and of the same general appearance as the patch on neck.

A patch also existed in the groin, below Poupart's ligament. The glands here were also enlarged and soft, evidently containing pus. Patient says these and the glands of the neck did not enlarge until late in the disease.

Heart, lungs, kidneys and abdominal organs were normal. There were present no evidences of tuberculosis or syphilis. The patient's general health has not been affected by his disease. No blood examination was made.

Operation was performed March 29, 1904, under chloroform anæsthesia. The patches were completely removed, with knife and curette; hæmorrhage was moderate, no vessels requiring ligation. The groin was next opened, and was found to be filled with thick, creamy pus.

The patient reacted nicely, and left the hospital in four days, his treatment consisting, locally, in a generous use of iodoform.

Internally, iodide of potash was given up to 2.3 centigrams three times daily. Under this treatment the ulcerated areas rapidly healed, but with a tendency to the formation of keloid. The patient has a keloid on right shoulder from a knife wound.

April 25th, the patch on inner side of leg had healed, the patch on the neck nearly so, a small sinus still persisting.

The patient was discharged May 15th, in a fine physical condition, weighing 156 pounds, more than he ever weighed before. The ulcerated areas had healed completely.

Slight enlargement still persists in the neck, and he was instructed to continue the iodide.

Microscopical diagnosis: Efforts to locate the fungus by staining the pus and by the potassium hydrate method, were negative. Cultures were then made on agar, Loeffler's blood serum, nutrient gelatin and plates of gelatin. These showed an abundant growth of staphylococcus and a small, unidentified bacillus.

After about five days, however, there appeared on the blood serum and one agar tube, small, whitish colonies of slow growth, irregular around the edges, elevated and densely adherent to culture media: in fact, growing into it, so that for examination it was necessary to remove the whole colony and with it some of the media.

Methylene blue stained only faintly, while gentian violet and

carbol-fuchsin stained the growth intensely. Under the microscope, the growth showed comparatively large oval bodies, some in process of budding and a few elongated branching bodies, simulating mycelial outgrowth: the oval bodies predominated.

Sections of growth, hardened in formalin alcohol, imbedded in celloidin, stained in hæmatoxylin-eosin and hæmatoxylin-picro-fuchsin showed massive epithelial hypertrophy, and in the epithelial growth, numerous small abscesses containing the organism observed in culture.

These could also be detected free between the epithelial cells, sometimes singly, but more often as strings or bunches. There were no giant cells observed in any of the sections.

The condition upon these findings was diagnosed as being, in all probability, a case of blastomycetic infection and as such was exhibited clinically.

In view of the rarity of the affection, the diagnosis was a tentative one, and realizing the importance of a corroborative opinion of a trustworthy nature, specimens of the growth were sent to Dr. Oliver S. Ormsby, of Chicago, whose experience in this disease entitles him to an authoritative opinion. In reply Dr. Ormsby wrote as follows: "The skin section is quite typical of blastomycosis. Large numbers of the organisms are present, in fact, an unusually large number. The second specimen is of epithelial growth with miliary abscesses containing the organisms. The sections are very interesting, and I am sending you one that I stained in which you will find enough to write a book upon."

The photomicrograph (Fig. 2) is made from this section; and in conclusion, we wish to thank Dr. Ormsby for the interest he has shown in this case.

The organism found, in our opinion, partakes more of the nature of a mould than of the yeast plant.

PLATE XLIV.—To Illustrate Article by Dr. Henry H. Koehler and Dr. Gaylord C. Hall.

Fig 1.
Patch of growth on neck showing papillomatous character and tendency to abscess formation. (Picture reversed in engraving.)

No. 2.
Photomicrograph of fungus in tissue section taken from growth on leg.

SOCIETY TRANSACTIONS.

NEW YORK DERMATOLOGICAL SOCIETY.

326th Regular Meeting, September 27, 1904.

Dr. George Henry Fox in the Chair.

Peliosis Rheumatica.

Dr. George Henry Fox presented a patient whom he had seen that day at the clinic for the first time. The patient stated that two weeks ago there was a well marked and extensive purpuric eruption upon the trunk and extremities. There were now rheumatic pains, particularly intense in the shoulders, with considerable œdema of the lower extremities and a slight exfoliation of the numerous patches which now appeared erythematous rather than purpuric.

Dr. Winfield agreed with Dr. Fox's diagnosis of peliosis rheumatica and inquired regarding the hæmorrhages.

Dr. Fox replied that the hæmorrhages had all disappeared, leaving no discoloration.

Dr. Sherwell was inclined to make the diagnosis of erythema multiforme. He recalled a photograph in Dr. Fox's book of erythema multiforme of the lower extremities in which there was a marked purpuric condition. Dr. Sherwell had seen desquamation occur in those cases. He looked upon the condition as one of severe erythema multiforme. Rheumatic pains may and usually do occur, as in peliosis rheumatica.

Dr. H. G. Koltz said in such hæmorrhagic or purpuric eruptions the lower extremities were usually mostly affected, but not in the case presented by Dr. Fox. This condition appeared to be a peculiar one to him.

Dr. Mewborn called attention to the amount of desquamation. The epidermis was detached in the center and adherent around the circumference of the lesions. He was rather inclined to regard it as a case of dermatitis medicamentosa.

Dr. Fox said that the exfoliation seemed to be an unusual phase of the eruption and it looked like a case of dermatitis medicamentosa, although the patient stated that he had taken no medicine before the hæmorrhagic spots appeared.

In answer to Dr. Klotz's statement regarding the lower extremities being usually affected, Dr. Fox said that in some other cases of purpura rheumatica which he had seen the eruption was on the arms; the joints and legs were comparatively free, unlike the ordinary form of purpura simplex.

With regard to the exfoliation following hæmorrhage he had seen hæmorrhages in erythema multiforme but with no subsequent desquamation. The exudation was usually absorbed and the epidermis remained unaffected. In purpura there was not apt to be desquamation. He be-

lieved that the diagnosis of peliosis rheumatica was the only one that could be made in this case.

A Case of Scleroderma, with Symptoms Simulating Addison's and Raynaud's Disease: Marked Improvement from the Administration of Extract of Suprarenal Gland.

Dr. James M. Winfield presented for Dr. C. R. Love, a woman, fifty-two years old, a widow, born in Ireland, who had had one child and no miscarriages. Her family history was negative. A brief history of her condition was given as follows: Prior to September, 1902, her health had been good. About this time she noticed that the hands frequently became cold and discolored. In January, 1903, the joints of her wrist and fingers became stiff and swollen. In April she had an attack of pleurisy and a month later, she noticed the skin was becoming dark. At this time the abdomen was enlarged and for several days had a slight discharge from the umbilicus. From this time on the skin grew darker and darker, and the joints of the wrists and fingers became almost immovable. The ring-fingers of both hands became swollen to more than twice their natural size, and had a purulent discharge from the distal phalangeal joint. At the first examination the patient was found to be emaciated, and the whole integument discolored. She was lying in bed with her knees drawn up, due to the pain and stiffness. Her tongue was dry and coated, appetite poor, nausea, and her bowels were constipated. The skin was dry, hard and cold and she complained greatly of the pain, cold and insomnia. She was treated with dessicated suprarenal capsule and a nutritious diet. There was immediate improvement except for two periods, one when there was substituted the liquor adrenalin, and again when this was stopped altogether. Improvement began as soon as the dessicated gland was resumed.

Scleroderma of Hands with Facial Atrophy (from the hospital*). Presented by Dr. Fox.

The patient was a female, aged sixty-seven years. The disease appeared about seventeen years ago as a numbness and blanching of the fingers and toes when exposed to cold. Later on a tingling sensation was noticed. In about five years the fingers began to ulcerate around the tips and around margins of nails, which finally dropped off. All the fingers are hard, smooth and shiny and constricted in appearance. The fingers are all flexed at first phalangeal articulation, while the thumbs are extended. As a result of the sloughing away, the finger tips are clubbed with small, thickened and brittle nails. The thumbs are not so deformed. Skin around the mouth tight drawn, marring the expression. The condition is always worse in cold weather and the patient is very subject to chilblains.

* Cases presented as (from the hospital) were patients in the New York Skin and Cancer Hospital, where the meeting was held.—Ed.

A Case of Scleroderma Improved under the Use of Dessicated Suprarenal Gland.

Dr. JAMES M. WINFIELD presented, for Dr. Love, a child, aged fifteen years. The child was born in this country. The trouble began three years ago. Family history was negative. At first it was noticed that the hands were apt to be cold, were discolored and slightly stiff, due to a hardening of the skin. The hardening increased gradually until the joints of the wrists and fingers became ankylosed, and the skin immovable. The knuckles became ulcerated and painful and the tips of several of the fingers had trophic ulcers. The muscles of the forearm and hand atrophied. The patient suffered from extreme nervousness and general malaise. The skin of the face next became involved with the same lesions with the exception of ulceration. Next the feet became involved causing pain and discomfort in walking. The treatment was dessicated suprarenal capsule and the improvement was immediate and progressive.

Dr. SHERWELL was surprised at the efficacy of the treatment employed in these cases. Though he could not comprehend its mode of action in these cases, it would certainly seem, from description of past conditions and observation of the present, to have been a fortunate experiment.

Erythema Perstans. Presented by Dr. James M. Winfield.

A girl, aged thirteen years and six months; in December, 1903, her face, hands and wrists began to appear red, "in spots." She applied to me for treatment in September, 1904, then the face was uniformly red except over the malar prominences, the redness had extended down over the neck and part of the chest. The wrists, hands and elbows were covered with small red erythematous spots, all of the redness disappeared upon pressure. In addition to the redness the skin covering the knuckles was rough and scaly, suggestive of psoriasis. The patient complains of the face itching and sometimes of heat. Menstruation not yet established, the patient seems to be perfectly well only slightly nervous.

Dr. SHERWELL said that the only conclusion he could come to in this case was that it was a case of erythema perstans. He had no idea what the cause was, but he thought of a theory which might explain the condition. This was a girl evidently at the period of adolescence and this suggested to him the possibility of a toxæmic origin. She might be troubled with what later might be a dysmenorrhœa, or possibly have an imperforate hymen and perhaps the blood might become absorbed. Evidently there was some disturbance present which produced some neurotic effect.

Dr. KLOTZ thought the condition might be a preliminary stage of something which would later develop. The changes over the elbows and knees, in fact, seemed to show an advanced development. The disease itself was certainly a very unusual one.

Dr. Fox believed there was something more than an erythema present. There was infiltration over the elbows and knuckles and it reminded him

of a case he had seen in private practice. The patient was a beautiful girl and in fair health. She had swellings, or elevations, bright red in color, over all the knuckles of the hands. The case was one that our English confréres would call "chilblain diathesis." He did not think the diagnosis erythema perstans would cover the condition present, but could not suggest any other diagnosis.

A Case of Lupus Erythematosus. Presented by Dr. Mewborn.

The patient was a young woman, a native of Ireland, and a child's nurse by occupation, who gave no history of rheumatism or syphilis, but when a child had suffered from measles and scarlet fever. About a year ago she had had a severe attack of iritis in the left eye, which had been actively treated with potassium iodide at first and later with calomel and soda until a mild stomatitis had developed. After four weeks' treatment a raised reddened patch appeared on the left cheek and one in front of the right ear. The patch on the left cheek developed a "blister" which dried up and formed a scab, which finally fell off leaving a slightly depressed red scar. Other lesions have appeared on the forehead and face and have remained stationary.

The lesion on the left cheek consists of an oval, yellowish, slightly depressed patch with a slightly raised, shiny border which shows a scaly desquamation on scratching with the nail. Around this are scattered about twenty small flattened papules, which, under pressure with a glass slide, show up as yellowish, semi-translucent areas, but without the deeply seated nodular appearance of lupus vulgaris. The lesion in front of the ear has a much more atrophic appearance with the hyperkeratosic border of a patch of lupus erythematosus as do also the lesions on the forehead. The stationary character and long duration, nearly one year, without any improvement from a vigorous specific treatment would be rather against a diagnosis of syphilis. But the case is considered interesting on account of the difficulty of differentiating it from a syphilide on account of the cluster *"en constellation"* on the cheek as well as the history of an iritis.

Dr. Winfield thought the case to be one of erythematous lupus.

Dr. Jackson regarded the case as one of lupus erythematosus. The lesion on the cheek had some irregular features, but the general character of the rest of the patches and the location of one patch in front of the right ear were decidedly in favor of that diagnosis.

Dr. Mewborn, in closing the discussion, said that the grouping of the lesions on the left cheek, the large central lesion with little ones around it, made it appear very much like a syphilide, but there had been nothing about the glandular system or mucous membranes to confirm such a diagnosis. There had been an iritis which might support this view, but there were no adhesions of the iris and the lesions on the face were not improved by the iodides or mercurial treatment.

A Case of Folliculitis Decalvans Affecting the Beard and the Pubic Region. Presented by Dr. Mewborn.

P. B., 45 years old, a native of Italy and a barber by occupation. He is married and has six healthy children. Twenty-five years ago he had gonorrhœa and a soft chancre with no history of secondaries. He had rheumatism fifteen years ago. He smokes but does not drink.

About four years ago he noticed a crusted and fissured lesion on the right cheek near the corner of the mouth which slowly spread until almost the entire beard, except mustache, was affected. Two years ago the pubic region became affected, progressing until all the hair in the genital region had been destroyed.

There has been no itching, no nodular infiltration, and while suppuration in the hair follicles has occurred in the beard the pyogenic process has not seemed to precede, but rather to be grafted upon the superficial inflammatory process which caused the hairs to loosen and fall out.

The beard shows some scaliness in places and the loosened hairs can be epilated without difficulty, only a few retain their root sheath. The epilated hairs, for the most part, are atrophic with pointed roots, and fail to show any signs of fungus on microscopical examination. The patient since childhood has suffered with reddened eyelids and almost all the hairs on arms and legs have been destroyed by keratosis pilaris which is still active in places.

Dr. Sherwell adhered to the diagnosis of folliculitis decalvans in unusual location; the relative absence of pustulation, and the clinical and microscopical evidence, in his mind, seem to confirm it.

Dr. Mewborn, closing the discussion, said there were several objections to the diagnosis of sycosis. It could not have been a case of hyphogenic sycosis because there were no evidences of any fungus and the lack of infiltration or nodular condition was against a staphylococcic sycosis. Again, when the hairs were pulled out in sycosis there was some thickening of their sheaths with escape of pus; in this case there was no sheath and the hairs pulled out easily. It was very much like folliculitis decalvans seen in the scalp, where the hairs pull out slender and soft and without sheaths.

A Case of Epidermolysis Bullosa. (from the hospital). Presented by Dr. Brinkley for Dr. Bulkley.

The patient was a girl of six years, native of Brooklyn, who developed a bulla on the great toe two days after birth. The bulla was filled with clear serum which ruptured in a few days and it was noticed that the slightest injury causes the appearance of bullæ, some of which were filled with a sanguinolent serum. From the age of two years to four years hæmorrhagic vesicles appeared on the tongue. She has twice suffered from pneumonia and has had the measles(?). Was vaccinated at five

years of age unsuccessfully. The patient's parents are healthy and two sisters, one four years older and one a year younger, are perfectly well. At present the nails are markedly thickened and rough, brittle and marked with transverse striæ. A bulla can be raised by rubbing with a wet towel and the patient is subject to chilly sensations so that she is compelled to remain indoors during cold weather. The patient has been under treatment at the Skin and Cancer Hospital since June, 1904, (arsenic internally and a lotion of magnesia and zinc oxide externally with benefit).

A Case of Epidermolysis Bullosa (from the hospital). Presented by Dr. Brinkley for Dr. Bulkley.

The patient was a boy, five years old, in whom the disease made its appearance four years ago. The first lesion followed a scratch on the back of hand. In a few days bullous lesions appeared on the arms and feet, most severe on prominent parts, as elbows, knees, ankles and nose. Vesicles may be induced by severe rubbing, severe injuries cause bullæ with sanguinolent contents. There were hæmorrhagic lesions on the tongue. As in the first case the parents were healthy and two brothers and one sister (all younger) are perfectly well. Under a treatment of iron and arsenic internally and soothing and protecting ointments externally, there has been a great improvement since treatment was commenced about fifteen months ago.

Dr. Mewborn wished to call attention to the congenital absence of toe-nails in the first case. In this connection he referred to the case reported by Dr. G. W. Wende in the January, 1904, Journal of Cutaneous Diseases, in which, in addition to the dystrophy of the nails, there was complete absence of eye-lashes, eye-brows and total alopecia.

A Case of Mycosis Fungoides treated by the X-Ray. (from the hospital). Presented by Dr. Brinkley for Dr. Bulkley.

The patient was a woman, fifty-seven years of age, in whom the disease began two and a half years ago. The first lesion was a bright erythematous spot on the right cheek, which spread slowly for the first five months and then spread rapidly until the eruption became general. The itching was not intense at any time in the progress of the disease. The lesions consist of erythematous patches, thickened and infiltrated patches varying in shade to a purple and dark brown. About a year ago lesions began to break down and ulcerate and the patient became much more restless, unable to sleep, and complaining of pain. X-ray treatment was begun in June, 1904, daily seances of thirty to forty-five minutes, later on two treatments during the day, the last just before retiring. At present all ulcers are healed except a few on the feet and backs of hands.

A Case of Mycosis Fungoides treated by the X-Ray. (from the hopital). Presented by Dr. Brinkley for Dr. Bulkley.

This case, a man forty-six years of age, had been previously shown

before the society about a year ago. Since then he has had about eighty-two exposures of thirty to forty-five minutes each and there has been a steady improvement. Appetite good, sleeps well, infiltration softening down, ulcerations healing.

Dr. Fox referred to a well marked case shown some years ago in which the body was covered with erythematous rings and gyrate lesions. At first he thought the condition was one of psoriasis glabra and the correct diagnosis was not made during the first six months. The patient went to Europe and returned one year later with well marked mycosis fungoides. The patient was shown to the members of the Society. This patient entirely recovered within a year and has remained well ever since. He saw this lady one or two months ago and she was in excellent health and perfectly free from any eruption. This was the first case of mycosis fungoides, under his observation, that had entirely recovered. Although such recoveries had been reported in the Society, personally, he had never met with one before.

A Case of Lupus (from the hospital). Presented by Dr. Fox.

The patient was a woman with lupus vulgaris, who had been subjected to a plastic operation by Dr. Curtis some four years ago, after curetting and grafting had failed. During the last two months she had been under the X-ray treatment and had undergone a marked improvement.

A Case for Diagnosis (from the hospital). Presented by Dr. Fox.

This patient had been seen on previous occasions and no diagnosis had been made. The patient was comparatively well at present. At one time one leg was twice the size of the other. The face was swollen and covered with a verrucous eruption. There were superficial pustules which gradually spread. Various forms of treatment had been tried and it was not known under what treatment he improved most. At times the eruption would break out over the face and scalp, producing superficial ulcerations. The legs, too, were covered with verrucous eruption, and with small vesicles. Iron and arsenic and strychnine have been given. The itching was never severe and there was no neurotic element in the case.

A Case of Lupus (from the hospital). Presented by Dr. Fox.

This patient was a woman who had been under X-ray treatment and nearly all the nodules had disappeared. Whether the cure would be permanent could not be said.

A Case of Tubercular Macular Leprosy (from the hospital). Presented by Dr. Fox.

The patient was a Chinaman who entered the clinic September 27. He

had his trouble for six years and had been in the country for thirteen years. He had been a resident of New Jersey for some time.

Dr. Samuel Sherwell recalled the history of a young man, thirty-two or thirty-four years old, married, and the father of four or five children, who had been a resident of the tropics, and also of Trinidad, and who presented himself at the clinic with anæsthetic patches over the buttocks.

Dr. Fox had obtained excellent results from the use of chaulmoogra oil in leprosy. Although change of climate is a great factor in the improvement of lepers coming from the West Indies and Hawaii the oil will produce most decided effects. Some patients he had found would take the oil freely for some time without any gastric disturbances while other patients could not tolerate it at all. At the Vanderbilt Clinic there was a woman who could take 200 drops of chaulmoogra oil daily without any trouble; she continued to improve under it and was almost well within a year, when unfortunately, at a lecture, she learned the nature of her condition for the first time, studied up the disease and then gave way to utter despondency. He recalled another case of a boy from Mexico who could not take five drops of the oil in any form without vomiting. He recently had made use of an emulsion with Philipp's milk of magnesia, glycerine and oil of gaultheria; with such an emulsion he found that this patient could take sixty to eighty drops of chaulmoogra oil without trouble. He had prescribed it in other diseases of a chronic nature and all his patients could take this emulsion in full doses.

A. D. Mewborn, Secretary.

REVIEW
of
DERMATOLOGY AND SYPHILIS

Under the Charge of John T. Bowen, M.D.

HYPERTROPHIES.

By John T. Bowen, M.D., Boston.

Ichthyose Cornée. (*Ann. de Derm. et Syph.*, March, 1904.)

Danlos presented a case of this disease to the French Society of Dermatology at the meeting of March 4, 1904. The patient was a man of twenty-five years, who had a generalized ichthyosis. The patient declared that he had always been in about the same condition and that none of his family had had a like affection. The disease had all the classical symptoms, plates of scales separated by deep fissures, of a dark color, seated

upon a reddened base. It occupied the usual distribution, the palms, soles, and nails being almost entirely free. On the upper part of the trunk, both in front and behind, the ichthyosis is very slightly marked; but it is much developed upon the arms and legs, there is very little upon the neck and almost none upon the face. The scalp is covered with a seborrhœic desquamation and presents normal, but sparse, hairs. There is scarcely any beard, in spite of the fact that the face is almost immune. The chief point of interest was that the flexures of the joints of the elbow, thighs, axillæ and knees were as much affected as the extensor surfaces, a fact which indicates a resemblance to congenital ichthyosis, from which it varies in other respects from the absence of ectropion and auricular deformities.

Fœtal Ichthyosis in Its Relation to Ichthyosis Vulgaris. J. Méneau (*Ann. de Derm. et Syph.*, Feb., 1903).

A comparison of the definitions of ichthyosis vulgaris and of fœtal ichthyosis given by a majority of authors would convey the impression that they are two absolutely different cutaneous affections. According to them, ichthyosis vulgaris may be defined as an affection beginning at a more advanced time of life, characterized by epidermic scales of variable thickness, resembling more or less in appearance the scales of fishes, and lasting during the whole period of life. Fœtal ichthyosis is a deformity of the skin, present from birth, developed probably about the fourth month of intra-uterine life, and characterized by epidermic plaques, thickened and cornified, of varying color, covering the whole surface of the body, and separated by more or less deep fissures. There are also malformations of the mouth, nose, ears, and extremities. It usually, but not constantly, leads to the death of the patient. If we limit ourselves to these definitions, it would seem that the two affections were absolutely different. The paper by Méneau seeks to prove that the differences between the two affections are more apparent than real; that they sometimes produce identical alterations, the difference only being diagnostic characteristics of relatively secondary importance.

The writer then enumerates the large number of different names that have been given to fœtal ichthyosis, which he retains as the shortest and most fitting title. Clinical differences can be explained without differences in etiology. Tommasoli has cited the co-existence in the same family of a child affected with fœtal ichthyosis and of another with ichthyosis vulgaris. Thibierge has pointed out that it is only the gravest forms of fœtal ichthyosis that we know of; we are absolutely ignorant of what the light forms are or may become; but this is no reason for denying their existence. With this opinion the writer is in accord, as he thinks there are transitional forms between the two affections which are sufficient to establish their common parentage. He divides fœtal ichthyosis into three

forms, severe, medium, and light. The first form comprises the cases developed during intra-uterine life, which are incompatible with life, the diffuse keratoma of Lebert. The second form comprises the cases which are developed within the uterus, but which survive for some days to some months. The third division comprises the cases developed at the moment of birth or post partem, or in the first months of extra-uterine life. They remain stationary, after a certain stage has been reached without hindering the development of the individual. These cases resemble closely ichthyosis vulgaris. The writer then takes up the symptomatology of these different forms. Passing over the description of the first two forms, he says of the third, or light form, that the skin is as if covered with collodion, which is peeling off. The skin has a white, mother-of-pearl color. This covering rapidly becomes dried by contact with the air and splits up, forming small white scales adherent at the center and raised at the edges. The skin seems to have taken on a horny consistency which prevents it from extending; and being too small to envelope the whole body, it cracks in places. These fissures often do not appear until after the birth of the subject when movements are first instituted.

The writer next discusses ichthyosis sebacea, which Kaposi believed was merely a crusting of the new born skin with masses of sebum. The writer regards the term "ichthyosis sebacea" as a false one. It has been used because the sebaceous masses on the skin have some resemblance to the crusty scales of ichthyosis. Yet they are soft, fatty masses which are easily detached from the corium. In severe cases, ichthyosis sebacea may have many points of resemblance with fœtal ichthyosis. In certain cases there are deeper alterations of the skin which terminate in death. Ichthyosis sebacea is only an exaggeration of physiological exfoliation, while fœtal ichthyosis is only an exaggeration of ichthyosis sebacea, the causes being the same, a stronger coherence of the horny cells of the epitrichial layer, from which results the formation of a horny envelope completely analogous to the epitrichium of certain animals. One of the chief arguments in favor of the non-identity of the two processes has been the difference in the seat of the two affections, fœtal ichthyosis, affecting the articular folds, the face, the palms, etc., while this is not true of ichthyosis vulgaris. It is shown, however, that there are several exceptions to this rule to render the argument not convincing. It is further shown that in the same person the skin may present varied aspects, in one part that of simple ichthyosis, in another that of the so-called ichthyosis hystrix. Upon the whole, the symptomatology gives no character absolutely specific of either of the two varieties.

Also the anatomical differences which separate, histologically, ichthyosis vulgaris from fœtal ichthyosis are no more incompatible than the clinical differences with the theory of the identity of the two processes. As in ichthyosis vulgaris, fœtal ichthyosis is characterized by an exagger-

ated production of horny cells, and its alterations resemble those of an ichthyosis vulgaris of colossal dimensions. There is the same hyperkeratosis in each, and the difference in thickness of the Malpighian layer ought not to affect this view.

Etiologically, ichthyosis vulgaris is apt to occur in families and is hereditary, while fœtal ichthyosis is not. Instances, however, are cited where children affected with fœtal ichthyosis were born of ichthyotic parents; and also instances of several children in the same family affected in this way. Moreover, heredity is not absolutely constant in ichthyosis vulgaris.

It is also noted that the two affections pursue a certain evolution, the purely ichthyotic lesions being more pronounced later than at the moment of birth. It is noted that ichthyosis vulgaris is endemic in certain places, which has not been observed in fœtal ichthyosis. It has been shown that both affections may disappear during the existence of infectious diseases, to reappear later on.

Pathologically, there is no full agreement. Some believe that fœtal ichthyosis is a true neoplasm of the horny layer, produced by an increased activity of the germinative layer. Unna has assumed a certain hereditary predisposition of the epithelium, a pathological generalization of what is normally seen to a limited degree in the palms and soles even in intrauterine life.

The hypothesis which seems to Méneau most plausible is that advanced by the reviewer of this article, namely, that the ichthyosis is due to a persistence of the epitrichium, a layer of cells which forms in certain animals a covering for the embryo in parts covered with hair. It appears in the second and third month, and has disappeared, normally, in the human embryo in six months. After the fall of the epitrichium, the normal epidermal layer beneath desquamates with fine scales. In certain cases of defective development, it is assumed that the epitrichium is not detached and remains adherent to the horny layer.

In conclusion, the writer declares that the majority of authors who have written on the subject of fœtal ichthyosis have only included under this term cases of great deformity incompatible with life; while the cases which have a longer life have been confounded with the ordinary form. The malformations and arrests of development may appear in both affections after birth, and whatever may be the degree of the affection, the same lesion is always seen. Hence ichthyosis fœtalis and ichthyosis vulgaris which develops after birth are only degrees of the same pathological process, a different expression of the same form of hyperkeratosis.

A Practical Treatise on the Diseases of the Skin for the Use of Students and Practitioners. By JAMES NEVINS HYDE, M.D., Professor of Skin, Genito-Urinary, and Venereal Diseases in the Rush Medical College, Chicago, etc., and FRANK HUGH MONTGOMERY, M.D., Associated Professor of Skin, Genito-Urinary and Venereal Diseases in the Rush Medical College, Chicago, etc. Seventh and Revised Edition. Lea Brothers & Co., Philadelphia and New York, 1904.

It is twenty-one years since the first edition of this most admirable book issued from the press. Since then it has steadily grown in size, in completeness, in scholarly diction, and in favor with the medical profession. Starting out with 572 pages and sixty-six illustrations, it now forms a stately volume of 938 pages embellished with 141 illustrations. The twenty-one years of its prosperous life have been years of great activity in the development of dermatology as a special branch of medicine, as is shown by the fact that the first edition described only one hundred and twenty-six diseases, while in the present edition there are some two hundred and fifty titles.

The author's reputation for careful and conscientious work is sustained throughout all the many editions. There are eight more diseases described in this edition than in the one just preceding, and radiotherapy and phototherapy are fully presented. With this book in his possession the dermatologist has no reason to buy treatises upon radiotherapy and phototherapy, because all that he needs to know is here. The special treatises on these subjects are voluminous, but a large part of their volume is taken up by matters of electrical science, surgical and medical diagnosis, and photography. Here we have what a dermatologist wishes to know, the diseases of the skin in which light is of therapeutic value, and how to obtain the best results. The authors have found X-rays of great service in acne, cicatrices, epithelioma, hypertrichosis, keloid, keratomia palmaris et plantaris, leucoplakia, lichen planus chronica, mycosis fungoides, nævus pigmentosus, pityriasis rosea, psoriasis, rosacea, sycosis, and tuberculosis cutis.

In common with most observers, our authors have found phototherapy of much less general usefulness than X-rays. They have seen benefit from its use in alopecia areata and small vascular nœvi, in lupus vulgaris, where it is most satisfactory though slow, and in lupus erythematosus, where they regard it as preferable to X-rays.

When a book has become of age in the way this one has he who buys it is sure that he buys a good thing. All the praise that the book has received in the past was deserved, and applies equally to this edition. It is up to date, honest, reliable, and readable. We miss the retrospective view of the boy with the hairy nævus that has so long stood sentinel before the entrance to the book, and extend a cordial greeting to the admirable picture of the girl with xeroderma pigmentosum. The latter is far superior to the former as a work of art. The new photographs all through are excellent.

There is not the least doubt but that the demand for the book will continue just as long as the authors care to devote themselves to the arduous work of getting out new editions. The book has succeeded because it has deserved to succeed. The authors have done their work conscientiously and well, and the publishers have supported them wisely and liberally. G. T. J.

Annex

COLUMBIA UNIVERSITY LIBRARIES

This book is due on the date indicated below, or at the expiration of a definite period after the date of borrowing, as provided by the library rules or by special arrangement with the Librarian in charge.

DATE BORROWED	DATE DUE	DATE BORROWED	DATE DUE
	FEB 11 1955		
	Annex		
	JUN 16 1969		

C28(251)100M

JOURNAL
CUTANEO
VOL 22
FEB 11 1955
Anne
Res
Dr
ON PE
5/29
Lewis Shapiro M.D.
CA Lute